

Treatment with sodium hyaluronate eye drops in a patient who had early-onset bleb leakage after trabeculectomy with mitomycin C

Hideto Sagara^{1,2}
Tetsuju Sekiryu²
Hiroki Noji²
Masashi Ogasawara²
Kimihiro Imaizumi²
Keiko Yago³

¹The Marui Eye Clinic, Minamisoma,
²Department of Ophthalmology,
School of Medicine, Fukushima
Medical University, ³Northern
Fukushima Medical Center, Fukushima,
Japan

Abstract: We present the case of a 47-year-old man who had bilateral proliferative diabetic retinopathy and neovascular glaucoma. Schirmer I test revealed tear secretions of 5 mm and 3 mm in the right and left eyes, respectively. Tear breakup times in the right and left eyes were 7 and 8 seconds, respectively. The ocular surface staining in both eyes was scored as Grade 1 as per the Oxford scheme. Retinal photocoagulation was performed for correction of the proliferative diabetic retinopathy and rubeosis iridis, which resolved with treatment. However, the intraocular pressure in the left eye could not be adequately controlled. Therefore, trabeculectomy with mitomycin C using limbal-based conjunctival flap was performed. Three hours after the surgery, the patient developed a large and diffuse filtering bleb, but no leakage occurred from the conjunctival scar. However, on the first postoperative day, leakage was noted and the conjunctiva was at the leakage point. The leakage resolved transiently, but recurred the next day. Severe keratoconjunctival epithelial failure was detected, and the patient was administered 0.1% sodium hyaluronate eye drops six times daily. The epithelial failure improved, and many microcysts were detected on the bleb surface where the epithelial failure improved. The leakage resolved 2 days after initiation of the sodium hyaluronate eye drops. The microcysts disappeared and the bleb surface became smooth 1 month later.

Keywords: trabeculectomy, bleb, bleb leak, microcyst, sodium hyaluronate

Introduction

The study adhered to the tenets of the Declaration of Helsinki principles. Treatment was administered after the purpose of the study was explained to the patient and they provided informed consent. Doctors explained that sodium hyaluronate eye drops effectively treat dry eye and rarely cause severe side effects. Moreover, the patient was told that the sodium hyaluronate eye drops prevent complications of trabeculectomy with mitomycin C (MMC).

Patients with a history of trabeculectomy may occasionally present with early-onset bleb leakages, which is difficult to treat in some cases.^{1,2} Treatment with sodium hyaluronate eye drops has been reported to be efficacious for dry eye³ and prevents late-onset bleb leakage after trabeculectomy with MMC.⁴ Epithelial failure of the bleb wall caused by tear dysfunction could contribute to late-onset bleb leakage after trabeculectomy with MMC,^{4,5} and dry eye was suspected as one cause of late-onset bleb leakage.⁵ Reports indicate that late-onset bleb leaks in patients with ocular surface diseases can be treated effectively by using a combination of sodium hyaluronate and autologous serum eye drops.⁶ Considering these findings, we speculated that tear dysfunction and/or epithelial failure of the bleb surface impedes wound healing and contributes to early-onset bleb leakage. In this report, we present a case of early-onset

Correspondence: Hideto Sagara
The Marui Eye Clinic, I-83-3, Honjinmae
Haramachi-ku, Minamisoma, Fukushima
Prefecture 975-0062, Japan
Tel +81 2 4424 0101
Fax +81 2 4424 0148
Email hide1234@ruby.ocn.ne.jp

bleb leakage, tear dysfunction, and epithelial failure of the bleb surface after trabeculectomy with MMC that was treated using sodium hyaluronate eye drops.

Case report

The patient was a 47-year-old man who had bilateral proliferative diabetic retinopathy, neovascular glaucoma, and tear dysfunction. Schirmer I test revealed tear secretion levels of 5 and 3 mm in the right and left eyes, respectively. Tear breakup times were 7 and 8 seconds for the right and left eye, respectively. The ocular surface staining with fluorescein dye⁷ was scored as Grade 1 in both eyes. Accordingly, retinal photocoagulation was performed to treat the proliferative diabetic retinopathy and rubeosis iridis; the latter resolved completely with treatment.

However, despite the administration of the maximum tolerated doses of topical antiglaucoma medications, intraocular pressure (IOP) continued to remain high, with the level in the left eye exceeding more than 25 mmHg. Therefore, trabeculectomy with MMC using limbal-based conjunctival flap was performed; during surgery, 0.04% MMC was applied for 5 minutes. Tenon's capsule was not excised, and the conjunctival flap and the underlying Tenon's capsule were closed tightly with shoelace 10-0 nylon sutures. Three hours after the operation, a large and diffuse filtering bleb was detected; however, no leakage of the conjunctival scar was noticed. However, leakage was detected on the first postoperative day, and the IOP was 7 mmHg with noncontact tonometer. Resuturing the conjunctiva at the point of

leakage stopped the leakage transiently, but it resumed the next day even though the subject was treated with a compression bandage after resuturing. On examination, severe keratoconjunctival epithelial failure (Figure 1) was detected, and the patient was treated with 0.1% sodium hyaluronate eye drops (Hyalein; Santen Pharmaceutical Co Ltd, Osaka, Japan) administered six times daily with the patient lying supine to allow the drops to spread onto the upper blebs. With this treatment, improvement in the epithelial failure was seen at some sites, which showed the presence of many microcysts on the bleb surface; the leakage resolved completely 2 days after starting the sodium hyaluronate eye drops without using compression bandage (Figure 2). One month after starting this treatment, the microcysts disappeared; the bleb surface was smooth; and the IOP was 10 mmHg (Figure 3). However, subsequently, 18 months after starting the application of sodium hyaluronate eye drops, the bleb was found to be flat and IOP was poorly controlled despite administration of maximum tolerated doses of topical antiglaucoma medications and exceeded 22 mmHg in the left eye. Therefore, trabeculectomy was performed, and thereafter, IOP has remained in control, at less than 15 mmHg, over a period of 5 years.

Discussion

Severe, early-onset bleb leakage causes various serious complications, including choroidal effusions, suprachoroidal hemorrhage, hypotonous maculopathy, and endophthalmitis. In addition, the resulting flat bleb may promote the forma-

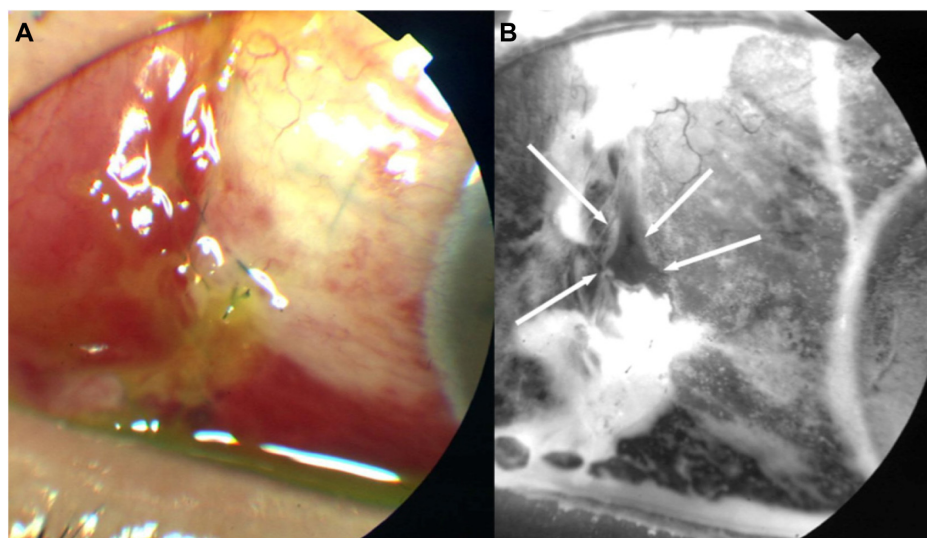


Figure 1 Apparent point leakage with severe ocular surface failure.

Notes: (A) Anterior segment photograph taken using a fundus camera 2 days after trabeculectomy. (B) The fundus camera in the fluorescein angiogram mode can distinguish exciting light from emitted light and allows the examination of epithelial failure in high contrast by using the appropriate filters. Severe epithelial failure of the bleb wall and cornea is observed and a leakage point is visible (arrows).

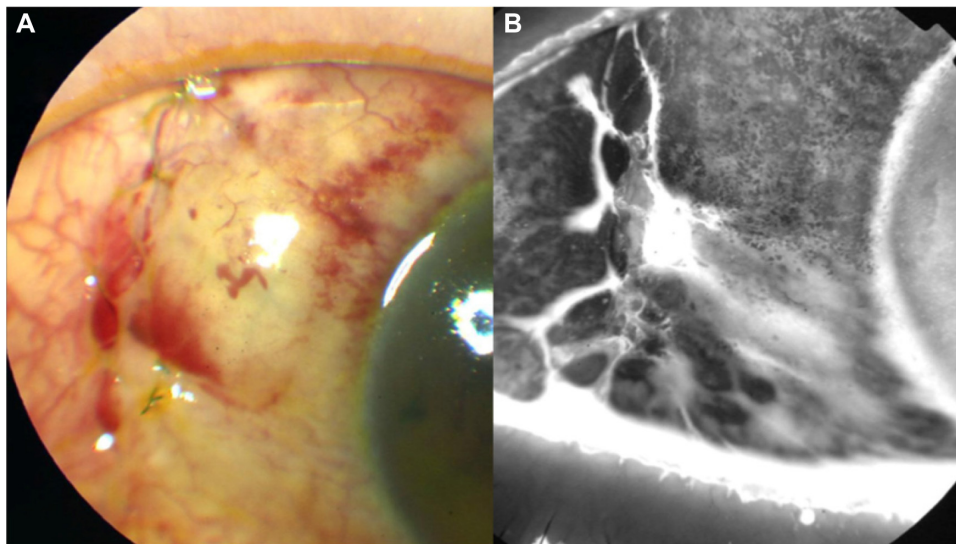


Figure 2 (A and B) Photographs obtained 2 days after the initiation of sodium hyaluronate eye drops.

Notes: The images show improvement of epithelial failure and resolution of the leakage point. Several microcysts are visible on the bleb surface at the sites where the epithelial failure showed improvement.

tion of adhesions between the roof and the base of the bleb, thereby hampering bleb evolution and increasing the risk of bleb scarring and failure. Early bleb leakage (caused by wound leak or conjunctival button holes) may be related to deficient wound closure, patent stitch tracts, or surgical trauma to the conjunctiva.^{1,8} In addition, the use of augmenting antimetabolites may suppress wound healing and further increase the risk of bleb leak.⁹ Severe, early-onset bleb leakage must be promptly treated to prevent the occurrence of these serious complications. However, in some cases, it

is difficult to detect the exact reason for the leak, and it can continue to persist for more than 100 days.² On the other hand, ocular surface complications following trabeculectomy with MMC are fairly common.¹⁰

In this case, we observed severe epithelial failure of the bleb wall, and the leakage recurred soon after resuturing. The severe epithelial failure on the bleb wall hindered the reepithelialization of the conjunctival scar, thereby contributing to the development of early leakage after trabeculectomy with MMC. Many microcysts were detected

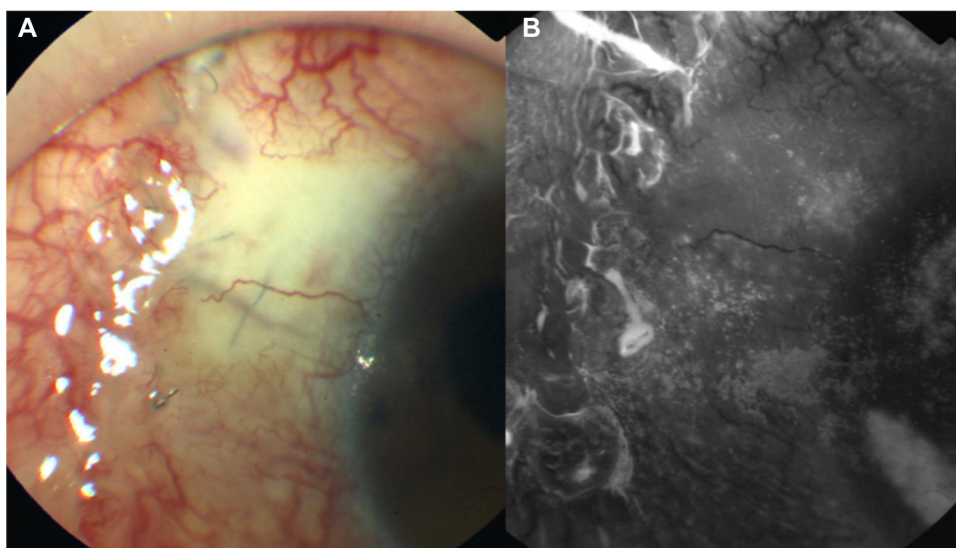


Figure 3 (A and B) Photograph taken 1 month after initiation of treatment with sodium hyaluronate eye drops.

Note: The microcysts are absent and the bleb surface is smooth.

on the bleb surface at sites where the epithelial failure showed improvement. Similar microcysts are frequently observed on the surface of the cornea with bullous keratopathy and in the presence of stromal edema of the cornea.¹¹ These microcysts frequently appear on functional, thin bleb surfaces.⁴ This case reiterates the findings of Sagara et al,⁴ who reported that microcysts occur on the avascular bleb surface when the defective epithelial area of the bleb wall showed improvement following the use of sodium hyaluronate eye drops. They speculated that stromal edema of the conjunctiva, which is caused by the aqueous humor within the bleb, induced the formation of microcysts in the presence of a thin conjunctival epithelium.⁴ Therefore, in this case, the microcysts may have appeared as a result of the reepithelialization of the bleb wall because the leakage from the defective epithelial area was suppressed by the presence of the thin conjunctival epithelium.

Sodium hyaluronate can suppress the breakup of the precorneal tear film.¹² The tear fluid contains various cytokines, such as epidermal growth factor and vitamin A, which help maintain the normal histology of the conjunctiva.^{13,14} Therefore, in our case, the application of sodium hyaluronate eye drops may have suppressed the breakup of the tear film and promoted the reepithelialization of the bleb surface.

However, the incidence of flattening or encapsulation of the bleb tends to be greater when sodium eye drops are administered immediately after trabeculectomy and continued for a long time.⁴ Sodium hyaluronate eye drops may advance fibrosis of the bleb wall and decrease bleb function when administered immediately after trabeculectomy. In the present case, the bleb was eventually rendered flat, and reoperation had to be performed to suppress the IOP. To avoid this, it is necessary to stop administration of the drops before the bleb becomes flat.

Conclusion

Close monitoring of the bleb surface after trabeculectomy is important, particularly in the presence of tear dysfunction

and/or ocular surface disorder. Our experience in this case suggests that the application of sodium hyaluronate eye drops may effectively resolve posttrabeculectomy early-onset bleb leaks that are caused by epithelial failure of the bleb wall.

Disclosure

The authors report no conflicts of interest in this work.

References

- Alwitary A, Rotchford A, Patel V, Abedin A, Moodie J, King AJ. Early bleb leak after trabeculectomy and prognosis for bleb failure. *Eye*. 2009;23(4):858–863.
- Henderson HW, Ezra E, Murdoch IE. Early postoperative trabeculectomy leakage: incidence, time course, severity, and impact on surgical outcome. *Br J Ophthalmol*. 2004;88(5):626–629.
- Mengher LS, Pandher KS, Bron AJ, Davey CC. Effect of sodium hyaluronate eye drops (0.1%) on break-up time (NIBUT) in patients with dry eyes. *Br J Ophthalmol*. 1986;70(6):442–447.
- Sagara H, Iida T, Suzuki K, Fujiwara T, Koizumi H, Yago K. Sodium hyaluronate eye drops prevent late-onset bleb leakage after trabeculectomy with mitomycin C. *Eye*. 2008;22(4):507–514.
- Sagara H, Yago K. Dry eye and bleb leaks after trabeculectomy with mitomycin C. *Folia Ophthalmol Jpn*. 2004;55:18–21. Japanese.
- Sagara H, Iida T, Saito K, Noji H, Ogasawara M, Oyamada H. Conservative treatment for late-onset bleb leaks after trabeculectomy with mitomycin C in patients with ocular surface disease. *Clin Ophthalmol*. 2012;6:1273–1279.
- Methodologies to diagnose and monitor dry eye disease. Report of the Diagnostic Methodology Subcommittee of the International Dry Eye WorkShop (2007). *Ocul Surf*. 2007;5(2):108–152.
- Rand Allingham R, editor. *Shields' Textbook of Glaucoma*. 5th ed. Philadelphia, PA: Lippincott Williams & Wilkins; 2005.
- Cohen JS, Greff LJ, Novack GD, Wind BE. A placebo-controlled, double-masked evaluation of mitomycin C in combined glaucoma and cataract procedures. *Ophthalmology*. 1996;103(11):1934–1942.
- Ono T, Yuki K, Ozeki N, Shiba D, Tsubota K. Ocular surface complications after trabeculectomy: incidence, risk factors, time course and prognosis. *Ophthalmologica*. 2013;230(2):93–99.
- Tuft S. The cornea. In: Spalton DJ, Hitchings RA, Hunter PA, Tan JCH, Harry J, editors. *Atlas of Clinical Ophthalmology*. 3rd ed. Philadelphia, PA: Elsevier-Mosby; 2005:147–186.
- Hamano T, Horimoto K, Lee M, Komemushi S. Sodium hyaluronate eye drops enhance tear film stability. *Jpn J Ophthalmol*. 1996;40(1):62–65.
- Watanabe H, Ohashi Y, Kinoshita S, Manabe R, Ohshiden K. Distribution of epidermal growth factor in rat ocular and periocular tissues. *Graefes Arch Clin Exp Ophthalmol*. 1993;231(4):228–232.
- Huang AJ, Tseng SC, Kenyon KR. Change of paracellular permeability of ocular surface epithelium by vitamin A deficiency. *Invest Ophthalmol Vis Sci*. 1991;32(3):633–639.

International Medical Case Reports Journal

Publish your work in this journal

The International Medical Case Reports Journal is an international, peer-reviewed open-access journal publishing original case reports from all medical specialties. Previously unpublished medical posters are also accepted relating to any area of clinical or preclinical science. Submissions should not normally exceed 2,000 words or

Submit your manuscript here: <http://www.dovepress.com/international-medical-case-reports-journal-journal>

4 published pages including figures, diagrams and references. The manuscript management system is completely online and includes a very quick and fair peer-review system, which is all easy to use. Visit <http://www.dovepress.com/testimonials.php> to read real quotes from published authors.

Dovepress