



Case report

Improvement of thrombocytopenia after treatment for *Helicobacter pylori* in a patient with immunologic thrombocytopenic purpura

Aline Maia Rocha^{a,*}, Luís Fábio Barbosa Botelho^a, David Maia Rocha^b

^a Universidade Federal da Paraíba (UFPB), João Pessoa, PB, Brazil

^b Universidade Estadual do Ceará (UECE), Fortaleza, CE, Brazil

ARTICLE INFO

Article history:

Received 25 July 2013

Accepted 18 December, 2013

Keywords:

Immune thrombocytopenic purpura

Helicobacter pylori

Platelet count

Causes

ABSTRACT

Immune thrombocytopenic purpura is the most common autoimmune hematologic disease, affecting individuals of different ages. Recently, the bacterium *Helicobacter pylori* entered the list of causes of immune thrombocytopenic purpura. Here we present the case of a 55-year-old female patient with low platelet counts initially attributed to chronic vaginal bleeding. As corticosteroid therapy was ineffective she was treated for *H. pylori* infection. Within four weeks the patient had a platelet count of $87.17 \times 10^9/L$ accompanied by clinical improvement of the symptoms.

© 2014 Associação Brasileira de Hematologia, Hemoterapia e Terapia Celular.
All rights reserved.

Introduction

Immune thrombocytopenic purpura (ITP) is the most common autoimmune hematologic disease, affecting individuals of different ages. The former name ('idiopathic' thrombocytopenic purpura) was used because, in most cases, the underlying cause was unknown. In recent decades, the list of causative agents has grown considerably and the term idiopathic is used less often. The recent entry of the bacterium *Helicobacter pylori*, the agent responsible for the most common

chronic human infection in the world, in this list of causes has been the subject of several studies.¹

H. pylori, a Gram-negative microaerophilic commensal bacterium that colonizes the human stomach, is globally known as a causative agent of gastritis, peptic ulcers and a risk factor for the development of gastric cancer and mucosa-associated lymphoid tissue lymphoma. Infection has also been associated to non-digestive diseases such as coronary heart disease, acne rosacea, chronic idiopathic urticaria and autoimmune diseases (rheumatoid arthritis, thyroiditis, Sjogren's syndrome and Henoch-Schonlein purpura).² The

*Corresponding author at: Universidade Federal da Paraíba, Cidade Universitária, 58051-900, João Pessoa, PB, Brazil.

E-mail address: lliny2010@yahoo.com.br (A.M. Rocha).

1516-8484/\$ - see front matter © 2014 Associação Brasileira de Hematologia, Hemoterapia e Terapia Celular. Published by Elsevier Editora Ltda. All rights reserved.

DOI: 10.5581/1516-8484.20140035

prevalence of *H. pylori* is variable in the population, reaching up to 80% but, in general, is less frequent in ITP patients.²

The relationship between *H. pylori* infection and ITP was first described in 1998, by an Italian group that reported a significant increase in the platelet numbers in eight of 11 patients in whom the bacterium was eradicated.³ In recent years, several studies have also shown that *H. pylori* eradication in infected patients with ITP could lead to a substantial and persistent increase in platelet counts in over half of the patients treated.

Case report

A 55-year-old female patient was diagnosed with ITP 10 years ago. Previously, the patient had been hospitalized due to severe thrombocytopenia. She was then treated with corticosteroids (1 mg/kg Prednisone) and had a satisfactory response. After that, she did not need to use this medication for a long time. Her first hospitalization was in another facility. There was little information on exams, just the patient's report. She was asymptomatic until May 2012 when she was admitted to the University Hospital, complaining of asthenia for eight days. Her platelet count was $56 \times 10^9/L$ and hemoglobin 5.84 g/dL with microcytic hypochromic anemia. During hospitalization, treatment was conducted with 1 mg/kg prednisone, with which she showed no clinical or laboratory improvement. Iron deficiency anemia was confirmed by ferritin levels; this was attributed to chronic vaginal bleeding.

Thus, with no response to initial corticosteroid therapy, she was prescribed pulse therapy of 1g methylprednisolone per day for three days, followed by 400 mg/kg immunoglobulin per day for five days. Again there was no clinical or laboratory improvement and the patient remained thrombocytopenic 15 days after completion of pulse therapy. The karyotype and immunophenotype of bone marrow were normal. A myelogram showed no significant changes. Serology for human immunodeficiency virus (HIV), hepatitis B and hepatitis C were negative as were fluorescent antibody virus neutralization assays and immunoglobulin G (IgG) and immunoglobulin M (IgM) for anticardiolipin antibodies. As the patient's platelet count was less than $100 \times 10^9/L$, upper gastrointestinal endoscopy was not indicated.

Based on reports of a positive urease test during the previous endoscopy, but with no other abnormalities, treatment for *H. pylori* infection was carried out for 14 days. The treatment was initiated after a positive IgG serology for *H. pylori* because there was no increase in the platelet levels 15 days after the end of the corticosteroid and immunoglobulin treatment. A breath test was not performed as it was unavailable in the facility. An increase in the platelet count of $22.32 \times 10^9/L$ was observed in seven days after the end of the eradication treatment using medication scheme 1 (clarithromycin, amoxicillin and proton pump inhibitor) and four weeks later the patient had a platelet count of $87.17 \times 10^9/L$ with clinical improvement (Figure 1). Subsequently, another endoscopy was performed and the urease test was negative. The patient remains in remission 15 months after completing treatment, with a platelet count of $178 \times 10^9/L$.

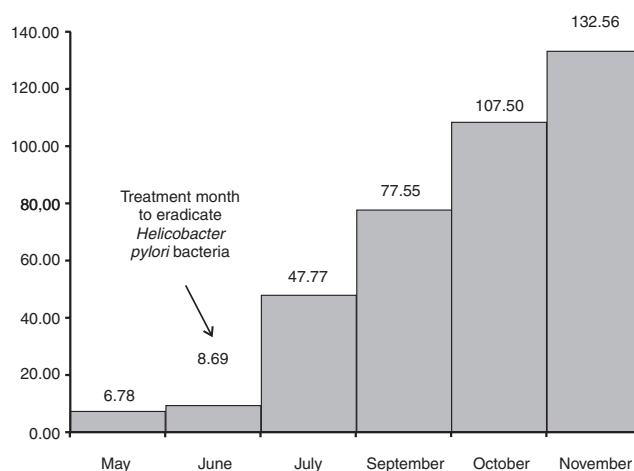


Figure 1 – Mean platelet count response to the eradication of *Helicobacter pylori* bacteria. The treatment to eradicate *H. pylori* was carried out in June 2012, and, from then on, there was a great increase in the platelet count.

Many interpretations have been suggested for the pathogenic mechanism, but the phenomenon is still poorly understood.^{1,2} Studies show that the outcome of bacterial eradication may depend on genetic factors of the host, on environmental factors or even on the *H. pylori* strain.² Of the several hypotheses on the mechanism by which the bacterium could cause ITP, the most accepted is molecular mimicry; that is, the bacterium induces the production of antibodies against antigens of its surface and, thus there is a cross-reaction against multiple platelet glycoprotein antigens.⁵

In some patients with chronic ITP, infections are associated with the exacerbation of thrombocytopenia.⁶

The main schemes prescribed to eradicate the *H. pylori* bacterium are relatively simple, accessible and rarely have any side effects. Extensive studies have shown a significant relationship between bacterial eradication and improvement in platelet counts. Thus, it seems reasonable to investigate *H. pylori* in ITP patients, especially in populations with a high prevalence of infections by this bacterium.⁵

Conflicts of interest

The authors declare no conflicts of interest.

REFERENCES

- Ahn YS. Triple play of *H. pylori* in ITP. *Blood*. 2010;115:4155-6.
- Emilia G, Luppi M, Zucchini P, Morselli M, Potenza L, Forghieri F, et al. *Helicobacter pylori* infection and chronic immune thrombocytopenic purpura: long-term results of bacterium eradication and association with bacterium virulence profiles. *Blood*. 2007;110:3833-41.
- Stasi R, Sarpatwari A, Segal JB, Osborn J, Evangelista ML, Cooper N, et al. Effects of eradication of *Helicobacter pylori* infection in patients with immune thrombocytopenic purpura: a systematic review. *Blood*. 2009;113:1231-40.

4. Jarque I, Andreu R, Llopis I, De la Rubia J, Gomis F, Senent L, et al. Absence of platelet response after eradication of *Helicobacter pylori* infection in patients with chronic idiopathic thrombocytopenic purpura. *Br J Haematol*. 2001;115:1002-3.
5. Stasi R, Provan D. *Helicobacter pylori* and Chronic ITP. *ASH Education Book*. 2008;206:11
6. Semple JW, Aslam R, Kim M, Speck ER, Freedman J. Platelet-bound lipopolysaccharide enhances Fc receptor-mediated phagocytosis of IgG-opsonized platelets. *Blood*. 2007;109:4803-5.