

Histopathological Evaluation of Protective Effect of Telmisartan against Radiation-Induced Bone Marrow Injury

Masoomeh Fooladi¹*, Mohsen Cheki², Alireza Shirazi¹, Peyman Sheikhzadeh³, Mahsa Amirrashedi^{1,4}, Fatemeh Ghahramani⁵, Mehdi Khoobi^{6,7,*}

ABSTRACT

Background: Radiation-induced hematopoietic suppression and myelotoxicity can occur due to the nuclear accidents, occupational irradiation and therapeutic interventions. Bone marrow dysfunction has always been one of the most important causes of morbidity and mortality after ionizing irradiation.

Objective: This study aims to investigate the protective effect of telmisartan against radiation-induced bone marrow injuries in a Balb/c mouse model.

Material and Methods: In this experimental study, male Balb/c mice were divided into four groups as follow: group 1: mice received phosphate buffered saline (PBS) without irradiation, group 2: mice received a solution of telmisartan in PBS without irradiation, group 3: mice received PBS with irradiation, and group 4: mice received a solution of telmisartan in PBS with irradiation. A solution of telmisartan was prepared and administered orally at 12 mg/kg body weight for seven consecutive days prior to whole body exposing to a single sub-lethal dose of 5 Gy X-rays. Protection of bone marrow against radiation induced damage was investigated by Hematoxylin-Eosin (HE) staining assay at 3, 9, 15 and 30 days after irradiation.

Results: Histopathological analysis indicated that administration of telmisartan reduced X-radiation-induced damage and improved bone marrow histology. The number of different cell types in bone marrow, including polymorphonuclear /mononuclear cells and megakaryocytes significantly increased in telmisartan treated group compared to the only irradiated group at all-time points.

Conclusion: The results of the present study demonstrated an efficient radioprotective effect of telmisartan in mouse bone marrow against sub-lethal X-irradiation.

Citation: Fooladi M, Cheki M, Shirazi AR, Sheikhzadeh P, Amirrashedi M, Ghahramani F, Khoobi M. Histopathological Evaluation of Protective Effect of Telmisartan against Radiation-Induced Bone Marrow Injury. *J Biomed Phys Eng.* 2022;12(3):277-284. doi: 10.31661/jbpe.v0i0.2012-1243.

Keywords

Radiation; Ionizing; Radioprotector; Bone Marrow; Telmisartan

Introduction

In recent years, due to increasing risk of nuclear disasters, occupational irradiation, and the widespread use of ionizing radiation in modern medicine, the use of safe and effective radioprotectors is highly required [1, 2].

Bone marrow, as one of the main components of the hematopoietic system, is very sensitive to ionizing radiation. Radiation damage in bone marrow can affect the proliferative ability in hematopoietic progenitor

¹PhD Candidate, Department of Medical Physics and Biomedical Engineering, Faculty of Medicine, Tehran University of Medical Sciences, Tehran, Iran

²PhD, Department of Medical Imaging and Radiation Sciences, Faculty of Paramedicine, Ahvaz Jundishapur University of Medical Sciences, Ahvaz, Iran

³PhD, Department of Nuclear Medicine, Imam khomeini Hospital complex, Tehran University of Medical Sciences, Tehran, Iran

⁴PhD Candidate, Research Center for Molecular and Cellular Imaging, Tehran University of Medical Sciences, Tehran, Iran

⁵MSc, Radiotherapy-Oncology Center, Yas Hospital, School of Medicine, Tehran University of Medical Sciences, Tehran, Iran

⁶PhD, Biomaterials Group, Pharmaceutical Sciences Research Center, The Institute of Pharmaceutical Sciences (TIPS), Tehran University of Medical Sciences, Tehran, Iran

⁷PhD, Department of Medicinal Chemistry, Faculty of Pharmacy, Tehran University of Medical Sciences, Tehran, Iran

*Corresponding author: Mehdi Khoobi Biomaterials Group, Pharmaceutical Sciences Research Center, The Institute of Pharmaceutical Sciences (TIPS), Tehran University of Medical Sciences, Tehran, Iran
E-mail: m-khoobi@tums.ac.ir

Received: 8 December 2020
Accepted: 20 January 2021

cells as well as immune system, which is the most important determinant of radiation-induced mortality [3]. On the other hand, a decrease in the number of peripheral white blood cells, especially lymphocytes following radiation therapy, has been widely reported. Given the key role of white blood cells in improving the immune system against cancer, reducing their number due to the radiation therapy can be a negative prognosis for survival and response to the treatment in patients with cancer. Therefore, protection and recovery of bone marrow (myeloprotection) is essential for survival and life quality of cancer patients undergoing radiation therapy [4, 5].

Over the past few decades, the development of new radioprotectors with natural or synthetic origin has always been of great interest. Despite many studies in the field of radioprotectors, no compound has been found for optimal radiation protection effects without toxicity [6]. The currently available radioprotector is amifostine, which has been clinically approved by the Food and Drug Administration (FDA). Although amifostine offers good radioprotection properties, its side effects, including hypotension, nausea, and vomiting have limited its acceptability. With this in mind, researchers have paid more attention to find less toxic and more effective radioprotectors, easily administered [7]. Previous studies have shown that modulating drugs of renin-angiotensin-aldosterone system (RAAS), including angiotensin converting enzyme inhibitors (ACEIs) and angiotensin receptor blockers (ARBs) are effective in protecting against radiation-induced injury in kidney, lung and brain [8-10].

Telmisartan is a highly selective AT1 receptor blocker, widely used in the treatment of hypertension [11]. Telmisartan has many advantages compared to other AT1-receptor blockers, including higher AT1 receptor affinity, longer duration of action and peroxisome proliferator-activated receptor (PPAR) activation, resulting in an effective anti-oxidant and anti-inflammation agent [12, 13]. In addition,

telmisartan chemically consists of benzimidazolic and benzoic groups providing unique scavenging properties for hydroxyl radicals [14]. Protective effects of telmisartan against various experimental models of tissue injuries have been reported in previous studies, indicating the efficacy of telmisartan for clinical conditions other than hypertension treatment. On the other hand, an ideal radioprotector should have an acceptable route of administration, preferably oral or intramuscular [15]. Compared with amifostine administered by intravenous injection, telmisartan can be orally administered. Telmisartan is also more available and cheaper than amifostine and has favorable safety profile and the longest half-life compared to amifostine or other ARB drugs [16, 17].

Recent study has also demonstrated that telmisartan provides the significant radioprotective effects in testis and reproductive tissues. To the best of our knowledge, the protective effect of telmisartan against radiation-induced injury in bone marrow has not been investigated so far. Hence, the present study was conducted to evaluate the radioprotective potential of telmisartan on bone marrow cellularity in a Balb/c mice model against sub-lethal X- irradiation.

Material and Methods

Animals

In this experimental study, adult male Balb/c mice (8–10 weeks old; weighting: 25–30 g) were purchased from the animal facility of Pharmaceutical Sciences Research Center, Tehran University of Medical Sciences. Mice were housed in good conditions at the university animal house and were fed with standard mouse pellet and tap water. All animals were kept under controlled laboratory condition of lighting (light: dark, 12:12 h) and temperature (22 ± 3 °C) with $50 \pm 10\%$ relative humidity. All animal-based protocols in this study were conducted in accordance with applied

research ethics national association guidelines for the welfare of experimental animals and approved by the Animal Ethics Committee of Tehran University of Medical Sciences (IR.TUMS.MEDICINE.REC.1398.575).

Study Design

A solution of telmisartan (Sigma–Aldrich Co., USA) in PBS (pH= 7.6) was freshly prepared and was daily administered by oral gavage in a constant volume to the mice. The animals were randomly divided into four groups as follow:

1) Control group: the mice were orally administered with phosphate buffered saline (PBS) and exposed to the sham-irradiation.

2) Telmisartan-treated group (TL group): the mice were orally administered with a solution of telmisartan in PBS (12 mg/kg b.wt.) and exposed to the sham- irradiation.

3) Irradiation-alone group (IR group): the mice were orally administered with PBS and exposed to 5 Gy X-radiation.

4) Telmisartan-treated group under irradiation (TL+IR group): the mice were orally administered with telmisartan (12 mg/kg b.wt.) and exposed to 5 Gy X-radiation.

All the mice were given gavage of the solutions for seven consecutive days, as described above. Five mice were placed in each group. On the seventh day, the mice were exposed to 5 Gy X-rays, 1 h after the last oral administration. Histopathological study was performed at days 3, 9, 15 and 30 after irradiation.

Irradiation

The mice were exposed to whole body irradiation (WBI) using a 6MV medical linear accelerator (Elekta, Compact). According to previous studies, the radiation dose of 5 Gy was selected to induce bone marrow injury in irradiated mice [18]. A single sub-lethal dose of 5 Gy was applied at a dose rate of 200 MU/min, through a field size of 40 cm × 40 cm, in an anterior-posterior direction at a depth of 2.0 cm. The source-to-skin distance was 100 cm. Figure 1 shows irradiation setup.

Histopathological Study

After treatment or radiation, the mice were deeply anesthetized intraperitoneally with a combination of ketamine (100 mg/kg) and xylazine (10 mg/kg), respectively, which was in accordance with recent American Veterinary Medical Association (AVMA) guidelines that injection of 100 μ L of a solution of ketamine: xylazine (10 mg:1 mg) in mice resulted in death within 3 to 5 s after completion of the injection. Therefore, animals had no nervous reflex, and this process eliminated the pain and distress at death [19, 20]. Right femurs were then surgically removed from anesthetized mice at days 3, 9, 15 and 30 after irradiation, fixed in the 10% neutral buffered formalin (NBF, pH= 7.26) for 48 h, processed and embedded in paraffin [21-24]. Then 5 μ m thick sections were prepared and stained with haematoxylin and eosin (H&E) using standard procedure. The histological slides were evalu-

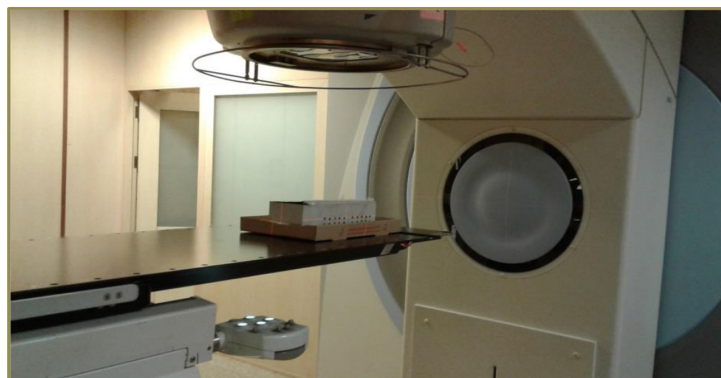

Figure 1: Irradiation setup using Elekta linear accelerator.

ated by the independent reviewer, using light microscopy (Olympus BX51; Olympus, Tokyo, Japan). For the counting of different cell types in bone marrow, three high-power fields (3HPF, $\times 800$) were randomly selected and the final measurements were collected by the average of the data achieved from these three fields. Histological parameters, polymorphonuclear /mononuclear cells and megakaryocytes were analyzed and recorded.

Statistical Analysis

All the results were expressed as mean \pm standard deviation (SD). Statistical analysis was performed using one-way analysis of variance (ANOVA) followed by Tukey's post hoc test for comparison between multiple groups (IBM SPSS Statistics Package for Windows, Version 23.0). A value of $P < 0.05$ was considered to be statistically significant.

Results

Micrographs of the bone marrow in control, IR, TL and TL+IR groups are seen in Figure 2. In addition, the histomorphometric analysis of harvested tissues of the bone marrow was

also listed in Table 1. Treatment with 12 mg/kg of telmisartan alone (TL group) did not show any decrease in bone marrow cellularity compared to the control group on the 3rd, 9th, 15th and 30th days ($p > 0.05$). The results confirmed the non-toxicity nature of telmisartan at the applied dosage. There was a significant reduction in the number of polymorphonuclear cells, mononuclear cells and megakaryocytes in IR group compared to the control group on the 3rd day ($p < 0.05$). Treatment with telmisartan before irradiation partially preserved bone marrow cellularity compared to the irradiated group at 3rd day, but the difference between the two groups was not statistically significant. By 9 days after irradiation, the number of polymorphonuclear cells, mononuclear cells and megakaryocytes had a decrease in both IR and TL+IR groups. In addition to the marked hypocellularity, cytolysis and adipose tissue replacement were observed, which were indicative of severe radiation-induced depletion of bone marrow. However, an increase in total cellularity of bone marrow was still significantly detectable in TL+IR group ($p < 0.05$). Although some relative recovery was observed

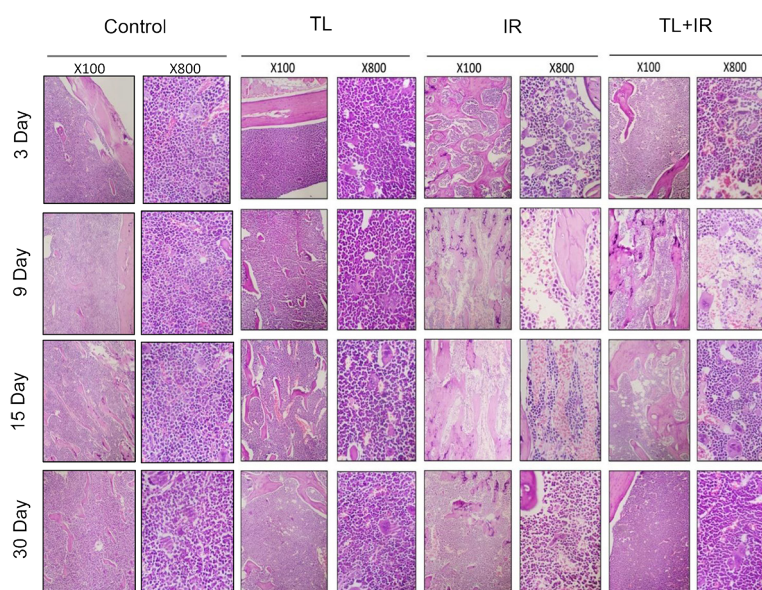


Figure 2: Photomicrographs of histologic sections of the femoral bone marrow in different experimental groups on 3rd, 9th, 15th, and 30th days; Control; TL: telmisartan (12 mg/kg body weight); IR: 5 Gy irradiation; TL+IR: telmisartan (12 mg/kg body weight)+5 Gy irradiation; H&E stain.

Table 1: The number of polymorphonuclear/mononuclear cells and megakaryocytes in bone marrow sections of different experimental groups (Mean±SD).

Factor	Control	TL	*IR	TL+IR
Polymorphonuclear cells	55.6±3.7 (3)	54±4 (3)	47±4 (3)	51.3±1.5 (3)
	54.5±2.5 (9)	53.3±3.5 (9)	19.6±2.5 (9)	#24.6±2.5 (9)
	55.8±3 (15)	54±2.5 (15)	22±3 (15)	#48±3 (15)
	56.5±2.2 (30)	56±2.6 (30)	43±4.5 (30)	#53.6±1.5 (30)
Mononuclear cells	44.3±2 (3)	43.6±3 (3)	36±3.5 (3)	37±2 (3)
	46.3±1.5 (9)	45.5±2.5 (9)	14.3±2.5 (9)	#18.6±2.5 (9)
	47±2.2 (15)	47.3±2.5 (15)	16.3±1.5 (15)	#25.4±2 (15)
	45.5±2.5 (30)	46.6±4.1 (30)	34±4 (30)	#45±3.5 (30)
Megakaryocytes	7.7±1 (3)	7±1.2 (3)	6.6±0.7 (3)	7.3±1.5 (3)
	7.2±1.2 (9)	7.5±1.5 (9)	0.3±0.1 (9)	#2.3±0.5 (9)
	7.5±1 (15)	7.3±1.1 (15)	1.6±0.3 (15)	#5±1 (15)
	7±1.5 (30)	7±1 (30)	3.3±0.5 (30)	#6.8±1.5 (30)

*p < 0.05 compared to the control and #p < 0.05 compared to IR group (5 Gy) for similar time points; TL: telmisartan (12 mg/kg body weight); IR: 5 Gy irradiation; TL+IR: telmisartan (12 mg/kg body weight) + 5 Gy irradiation. The numbers in parentheses represent the time points (day) of the histopathology analysis.

in IR group on the 15th and 30th days, there was still a statistically significant decrease in the number of polymorphonuclear cells, mononuclear cells and megakaryocytes compared to the control group (p < 0.05). Moreover, the number of cellularity in bone marrow sections, including polymorphonuclear cells, mononuclear cells and megakaryocytes was significantly higher in TL+IR group than IR group on 15th and 30th days (p < 0.05). By the 30th day, the total cellularity in the TL+IR group returned to the normal level.

Discussion

Ionizing radiation exposure often has fatal effects on the hematopoietic system, leading to serious concerns about human health and limiting the use of radiation therapy in cancer patients [25]. Bone marrow, as the most important hematopoietic organ, is highly radiosensitive. It maintains a high rate of cell proliferation and forms the various stages of hematopoietic cell growth. Bone marrow damage can suppress hematopoiesis, resulting in low counts of circulating blood cells and adverse side effects such as bleeding, anemia

and immune impairment [26]. Therefore, it is important to develop safe and effective radioprotectors to modify the natural response of hematopoietic system to radiation-induced toxicity or fatality. In this regard, histological analysis of bone marrow has demonstrated that pre-treatment with radioprotective agents such as roxadustat, dammarane sapogenins, CpG-oligodeoxy nucleotides (ODN), homogeneous polysaccharides (APS-1a and APS-3a), chlorobenzylsulfone derivative (ON 01210.Na), 17-dimethylaminoethylamino-17-demethoxygeldanamycin, ascorbic acid, δ -tocotrienol (DT3) and genistein improves the cellularity in bone marrow and ameliorates hematopoietic toxicity in mice [18, 21-24, 27-30]. Recently, it was reported that telmisartan protected testis and reproduction organs against radiation-induced toxicity in animal models. The radioprotection activity of telmisartan has been attributed to its radical scavenging and anti-inflammatory effects resulting in the regeneration of radiation-induced damage [31-33]. In the present study, orally administered telmisartan, an ARB drug, was tested for the bone marrow radioprotection in the Balb/c

mice.

In accordance with other studies, bone marrow histopathological examination was used as an indicator of radiation-induced myelosuppression and the presence of polymorphonuclear /mononuclear cells and megakaryocytes was studied. Bone marrow sections from the control and TL groups showed a normal number of cellularity at all-time points. They contained the clusters of polymorphonuclear /mononuclear cells and megakaryocytes mixed with adipocytes in normal proportions. Our results showed that both TL+IR and IR groups had almost similar number of bone marrow cells at 3 days after irradiation, but the early onset of marrow destruction was also observed. There were marked hypocellularity, cytolysis, vacuolization and adipose replacement in both IR and TL+IR groups, indicating that radiation induced severe marrow depletion on 9 days after irradiation. But, on days 15th and 30th, the number of bone marrow cells, including polymorphonuclear cells, mononuclear cells and megakaryocytes in the TL+IR group was significantly higher than the IR group. The time course study ranging from 3 to 30 days indicated faster recovery of radiation-induced bone marrow cell loss in the TL+IR group than IR group. By the day 30th, a significant recovery in bone marrow cellularity, near to normal level, was observed in mice treated with telmisartan, indicating that telmisartan minimized radiation-induced myelosuppression.

Previous studies have shown that treatment with renin angiotensin aldosterone system (RAAS) modulators restored bone marrow cellularity and the number of hematopoietic progenitor cells after radiation exposure [34]. It was considered that possible mechanisms of telmisartan may be involved into the following aspects. Firstly, administration of telmisartan, as a RAAS modulator, markedly increases tetrapeptide AcSDKP (Acetyl-N-Ser-Asp-Lys-Pro) plasma concentration, showing a direct myeloprotective effect. The AcSDKP is

a hematopoiesis regulator and also acts as a potent myeloprotector. It was reported that AcSDKP mediates G0/G1arrest and prevents subsequent DNA breakage and apoptosis during S phase of the cell cycle [35]. The second mechanism is probably related to the role of RAAS modulators in hematopoiesis, either by acting directly on hematopoietic stem cells through promoting entry into the cell-cycle, or indirectly by stimulating the secretion of the cytokines and growth factors from stromal cells [36]. Finally, it is thought that telmisartan enhances marrow repopulation capacity and hematopoietic function through activating the internal antioxidant defense system in irradiated mice, because reactive oxygen species are involved in many ionizing radiation toxicities [13, 37, 38]. However, the mechanisms related to the radioprotective effects of telmisartan on hematopoiesis and bone marrow need further explorations. In the future, we will focus on a more detailed mechanistic study of the factors, affecting the results of telmisartan treatment against radiation induced myelo/hematopoietic toxicity.

Conclusion

In conclusion, this study is the first report demonstrating that administration of telmisartan before irradiation effectively protects bone marrow tissue against radiation-induced injuries and this effect is associated with the recovery of its structure and function. Telmisartan is a well-tolerated, easily available and cost-effective FDA-approved drug with no toxicity and can be orally administrated. These features make telmisartan as an excellent radioprotector for conditions, in which there is always a risk of damage to the hematopoietic system during irradiation. It would be considered for further clinical study in future.

Acknowledgment

The authors thank Anita Ebrahimpour and Nasrin Seyedpour for their help in taking care and preparing animals for histological analy-

sis. This study was supported financially by a grant from Tehran University of Medical Sciences (grant number: 42235-30-02-98).

Authors' Contribution

M. Fooladi, M. Khoobi, M. Cheki, A. Shirazi and P. Sheikhzadeh conceived the idea. Introduction of the paper was written by M. Fooladi with consultant of M. Khoobi and M. Cheki. M. Fooladi gathered the images and the related literature and also performed related animal works. The method implementation was carried out by M. Fooladi, P. Sheikhzadeh, M. Amirrashedi and F. Ghahramani. Results and Analysis was carried out by M. Fooladi and M. Amirrashedi. The research work was proofread and supervised by M. Khoobi and M. Cheki. All the authors read, modified, and approved the final version of the manuscript.

Ethical Approval

The Ethics Committee of Tehran University of Medical Sciences approved the protocol of the study (IR.TUMS.MEDICINE.REC.1398.575).

Informed consent

Only experimental animals were used in this study and there were no experiments or processes on humans.

Funding

This study was supported financially by a grant from Tehran University of Medical Sciences (grant number: 42235-30-02-98).

Conflict of Interest

None

References

- Xiao M, Whitnall MH. Pharmacological countermeasures for the acute radiation syndrome. *Curr Mol Pharmacol*. 2009;**2**(1):122-33. doi: 10.2174/1874467210902010122. PubMed PMID: 20021452.
- Ko S, Chung HH, Cho SB, Jin YW, et al. Occupational radiation exposure and its health effects on interventional medical workers: study protocol for a prospective cohort study. *BMJ Open*. 2017;**7**(12):e018333. doi: 10.1136/bmjopen-2017-018333. PubMed PMID: 29248885. PubMed PMCID: PMC5778344.
- Calvi LM, Frisch BJ, Kingsley PD, et al. Acute and late effects of combined internal and external radiation exposures on the hematopoietic system. *Int J Radiat Biol*. 2019;**95**(11):1447-61. doi: 10.1080/09553002.2019.1644932. PubMed PMID: 31329495.
- López M, Martín M. Medical management of the acute radiation syndrome. *Reports Pract Oncol Radiother*. 2011;**16**(4):138-46. doi: 10.1016/j.rpor.2011.05.001. PubMed PMID: 24376971. PubMed PMCID: PMC3863169.
- Zhang X, Xing X, Liu H, Feng J, et al. Ionizing radiation induces ferroptosis in granulocyte-macrophage hematopoietic progenitor cells of murine bone marrow. *Int J Radiat Biol*. 2020;**96**(5):584-95. doi: 10.1080/09553002.2020.1708993. PubMed PMID: 31906761.
- Kamran MZ, Ranjan A, Kaur N, Sur S, Tandon V. Radioprotective agents: strategies and translational advances. *Med Res Rev*. 2016;**36**(3):461-93. doi: 10.1002/med.21386. PubMed PMID: 26807693.
- Mun G-I, Kim S, Choi E, Kim CS, Lee Y-S. Pharmacology of natural radioprotectors. *Arch Pharm Res*. 2018;**41**(11):1033-50. doi: 10.1007/s12272-018-1083-6. PubMed PMID: 30361949. PubMed PMCID: PMC6224001.
- Davis TA, Landauer MR, Mog SR, et al. Timing of captopril administration determines radiation protection or radiation sensitization in a murine model of total body irradiation. *Exp Hematol*. 2010;**38**(4):270-81. doi: 10.1016/j.exphem.2010.01.004. PubMed PMID: 20116413. PubMed PMCID: PMC2843794.
- Moulder J, Fish B, Cohen E. Treatment of radiation nephropathy with ACE inhibitors and All type-1 and type-2 receptor antagonists. *Curr Pharm Des*. 2007;**13**(13):1317-25. doi: 10.2174/138161207780618821. PubMed PMID: 17506717.
- Medhora M, Gao F, Jacobs ER, Moulder JE. Radiation damage to the lung: Mitigation by angiotensin-converting enzyme (ACE) inhibitors. *Respirology*. 2012;**17**(1):66-71. doi: 10.1111/j.1440-1843.2011.02092.x. PubMed PMID: 22023053. PubMed PMCID: PMC3245332.
- Yusuf S, Diener H-C, Sacco RL, et al. Telmisartan to prevent recurrent stroke and cardiovascular events. *N Engl J Med*. 2008;**359**(12):1225-37. doi: 10.1056/NEJMoa0804593. PubMed PMID: 18753639. PubMed PMCID: PMC2714258.
- Al-Hejjaj WK, Numan IT, Al-Sa'ad RZ, Hussain SA. Anti-inflammatory activity of telmisartan in rat models of experimentally-induced chronic inflammation: Comparative study with dexamethasone. *Saudi Pharm J*. 2011;**19**(1):29-34. doi: 10.1016/j.jsps.2010.10.004. PubMed PMID: 23960739. PubMed PMCID: PMC3745173.
- Goyal S, Bharti S, Bhatia J, et al. Telmisartan, a dual ARB/partial PPAR- γ agonist, protects myocardium from ischaemic reperfusion injury in experimental diabetes. *Diabetes, Obes Metab*. 2011;**13**(6):533-41. doi: 10.1111/j.1463-1326.2011.01377.x. PubMed PMID: 21320264.
- Eslami H, Sharifi AM, Rahimi H, Rahati M. Protective effect of telmisartan against oxidative damage induced by high glucose in neuronal PC12 cell. *Neurosci Lett*. 2014;**558**:31-6. doi: 10.1016/j.neulet.2013.10.057. PubMed PMID: 24211690.

15. Hosseinimehr SJ. Trends in the development of radio-protective agents. *Drug Discov Today*. 2007;**12**(19-20):794-805. doi: 10.1016/j.drudis.2007.07.017. PubMed PMID: 17933679.
16. Remuzzi A, Remuzzi G. Potential protective effects of telmisartan on renal function deterioration. *J Renin-Angiotensin-Aldosterone Syst*. 2006;**7**(4):185-91. doi: 10.3317/jraas.2006.036. PubMed PMID: 17318786.
17. Abraham HMA, White CM, White WB. The comparative efficacy and safety of the angiotensin receptor blockers in the management of hypertension and other cardiovascular diseases. *Drug Saf*. 2015;**38**(1):33-54. doi: 10.1007/s40264-014-0239-7. PubMed PMID: 25416320. PubMed PMCID: PMC4303500.
18. Suman S, Maniar M, Fornace AJ, Datta K. Administration of ON 01210. Na after exposure to ionizing radiation protects bone marrow cells by attenuating DNA damage response. *Radiat Oncol*. 2012;**7**(1):1-9. doi: 10.1186/1748-717X-7-6. PubMed PMID: 22264334. PubMed PMCID: PMC3275448.
19. Vaupel D, McCoun D, Cone EJ. Phencyclidine analogs and precursors: rotarod and lethal dose studies in the mouse. *J Pharmacol Exp Ther*. 1984;**230**(1):20-7. PubMed PMID: 6747825.
20. Underwood W, Anthony R. AVMA Guidelines for the Euthanasia of Animals: 2020 Edition. The American Veterinary Medical Association (AVMA); 2020.
21. Zhang C, Lin J, Cui J, Li B, et al. Radioprotection of bone marrow hematopoiesis by CpG-oligodeoxynucleotides administered to mice after total-body irradiation. *J Radiat Res*. 2011;**52**(6):828-33. doi: 10.1269/jrr.10098. PubMed PMID: 22104272.
22. Lu X, Nurmehmet D, Bolduc DL, et al. Radioprotective effects of oral 17-dimethylaminoethylamino-17-demethoxygeldanamycin in mice: bone marrow and small intestine. *Cell Biosci*. 2013;**3**(1):1-16. doi: 10.1186/2045-3701-3-36. PubMed PMID: 24499553. PubMed PMCID: PMC3852109.
23. Zhang P, Du J, Zhao H, Cheng Y, et al. Radioprotective effects of roxadustat (FG-4592) in haematopoietic system. *J Cell Mol Med*. 2019;**23**(1):349-56. doi: 10.1111/jcmm.13937.
24. Sato T, Kinoshita M, Yamamoto T, Ito M, et al. Treatment of irradiated mice with high-dose ascorbic acid reduced lethality. *PLoS One*. 2015;**10**(2):e0117020. doi: 10.1371/journal.pone.0117020. PubMed PMID: 25651298. PubMed PMCID: PMC4317183.
25. Li D, Tian Z, Tang W, Zhang J, Lu L, Sun Z, et al. The protective effects of 5-methoxytryptamine- α -lipoic acid on ionizing radiation-induced hematopoietic injury. *Int J Mol Sci*. 2016;**17**(6):935. doi: 10.3390/ijms17060935. PubMed PMID: 27314327. PubMed PMCID: PMC4926468.
26. Simonnet AJ, Nehmé J, Vaigot P, Barroca V, et al. Phenotypic and functional changes induced in hematopoietic stem/progenitor cells after gamma-ray radiation exposure. *Stem Cells*. 2009;**27**(6):1400-9. doi: 10.1002/stem.66. PubMed PMID: 19489102.
27. Dong L, Yang Y, Lu Y, Lu C, Lv J, Jiang N, et al. Radioprotective effects of dammarane sapogenins against 60Co-induced myelosuppression in mice. *Phyther Res*. 2018;**32**(4):741-9. doi: 10.1002/ptr.6027. PubMed PMID: 29356175.
28. Zhao L, Wang Y, Shen H-l, Shen X-d, et al. Structural characterization and radioprotection of bone marrow hematopoiesis of two novel polysaccharides from the root of *Angelica sinensis* (Oliv.) Diels. *Fitoterapia*. 2012;**83**(8):1712-20. doi: 10.1016/j.fitote.2012.09.029. PubMed PMID: 23063893.
29. Li XH, Fu D, Latif NH, Mullaney CP, Ney PH, Mog SR, et al. δ -tocotrienol protects mouse and human hematopoietic progenitors from γ -irradiation through extracellular signal-regulated kinase/mammalian target of rapamycin signaling. *Haematologica*. 2010;**95**(12):1996-2004. doi: 10.3324/haematol.2010.026492. PubMed PMID: 20823133. PubMed PMCID: PMC2995556.
30. Davis TA, Clarke TK, Mog SR, Landauer MR. Subcutaneous administration of genistein prior to lethal irradiation supports multilineage, hematopoietic progenitor cell recovery and survival. *Int J Radiat Biol*. 2007;**83**(3):141-51. doi: 10.1080/09553000601132642. PubMed PMID: 17378522.
31. Cristina Schwarz F, Da Silva Mansano N, Bruno Chies A, et al. Potential Radioprotective Effect of AT 1 Receptor Antagonists Against Morphological and Ultrastructural Changes in the Testes Induced by Ionizing Radiation. *Int J Morphol*. 2017;**35**(3):820-30. doi: 10.4067/S0717-95022017000300005.
32. Da Silva Mansano N, Jorge IF, Chies AB, et al. Effects of telmisartan and losartan on irradiated testes. *Life Sci*. 2018;**194**:157-67. doi: 10.1016/j.lfs.2017.12.031. PubMed PMID: 29287783.
33. Cavalim Vale AP, Dos Santos G, Da Silva, et al. Influence of the AT1 Receptor Antagonists Telmisartan and Losartan on Reproduction and Offspring After Paternal Exposure to Ionizing Radiation. *Reprod Sci*. 2019;**26**(5):639-48. doi: 10.1177/1933719118783251. PubMed PMID: 29938606.
34. Charrier S, Michaud A, Badaoui S, et al. Inhibition of angiotensin I-converting enzyme induces radioprotection by preserving murine hematopoietic short-term reconstituting cells. *Blood*. 2004;**104**(4):978-85. doi: 10.1182/blood-2003-11-3828. PubMed PMID: 15105290.
35. Liu J-M, Lawrence F, Kovacevic M, Bignon J, et al. The tetrapeptide AcSDKP, an inhibitor of primitive hematopoietic cell proliferation, induces angiogenesis in vitro and in vivo. *Blood, J Am Soc Hematol*. 2003;**101**(8):3014-20. doi: 10.1182/blood-2002-07-2315. PubMed PMID: 12480715.
36. Haznedaroglu IC, Öztürk MA. Towards the understanding of the local hematopoietic bone marrow renin-angiotensin system. *Int J Biochem Cell Biol*. 2003;**35**(6):867-80. doi: 10.1016/S1357-2725(02)00278-9. PubMed PMID: 12676173.
37. Hubert C, Savary K, Gasc J-M, Corvol P. The hematopoietic system: a new niche for the renin-angiotensin system. *Nat Clin Pract Cardiovasc Med*. 2006;**3**(2):80-5. doi: 10.1038/ncpcardio0449. PubMed PMID: 16446776.
38. Arab HH, Al-Shorbagy MY, Abdallah DM, Nassar NN. Telmisartan attenuates colon inflammation, oxidative perturbations and apoptosis in a rat model of experimental inflammatory bowel disease. *PLoS One*. 2014;**9**(5):e97193. doi: 10.1371/journal.pone.0097193. PubMed PMID: 24831514. PubMed PMCID: PMC4022743.