



Research paper

Intraoperative monitoring of corticospinal tracts in anterior cervical decompression and fusion surgery: Excitability differentials of lower extremity muscles



Avner Michaeli ^{a,*}, Shmuel Appel ^{a,b}, Akiva Korn ^{a,c}, Joseph Danto ^a, Ely Ashkenazi ^d

^a Surgical Monitoring Services LTD, Beit Shemesh, Israel

^b Department of Neurology, Barzilai Medical Center, Ashkelon, Israel, Affiliated with the Joyce & Irving Goldman School of Medicine, Ben Gurion University of the Negev, Israel

^c Department of Pediatric Neurosurgery, Tel Aviv Sourasky Medical Center, Tel Aviv, Israel, Affiliated with the Sackler School of Medicine of Tel Aviv University, Israel

^d Israel Spine Center, Assuta Medical Center, Tel Aviv, Israel

ARTICLE INFO

Article history:

Received 30 December 2019

Received in revised form 28 January 2020

Accepted 13 February 2020

Available online 10 March 2020

Keywords:

Anterior cervical decompression and fusion

Intraoperative neuromonitoring

Transcranial motor evoked potential

Tibialis anterior

Abductor hallucis

ABSTRACT

Objective: This study examines and compares excitability characteristics of tibialis anterior (TA) and abductor hallucis (AH) transcranial motor evoked potentials (tcMEP) during anterior cervical decompression and fusion (ACDF) surgery.

Methods: Electrophysiological and clinical data of 89 patients who underwent ACDF procedure were retrospectively reviewed. TcMEP data of TA and AH muscles from 178 limbs were analyzed for availability, robustness and stability during the procedure.

Results: TA tcMEP was available at 83% whereas AH tcMEP was available at 99% of the monitored lower limbs at preposition baseline. Availability of both TA and AH tcMEP was demonstrated in 147/178 limbs. The baseline amplitude of AH tcMEP was significantly greater than that of TA tcMEP recorded from the same limb (744.6 ± 54.0 and 326.9 ± 33.3 μ V, respectively). Simultaneous deterioration of TA and AH tcMEP data was demonstrated in 10/147 limbs. Deterioration of either TA or AH tcMEP data accompanied by unchanged tcMEP data from the other lower limb muscle was noted in 32/147 compared to 1/147 limbs, respectively. The deteriorated TA and AH tcMEP data returned to baseline before closing at incidence of 17% compared to 46%, respectively. No new lower extremity (LE) neurological deficit was presented postoperatively in any patient.

Conclusions: AH tcMEP is a more reliable candidate than TA tcMEP for intraoperative LE monitoring in ACDF procedure.

Significance: The excitability differentials in LE tcMEP in ACDF is a variable that need to be considered while interpreting intraoperative neurophysiological data.

© 2020 International Federation of Clinical Neurophysiology. Published by Elsevier B.V. This is an open access article under the CC BY-NC-ND license (<http://creativecommons.org/licenses/by-nc-nd/4.0/>).

1. Introduction

Spinal cord and nerve root injuries are potential risks associated with cervical decompression surgery (Yonenobu et al., 1991; Sakaura et al., 2003; Nanda et al., 2014). Intraoperative neurophysiological monitoring (IONM) is designed and intended to detect impending neural damage, associated with presurgical and surgical maneuvers such as neck positioning, spinal cord and nerve root

decompression and vertebral column fixation. The physiological integrity of the cervical ventral nerve roots is monitored by recording transcranial motor evoked potentials (tcMEP) from muscles innervated by the nerve roots involved in the surgical procedure. The physiological continuity of the corticospinal tracts is assessed intraoperatively by monitoring tcMEP from upper and lower extremity (LE) muscles (Gonzalez et al., 2009; Epstein, 2013). Essentially, the monitored potentials are anticipated to present high signal-to-noise ratio, maximal sensitivity to surgery-related impending neural damage and minimal sensitivity to physiological systemic factors not associated with postoperative neurological deficit. Choosing a reliable monitorable motor evoked potential is a key factor for effective intraoperative neuromonitoring, which will maximize the benefit of the surgical procedure and reduce

Abbreviations: ACDF, anterior cervical decompression and fusion; AH, abductor hallucis; EMG, electromyography; IONM, intraoperative neurophysiological monitoring; LE, lower extremity; SSEP, somatosensory evoked potential; TA, tibialis anterior; TcMEP, transcranial motor evoked potential.

* Corresponding author.

E-mail address: avnerm@surgicalphysiology.com (A. Michaeli).

<https://doi.org/10.1016/j.cnp.2020.02.002>

2467-981X/© 2020 International Federation of Clinical Neurophysiology. Published by Elsevier B.V.

This is an open access article under the CC BY-NC-ND license (<http://creativecommons.org/licenses/by-nc-nd/4.0/>).

the rate of false alarm neurophysiological alerts. The tibialis anterior (TA) and abductor hallucis (AH) muscles are traditional candidates for monitoring tcMEP from the lower limb in cervical decompression surgeries (Bose et al., 2004; Legatt et al., 2016; Simon, 2018). To our knowledge the compatibility of these muscles for LE tcMEP intraoperative monitoring has not been studied. In this retrospective study, the robustness and stability of tcMEP data from TA and AH muscles were assessed in anterior cervical decompression and fusion (ACDF) procedures.

2. Methods

2.1. Subjects

This study was approved by Assuta institutional research board. IONM data and clinical records of patients who underwent ACDF surgery in Assuta Medical Center during the years 2016–2018 were retrospectively reviewed. The study cohort included 60 males and 29 females at ages 18–85 (mean 52) years old. The surgical procedures included 49 discectomies, 32 corpectomies and 8 cases of both, discectomy and corpectomy, at one, two or three levels. No new LE neurological deficit was presented in any patient postoperatively.

2.2. Surgical procedure

The surgeries were performed by members of Israel Spine Center, Assuta Medical Center, Israel. All surgeries involved the cervical spine (C3–T1), and access was achieved via an anterior approach. Surgeries were conducted under total intravenous anesthesia (Tamkus et al., 2014), and short-acting muscle relaxant was used at induction only if needed, with no further paralytic agent administered following intubation. Neurophysiologists were all members of one neuromonitoring team and adhered to a consistent set of monitoring guidelines and protocols.

2.3. IONM setup

The monitoring protocol included: somatosensory evoked potentials (SSEP), tcMEP and free-running electromyography (EMG). For SSEP, surface or needle electrodes were placed along the lateral aspect of each wrist for bipolar stimulation of the ulnar nerves, and along the medial aspect of each ankle at the malleoli level for bipolar stimulation of the posterior tibial nerves. Cortical SSEP were recorded over the cerebral cortex using subdermal electrodes placed approximately 1–2 cm posterior to the Cz, C3 and C4 landmarks. Subcortical SSEP were recorded using a subdermal electrode placed at the left or right mastoid process. Recording electrodes were referenced to a subdermal electrode at the FPz landmark, or to each other. For tcMEP, subdermal electrodes were placed approximately 1–2 cm anterior and medial to C3 and C4 scalp positions for transcranial stimulation. Stimulus parameters included: 5–7 pulses, pulse duration 500 μ s and 50–600 V or 5–9 pulses, pulse duration 75 μ s and 100–1000 V; interstimulus interval 2–4 ms. TcMEP were recorded at the bilateral thenar, abductor hallucis, tibialis anterior, deltoid, biceps and occasionally triceps muscles using subdermal paired needle electrodes. In establishing reliable baseline tcMEP data, technical and pharmacological effects were ruled out by careful inspection of electrode placement and impedances, optimizing stimulus parameters and occasionally pausing the procedure until induction effects were minimized. Free-running EMG activity was monitored from the myotomes of the involved nerve roots spanning the surgical spinal levels, including the deltoid, biceps and occasionally triceps and thenar muscles using subdermal needle electrodes. EMG activity was displayed on

video and audio monitors for visual and auditory recognition. Stimulations and recordings were performed using NIM-ECLIPSE (Axon) system.

2.4. Analysis

IONM data were reviewed and analyzed by an experienced neurophysiologist (AM). The documented preoperative and postoperative clinical data were reviewed by a senior neurologist (SA). TcMEP amplitude at baseline was measured peak-to-peak from a representative potential recorded after intubation and before any manipulation including neck positioning. Effort was made to take into consideration only data which were recorded under stable physiological parameters, according to anesthesiology and neurophysiology teams. The decrease of tcMEP amplitude was measured from a representative deteriorated potential. For analysis purposes, only attenuation of more than 50% compared with baseline amplitude, which persisted for more than 4 consecutive trials during a time period of more than 5 min, was categorized as significant change in tcMEP data. All percentages were rounded off to the nearest whole number. Data sets were compared using *t* test at a significance level of 0.05. All relevant values are presented as average \pm SEM.

3. Results

3.1. Preoperative availability of LE tcMEP data

Following intubation on the operating table and before placing the patient in final position, baseline neurophysiological data were recorded. For preoperative assessment of the physiological integrity of the motor tracts, tcMEP data from bilateral TA and AH muscles were collected, alongside upper extremity tcMEP data. As candidates for cervical decompression surgery experience varying degrees of myelopathy and clinical neurological deficits, the recorded baseline tcMEP data under general anesthesia are occasionally not available at all monitored muscles, even after fully exploiting the available parameters for transcranial stimulation (intensity, pulses per train, double train, polarity). Yet, obtaining baseline LE tcMEP data is crucial for conducting reliable and effective intraoperative monitoring, and an absence of baseline physiological information compromises procedure monitoring. Preoperative monitorable tcMEP data from the TA muscle was available in 148/178 (83%) of the monitored lower limbs (Fig. 1a), whereas preoperative monitorable tcMEP data from the AH muscle was available in 177/178 (99%) limbs (Fig. 1b). The preoperative availability of LE tcMEP data from either TA or AH or both muscles was demonstrated in 178/178 (100%) limbs. Preoperative LE tcMEP data from both TA and AH muscles was available at 147/178 (83%) limbs. The average amplitudes of baseline-available TA and AH tcMEP, calculated only from limbs where data were available at both muscles, were 326.9 ± 33.3 and 744.6 ± 54.0 μ V, respectively ($n = 147$; $p < 0.001$) (Fig. 1c).

3.2. Intraoperative stability of LE tcMEP data

Recording stable reproducible tcMEP data from a LE muscle throughout a cervical decompression procedure, has been shown to correlate with preservation of the physiological continuity of the corticospinal tracts (Hilibrand et al., 2004; Kim et al., 2007). On the other hand, deterioration of LE tcMEP data during the procedure may result from causes other than neural damage (e.g. changes in blood pressure, anesthesia level and body temperature) (Bose et al., 2004; Wang et al., 2009; Li et al., 2012; Traynelis et al., 2012; Ushirozako et al., 2019), which can lead to false positive

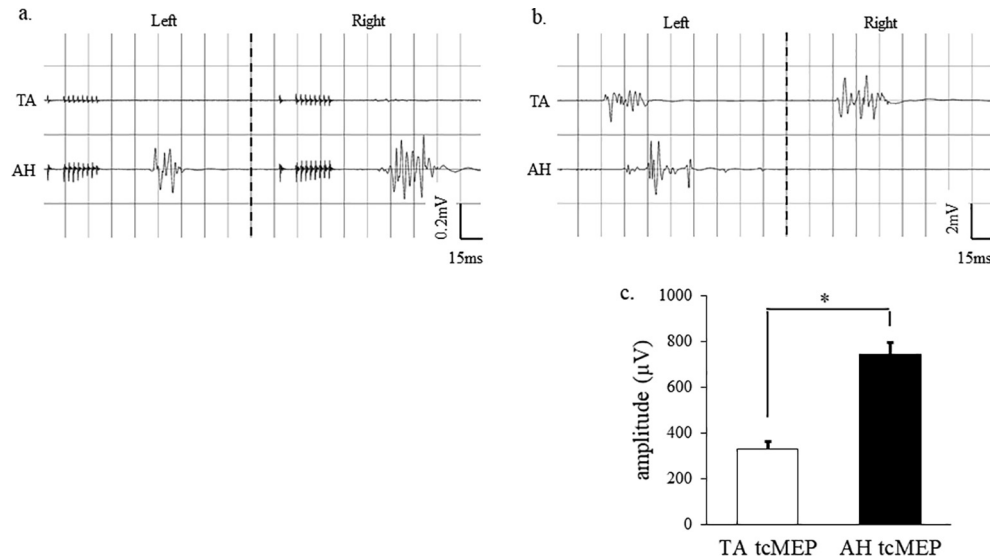


Fig. 1. Preoperative availability and amplitude of TA and AH tcMEP data. (a, b), Examples of preoperative absence of bilateral TA tcMEP (a) and unilateral AH tcMEP (b). (c), Bar graphs presenting the average baseline amplitudes of TA and AH tcMEP ($*p < 0.001$; t -test). Error bars represent SEM.

neuromonitoring alerts. Deterioration of TA tcMEP data was noted in 42/148 (28%) and deterioration of AH tcMEP data in 13/177 (7%) of the monitored lower limbs. Simultaneous deterioration of tcMEP data from both TA and AH muscles at the same surgical stage was demonstrated in 10/147 (7%) limbs. Of the 42 limbs with TA tcMEP changes, 32 (76%) demonstrated unchanged AH tcMEP data (Fig. 2). Of the 13 limbs with AH tcMEP changes, in one limb TA tcMEP was not available at baseline and in another one TA tcMEP attenuated during an earlier stage. Thus, of the remaining 11 limbs with AH tcMEP changes, only one (9%) limb demonstrated unchanged TA tcMEP data. Deterioration of either TA or AH tcMEP data or both was noted in 44/178 (25%) of the monitored lower limbs.

3.3. Characteristics of the LE tcMEP instability

An intraoperative neuromonitoring alert reflects the possibility of compromised integrity of the respective neural pathway associated with the observed change. Interpretation of intraoperative deterioration of tcMEP data is derived from multiple parameters. One parameter is substantial loss of amplitude of the recorded potential. The more significant amplitude loss is assumed to be more highly correlated with neural compromise and postoperative neurological deficit. The average amplitude loss of the deteriorated TA tcMEP was $88.3 \pm 2.4\%$, and the average amplitude loss of the

deteriorated AH tcMEP was $89.5 \pm 4.0\%$ ($p > 0.05$). In cases where changes in the amplitude of both TA and AH tcMEP were demonstrated simultaneously, the average attenuation of TA tcMEP was $92.1 \pm 5.1\%$, while the attenuation of AH tcMEP was $88.1 \pm 4.5\%$ ($p > 0.05$). A second parameter which affects the interpretation of intraoperative deterioration of a monitored potential is its recovery pattern. An absence of recovery of an intraoperatively deteriorated potential during the procedure is associated with higher probability of postoperative neural deficit (Holdefer et al., 2015; Appel et al., 2019). Remarkably, 7/42 (17%) of the deteriorated TA tcMEP data and 6/13 (46%) of the deteriorated AH tcMEP data recovered to baseline magnitude before final closure of the surgical wound (Fig. 3).

4. Discussion and conclusions

Monitoring tcMEP from upper and LE muscles in cervical decompression procedures seeks to detect impending neural damage to the corticospinal tracts, or other corticospinal tracts-supporting conductive fibers, during the different stages of the procedure. As candidates for cervical decompression surgery frequently experience severe cervical myelopathy accompanied by weakness of distal muscles, reliable physiological potentials need

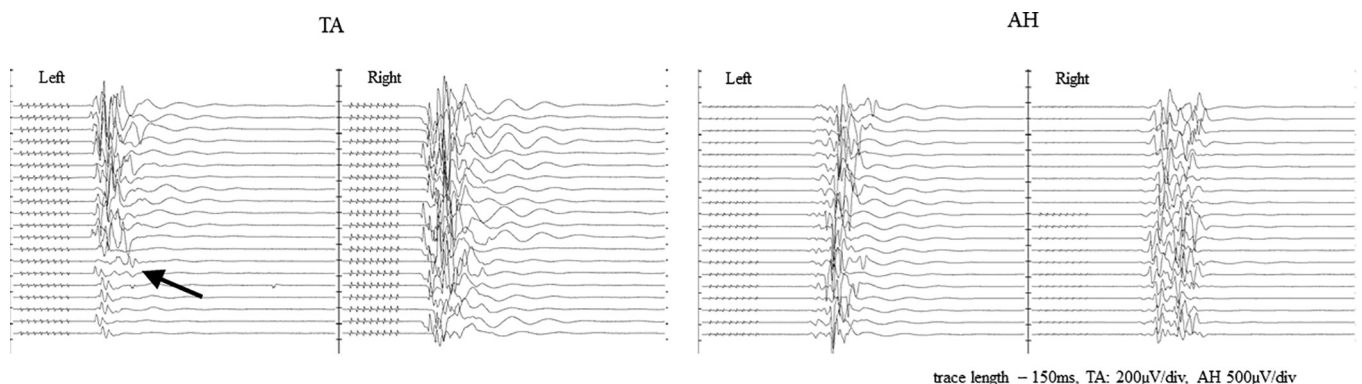


Fig. 2. Intraoperative isolated deterioration of TA tcMAP data. Full-length stack data showing deterioration of unilateral TA tcMEP accompanied by an unchanged AH tcMEP. The neurophysiological change in this example was associated with anterior column instrumentation. Time of deterioration onset is indicated by an arrow.

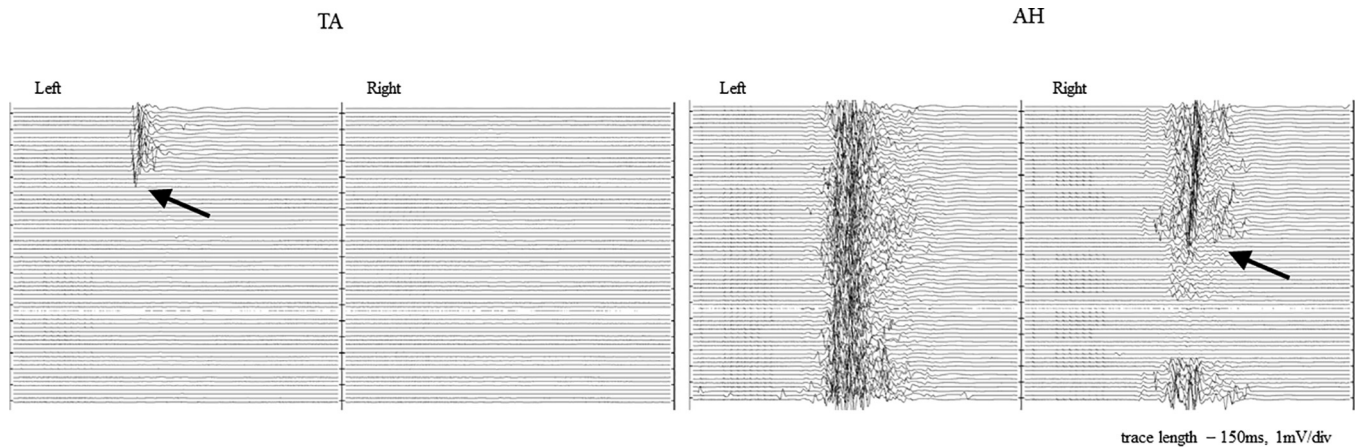


Fig. 3. Intraoperative transient and lasting deterioration of LE tcMAP data. Full-length stack data showing unrecovered deterioration of unilateral TA tcMEP data followed by transient deterioration of the contralateral AH tcMEP data. The neurophysiological changes in this example were associated with early (TA) and advanced (AH) stages of spinal cord decompression. Time of deterioration onset is indicated by an arrow.

to be chosen for corticospinal tracts monitoring. The data from this study suggest that AH muscle is a better candidate than TA muscle for LE tcMEP monitoring in ACDF surgery.

Establishment of reliable baseline tcMEP data is crucial for conducting an effective intraoperative neurophysiological monitoring; Preoperative monitorable AH tcMEP data were available at 99% of the monitored lower limbs, whereas preoperative monitorable TA tcMEP data were available only at 83% of the lower limbs. Yet, recording tcMEP data from both TA and AH muscles and relying on tcMEP data from either one enables 100% availability of preoperative monitorable LE tcMEP data. In addition, according to the current study, AH tcMEP amplitude was significantly greater than TA tcMEP at baseline measurement (326.9 ± 33.3 and 744.6 ± 54.0 μV at baseline, respectively).

Reproducible stable and robust tcMEP data from a LE muscle throughout a cervical-spine procedure is an indication for preservation of the physiological integrity of the LE-supplying corticospinal tracts. The data from this study demonstrate that the intraoperative reproducibility of tcMEP data from TA and AH muscles is different in ACDF procedures. Stable tcMEP data from one LE muscle were frequently accompanied by deterioration of tcMEP data from the other muscle in the same limb. It is reasonable to assume that as long as tcMEP data from one LE muscle remains stable, the probability of an injury to the corticospinal tracts supplying that limb is low. Under this assumption, AH muscle again seems a more reliable candidate for monitoring the integrity of the descending spinal tracts; Deterioration of AH tcMEP data was noted in 7% of the monitored lower limbs and only minor fraction of this group was accompanied by unchanged TA tcMEP data (1/11 limbs). On the contrary, TA tcMEP data deteriorated at higher rate of 28%, and major portion of this group was accompanied by unchanged AH tcMEP data (32/42 limbs). While the deterioration degree of TA and AH tcMEP was comparable, 46% the deteriorated AH tcMEP data recovered back to preoperative baseline before closure of the surgical wound, whereas only 17% of the deteriorated TA tcMEP data returned to baseline before closure.

Optimal neuromonitoring design is a value shared by both spine surgeons and neurophysiologists. Recording tcMEP data from two different bilateral LE muscles in cervical decompression procedures aims to overcome and reduce false positive neurophysiological alerts when a significant change is noticed but the probability of a real neurological damage is low. This approach is based on the assumption that as long as reliable and reproducible tcMEP data from at least one LE muscle is evident, the corticospinal tracts leading to this target limb are physiologically intact. According to this approach, even when a significant change is noticed in one LE mus-

cle during a relevant surgical context, uni- or bilaterally, no surgical intervention is usually required, as long as another tcMEP signal representing the identical pathway is intact. This strategy has been proposed and developed at our institution after experiencing false alarm neurophysiological alerts leading to false positives, based on LE tcMEP data. According to this study, the incidence of false positive neurophysiological alerts in ACDF procedures would have been unacceptable if solely the TA tcMEP was chosen for monitoring the integrity of the descending spinal tracts. On the other hand, AH tcMEP data were found to be more reliable. Considering only events with AH tcMEP changes dramatically reduces the rate of false positive potential alerts. Relying on both TA and AH muscles for monitoring tcMEP enabled a slightly better availability of LE tcMEP data at preposition baseline and a slightly lower rate of false positive potential alerts, compared to relying on AH tcMEP alone (baseline availability: 178/178 and 177/178 limbs, respectively; potential false alerts: 10/147 and 13/178 limbs, respectively). More data are needed to support the above results.

Although not systematically studied, our experience suggests the instability of LE tcMEP is a matter not associated with other spine procedures such as scoliosis correction and other procedures of posterior fusions. The anterior approach and the myelopathic conditions are two characteristics which – individually or combined – may contribute to the instability of LE tcMEP. In anterior cervical approach the spinal descending pathways, including the corticospinal tracts, are substantially exposed to potential mechanical pressure during decompression of the cord and instrumentation of the spine. Thus, even minor manipulation of the cord may lead to noticeable changes in anterior and antero-lateral tracts conduction in contrast with posterior approach procedures. On the other hand, the tightly compressed cord due to myelopathy makes the cord fibers more fragile and tenuous and therefore less tolerant of physical and manipulation. Hence, even slight pressure may disturb the physiology of the corticospinal tracts in a myelopathy, but not a healthy cord. More studies are needed to clarify these possibilities.

It has been shown that distal muscles of the upper extremity have larger cortical representation compared to proximal muscles, and motor evoked potentials recorded from distal muscles were of higher amplitude compared to proximal muscles (Wassermann et al., 1992). It is possible that the same principle is applied to LE muscles and the higher excitability of AH tcMEP is derived from a larger cortical representation. In addition, cortical representation for TA and AH function emanates from different somatotopic locations along the motor homunculus, and as such the pyramidal cell body orientations differ in relation to cranial stimulation arc.

This may also have a differential effect in the excitability of each muscle group. More research is required to explore the physiological basis for the excitability differentials between TA and AH muscles, as was demonstrated in this study.

Even though the excitability differentials in LE tcMEP, shown in this study, are theoretically supposed to be independent of external variables, the baseline-availability percentages may be different between groups. TcMEP recording is highly affected by systemic physiological parameters (Bose et al., 2004; Wang et al., 2009; Li et al., 2012; Traynelis et al., 2012), which are controlled intraoperatively by the anesthesiology team. Thus, variances in the anesthesiology methodology will be associated with varying degrees of baseline-availability of TA and AH tcMEP data.

Having additional LE tcMEP channel increases the confidence to alert the surgeon when both LE tcMEP channels deteriorate simultaneously. However, excitability differentials of the LE muscles can lead to conflicting information and probable confusion in interpreting the monitored data. Setting up two bilateral channels for recording tcMEP from two LE muscles, instead of one, does not seem to increase the surgery cost but may raise other concerns. First, it increases the volume of incoming physiological data, which need to be quickly and accurately processed by the neurophysiologist, and may distract attention from other tcMEP channels, as well as EMG and SSEP data. Second, technical limits of some current intraoperative neuromonitoring machines require abandoning simultaneous recording of other modalities as EMG and electroencephalography in order to introduce additional tcMEP channel. Adopting or rejecting the methodology of monitoring tcMEP data from two LE muscles in ACDF procedure should be based on the accompanying advantages and limitations, preferences of the surgical team and expertise of the neurophysiologist. According to this study, more weight should be placed on that emanating from AH tcMEP over TA tcMEP.

Conflict of interest

None.

References

- Appel, S., Biron, T., Goldstein, K., Ashkenazi, E., 2019. Effect of intra- and extraoperative factors on the efficacy of intraoperative neuromonitoring during cervical spine surgery. *World Neurosurg.* 123, e646–e651.
- Bose, B., Sestokas, A.K., Schwartz, D.M., 2004. Neurophysiological monitoring of spinal cord function during instrumented anterior cervical fusion. *Spine J.* 4, 202–207.
- Epstein, N.E., 2013. The need to add motor evoked potential monitoring to somatosensory and electromyographic monitoring in cervical spine surgery. *Surg. Neurol. Int.* 4, S383–91.
- Gonzalez, A.A., Jeyanandarajan, D., Hansen, C., Zada, G., Hsieh, P.C., 2009. Intraoperative neurophysiological monitoring during spine surgery: a review. *Neurosurg. Focus* 27, E6.
- Hilibrand, A.S., Schwartz, D.M., Sethuraman, V., Vaccaro, A.R., Albert, T.J., 2004. Comparison of transcranial electric motor and somatosensory evoked potential monitoring during cervical spine surgery. *J. Bone Joint Surg. Am.* 86, 1248–1253.
- Holdefer, R.N., MacDonald, D.B., Skinner, S.A., 2015. Somatosensory and motor evoked potentials as biomarkers for post-operative neurological status. *Clin. Neurophysiol.* 126, 857–865.
- Kim, D.H., Zaremski, J., Kwon, B., Jennis, L., Woodard, E., Bode, R., et al., 2007. Risk factors for false positive transcranial motor evoked potential monitoring alerts during surgical treatment of cervical myelopathy. *Spine* 32, 3041–3046.
- Legatt, A.D., Emerson, R.G., Epstein, C.M., MacDonald, D.B., Deletis, V., Bravo, R.J., et al., 2016. ACNS guideline: transcranial electrical stimulation motor evoked potential monitoring. *J. Clin. Neurophysiol.* 33, 42–50.
- Li, F., Gorji, R., Allott, G., Modes, K., Lunn, R., Yang, Z.-J., 2012. The usefulness of intraoperative neurophysiological monitoring in cervical spine surgery: ' a retrospective analysis of 200 consecutive patients. *J. Neurosurg. Anesthesiol.* 24, 185–190.
- Nanda, A., Sharma, M., Sonig, A., Ambekar, S., Bollam, P., 2014. Surgical complications of anterior cervical discectomy and fusion for cervical degenerative disk disease: a single surgeon's experience of 1,576 patients. *World Neurosurg.* 82, 1380–1387.
- Sakaura, H., Hosono, N., Mukai, Y., Ishii, T., Yoshikawa, H., 2003. C5 palsy after decompression surgery for cervical myelopathy: review of the literature. *Spine* 28, 2447–2451.
- Simon, M.V., 2018. *Intraoperative Neurophysiology: A Comprehensive Guide to Monitoring and Mapping.* Springer Publishing Company, New York, NY.
- Tamkus, A.A., Rice, K.S., Kim, H.L., 2014. Differential rates of false-positive findings in transcranial electric motor evoked potential monitoring when using inhalational anesthesia versus total intravenous anesthesia during spine surgeries. *Spine J.* 14, 1440–1446.
- Traynelis, V.C., Abode-Iyamah, K.O., Leick, K.M., Bender, S.M., Greenlee, J.D.W., 2012. Cervical decompression and reconstruction without intraoperative neurophysiological monitoring. *J. Neurosurg. Spine* 16, 107–113.
- Ushirozako, H., Yoshida, G., Kobayashi, S., Hasegawa, T., Yamato, Y., Yasuda, T., et al., 2019. Impact of total propofol dose during spinal surgery: anesthetic fade on transcranial motor evoked potentials. *J. Neurosurg. Spine* 1–9.
- Wang, A.C., Than, K.D., Etame, A.B., La Marca, F., Park, P., 2009. Impact of anesthesia on transcranial electric motor evoked potential monitoring during spine surgery: a review of the literature. *Neurosurg. Focus* 27, E7.
- Wassermann, E.M., McShane, L.M., Hallett, M., Cohen, L.G., 1992. Noninvasive mapping of muscle representations in human motor cortex. *Electroencephalogr. Clin. Neurophysiol.* 85, 1–8.
- Yonenobu, K., Hosono, N., Iwasaki, M., Asano, M., Ono, K., 1991. Neurologic complications of surgery for cervical compression myelopathy. *Spine* 16, 1277–1282.