

Vandetanib induces a marked anti-tumor effect and amelioration of ectopic Cushing's syndrome in a medullary thyroid carcinoma patient

Hashem Bseiso¹, Naama Lev-Cohain², David J Gross¹ and
Simona Grozinsky-Glasberg¹

¹Department of Medicine, Neuroendocrine Tumor Unit, Endocrinology & Metabolism Service and

²Department of Radiology, Hadassah-Hebrew University Medical Center, Jerusalem, Israel

Correspondence
should be addressed
to S Grozinsky-Glasberg
Email
simonag@hadassah.org.il

Summary

A 55-year-old woman diagnosed with sporadic MTC underwent total thyroidectomy 20 years ago. After the first surgery, elevated calcitonin levels in parallel with local disease persistence were noted and therefore she underwent repeated neck dissections. During follow-up, multiple foci of metastatic disease were noted in the neck and mediastinal lymph nodes, lungs and bones; however, the disease had an indolent course for a number of years, in parallel with a calcitonin doubling time of more than two years and without significant symptoms. During a routine follow-up visit 2 years ago, findings suggestive of Cushing's syndrome were observed on physical examination. The biochemical evaluation demonstrated markedly elevated serum calcitonin level, in parallel with lack of cortisol suppression after an overnight 1 mg dexamethasone suppression test, lack of cortisol and ACTH suppression after high-dose IV dexamethasone 8 mg, elevated plasma ACTH up to 79 pg/mL (normal <46 pg/mL) and elevated 24-h urinary free cortisol up to 501 µg/24 h (normal 9–90 µg/24 h). After a negative pituitary MRI, she underwent IPSS, which was compatible with EAS. Whole-body CT demonstrated progressive disease at most of the tumor sites. Treatment with vandetanib at a dosage of 200 mg/day was commenced. The patient showed a significant, rapid and consistent clinical improvement already after two months of treatment, in parallel with biochemical improvement, whereas a decrease in tumor size was demonstrated on follow-up CT.

Learning points:

- Ectopic Cushing's syndrome due to ectopic ACTH secretion (EAS) by MTC is an uncommon and a poor prognostic event, being associated with significant morbidity and mortality.
- We demonstrate that vandetanib is effective in controlling the signs and symptoms related to the EAS in patients with advanced progressive MTC.
- We demonstrate that vandetanib is effective in decreasing tumor size and in inducing tumor control.

Background

Medullary thyroid carcinoma (MTC) arises from the parafollicular C cells of the thyroid gland, which secrete calcitonin (1). MTC is a rare neuroendocrine tumor that accounts for only 3–5% of all thyroid carcinomas, being responsible for up to 13.4% of all thyroid

cancer-related deaths (2). The 10-year survival rate of patients with MTC is influenced by the stage of the disease at presentation, reaching up to 96% when the tumor is confined to the thyroid gland, and decreasing to about 26% when distant metastases are present,



Table 1 The biochemical evaluation at ectopic Cushing's syndrome diagnosis.

Parameters	Normal values	At EAS diagnosis	6 months earlier
Calcitonin, pg/mL	<5	111 760	67 377
CEA, ng/mL	<4.6	494	209
Cortisol (nmol/mL) after			
DST 1 mg	<50	634	
DST 8 mg	<50	540	
ACTH, pg/mL	<46	79	
UFC, µg/24 h	9–90	501	

previously to the introduction of tyrosine kinases inhibitors therapy (3).

MTC produces calcitonin, which is a specific serum marker; it may also secrete carcinoembryonic antigen (CEA) and other peptides such as adrenocorticotrophic hormone (ACTH), corticotrophin-releasing hormone (CRH), serotonin, vasoactive intestinal peptide and others (4). Ectopic Cushing syndrome due to ectopic ACTH secretion (EAS) by MTC is an uncommon and poor prognostic event, being associated with significant morbidity and mortality, as the associated complications of hypercortisolism cause death in about 50% of these patients (5). Medical therapy with inhibitors of steroidogenesis or ACTH secretion to control the complications of hypercortisolism is often unsuccessful, and bilateral adrenalectomy may be required.

Vandetanib (Caprelsa, ZD6474; AstraZeneca), a tyrosine kinase inhibitor selectively targeting the RET receptor, the epidermal growth factor receptor (EGFR) and the vascular endothelium growth factor receptor (VEGFR), is approved for the treatment of symptomatic, progressive MTC in patients with locally advanced, unresectable or metastatic disease. Several case reports have recently described the reversal of Cushing's syndrome-related symptoms induced by the known anti-secretory effect of vandetanib; however, to date, no tumor size reduction has been reported in Ectopic MTC-related Cushing's patients treated with vandetanib (6).

In this manuscript, we present a patient with sporadic long-standing metastatic MTC that developed EAS after 20 years of disease, in parallel with tumor progression. After the failure of treatment with metyrapone, vandetanib was initiated, inducing a significant clinical improvement, in parallel with both biochemical response and tumor regression.

Case presentation

A 55-year-old woman was diagnosed with sporadic MTC and underwent total thyroidectomy 20 years ago. After the first surgery, elevated calcitonin levels in parallel with local and neck lymph node disease persistence were noted and therefore she underwent repeated modified neck dissections; despite the relative decrease in serum calcitonin levels after the procedures, they never completely normalized. During follow-up, multiple foci of metastatic disease were noted in the neck and mediastinal lymph nodes, as well as in the lungs and the bones; however, the disease had an indolent course with a very slow progression rate for a number of years, both clinically (no significant symptoms) and on whole-body high-resolution CT scan imaging, in parallel with a calcitonin doubling time of more than two years. However, about three years ago, she started to suffer from secretory diarrhea and flushing, and treatment with monthly injections of somatostatin analogue Somatuline Depot 120 mg (lanreotide Autogel) (Ipsen Pharma) was initiated, after a somatostatin receptor imaging with Ga⁶⁸-DOTATATE-PET-CT showing an increased uptake in some of the tumor-related metastases. Although the diarrhea and the flushing partially improved, the treatment was interrupted due to the development of acute colitis and bowel perforation, requiring surgical intervention. During a routine follow-up visit two years ago, findings suggestive of Cushing's syndrome, namely

Table 2 Inferior petrosal sinus sampling results compatible with ectopic Cushing's syndrome. If the pituitary-to-peripheral ratio (PPR) is less than 1.5 (less than 3 if CRH was given), the patient has ectopic Cushing's.

Time (min)*	Right	Left	Periphery	PPR	Periphery
-5	49.4	**	51.7	0.95	911
0	61.6	-	55.1	1.11	878
3	33.7	-	51	0.66	914
5	61.7	-	43.4	1.42	974
10	53.5	-	44.9	1.19	980
20		-	51		924

*, related to CHR injection; **, Not performed due to technical difficulties.

Table 3 The biochemical evaluation before and during treatment with vandetanib.

Biochemical evaluation	Normal values	Before treatment with vandetanib	After 2 months of vandetanib treatment
Calcitonin (pg/mL)	<5	111 760	13 132
ACTH (pg/mL)	<46	79	31
UFC (µg/24 h)	9–90	501	28

moon face and plethora, central obesity, peripheral edema, hirsutism, acne and buffalo hump together with hypertension were observed on physical examination.

Investigation

The biochemical evaluation at that time (Table 1) demonstrated marked elevations of serum calcitonin levels up to 111 760 pg/mL, compared with 67 377 pg/mL six months earlier (normal <5 pg/mL), CEA 494 ng/mL (previous 209 ng/mL, normal <4.6 ng/mL), in parallel with lack of cortisol suppression after an overnight 1 mg dexamethasone suppression test, lack of cortisol and ACTH suppression after high-dose IV dexamethasone 8 mg test, elevated plasma ACTH up to 79 pg/mL (normal <46 pg/mL) and elevated 24 h urinary free cortisol up to 501 µg/24 h (normal 9–90 µg/24 h). After a normal pituitary MRI, she underwent an inferior petrosal sinus sampling, which was compatible with EAS (Table 2). Whole-body CT demonstrated progressive disease at most of the tumor sites.

Treatment

Based on a low body mass index (BMI), treatment with vandetanib at a reduced dosage of 200 mg/day was commenced. However, the dosage was further decreased to 100/200 mg/day, alternate days, due to the prolongation of the QT interval on electrocardiography.

Outcome and follow-up

The patient showed a significant and rapid clinical improvement (the blood pressure normalized, the edema, plethora and acne completely disappeared and the fatigue improved) already two months after treatment initiation, in parallel with biochemical improvement (Table 3). The clinical and biochemical improvement has continued until the time of this publication (9 months since treatment start), whereas a decrease in tumor size was also demonstrated on follow-up CT (Fig. 1).

Discussion

ACTH-dependent ectopic Cushing's syndrome is responsible for approximately 15% of adult Cushing's syndrome. Cushing's syndrome due to ectopic ACTH secretion (EAS) by MTC is rare and associated with poor prognosis, as up to 80% of these patients do not survive more than ~12.8 months after the diagnosis of hypercortisolemia (7). The diagnosis of MTC-related Cushing's syndrome is based on the presence of hypercortisolism (with high or inappropriately normal ACTH concentrations) that is not suppressed by high-dose dexamethasone, the absence of a pituitary adenoma and the parallel progression of Cushing's syndrome and MTC (4, 8).

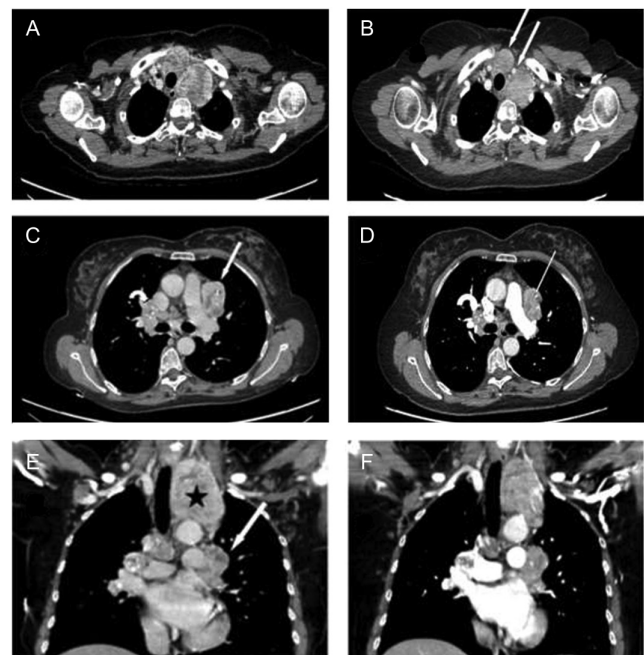


Figure 1

Computed tomography of the neck and chest showing a decrease in tumor size observed in our patient under the treatment with vandetanib. Axial CT images with contrast of the chest: Heterogeneous masses are seen in the upper mediastinum (arrows) before the treatment (A); there is decrease in their size after treatment (B). Heterogeneous masses are seen in the mediastinal (arrow) and hilum areas (curved arrow), demonstrating microcalcifications (C); after treatment, the masses have decreased in size. (D) Coronal CT images with contrast of the chest: The metastatic disease is seen in the upper mediastinum (asterisk) and lung hilum bilaterally (arrows) (E); decrease in lesions size after treatment (F).



Table 4 A summary of the case reports of ectopic Cushing's syndrome related to medullary thyroid carcinoma, including our patient, who received vandetanib, to date (adapted from Pitoia F *et al.* Arch Endocrinol Metab. 2015;59(4):343–6).

Case report	MTC type (familial/ sporadic)	Treatment dose of vandetanib	Treatment duration (months)	Response of EAS (days)	Tumor response	Treatment withdrawal/under treatment
Nella <i>et al.</i> (8)	MEN 2B	200 mg/day	29	30	Stable	Tumor progression
Baudry <i>et al.</i> (6)	Not reported	300 mg/day	4.2	15	Stable	Not reported
Fabián <i>et al.</i> (10)	Not reported	300 mg/day	8	30	Stable	Under treatment
This report	Sporadic	100/200 mg/day, alternately	10, continuing	30	Partial response	Under treatment

The usual treatment of these patients involves either chemical (using adrenolytic drugs such as ketoconazole, metyrapone, etomidate, etc.) or surgical adrenalectomy, in an attempt to control the severe hypercortisolism and its related morbidity (5).

Vandetanib, a tyrosine kinase inhibitor targeting a variety of receptors involved in tumor progression (e.g., the RET receptor, the epidermal growth factor receptor (EGFR), the vascular endothelial growth factor receptor-2 (VEGFR)), has been proven effective in patients with progressive MTC, both sporadic and familial types (9). Since its approval in 2011 by the Food and Drug Administration in the United States, a few case reports demonstrated that vandetanib may be effective for control of EAS-related symptoms in patients with advanced MTC (8, 9). Two recent reports suggested that vandetanib effectively reversed the ACTH-dependent ectopic Cushing's syndrome in two adult patients with MTC, and this effect was confirmed in a young adolescent patient with MTC-related Cushing's syndrome also; interestingly, the control of the hypercortisolism was prolonged and independent of MTC tumor progression (5, 6, 8). However, no clear anti-proliferative tumor effect was reported to date, in terms of reduction in tumor size, in patients with MTC-related EAS (Table 4).

In the present report, the rapid control of the hypercortisolism with vandetanib treatment is in agreement with the hypothesis that this class of drugs could have a cortisol-lowering effect by blocking CRH and/or ACTH secretion by the tumor cells (6). In addition, the decrease in tumor size observed in our patient suggests that vandetanib treatment may also have an antiproliferative effect in the rare patients with MTC-associated EAS.

Our report confirms the previous findings by showing that treatment with vandetanib may effectively control the signs and symptoms related to ectopic ACTH secretion in patients with advanced progressive MTC and that it is also effective in decreasing tumor size and inducing

tumor control. Additional studies are needed to assess the anti-secretory effect in other neuroendocrine tumor-related EAS and to confirm our observation on vandetanib anti-tumor effect.

Patient's perspective

We welcome comments from your patient; their own description of their experience may help other patients or clinicians who are dealing with a similar problem. If your patient would like to contribute please ensure they include only relevant personal details. Patients may describe their symptoms, how any tests and treatments affected them and how the problem is now.

Declaration of interest

The authors declare that there is no conflict of interest that could be perceived as prejudicing the impartiality of the research reported.

Funding

This research did not receive any specific grant from any funding agency in the public, commercial or not-for-profit sector.

Patient consent

Written informed consent was obtained from the patient for publication of this case report.

References

- Grozinsky-Glasberg S, Benbassat CA, Tsvetov G, Feinmesser R, Peretz H, Shimon I & Lapidot M 2007 Medullary thyroid cancer: a retrospective analysis of a cohort treated at a single tertiary care center between 1970 and 2005. *Journal of American Thyroid Association* **17** 549–556. (doi:10.1089/thy.2006.0229)
- Wells SA Jr, Asa SL, Dralle H, Elisei R, Evans DB, Gagel RF, Lee N, Machens A, Moley JF, Pacini F, *et al.* 2015 Revised American thyroid association guidelines for the management of medullary thyroid carcinoma. *Journal of American Thyroid Association* **25** 567–610. (doi:10.1089/thy.2014.0335)
- Roman S, Lin R & Sosa JA 2006 Prognosis of medullary thyroid carcinoma: demographic, clinical, and pathologic predictors of survival in 1252 cases. *Cancer* **107** 2134–2142. (doi:10.1002/cncr.22244)



- 4 de Groot JW, Kema IP, Breukelman H, van der Veer E, Wiggers T, Plukker JT, Wolffenbuttel BH & Links TP 2006 Biochemical markers in the follow-up of medullary thyroid cancer. *Journal of American Thyroid Association* **16** 1163–1170. (doi:10.1089/thy.2006.16.1163)
- 5 Barbosa SL, Rodien P, Leboulleux S, Niccoli-Sire P, Kraimps JL, Caron P, Archambeaud-Mouveroux F, Conte-Devolx B & Rohmer V 2005 Ectopic adrenocorticotrophic hormone-syndrome in medullary carcinoma of the thyroid: a retrospective analysis and review of the literature. *Journal of American Thyroid Association* **15** 618–623. (doi:10.1089/thy.2005.15.618)
- 6 Baudry C, Paepgaey AC & Groussin L 2013 Reversal of Cushing's syndrome by vandetanib in medullary thyroid carcinoma. *New England Journal of Medicine* **369** 584–586. (doi:10.1056/NEJMc1301428)
- 7 Findling JW & Tyrrell JB 1986 Occult ectopic secretion of corticotropin. *Archives of Internal Medicine* **146** 929–933. (doi:10.1001/archinte.1986.00360170151022)
- 8 Nella AA, Lodish MB, Fox E, Balis FM, Quezado MM, Whitcomb PO, Derdak J, Kebebew E, Widemann BC & Stratakis CA 2014 Vandetanib successfully controls medullary thyroid cancer-related Cushing's syndrome in an adolescent patient. *Journal of Clinical Endocrinology and Metabolism* **99** 3055–3059. (doi:10.1210/jc.2013-4340)
- 9 Durante C, Paciaroni A, Plasmati K, Trulli F & Filetti S 2013 Vandetanib: opening a new treatment practice in advanced medullary thyroid carcinoma. *Endocrine* **44** 334–342. (doi:10.1007/s12020-013-9943-9)
- 10 Pitoia F, Bueno F, Schmidt A, Lucas S & Cross G 2015 Rapid response of hypercortisolism to vandetanib treatment in a patient with advanced medullary thyroid cancer and ectopic Cushing's syndrome. *Archives of Endocrinology and Metabolism* **59** 343–346. (doi:10.1590/2359-3997000000057)

Received in final form 27 September 2016

Accepted 5 October 2016