



Case report

A rare tumor of trachea: Inflammatory myofibroblastic tumor diagnosis and endoscopic treatment



Mehmet Akif Özgül^a, Ümran Toru^{b,*}, Murat Acat^c, Güler Özgül^d, Erdoğan Çetinkaya^a, H. Erhan Dinçer^e, Derya Özden Omaygenç^f, Halide Nur Ürer^g

^a Yedikule Chest Diseases and Thoracic Surgery Training and Research Hospital, Department of Chest Diseases, İstanbul 34020, Turkey

^b Dumlupınar University Faculty of Medicine, Department of Chest Diseases, Kütahya 43100, Turkey

^c Karabük University Faculty of Medicine, Department of Chest Diseases, Karabük 78050, Turkey

^d Bağcılar Education and Research Hospital, Department of Chest Diseases, İstanbul 34200, Turkey

^e University of Minnesota Division of Pulmonary, Allergy, Sleep and Critical Care, MN OH 43210, United States

^f Yedikule Chest Diseases and Thoracic Surgery Training and Research Hospital, Department of Anesthesiology and Reanimation, İstanbul 34020, Turkey

^g Yedikule Chest Diseases and Thoracic Surgery Training and Research Hospital, Department of Pathology, İstanbul 34020, Turkey

A B S T R A C T

Keywords:

Inflammatory myofibroblastic tumor
Trachea
Bronchoscopy

Inflammatory myofibroblastic tumors (IMTs) are rare childhood neoplasms, with benign clinical course. Although etiology of IMTs are not clear, recent studies have reported that IMT is a true neoplasm rather than a reactive or inflammatory lesion. IMTs are rarely seen in adults and tracheal involvement is also rare both in adults and also in children. We describe a 16-year old female patient who was misdiagnosed and treated as asthma in another center for a few months and presented with acute respiratory distress due to upper airway obstruction. Computerized tomography (CT) of the chest and rigid bronchoscopy revealed a mass lesion that was nearly totally obliterating tracheal lumen. Bronchoscopic resection was performed under general anesthesia and the final pathological diagnosis was tracheal IMT.

© 2014 The Authors. Published by Elsevier Ltd. This is an open access article under the CC BY-NC-ND license (<http://creativecommons.org/licenses/by-nc-nd/3.0/>).

Introduction

IMTs are rare, benign neoplasms and usually encountered in children under 16 years of age. The natural history of this disease is poorly understood [1–3]. Although IMTs have been described in virtually every anatomic location, there are only a few documented reports with tracheal involvement [4].

Here we report a 16-year old female patient with tracheal IMT who presented with acute respiratory distress due to upper airway obstruction.

Case report

A 16-year old female patient was admitted to our hospital with dyspnea and acute respiratory distress. Her medical history was unremarkable except for asthma that was treated in another institution for a few months. At presentation, stridor was the only

abnormal finding on physical examination. Pulmonary function tests (PFTs) could not be performed because of respiratory distress. Laboratory data revealed mild leukocytosis and normal comprehensive metabolic panel. Arterial blood gas analysis revealed pH: 7.42, PCO₂: 35 mm Hg, PO₂: 41 mm Hg, SaO₂%, 77.8%, HCO₃⁻: 22.9 mmol/L. Although postero-anterior (PA) Chest X-Ray was normal and Thorax CT showed a mass which was nearly totally obliterating the tracheal lumen (Fig. 1).

Rigid bronchoscopy was performed under general anesthesia and showed a vascularized, smooth-surfaced, lobulated mass lesion that was obliterating tracheal lumen just below the cord vocals (Fig. 2). The mass was removed with electrocautery snare and the surrounding area of tumor was coagulated with Argon Plasma Coagulation (APC). Cryotherapy was performed after APC (Fig. 3). On clinical follow-up, inspiratory stridor was diminished after the procedure and PFT values were as follows; FVC: 3.5 L (108.2% of predicted), FEV₁: 3.3 L (121.8% of predicted), FEV₁/FVC: 95.59%. Immunohistochemical studies were performed in addition to routine histologic examination and histological findings of the lesion showed a positivity for vimentin, smooth muscle actin (SMA) and Ki-67 that was accompanied by myofibroblastic spindle cells and inflammatory cell infiltration. Pathological diagnosis of the mass was consistent with IMT.

* Corresponding author. Tavşanlı Yolu. 10. km, Dumlupınar University Faculty of Medicine, Department of Chest Diseases, Kütahya 43100, Turkey. Tel.: +90 543 216 16 98; fax: +90 274 265 22 85.

E-mail address: umran_toru_81@hotmail.com (Ü. Toru).

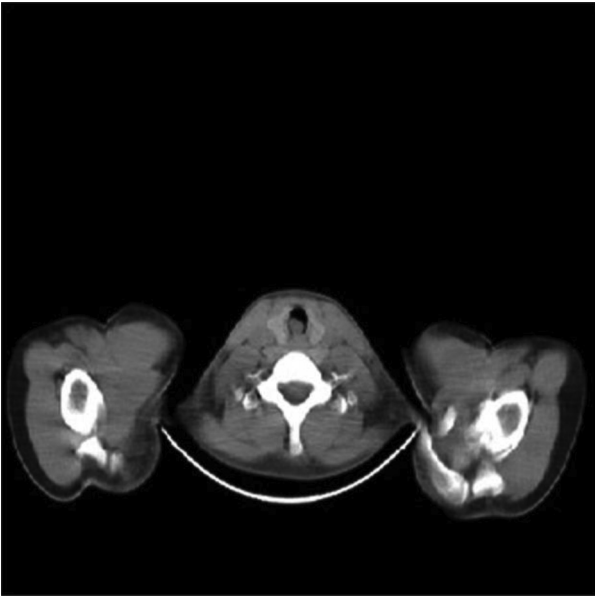


Fig. 1. Chest CT image of the mass lesion which was obliterating tracheal lumen.

After endoscopic treatment, control positron emission tomography (PET)–CT showed local involvement around the resection site and there was no distant metastasis. A thoracotomy with segmental tracheal resection was planned. Because the patient did not accept the treatment she was discharged home with the plan of close follow-up in the clinic.

Discussion

World Health Organization recognizes IMT as a distinctive lesion composed of a myofibroblastic spindle cell population accompanied by an inflammatory infiltrate of plasma cells, lymphocytes, and eosinophils [4].

Because of its histopathological character IMTs have also been named as plasma cell granuloma, fibrous histiocytoma, xanthogranuloma, or inflammatory pseudotumor, but it is popularly known

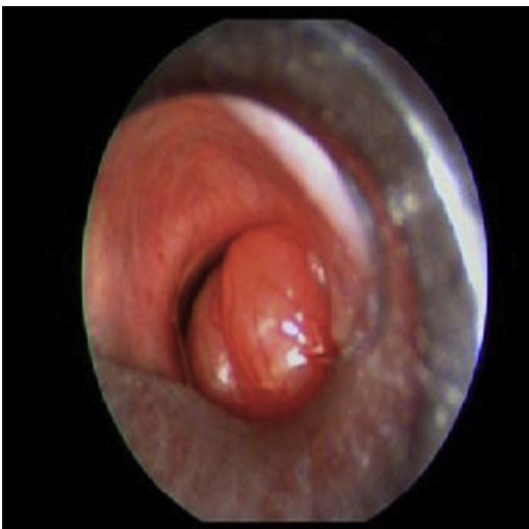

Fig. 2. Bronchoscopic view of vascularized, smooth-surfaced, lobulated mass lesion that was obliterating tracheal lumen after cord vocals.

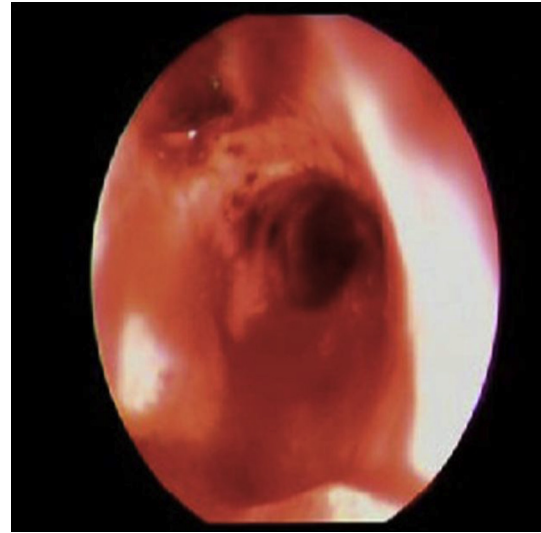


Fig. 3. Bronchoscopic view after endoscopic resection, APC and cryotherapy.

as inflammatory pseudotumor. It is a slow-growing quasi-neoplastic lesion. Although its clinical course is benign it can mimic malignancy both clinically and radiologically [5,6].

Recently, rare cases with aggressive clinical picture, such as local recurrence, malignant transformation, or distant metastasis, were reported. Now it is believed that IMTs are low-grade mesenchymal malignancies [4]. However the overall prognosis is generally excellent [2,7].

Although the lung is the most common site for these tumors, IMTs may also develop in other sites such as stomach, orbit, mesentery, heart, gastrointestinal tract, adrenal gland and central nervous system [3,6,8–10]. Lung IMTs are rare in adults although they represent one of the most common lung tumors in pediatric population. Their frequency is 0.04%–0.07%. IMTs constitute of 20% of all primary lung tumors and 57% of all benign lung tumors [11–13].

Based on the location within the chest, IMTs are divided into two groups as parenchymal and airway IMTs. Most IMTs manifest as a solitary lesion in the lung parenchyma, and only 10% of these develop within the airway that usually present with early respiratory symptoms [14]. Involvement of trachea and bronchi constitutes of 6.7% of cases, and trachea alone is extremely rare with only 2.7% of all reported cases [12,13].

As we see from the literature airway IMTs, especially those with tracheal involvement, are rarely seen in both adults and children therefore our 16-years old case is an example of this rare tracheal entity.

Although the etiology of IMTs is not understood, it is thought that they may be a result of the inflammation following a minor trauma or surgery. Association with malignancy or an autoimmune process have also been described [4,15,16]. A study by Marsubara et al. reported the possibility of infection as a triggering factor for IMT since all of their 32 cases were originated from organizing pneumonia [17]. On the other hand, our patient did not have history of trauma or surgery or evidence of infection.

Applebaum et al. proposed that COX2 and VEGF, as mediators of angiogenesis, may play a role in the pathogenesis and growth of IMTs [18]. Although previous studies have suggested that IMTs could be inflammatory, and reactive lesions which develop as a consequence of some type of pulmonary infection, recent studies suggested that they are true neoplasms rather than a purely inflammatory or reactive lesion because of the presence of clonal

chromosomal abnormalities of 2p23 and rearrangement of the anaplastic lymphoma kinase (ALK) receptor tyrosine-kinase gene locus or fusion of ALK with the clathrin heavy chain gene localized on 17q23 [19,20].

The symptoms of IMTs are usually nonspecific and depends on the location, including dyspnea, stridor, chronic cough, hemoptysis, and pleuritic chest pain. In the small number of patients with endobronchial lesions, the clinical presentation may be acute and serious due to post-obstructive pneumonia or symptoms associated with airway obstruction. Some cases have been misdiagnosed and treated as asthma [4,21]. Our patient had typical symptoms of upper airway obstruction such as stridor and severe respiratory distress. She also carried a diagnosis of asthma which we believe was not the case since her symptoms improved after treatment.

Radiographic investigation with PA and left lateral chest radiograms, CT imaging and endoscopy are the essential methods in diagnostic workup of every obstructive tracheal lesion [2]. In our case we performed PA chest radiogram and Chest CT for radiological evaluation. While chest radiogram was unremarkable, CT showed a mass lesion that was nearly totally obliterating the proximal tracheal lumen.

IMTs should be in the differential diagnosis of tracheal tumors and a tissue biopsy is necessary for a definitive diagnosis of IMT [6,22].

Immunohistochemical analysis of the biopsy demonstrates a positivity for vimentin, muscle-specific actin, SMA and cytokeratin which are characteristic for myofibroblasts [10]. Immunohistochemical analysis of the tumor in our case showed a positivity for vimentin and SMA with myofibroblastic spindle cells and inflammatory cell infiltration. Final pathological diagnosis was IMT.

While the treatment of IMT used to be wide local excision and radiation therapy reserved for recurrences in the past, the current approach to treatment is conservative surgery. Ramachandra et al. reported their experiences of 18 cases of soft tissue IMTs and underlined that simple surgical resection was curative in the treatment of these lesions [2,7,23,24].

Recurrence can occur after resection so local excision with a rim of normal tissue should be performed to decrease the rate of recurrence [21,23,24]. Coffin et al. reported a recurrence rate of 25% in those with incomplete resection and the overall aggressive behavior of IMTs in their series was related to the anatomic site, proximity of the tumor to vital structures, and multinodularity of the lesion, all of which required definitive resection [10].

Although the usual treatment for this entity is surgical excision, endoscopic resection may be an adequate approach when the tumor is completely endoluminal [21].

For tracheal lesions, CO₂ laser or electrocautery has been successful with no need for tracheal resection. Low-dose radiotherapy (RT) has been found to be successful in a small number of cases especially those tumors predominantly with lymphoplasmacytic cell infiltration rather than fibrous tissue. RT is reserved as a last resort in treatment when surgery is no feasible [2,9,22,24].

Recently, some studies showed successful results with steroids as initial therapy in tumors outside the orbit. Chemotherapy in the form of cyclosporine, methotrexate, azothioprine, and cyclophosphamide has been used only in those with malignancy on pathology or distant metastasis with various results [7,9,22].

A long-term follow-up is essential in the management of IMTs and follow-up should be at regular intervals during the first few years because most recurrences will occur within one year of initial surgery, with only a few reports of late recurrences in the literature [2,23,24].

The obstructing tracheal mass in our case was removed by using electrocautery snare. After coagulation was achieved with APC, cryotherapy was done for the remaining endoluminal lesions.

Following endobronchial resection and the diagnosis of IMT, we performed PET-CT and local involvement was detected around the resection site. We did not use steroids, RT or chemotherapy as further treatment options in our case because there was no diagnosis of malignancy or any evidence of distant metastasis according to histopathological and radiological evaluation. We offered thoracotomy with local excision of the involved trachea however our patient declined the surgical approach but agreed to be followed in the clinic.

In summary, the surgical resection has been the most relevant treatment for tracheal IMTs. Resection of these tumors can be performed either bronchoscopically by using debulking methods such as CO₂ laser, electrocautery, or open surgical intervention with segmental tracheal resection. If the lesion is completely endoluminal based on imaging studies, endoscopic resection is suggested. Radical surgery and/or adjuvant RT and chemotherapy are not indicated unless the disease is malignant or metastasized [4,21].

Consequently, it is important to consider tracheal IMT in the differential diagnosis of cases with respiratory distress due to upper airway obstruction. IMTs can mimic malignancies both clinically and radiologically but if there is a prediagnosis of IMT, clinicians must be cautious not to perform a radical surgery until the final pathologic diagnosis is completed. There are several treatment options but complete extirpation of the lesion is desirable if the tumor is completely endoluminal and endoscopic resection is the current treatment of choice with excellent results.

Authorship statement

The conception and design of the study: Mehmet Akif Özgül, Ümran Toru, Murat Acat, Erdoğan Çetinkaya, Derya Özden Omaygenç, Halide Nur Ürer.

Drafting or revising the article critically for important intellectual content: Mehmet Akif Özgül, Ümran Toru, Güler Özgül, H. Erhan Dinçer, Derya Özden Omaygenç, Halide Nur Ürer.

Final approval of the version to be submitted: Mehmet Akif Özgül, Ümran Toru, Murat Acat, Güler Özgül, Erdoğan Çetinkaya, H. Erhan Dinçer, Derya Özden Omaygenç, Halide Nur Ürer.

Conflict of interest

There is no conflict of interest between the authors.

Ethics

Our work has been approved by the ethical committees of the related hospitals institutions and the subjects gave informed consent to the work.

Acknowledgments

There is not any acknowledgements.

References

- [1] Debelenko LV, Arthur DC, Pack SD, et al. Identification of CARS-ALK fusion in primary and metastatic lesions of an inflammatory myofibroblastic tumor. *Lab Invest* 2003;83:1255–65.
- [2] Bumber Z, Jurčina M, Manojlović S, et al. Inflammatory pseudotumor of the trachea. *J Pediatr Surg* 2001;36:631–4.
- [3] Jain S, Chopra P, Agarwal A, et al. Inflammatory myofibroblastic tumor of trachea. *J Bronchology Interv Pulmonol* 2013;20:80–3. <http://dx.doi.org/10.1097/LBR.0b013e31827cd58f>.
- [4] Venizelos I, Papatheomas T, Anagnostou E, et al. Pediatric inflammatory myofibroblastic tumor of the trachea: a case report and review of the literature. *Pediatr Pulmonol* 2008;43:831–5. <http://dx.doi.org/10.1002/ppul.20869>.
- [5] Lee HJ, Kim JS, Choi YS, et al. Treatment of inflammatory myofibroblastic tumor of the chest: the extent of resection. *Ann Thorac Surg* 2007;84:221–4.

- [6] Browne M, Abramson LP, Chou PM, et al. Inflammatory myofibroblastic tumor (Inflammatory pseudotumor) of the neck infiltrating the trachea. *J Pediatr Surg* 2004;39:e1–4.
- [7] Fradis M, Rosenman D, Podoshin L, et al. Steroid therapy for plasma cell granuloma of the larynx. *Ear Nose Throat J* 1988;67:558–64.
- [8] Ono Y, Miyoshi T, Inutsuka K, et al. Inflammatory myofibroblastic tumor of the trachea; report of a case. *Kyobu Geka* 2006;59:871–5.
- [9] Narla LD, Newman B, Spottswood SS, et al. Inflammatory pseudotumor. *Radiographics* 2003;23:719–29.
- [10] Coffin CM, Watterson J, Priest JR, et al. Extrapulmonary inflammatory myofibroblastic tumor (inflammatory pseudotumor). A clinicopathologic and immunohistochemical study of 84 cases. *Am J Surg Pathol* 1995;19:859–72.
- [11] Ishida T, Oka T, Nishino T, et al. Inflammatory pseudotumor of the lung in adults: radiographic and clinicopathological analysis. *Ann Thorac Surg* 1989;48:90–5.
- [12] Hartman GE, Shochat SJ. Primary pulmonary neoplasms of childhood: a review. *Ann Thorac Surg* 1983;36:108–19.
- [13] Barker AP, Carter MJ, Matz LR, et al. Plasma-cell granuloma of the trachea. *Med J Aust* 1987;146:443–5.
- [14] Do KH, Lee JS, Seo JB, et al. Pulmonary parenchymal involvement of low-grade lymphoproliferative disorders. *J Comput Assist Tomogr* 2005;29:825–30.
- [15] Sanders BM, West KW, Gingalewski C, et al. Inflammatory pseudotumor of the alimentary tract: clinical and surgical experience. *J Pediatr Surg* 2001;36:169–73.
- [16] Maves CK, Johnson JF, Bove K, et al. Gastric inflammatory pseudotumor in children. *Radiology* 1989;173:381–3.
- [17] Matsubara O, Tan-Liu NS, Kenney RM, et al. Inflammatory pseudotumors of the lung: progression from organizing pneumonia to fibrous histiocytoma or to plasma cell granuloma in 32 cases. *Hum Pathol* 1988;19:807–14.
- [18] Applebaum H, Kieran MW, Cripe TP, et al. The rationale for nonsteroidal anti-inflammatory drug therapy for inflammatory myofibroblastic tumors: a Children's Oncology Group study. *J Pediatr Surg* 2005;40:999–1003.
- [19] Snyder CS, Dell'Aquila M, Haghghi P, et al. Clonal changes in inflammatory pseudotumor of the lung: a case report. *Cancer* 1995;76:1545–9.
- [20] Bridge JA, Kanamori M, Ma Z, et al. Fusion of the ALK gene to the clathrin heavy chain gene, CLTC, in inflammatory myofibroblastic tumor. *Am J Pathol* 2001;159:411–5.
- [21] Andrade FM, Abou-Mourad OM, Judice LF, et al. Endotracheal inflammatory pseudotumor: the role of interventional bronchoscopy. *Ann Thorac Surg* 2010;90:e36–7. <http://dx.doi.org/10.1016/j.athoracsur.2010.06.013>.
- [22] Weisman RA, Osguthorpe JD. Pseudotumor of the head and neck masquerading as neoplasia. *Laryngoscope* 1988;98:610–4.
- [23] Ramachandra S, Hollowood K, Bisceglia M, et al. Inflammatory pseudotumour of soft tissues: a clinicopathological and immunohistochemical analysis of 18 cases. *Histopathology* 1995;27:313–23.
- [24] Souid AK, Ziemba MC, Dubansky AS, et al. Inflammatory myofibroblastic tumor in children. *Cancer* 1993;72:2042–8.