

# Pediatric knowledge update: Approach to the management of vein of Galen aneurysmal malformations in neonates

Daniel Hansen, Peter T. Kan, Gaddum D. Reddy, Arvind Chintagumpala Mohan, Andrew Jea, Sandi Lam

Department of Neurosurgery, Division of Pediatric Neurosurgery, Baylor College of Medicine, Texas Children’s Hospital, Houston, TX, USA

E-mail: Daniel Hansen - [dxhansel@texaschildrens.org](mailto:dxhansel@texaschildrens.org); Peter T. Kan - [peter.kan@bcm.edu](mailto:peter.kan@bcm.edu); Gaddum D. Reddy - [gdreddy@bcm.edu](mailto:gdreddy@bcm.edu); Arvind Chintagumpala Mohan - [arvind.mohan@bcm.edu](mailto:arvind.mohan@bcm.edu); Andrew Jea - [ahjea@texaschildrens.org](mailto:ahjea@texaschildrens.org); \*Sandi Lam - [sklam@texaschildrens.org](mailto:sklam@texaschildrens.org)  
\*Corresponding author

Received: 27 November 15    Accepted: 26 March 16    Published: 13 May 16

**Key Words:** Neonate, pediatric, vascular, vein of Galen aneurysmal malformation, vein of Galen malformation

## CASE EXAMPLE

A newborn female born via cesarean section at 39 weeks gestation was transferred to our institution for severe respiratory distress after delivery. She was intubated and required 100% fraction of inspired oxygen to maintain adequate saturations. She was also started on vasopressor medications secondary to hypotension. An echocardiogram of the heart showed diastolic flow reversal in the transverse aortic arch and increased flow in the superior vena cava. A bruit was auscultated over the anterior fontanelle that was concerning for an intracranial vascular malformation. Bedside, head ultrasound confirmed the presence of a vein of Galen malformation. Her liver was enlarged without signs of liver failure. Her anuria resolved with improved renal function after her hypotension was treated. Electroencephalography was negative for seizure activity. Her Bicêtre score was calculated to be between 9 and 11. As per the Lasjaunias algorithm, the baby was a candidate for emergent endovascular embolization.

Cerebral angiogram revealed an extensive choroidal type vein of Galen malformation with severe arteriovenous shunting [Figures 1 and 2]. Partial embolization was achieved using a combination of platinum coils and the liquid embolic agent Onyx, with a significant reduction in posttreatment arteriovenous shunting. Posttreatment echocardiogram showed improvement in the left ventricular function. Repeated partial embolizations were performed 3 more times over the next 3 months [Figure 3]. Ventriculomegaly remained stable on serial imaging. Her cardiac function as assessed by her

brain natriuretic peptide normalized. Her pulmonary hypertension steadily improved, allowing her to be discharged to home on room air.

## BACKGROUND

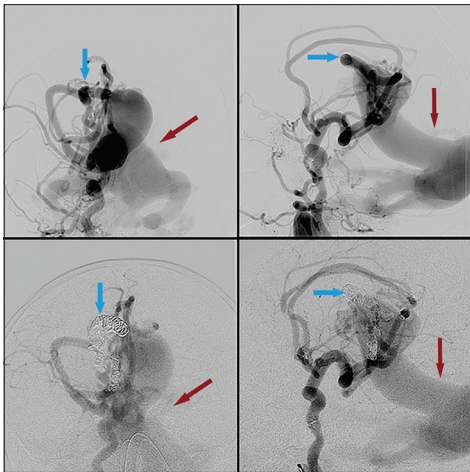
Neonatal vein of Galen aneurysmal malformations (VGAMs) are rare; the incidence is approximately 1 in 25,000.<sup>[13,17,22]</sup> The most common presentation of VGAM as a neonate is high-output congestive heart failure, which carries high rates of morbidity and mortality.<sup>[6]</sup> The age of symptomatic onset is often characterized by a distinct clinical presentation: Neonates usually present with high-output cardiac failure;

This is an open access article distributed under the terms of the Creative Commons Attribution-NonCommercial-ShareAlike 3.0 License, which allows others to remix, tweak, and build upon the work non-commercially, as long as the author is credited and the new creations are licensed under the identical terms.

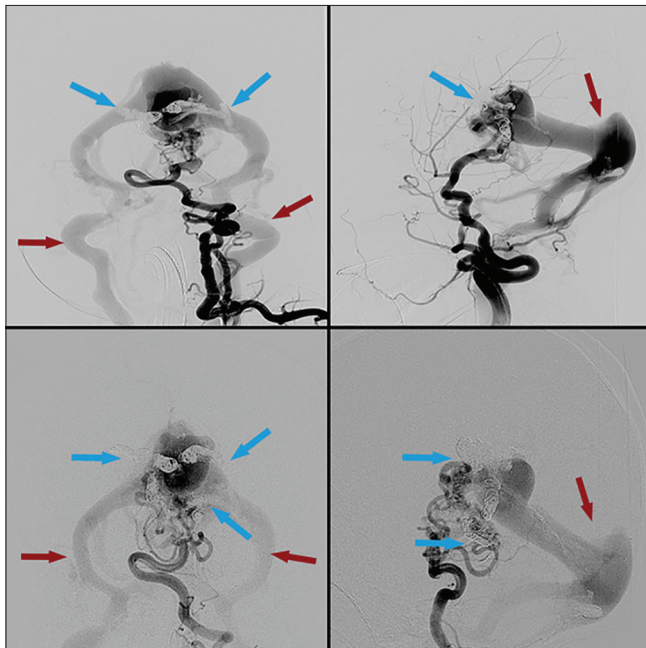
For reprints contact: [reprints@medknow.com](mailto:reprints@medknow.com)

Access this article online	
Quick Response Code:	Website: <a href="http://www.surgicalneurologyint.com">www.surgicalneurologyint.com</a>
	DOI: 10.4103/2152-7806.182415

**How to cite this article:** Hansen D, Kan PT, Reddy GD, Mohan AC, Jea A, Lam S. Pediatric knowledge update: Approach to the management of vein of Galen aneurysmal malformations in neonates. *Surg Neurol Int* 2016;7:S317-21.  
<http://surgicalneurologyint.com/Pediatric-knowledge-update:-Approach-to-the-management-of-vein-of-Galen-aneurysmal-malformations-in-neonates/>



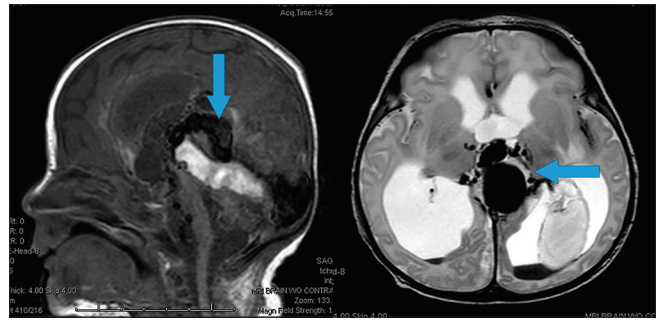
**Figure 1:** First embolization treatment. Right internal carotid injection. Pretreatment (top) and posttreatment (bottom). Blue arrows highlighting arterial feeders pre- and post-coil embolization. Note slightly decreased contrast filling of venous outflow after coil placement, highlighted by red arrows



**Figure 3:** Third and fourth embolization treatments. Left vertebral injection. Pretreatment (top) and posttreatment (bottom). Multiple coil constructs (blue arrows) are now visible with further reduction in contrast filling of the venous outflow (red arrows)

infants present with increasing head circumference and hydrocephalus; toddlers present with developmental delay, hydrocephalus, and/or seizures; and older children can have subarachnoid hemorrhage, headache, and/or seizures.<sup>[1,21]</sup> Reviewing treatment outcomes by age shows that mortality affects 37% of neonates following endovascular treatment, and 6.5% and 3.2%, respectively, of infants and children following treatment.<sup>[1,10,15]</sup>

VGAM represents an embryonic arteriovenous shunt in the subarachnoid space and the choroidal fissure.



**Figure 2:** Magnetic resonance imaging of the brain without contrast. Sagittal T1 (left) sequence and axial T2 (right) sequence highlighting dilated vessels (arrows) converging to the vein of Galen varix, dilations of the draining straight sinus

Steinheil first described this entity in 1895, but it was Boldrey and Miller in 1949 who first documented a true form of VGAM by identifying multiple arteriovenous communications draining into the dilated vein of Galen.<sup>[1]</sup> In 1989, Rayboud traced the anatomy to a persistent embryological precursor to the vein of Galen: The median prosencephalic vein of Markowski (MProsv).<sup>[12]</sup> Lasjaunias classified VGAM into two anatomical forms, a mural form (direct fistula from MProsv) and a choroidal form (multiple choroidal arteries contributing to an intermediary network before drainage into the large venous pouch), the predominant form.<sup>[16]</sup>

The diagnosis can be made in utero by ultrasound and can be identified between the 6<sup>th</sup> and 11<sup>th</sup> week of gestation. Fetal magnetic resonance imaging can better evaluate cerebral atrophy, ventricular size, and cardiac insufficiency. Fetal distress presents as cardiac insufficiency and/or hydrops. Neonatal diagnosis is typically made after identifying severe cardiopulmonary distress during or acutely after birth, along with the associated pulmonary, neurological, hepatic, and renal dysfunction.<sup>[9]</sup>

Before the advent of endovascular interventions, mortality in neonatal VGAM was nearly 90%.<sup>[19]</sup> With the introduction of embolization techniques and advanced neonatal critical care for severe cardiopulmonary illness, mortality has decreased to around 50%.<sup>[19]</sup> Immediate multidisciplinary neonatal assessment and care are clearly imperative.

In 2006, Lasjaunias described his large experience with VGAM management. The primary and immediate goal is stabilization of the life-threatening congestive heart failure. The next step is to attempt treatment of the VGAM. He recommends a staged approach to better manage the risk that comes with the instant flow reversal with obliteration of the VGAM. Any presenting hydrocephalus is not treated until after treatment of the VGAM to avoid worsening flow through the VGAM, which can occur with lowering of intracranial pressure.<sup>[5,10,16]</sup>

## EVALUATION AND TREATMENT

Initial consultation should include a thorough neurological examination, bedside electroencephalography, auscultation for cranial bruit, measurement of head circumference, and signs or symptoms of hydrocephalus. Although the immediate clinical concern is cardiac failure, VGAM has direct cerebral consequences including encephalopathy, hydrocephalus, seizures, and developmental delay.

One option for evaluation of the newborn with VGAM is based on the Bicêtre score to determine potential treatment options.<sup>[10,16]</sup> This 21-point scale gives points for the severity of signs and symptoms pertaining to the cardiac, pulmonary, neurological, hepatic, and renal systems [Table 1]. Clinical and laboratory values are used to calculate the Bicêtre score for the neonate presenting with VGAM. A score of <8 out of 21 suggests a near fatal prognosis, and the infant is considered too unstable for emergent embolization. A score between 8 and 12 characterizes neonates who are most likely to benefit from emergent embolization. A score >12 suggests infants who are candidates for medical management of their cardiopulmonary insufficiency. Medical management is continued until around 5 months of age when their larger size decreases the risks of extended embolization. Figure 4 summarizes this treatment algorithm.

Cardiology assessment of cardiac function and superior vena cava flow should proceed right away. An echocardiogram should be performed to assess for the function of all the cardiac chambers, the presence of a pulmonary ductus arteriosus shunt, degree of pulmonary arterial pressure (measured indirectly with the velocity of flow through the insufficient tricuspid valve), and other cardiac anomalies such as atrial septal defect and aortic coarctation.

Potential medical treatments are aimed at controlling the heart's left-to-right shunting caused by the VGAM. Nitric

oxide can aid with persistent pulmonary hypertension. Other pharmacologic agents include diuretics and beta agonists such as dopamine, inotropes, prostaglandins, or phosphodiesterase inhibitors.<sup>[8]</sup> No guidelines for medical treatment exist, as no clinical trials have been conducted to date. If the diagnosis is made antenatally, one study has suggested that dosing maternal digoxin may result in concurrent fetal dosing and possible treatment while in utero.<sup>[3]</sup>

Laboratory tests should evaluate liver and renal function, in addition to serving as secondary markers of cardiac and pulmonary status. Brain natriuretic protein levels act as a marker for cardiac injury due to pulmonary hypertension.<sup>[4]</sup> Serum tests for coagulopathy and ultrasound examinations of size assess liver function, while volume of urine output and blood urea nitrogen/serum creatinine levels aid in determining the systemic impact of the heart failure.

## TREATMENT

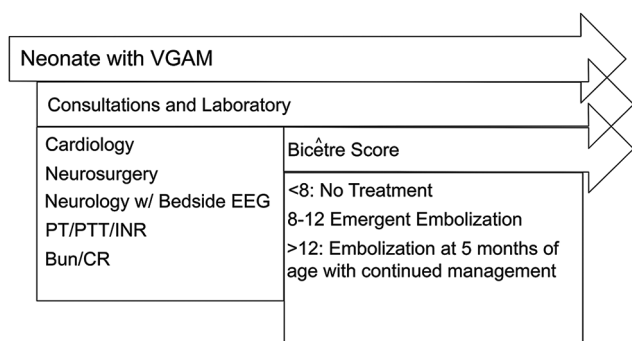
Treatment options for VGAMs have historically included either open surgery, a direct transtorcular approach to ligation, transarterial embolization, or transvenous embolization. Reports show nearly 100% mortality with open surgical approaches; transtorcular approaches have, likewise, not been successful; and transvenous approaches are reported to have poor cognitive outcomes.<sup>[11]</sup> Thus, their use has been relegated to second-line options, for use when a transarterial approach cannot be achieved.

Transarterial embolization, in a staged fashion, for partial occlusion of the VGAM is the only current treatment that has been shown to result in a safe reduction of cardiac failure. Access in neonates is often found through the umbilical artery. Protecting this route of access during birth and the acute postnatal period is important. This artery has the benefit of providing adequate access for the needed endovascular catheters, while sparing trauma

**Table 1: Bicêtre score**

Points	Cardiac function	Cerebral function	Respiratory function	Hepatic function	Renal function
5	Normal	Normal	Normal	-	-
4	Overload, no medical treatment	Subclinical, isolated EEG <sup>a</sup> abnormalities	Tachypnea finishes bottle	-	-
3	Failure, stable with medical treatment	Nonconvulsive intermittent neurologic signs	Tachypnea does not finish bottle	No hepatomegaly, normal hepatic function	Normal
2	Failure, not stable with medical treatment	Isolated convulsion	Assisted ventilation, normal saturation FiO <sub>2</sub> <sup>b</sup> <25%	Hepatomegaly, normal hepatic function	Transient anuria
1	Ventilation necessary	Seizures	Assisted ventilation, normal saturation FiO <sub>2</sub> >25%	Moderate or transient hepatic insufficiency	Unstable diuresis with treatment
0	Resistant to medical therapy	Permanent neurological signs	Assisted ventilation, desaturation	Abnormal coagulation, elevated enzymes	Anuria

<sup>a</sup>EEG: Electroencephalogram, <sup>b</sup>FiO<sub>2</sub>: Fractional inspired oxygen; Maximal score: 5 (cardiac) + 5 (cerebral) + 5 (respiratory) + 3 (hepatic) + 3 (renal)=21



**Figure 4: Treatment algorithm**

to the femoral artery in small neonates. It is essential to maintain the patency of this vessel and utilize other routes for serial blood work.<sup>[9]</sup>

Embolization aims to occlude, or partially occlude, the arterial side of the fistula. Currently, there are two primary materials used: (1) N-butyl-cyanoacrylate (NBCA) or (2) Onyx liquid, an ethylene vinyl alcohol copolymer that is delivered in dimethyl sulfoxide (DMSO) solvent. Once in contact with an ionic substance (blood), the DMSO quickly dissolves, leaving a firm spongy substance that rapidly occludes the vessel. It is admixed with tantalum powder to render it visible on fluoroscopy and computed tomography. This gives it a dark purple/black appearance *in vivo*. The use of Onyx has been largely described in the adult population, but there is a growing body of literature supporting its use as safe in pediatric patients when used by experienced practitioners.<sup>[2,23,24]</sup>

The extreme flow through the VGAM is a major concern during endovascular treatment. Injection of the embolic material is difficult to control at such high flow rates and can lead to the NBCA or Onyx passing through the fistula without successfully depositing in the VGAM. There are three general techniques to deal with this problem. First, coils can be placed distally in the arterial pedicle to catch the Onyx or NBCA.<sup>[18]</sup> Second, Onyx can be injected through a dual lumen balloon catheter, with the balloon inflated in the distal arterial pedicle to arrest flow, which allows the Onyx to form. However, Care must be taken to not dislodge the Onyx cast once the balloon is deflated. Despite this risk, the double-balloon technique has been shown to be an effective treatment option.<sup>[20]</sup> Finally, a mixture of 80–100% NBCA can be used so that it polymerizes immediately on contact with blood. However, it is more difficult to visualize fluoroscopically and can become glued to the catheter; the development of detachable catheter tips has helped to reduce this potential problem.

After treating the primary problem of the VGAM, there may still be associated hydrocephalus to be addressed. Diagnosis is made by a combination of anterior fontanelle evaluation, head circumference

measurements, and ultrasound assessment of ventricular caliber; more advanced imaging modalities may be used as well. The purported causes for the development of hydrocephalus in this setting include ineffective cerebrospinal fluid (CSF) reabsorption due to venous stenosis outside the VGAM, underdeveloped arachnoid granulations, and aqueductal obstruction resulting from the mass effect of the VGAM. Treatment should not precede control of the cardiac failure and VGAM.<sup>[3]</sup> CSF shunting in the setting of a persistent VGAM exacerbates the low vascular resistance and can lead to intracerebral hemorrhage or worsening of flow through the lesion.<sup>[13,21]</sup> Any considered interventions should be performed secondarily if needed.

## OUTCOMES

VGAM treated in neonates carries significant risks. The largest series from Lasjaunias at the Hospital Bicêtre determined that of the 216 patients treated with endovascular embolization, 23 (10.6%) died, 20 (10.5%) suffered severe intellectual disabilities, and 30 (15.6%) were moderately intellectually disabled. The remaining 143 (74%) were neurologically normal at follow-up.<sup>[16]</sup> Frawley *et al.* reported similar outcomes with nine patients with follow-up times from 6 months to 4 years.<sup>[6]</sup> Others have reported that congestive heart failure, perinatal presentation, and choroidal angioarchitecture showed the worst outcomes.<sup>[7]</sup> In another series of 13 patients with VGAM treated between 1987 and 2001, two of five patients with choroidal malformations died, and one had a significant impairment; three of seven children with mural lesions died, and four were neurologically normal after treatment.<sup>[14]</sup>

The management of VGAM is evolving, and the addition of transarterial embolization techniques is allowing increased treatment of these complex lesions with improving outcomes. Nevertheless, overall prognosis remains poor. Even with recent technological advances, a large population of patients remains untreatable or has poor long-term outcomes. Moving forward, there is a need for prospective studies, clinical registries, and ideally, a randomized controlled trial to determine the best medical and interventional treatments in these complex neonates.

At our institution, our collaborative multidisciplinary team follows the diagnostic and treatment algorithm outlined in Figure 4. For an infant with VGAM, neonatology, pediatric neurosurgery, pediatric neurology, neurointerventional endovascular, and pediatric cardiology services all combine to provide a tailored and individualized response to this challenging problem.

## Financial support and sponsorship

Nil.

## Conflicts of interest

There are no conflicts of interest.

## REFERENCES

- Alvarez H, Garcia Monaco R, Rodesch G, Sachet M, Krings T, Lasjaunias P. Vein of Galen aneurysmal malformations. *Neuroimaging Clin N Am* 2007;17:189-206.
- Ashour R, Aziz-Sultan MA, Soltanolkotabi M, Schoeneman SE, Alden TD, Hurley MC, et al. Safety and efficacy of Onyx embolization for pediatric cranial and spinal vascular lesions and tumors. *Neurosurgery* 2012;71:773-84.
- Berenstein A, Fifi JT, Niimi Y, Presti S, Ortiz R, Ghatan S, et al. Vein of Galen malformations in neonates: New management paradigms for improving outcomes. *Neurosurgery* 2012;70:1207-13.
- Chevret L, Durand P, Alvarez H, Lambert V, Caeymax L, Rodesch G, et al. Severe cardiac failure in newborns with VGAM. Prognosis significance of hemodynamic parameters in neonates presenting with severe heart failure owing to vein of Galen arteriovenous malformation. *Intensive Care Med* 2002;28:1126-30.
- Foran A, Donohue V, McParland P, Lynch B, Lasjaunias P, Rodesch G, et al. Vein of Galen aneurysmal malformation (VGAM): Closing the management loop. *Ir Med J* 2004;97:8-10.
- Frawley GP, Dargaville PA, Mitchell PJ, Tress BM, Loughnan P. Clinical course and medical management of neonates with severe cardiac failure related to vein of Galen malformation. *Arch Dis Child Fetal Neonatal Ed* 2002;87:F144-9.
- Fullerton HJ, Aminoff AR, Ferriero DM, Gupta N, Dowd CF. Neurodevelopmental outcome after endovascular treatment of vein of Galen malformations. *Neurology* 2003;61:1386-90.
- Gailloud P, O'riordan DP, Burger I, Lehmann CU. Confirmation of communication between deep venous drainage and the vein of Galen after treatment of a vein of Galen aneurysmal malformation in an infant presenting with severe pulmonary hypertension. *AJNR Am J Neuroradiol* 2006;27:317-20.
- Gailloud P, O'riordan DP, Burger I, Levrier O, Jallo G, Tamargo RJ, et al. Diagnosis and management of vein of Galen aneurysmal malformations. *J Perinatol* 2005;25:542-51.
- Gold A, Ransohoff J, Carter S. Vein of Galen malformation. *Acta Neurol Scand Suppl* 1964;40 Suppl 11:S1-31.
- Gupta AK, Varma DR. Vein of Galen malformations: Review. *Neurol India* 2004;52:43-53.
- Iizuka Y, Kakihara T, Suzuki M, Komura S, Azusawa H. Endovascular remodeling technique for vein of Galen aneurysmal malformations – Angiographic confirmation of a connection between the median prosencephalic vein and the deep venous system. *J Neurosurg Pediatr* 2008;1:75-8.
- Jea A, Bradshaw TJ, Whitehead WE, Curry DJ, Dauser RC, Luerssen TG. The high risks of ventriculoperitoneal shunt procedures for hydrocephalus associated with vein of Galen malformations in childhood: Case report and literature review. *Pediatr Neurosurg* 2010;46:141-5.
- Jones BV, Ball WS, Tomsick TA, Millard J, Crone KR. Vein of Galen aneurysmal malformation: Diagnosis and treatment of 13 children with extended clinical follow-up. *AJNR Am J Neuroradiol* 2002;23:1717-24.
- Khullar D, Andeejani AM, Bulsara KR. Evolution of treatment options for vein of Galen malformations. *J Neurosurg Pediatr* 2010;6:444-51.
- Lasjaunias PL, Chng SM, Sachet M, Alvarez H, Rodesch G, Garcia-Monaco R. The management of vein of Galen aneurysmal malformations. *Neurosurgery* 2006;59 5 Suppl 3:S184-94.
- Li AH, Armstrong D, terBrugge KG. Endovascular treatment of vein of Galen aneurysmal malformation: Management strategy and 21-year experience in Toronto. *J Neurosurg Pediatr* 2011;7:3-10.
- Li MH, Li WB, Fang C, Gao BL. Transarterial embolization with berenstein liquid coils and N-butyl cyanoacrylate in a vein of Galen aneurysmal malformation: A case report. *Korean J Radiol* 2007;8:164-8.
- Malhotra RK, Florez L, White D, Papasozomenos S, Covinsky M, Bhattacharjee M. Vein of Galen aneurysmal malformation associated with high output cardiac failure in three neonates. *J Neuropathol Exp Neurol* 2007;66:438.
- Pop R, Manisor M, Wolff V, Kehrl P, Marescaux C, Beaujeux R. Flow control using Scepter™ balloons for Onyx embolization of a vein of Galen aneurysmal malformation. *Childs Nerv Syst* 2015;31:135-40.
- Schneider SJ, Wisoff JS, Epstein FJ. Complications of ventriculoperitoneal shunt procedures or hydrocephalus associated with vein of Galen malformations in childhood. *Neurosurgery* 1992;30:706-8.
- Stephan S, Rodesch G, Eloff E, Wiemann D, Jorch G. Vein of Galen aneurysmal malformations: An ultrasonographic incidental finding – A case report. *Case Rep Pediatr* 2012;2012:824284.
- Thiex R, Williams A, Smith E, Scott RM, Orbach DB. The use of Onyx for embolization of central nervous system arteriovenous lesions in pediatric patients. *AJNR Am J Neuroradiol* 2010;31:112-20.
- Zaidi HA, Kalani MY, Spetzler RF, McDougall CG, Albuquerque FC. Multimodal treatment strategies for complex pediatric cerebral arteriovenous fistulas: Contemporary case series at Barrow Neurological Institute. *J Neurosurg Pediatr* 2015;15:615-24.