

# A Close Look at the Clinical Efficacy of Rho-Associated Protein Kinase Inhibitor Eye Drops for Fuchs Endothelial Corneal Dystrophy

Shigeru Kinoshita, MD, PhD,\* Kathryn A. Colby, MD, PhD,† and Friedrich E. Kruse, MD, PhD‡

**Abstract:** The current understanding on the clinical efficacy of Rho-associated protein kinase (ROCK) inhibitor for treating Fuchs endothelial corneal dystrophy is summarized to clarify whether the “off-label” ROCK-inhibitor eye-drop application are appropriate. ROCK-inhibitor eye drops may eventually be deemed a cutting-edge therapy for Fuchs endothelial corneal dystrophy patients with acute corneal endothelial defect.

**Key Words:** corneal endothelium, Rho-associated protein kinase inhibitor, Fuchs endothelial corneal dystrophy

(*Cornea* 2021;40:1225–1228)

Fuchs endothelial corneal dystrophy (FECD), the leading cause of corneal endothelial dysfunction, is a complex, age-related genetic disorder and the most common indication for corneal transplantation in industrialized nations. FECD is characterized by the accumulation of extracellular collagenous deposits that form mound-shaped aggregates, called “guttae,” which ultimately leads to severe visual impairment because of consistent gradual loss of corneal endothelial cells (CECs). Recent investigations have provided key insights into the underlying molecular pathophys-

iological mechanisms involving cell apoptosis, RNA toxicity, endoplasmic reticulum stress, and unfolded protein response and epithelial–mesenchymal transition and mitochondrial dysfunction. In addition, the findings in recent studies have revealed the increased susceptibility of endothelial cells to oxidative stress, which is believed to be a central contribution to the pathogenesis of FECD through increased DNA damage and CEC apoptosis. Despite these substantial advancements that help provide a deeper understanding of FECD, there are currently no standardized or governmental-approved pharmacological treatments for patients afflicted with the disease.

The findings in a few recent studies have shown that several pharmaceutical agents, such as antioxidants, mammalian target of rapamycin inhibitors, and Rho-associated protein kinase (ROCK) inhibitors, produce potentially beneficial effects on CECs. Of those, some low-molecular-weight ROCK inhibitor compounds have now received governmental approval in a few countries for both topical and systemic use for the treatment of other diseases after clinical trial–based regulatory assurance of the safety and efficacy of the compounds. For example, fasudil hydrochloride hydrate (Fasudil; Asahi Kasei Pharma Corporation, Tokyo, Japan/Woolsey Pharmaceuticals Corporation, New York, NY), a ROCK inhibitor, has long been on the market as a pharmaceutical treatment for cerebrovascular disorders, and other ROCK inhibitors, such as K-115 (ripasudil hydrochloride hydrate), AR-13324 (netarsudil mesylate), and Y-27632, have now attracted significant attention in the field of ophthalmology, primarily because of their ability to lower intraocular pressure in glaucoma patients.<sup>1,2</sup>

Because of the immense growing interest worldwide, ROCK inhibitor compounds such as ripasudil hydrochloride hydrate ophthalmic solution 0.4% (GLANATEC; Kowa Co, Ltd, Nagoya, Japan), which is currently approved for use in Japan, and netarsudil ophthalmic solution 0.02% (Rhopressa; Aerie Pharmaceuticals, Inc, Durham, NC), which is currently approved for use in the United States and a few other countries, have now gained wide acceptance as effective antiglaucoma agents, with Rhopressa also reportedly showing beneficial effects on the survival of retinal ganglion cells and optic nerve axon regeneration.<sup>3</sup> Moreover, the findings in some reports seem to indicate the beneficial effects of ROCK inhibitor Y-27632 on corneal restoration in cases of corneal endothelial damage, including those afflicted with FECD.<sup>4</sup>

Received for publication August 28, 2020; revision received October 27, 2020; accepted November 9, 2020. Published online ahead of print February 3, 2021.

From the \*Department of Frontier Medical Science and Technology for Ophthalmology, Kyoto Prefectural University of Medicine, Kyoto, Japan; †Department of Ophthalmology, New York University (NYU), New York, NY; and ‡Department for Ophthalmology, Friedrich-Alexander-University of Erlangen-Nürnberg, Erlangen, Germany.

The authors have no funding or conflicts of interest to disclose.

S. Kinoshita, K. A. Colby, and F. E. Kruse contributed equally to this article. Conception and design of the study (S. Kinoshita, K. A. Colby, F. E. Kruse), writing of the article (S. Kinoshita, K. A. Colby, F. E. Kruse), approval of the manuscript (S. Kinoshita, K. A. Colby, F. E. Kruse), obtaining of funding (S. Kinoshita, K. A. Colby, F. E. Kruse), searching the literature (S. Kinoshita, K. A. Colby, F. E. Kruse).

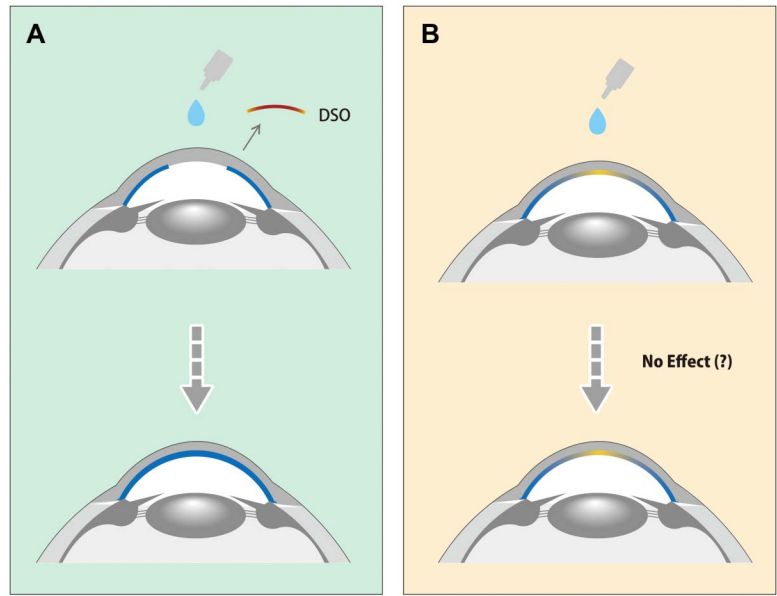
Correspondence: Shigeru Kinoshita, MD, PhD, Department of Frontier Medical Science and Technology for Ophthalmology, Kyoto Prefectural University of Medicine, 465 Kajii-cho, Hirokoji-agaru, Kawaramachidori, Kamigyo-ku, Kyoto 602-0841, Japan (e-mail: fmstoph@koto.kpu-m.ac.jp).

Copyright © 2021 The Author(s). Published by Wolters Kluwer Health, Inc. This is an open-access article distributed under the terms of the Creative Commons Attribution-Non Commercial-No Derivatives License 4.0 (CCBY-NC-ND), where it is permissible to download and share the work provided it is properly cited. The work cannot be changed in any way or used commercially without permission from the journal.

## WHAT IS KNOWN, AND WHAT IS NOT KNOWN

Studies have shown that ROCK inhibitor Y-27632 promotes cell adhesion, cell proliferation, and antiapoptotic

**FIGURE 1.** Cross-section diagrams of the cornea illustrating 2 clinical situations of FECD in which the topical application of ROCK inhibitor eye drops is used. A, Cross-section diagram illustrating a cornea post-DSO (upper panel). Note that the interrupted convex blue lines indicate the residual CEC layer postremoval of the diseased FECD endothelium including Descemet membrane with guttae (red line), whereas the peripheral CECs are still relatively normal. The topical administration of ROCK inhibitor eye drops might possibly enhance the CEC layer wound-healing process by promoting the proliferation and migration of healthy CECs surrounding the corneal defect (lower panel). This situation is somewhat similar to that seen in cases of acute CECs injury postcataract surgery, etc. B, Diagram illustrating a case of early- to moderate-stage FECD without surgical intervention. Note that the noninterrupted convex yellow lines at the center in both the upper and lower diagrams indicate the CEC layer with Descemet membrane and guttae, whereas the convex blue lines at the periphery in the diagrams indicate the CEC layer with Descemet membrane, yet without guttae. In such early- to moderate-stage cases of FECD with corneal guttae and a low CEC density, the topical administration of ROCK inhibitor eye drops might not be effective for improving the status of the CEC layer. (The full color version of this figure is available at [www.corneajrnl.com](http://www.corneajrnl.com).)

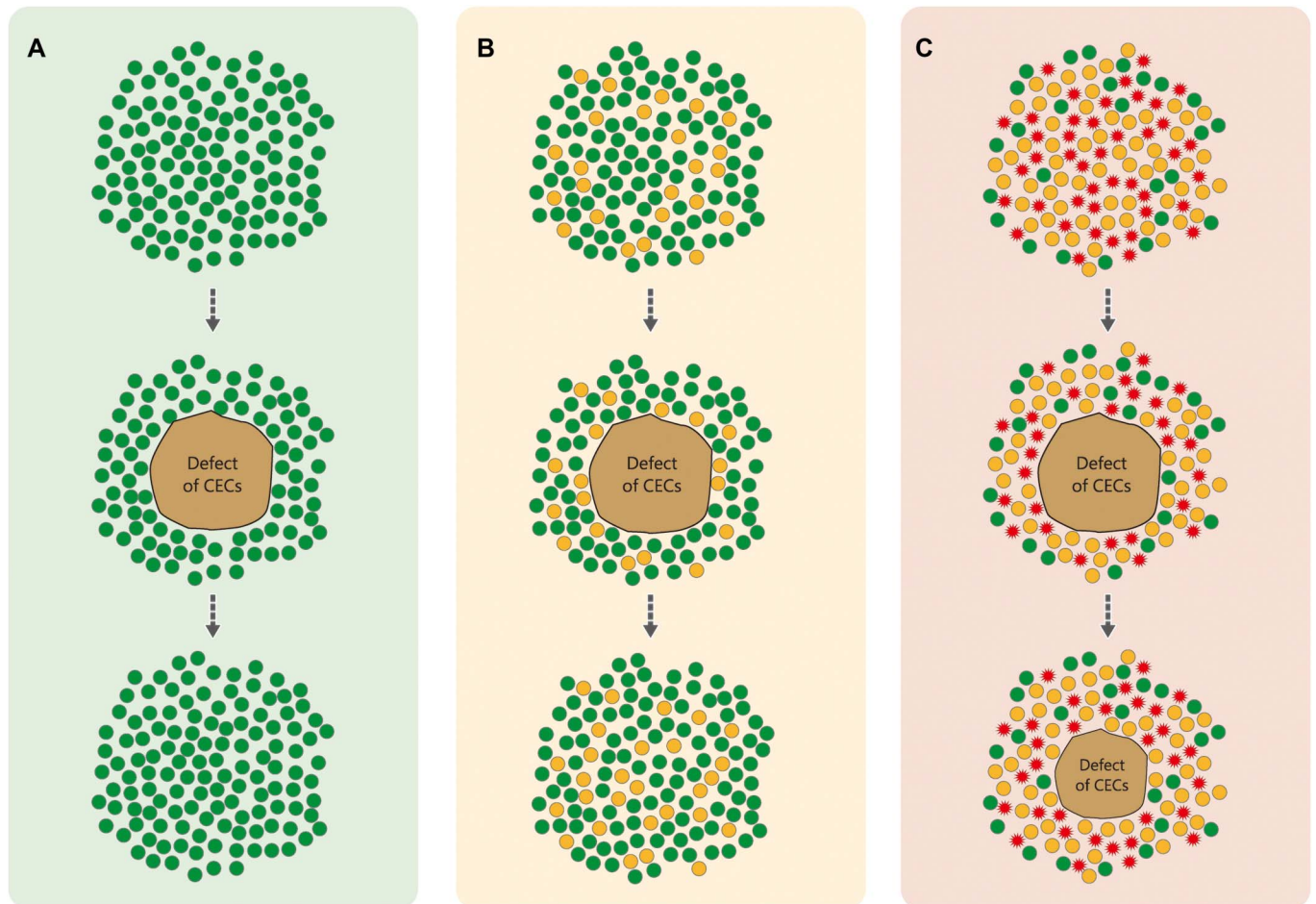


effects in cultured monkey and human CECs.<sup>5,6</sup> Furthermore, the CEC layer can now be consistently reconstructed using regenerative medicine, that is, the administration of cultured human CECs combined with ROCK inhibitor Y-27632 into the anterior chamber for the treatment of patients afflicted with bullous keratopathy.<sup>7</sup> Thus, there is now a substantial amount of conceptual evidence to support the effectiveness of using ROCK inhibitors for the treatment of specific corneal endothelial diseases and for patients afflicted with CEC injury and loss. However, and in comparison, the amount of definitive scientific evidence on the clinical efficacy of ROCK inhibitor eye drops remains somewhat thin.

Alongside this emergent and exciting backdrop, it has now been shown that the topical administration of ROCK inhibitor eye drops is effective for the recovery of corneal transparency posttranscorneal freezing to create a small corneal-endothelium defect at the guttae area in cases of early-stage FECD.<sup>4</sup> In brief, the underlying idea of this procedure is to release the contact inhibition of *in vivo* CECs by CECs removal, including abnormally differentiated or very large-sized cells, which can induce the proliferation and migration of relatively healthy CECs to surround the corneal endothelial defect area through the ROCK inhibitor's biological effects. A similar idea was pursued for the treatment of early- to middle-stage FECD using a surgical procedure known as Descemet-stripping only (DSO)<sup>8</sup> or DSO in combination with topical ROCK inhibitor administration (Fig. 1A). Based on what is currently known, the success or failure of DSO-type treatments probably depends on the biological healthiness of the untouched corneal endothelium surrounding the defect, with the addition of the ROCK inhibitor possibly accelerating

the migration and proliferation of not only the healthy CECs but also the cell-state transition-type CECs that surround the defect area (Fig. 2). In this study, cell-state transition-type CECs are characterized as cells that transition into a senescence phenotype, epithelial-mesenchymal transition, and fibroblastic cell morphology. However, the exact behavior of the CECs in such cases requires further detailed investigation. At present, because the findings in a few single-center clinical studies have shown that the administration of ROCK inhibitor eye drops after DSO in FECD cases results in a successful early recovery of corneal restoration,<sup>9,10</sup> it can be surmised that the application of ROCK inhibitor eye drops after DSO in FECD and the treatment of acute CEC injury produces beneficial effects.

Currently, there is an ongoing debate as to the proper daily frequency and number of ROCK inhibitor eye drop instillations after DSO: that is, twice daily, 3 times daily, or 4 times daily. To that regard, specular microscopy examinations have shown that, in normal subjects, the effect of a single topical instillation of ripasudil hydrochloride hydrate ophthalmic solution 0.4% on the cornea lasts approximately 6 hours based on the morphological alteration of the CECs.<sup>11</sup> The long-term use of that same drug in glaucoma patients has also been confirmed to produce a similar phenomenon for up to 6 hours. However, the duration of the biological effects needs to be estimated in a logical manner and based on its pharmacokinetics in the cornea and aqueous humor after the topical application of the drug. Hence, the efficacy of using these drugs as “off-label” medications is a somewhat minor yet important question that remains to be answered. In addition, there seems to be a general misunderstanding as to the clinical efficacy of using ROCK inhibitor eye drops in FECD cases with corneal guttae-related loss of CEC density. It should be noted



**FIGURE 2.** Conceptual schemas illustrating the various statuses of in vivo CECs and CECs after DSO in a time-dependent manner, with the addition of ROCK inhibitor eye drops. A, Corneal endothelial wound healing by the migration of healthy CECs. B, Mild-stage FECD. C, Moderate-stage FECD. The solid green circles, solid yellow circles, and solid red expanding circles signify healthy CECs, mild cell-state transition (CST) FECD CECs, and advanced CST FECD CECs, respectively. The solid brown areas signify the CEC defect/DSO regions. Situation A: The healthy CECs (top group) surround the CEC defect region immediately after DSO (middle group) and then migrate into the defect area with some CEC proliferation, ultimately resulting in complete endothelial closure with reasonable CEC function (bottom group). This situation closely mimics that observed in cases of acute CEC injury after cataract surgery. Situation B: Immediately after DSO, both healthy and CST CECs (top group) surround the CEC defect region (middle group), gradually healing the defect site by the purported beneficial effects of the topically applied ROCK inhibitor eye drops on the healthy and CST CECs (bottom group). As shown in the bottom group, it is surmised that the complete closure of the corneal endothelial defect site is accomplished in most cases. Situation C: An abundant amount of mild and advanced CST CECs intermixed with the small amount of healthy CECs (top group) immediately surround the CEC defect region after DSO (middle group). However, the wound-healing process might falter due to improper migration of the malfunctioning CST CECs even in the presence of ROCK inhibitor eye drops. Thus, the process of corneal endothelial wound healing after DSO probably depends on the biological characteristics of the CECs that surround the CEC defect region after surgery. The current presumption is that ROCK inhibitor eye drops beneficially modify the biological characteristics of CECs. (The full color version of this figure is available at [www.corneajrnl.com](http://www.corneajrnl.com).)

that, in such cases, it remains unclear as to whether or not ROCK inhibitors are clinically effective. Moreover, it has yet to be scientifically shown that the administration of ROCK inhibitor eye drops has any beneficial effect in cases where the CEC layer is not disrupted (Fig. 1B). Hence, this raises the simple question of whether or not the effect of the ROCK inhibitor is sufficiently exerted in the presence of cell-to-cell contact inhibition, that is, in the presence of a strong inhibitory environment on CEC migration and/or proliferation by the expression of connexin 43,<sup>12</sup> etc.

With that aside, it should be noted that FECD is characterized by a specific change in the expression patterns of matrix proteins, which results in an altered composition and guttae formation on Descemet membrane that might be induced by increased stress conditions or increased levels of the profibrotic growth factors, such as transforming growth factor  $\beta$ . Thus, current investigations aimed at a nonsurgical treatment of FECD should focus on modifying the production of the pathological matrix. Preliminary studies have provided evidence that the “ROCK signaling pathway” is involved in these abnormal matrix

processes and the profibrotic reactions of endothelial cells in response to stress or growth factors. There currently is scientific evidence showing that when ROCK inhibitors are supplemented into culture media, they help to suppress the abnormal extracellular matrix secretion by the cultured human CECs, which seems to imply that they suppress the development of abnormal deposits on Descemet membrane, that is, namely the formation of corneal guttae (Kruse et al. ARVO 2019 Abstract, *Invest Ophthalmol Vis Sci.* 2019;60(9):2172).

### FUTURE STUDIES AND DIRECTIONS

To fully elucidate the clinical safety and efficacy of ROCK inhibitor eye drops for the treatment of FECD, it must be approached by differentiating the problem into at least 2 situations: the first being restoration of the acutely damaged corneal endothelium, possibly immediately after cataract surgery and DSO in early-stage FECD cases, and the second being preservation of the deteriorating CEC layer in chronic cases (Fig. 1). To that end, because no multicenter clinical trials have been performed, a clinical trial is currently being planned to obtain a valid proof of concept to establish “level 1” clinical evidence for ROCK inhibitor eye drops in patients with FECD after DSO. In the future, if a beneficial effect of ROCK inhibitor eye drop instillation post-DSO becomes widely acknowledged, then it might become standardized for use in all DSO and corneal transplantation cases in the early postoperative period because some corneal endothelial defects usually develop immediately after penetrating keratoplasty, corneal endothelial transplantation, and cultured human CEC-injection therapy.<sup>7</sup> Moreover, ROCK inhibitor eye drop instillation might ultimately also prove effective for the treatment of corneal endothelial damage in the initial phase after intraocular surgery, including cataract surgery, glaucoma surgery, etc.

### CURRENT SPECIFIC CLINICAL RECOMMENDATION

In summary, and depending on the results of future clinical trials, it seems that the topical instillation of ROCK inhibitor eye drops will remain as a benchmark cutting-edge clinical therapy for patients after DSO or specialized treat-

ments for acute-stage corneal endothelial injury. However, it still seems wise to wait for evidential level 1 findings to emerge before using off-label ROCK inhibitor eye drops for the treatment of FECD before surgical indications.

### ACKNOWLEDGMENTS

*The authors thank John Bush for his excellent review of the manuscript.*

### REFERENCES

1. Tanihara H, Inoue T, Yamamoto T, et al. Additive intraocular pressure-lowering effects of the rho kinase inhibitor ripasudil (K-115) combined with timolol or latanoprost: a report of 2 randomized clinical trials. *JAMA Ophthalmol.* 2015;133:755–761.
2. Koczymanski CC, Epstein DL. Emerging trabecular outflow drugs. *J Ocul Pharmacol Ther.* 2014;30:85–87.
3. Shaw PX, Sang A, Wang Y, et al. Topical administration of a Rock/Net inhibitor promotes retinal ganglion cell survival and axon regeneration after optic nerve injury. *Exp Eye Res.* 2017;158:33–42.
4. Okumura N, Koizumi N, Kay EP, et al. The ROCK inhibitor eye drop accelerates corneal endothelium wound healing. *Invest Ophthalmol Vis Sci.* 2013;54:2493–2502.
5. Okumura N, Ueno M, Koizumi N, et al. A ROCK inhibitor enhances survival of primate corneal endothelial cells in vitro. *Invest Ophthalmol Vis Sci.* 2009;50:3680–3687.
6. Toda M, Ueno M, Hiraga A, et al. Production of homogeneous cultured human corneal endothelial cells indispensable for innovative cell therapy. *Invest Ophthalmol Vis Sci.* 2017;58:2011–2020.
7. Kinoshita S, Koizumi N, Ueno M, et al. Injection of cultured cells with a ROCK inhibitor for bullous keratopathy. *N Engl J Med.* 2018;378:995–1003.
8. Borkar DS, Veldman P, Colby KA. Treatment of Fuchs endothelial dystrophy by Descemet stripping without endothelial keratoplasty. *Cornea.* 2016;35:1267–1273.
9. Moloney G, Petsoglou C, Ball M, et al. Descemetorhexis without grafting for Fuchs endothelial dystrophy-supplementation with topical ripasudil. *Cornea.* 2017;36:642–648.
10. Macsai MS, Shiloach M. Use of topical rho kinase inhibitors in the treatment of Fuchs dystrophy after Descemet stripping only. *Cornea.* 2019;38:529–534.
11. Nakagawa H, Koizumi N, Okumura N. Morphological changes of human corneal endothelial cells after rho-associated kinase inhibitor eye drop (ripasudil) administration: a prospective open-label clinical study. *PLoS One.* 2015;10:e0136802.
12. Nakano Y, Oyamada M, Dai P, et al. Connexin43 knockdown accelerates wound healing but inhibits mesenchymal transition after corneal endothelial injury in vivo. *Invest Ophthalmol Vis Sci.* 2008;49:93–104.