

# Salvage of a DIEP Flap after Injury to the Inferior Epigastric Vessels after Laparoscopic Surgery

Laura H.J. Solberg, MD\*  
 Anouk J.M. Cornelissen, MD, PhD\*  
 Cas van Cruchten, MD†  
 Shan Shan Qiu, MD, PhD\*

**Summary:** The problem of previous laparoscopic scars specifically endangering the DIEP flap harvest for breast reconstruction has not been described yet. Even though in our center, preoperative imaging by means of a magnetic resonance angiography (MRA) is routinely performed before a bilateral DIEP-flap reconstruction, it may not correspond with the intraoperative findings. This case was presented to increase awareness among plastic surgeons about the complications after laparoscopic surgery and to emphasize the importance of thorough history taking when performing a DIEP flap breast reconstruction after previous laparoscopic procedures. (*Plast Reconstr Surg Glob Open* 2022;10:e4169; doi: [10.1097/GOX.0000000000004169](https://doi.org/10.1097/GOX.0000000000004169); Published online 18 March 2022.)

An increasing number of women desire an autologous breast reconstruction. The quality of life after mastectomy keeps gaining importance. The two main reasons for this are a higher survival rate after breast cancer and a higher number of preventive mastectomies.

The first choice in donor site selection remains the abdomen: the deep inferior epigastric perforator (DIEP) flap. This flap has numerous advantages such as a long pedicle, relatively easy dissection, and supine position.

Simultaneously with the growth of popularity of the DIEP-flap breast reconstruction, the use of laparoscopic surgery gained acceptance. The widespread introduction of laparoscopic surgery in the field of general surgery only began after development of a multiple use laparoscopic clip applicator. This made laparoscopic gallbladder removal, appendectomy, and gynecological malignancy treatment more accessible. Taking this into consideration, many experienced microsurgeons may not have encountered much of laparoscopic surgery during their residency. Thus, they might not be familiar with the common complications of laparoscopic surgery. Nevertheless, these complications can have substantial consequences for the vascularization of the abdominal wall. Accidental injury of the abdominal wall vessels occurs in 0.2%–2% of

laparoscopic cases.<sup>1</sup> Even more importantly, the epigastric vessels are by far the most injured. This type of injury can result in external oozing around the port site or internal dripping into the abdominal cavity. However, the injury can easily remain unrecognized due to temporary tamponade by the cannula and pneumo-peritoneum, and can present as a hematoma or pseudoaneurysm afterward. Consequently, this case report is a contribution to the field of plastic surgery, illustrating complications after laparoscopic surgery (harmed epigastric vessels) and a way to salvage the flap; it is essential to be aware of them before planning a DIEP flap.

## CASE REPORT

### Preoperative

A 55-year old woman with a medical history of a cesarean section and a laparoscopic extirpation of the adnexa, presented at the outpatient clinic of plastic surgery. She has a BRCA-1 genetic mutation and opted for a preventive bilateral mastectomy with direct autologous reconstruction using abdominal tissue. A preoperative abdominal magnetic resonance angiography (MRA) concluded that the most eligible perforators of the inferior epigastric artery (IEA) were 1.3 cm lateral to the umbilicus on the right side and 3.2 cm lateral to the umbilicus on the left side. No remarks were mentioned on this MRA by the radiologist nor were they noticed by the operating plastic surgeon.

### Intraoperative

The harvest of the DIEP flap on the right side went uneventfully. On the left side, substantial adhesions and scar tissue were noticed surrounding the vascular pedicle. This resulted in vasoconstriction of the IEA

From the \*Department of Plastic Surgery, Maastricht University Medical Centre, Maastricht, the Netherlands; and †Department of General Surgery, Zuyderland Medical Centre, Sittard-Geleen, the Netherlands.

Received for publication November 2, 2020; accepted January 6, 2022.

Copyright © 2022 The Authors. Published by Wolters Kluwer Health, Inc. on behalf of The American Society of Plastic Surgeons. This is an open-access article distributed under the terms of the [Creative Commons Attribution-Non Commercial-No Derivatives License 4.0 \(CCBY-NC-ND\)](https://creativecommons.org/licenses/by-nc-nd/4.0/), where it is permissible to download and share the work provided it is properly cited. The work cannot be changed in any way or used commercially without permission from the journal.

DOI: [10.1097/GOX.0000000000004169](https://doi.org/10.1097/GOX.0000000000004169)

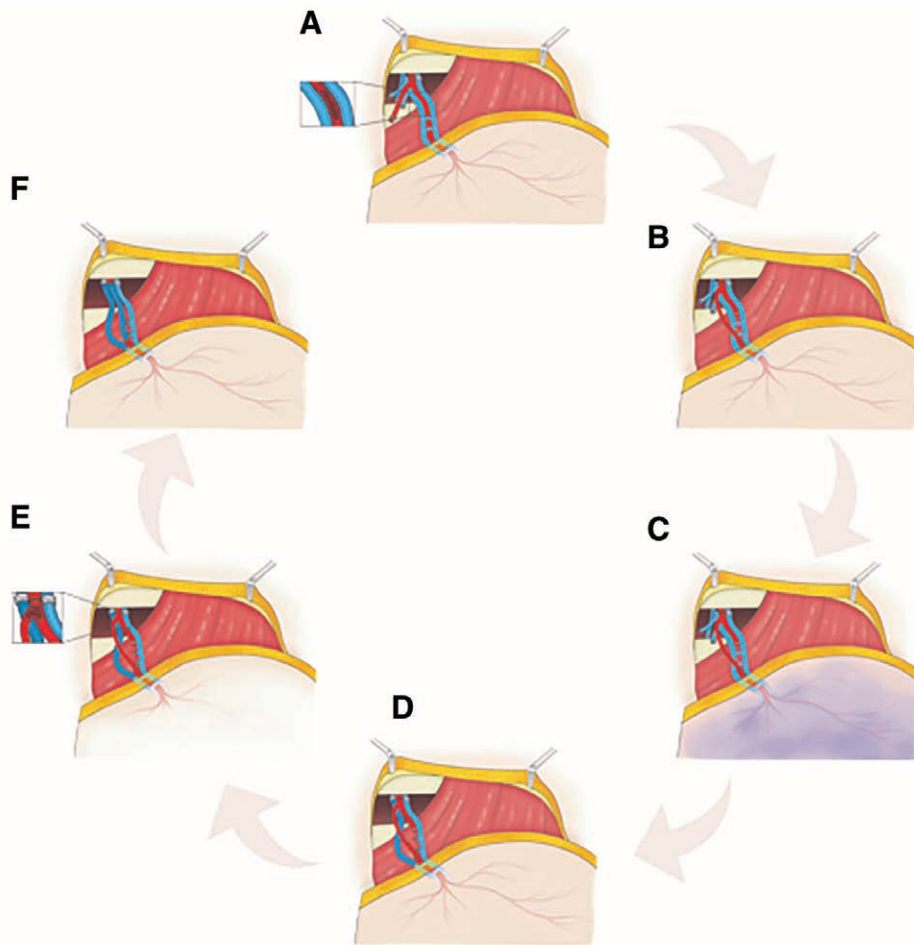
**Disclosure:** The authors have no financial interest to declare in relation to the content of this article.

during dissection. Eventually, the pulsations were no longer visible and a signal of the hand-held Doppler was lacking. The dissection was nevertheless continued until Hesselbach's triangle,<sup>2</sup> whereupon no flow was present in the left DIEP flap. This flap was transferred immediately to the thorax for anastomosis with the internal mammary vessels to minimize the ischemia time. A coupler 2.5 was used for the venous anastomosis. Before performing the arterial anastomosis, the artery of the flap was flushed with heparin solution. During this process, a long fibrinous structure was seen inside the lumen and removed. The intima layer of the artery seemed to be damaged (Fig. 1). Nevertheless, the procedure was continued and the arterial anastomosis was performed. Unfortunately there was no arterial inflow in the flap after anastomosis. The only pulsation visible

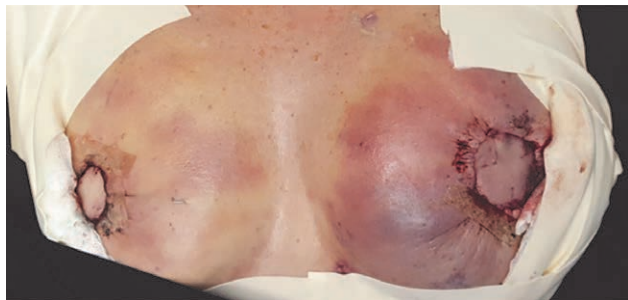
was present in a large branch of the artery, distal to the anastomosis. A new anastomosis was performed between the distal end of the arterial branch and the perforator, 2 cm before entering the flap tissue (Fig. 1). Pulsations of the pedicle became visible again, and a vital skin color with a Doppler signal was noted.

**Postoperative**

One day postoperatively, signs of venous congestion of the left flap were seen. During surgical exploration, a second concomitant vein of the inferior epigastric vein was anastomosed to the second concomitant internal mammary vein using a vein graft to bypass the damaged area of the pedicle (Figs. 1, 2). Vein grafts were harvested from the right foot. The flap was vital after this procedure.



**Fig. 1.** Explanation of the salvage procedures of the DIEP flap. A, DIEP flap after finishing the anastomosis to the internal mammary artery and vein. No pulsation was observed due to the presence of an arterial thrombus in the perforator. B, To bypass the thrombus, a new anastomosis between a proximal branch of the pedicle and the distal stump of the perforator was created, after which pulsations were immediately present. C, A congested DIEP flap was seen 24 hours after surgery. D, A second vein graft was harvested, to bypass the damaged area of the pedicle's vein. E, Ischemic flap at day 4 after surgery was observed. Intraoperative, an arterial thrombus was found in the proximal branch of the pedicle. F, A vein graft was used to bypass the damaged part of the artery and connect directly the internal mammary artery with the distal stump of the perforator. Normal flow was observed after this procedure.



**Fig. 2.** Venous congestion at postoperative day 1.

Four days postoperatively, a pale flap with absence of a Doppler signal was reported. Re-exploration revealed thrombosis of the side branch of the IEA. Another vein graft was harvested from the right foot and was used to connect the internal mammary artery to the perforator, replacing the previously used side branch (Fig. 1).

The patient was discharged in good clinical condition after 14 days (Fig. 3). Six weeks postoperatively, a satisfactory result was seen (Fig. 4). As usual, extra surgeries might be needed to accomplish symmetry in volume and form after several months.

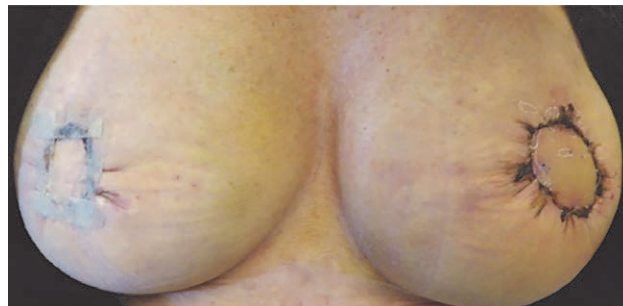
Only after the first operation in which the peculiar scar tissue around the left pedicle was encountered, which was not noticed on the MRA and for which we did not have a clear explanation, a thorough history was taken from the patient. This revealed that she presented with severe bleeding from one of the trocar wounds shortly after the laparoscopic extirpation of the adnexa. This laparoscopic procedure took place 2 years before the bilateral breast reconstruction.

### DISCUSSION

Although, vessel damage may be rare (0.2%–2%) after laparoscopy, awareness of this complication is substantial, as it may facilitate unexpected situations.<sup>3</sup> Problems specifically encountered during DIEP flap harvest after laparoscopic surgery have not been mentioned in the literature. However, other abdominal scars, such as from a Pfannenstiel or McBurney incisions, were frequently reported.<sup>3</sup>

This case illustrates that the epigastric vessels following laparoscopic surgery can be severely damaged without any sign on the MRA. The introduction of trocars for laparoscopic surgery could lead to injury of the blood vessels of the anterior abdominal wall, specifically to the IEA.<sup>4</sup> According to Rao et al, this percentage may be higher in case of anatomical variations of the epigastric vessels.<sup>5</sup> To avoid potential injury to the inferior epigastric vessels, both Hurd et al and Balzer et al<sup>6,7</sup> recommended the introduction of trocars in a “safety zone.”

Many reasons may explain why the laparoscopic procedure is the most likely culprit of the damage to the vessels and scar tissue. First of all, the scar tissue encountered during the harvesting of the IE vascular pedicle was located close to the skin island: 2–3 cm proximal to the rectus abdominis fascia. The location was high for it to be



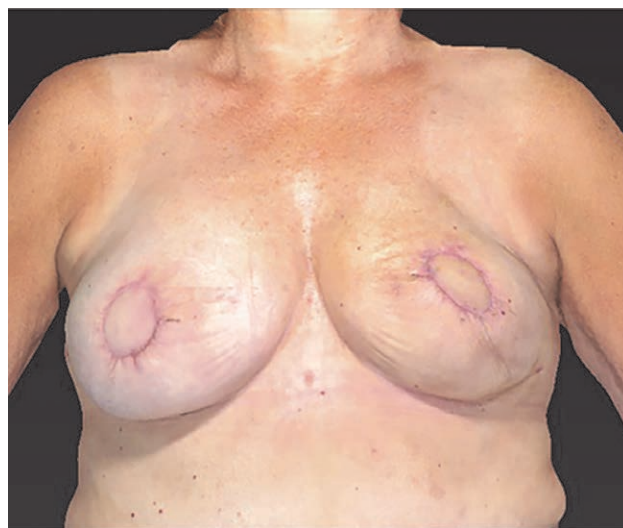**Fig. 3.** Result at 2 weeks postoperative.

attributed to the pfannenstiel scar. Secondly, the requirement of reoperation due to hematoma after the previous laparoscopic procedure might suggest that vessel damage had occurred. Lastly, in retrospect, the scar tissue was seen on the abdominal MRA 2–3 cm below the umbilicus level, and the pfannenstiel scar could be located lower on the same scan.

Although preoperative imaging by means of an MRA can show adequate flow, in our case report we found that this might not be a guarantee of intact vessels. Hence, a more thorough history regarding previous abdominal laparoscopic surgery might be even more valuable in predicting potential problems than the preoperative imaging workup used for breast reconstruction. Proper knowledge and patient counseling may help the surgeon to deal with unexpected events, and the patient to overcome undesired events in case of previously damaged vessels.

### CONCLUSIONS

Although damage of epigastric vessels after laparoscopic procedures is rare, detailed information regarding previous abdominal incisions might prevent intraoperative surprises. The use of vein grafts for salvage procedure has resulted in a successful procedure in this case.



**Fig. 4.** Result at 6 weeks postoperative.

**Shan Shan Qiu, MD, PhD**  
 Maastricht University Medical Centre  
 Department of Plastic Surgery  
 P. Debyelaan 25  
 6229 HX  
 Maastricht, the Netherlands  
 E-mail: shanshan.qiushao@mumc.nl

#### REFERENCES

1. Saber AA, Meslemani AM, Davis R, et al. Safety zones for anterior abdominal wall entry during laparoscopy: a CT scan mapping of epigastric vessels. *Ann Surg.* 2004;239:182–185.
2. Bou Antoun M, Reboul G, Ronot M, et al. Imaging of inguinal-related groin pain in athletes. *Br J Radiol.* 2018;91:20170856.
3. Hamdi M, Larsen M, Craggs B, et al. Harvesting free abdominal perforator flaps in the presence of previous upper abdominal scars. *J Plast Reconstr Aesthet Surg.* 2014;67:219–225.
4. Laporta R, Longo B, Sorotos M, et al. Tips and tricks for DIEP flap breast reconstruction in patients with previous abdominal scar. *Microsurgery.* 2017;37:282–292.
5. Rao MP, Swamy V, Arole V, et al. Study of the course of inferior epigastric artery with reference to laparoscopic portal. *J Minim Access Surg.* 2013;9:154–158.
6. Hurd WW, Pearl ML, DeLancey JO, et al. Laparoscopic injury of abdominal wall blood vessels: a report of three cases. *Obstet Gynecol.* 1993;82(4 pt 2 suppl):673–676.
7. Balzer KM, Witte H, Recknagel S, et al. Anatomic guidelines for the prevention of abdominal wall hematoma induced by trocar placement. *Surg Radiol Anat.* 1999;21:87–89.