

Pars plana insertion of glaucoma shunt in eyes with refractory neovascular glaucoma

Case report

Chu-Yu Yen, MD, Gow-Lieng Tseng, MD, PhD*

Abstract

Rationale: Neovascular glaucoma (NVG) is one of the most aggressive types of glaucoma in clinical practice. The outcomes are unsatisfactory despite the successful trabeculectomy with glaucoma shunt insertion.

Patient concerns: EX-PRESS Glaucoma Filtration Device (Alcon Laboratories, Fort Worth, TX), which is used in open-angle glaucoma surgery, could minimize the potential injury caused by traditional trabeculectomy. However, no study reported about the posterior segment insertion of this device. This article reports an alternative surgical technique and outcomes of pars plana insertion of glaucoma shunt in a patient with refractory NVG.

Diagnoses: This research was a retrospective study of a patient with refractory NVG and in whom trabeculectomy with EX-PRESS implantation was performed. However, bleb failure developed three times in four years.

Interventions: In this patient, the previous EX-PRESS shunt was retrieved and reinserted into the posterior segment through the pars plana 3.5 mm behind the limbus.

Outcomes: The post-operation intraocular pressure was stable for more than eight months after surgery without any surgical intervention or antiglaucoma medication use. No discomfort nor major complication was observed after this operation.

Lessons: Pars plana insertion of glaucoma shunt may provide an alternative to treat refractory NVG in patients who had received pars plana vitrectomy.

Abbreviations: IOP = intraocular pressure, NVG = neovascular glaucoma, PPV = pars plana vitrectomy.

Keywords: bleb failure, EX-PRESS shunt, neovascular glaucoma, pars plana insertion, pars plana vitrectomy, trabeculectomy

1. Introduction

Glaucoma is one of the leading causes of visual loss in worldwide. More than 70 million people are affected nowadays, and 10% are bilaterally blind.^[1] Neovascular glaucoma (NVG), which is attributed to the new blood vessels obstructing the aqueous humor outflow, is one of the most devastating types of glaucoma. This condition may cause open-angle glaucoma by direct invasion of the fibrovascular membrane into the anterior chamber and secondary synechial angle-closure glaucoma by contraction of the membrane.^[2] The treatment of NVG is aimed from 2 aspects. The first aspect involves reduction of the intraocular pressure (IOP), either medically or surgically, to ideal levels. The second aspect involves reduction of the tendency of neovascularization, and this goal can

be achieved by panretinal photocoagulation and intravitreal antivascular endothelial growth factor injection.^[3] However, the outcomes are unsatisfactory. One report stated that the success rate of trabeculectomy for NVG reaches 62.6% in 1 year and declines to 51.7% in 5 years.^[4] Our team reported a case series of 4 patients receiving primary trabeculectomy with EX-PRESS glaucoma shunt. Three of these patients received postoperative IOP under 21 mm Hg without any antiglaucoma medication control in 2 years. However, shunt reposition had been performed in 3 cases due to failed blebs or recurrent NVG.^[5] These experiences in dealing with the intractable NVG urged us to search for another procedure which could serve as an adjunctive and maintain the IOP level in a range more ideal than the previous one. In this paper, we present the surgical procedure and outcome of pars plana EX-PRESS shunt implantation in a patient with refractory NVG.

2. Case report

An 87-year-old female presented poor control of IOP in the left eye for 1 month despite administration of topical Cosopt (2% dorzolamide + 0.5% timolol) (1 drop thrice a day), Brimonidine 0.15% (1 drop thrice a day), and Travoprost 0.004% (1 drop at bedtime). Tracing back her ophthalmologic history, the patient presented an episode of rhegmatogenous retinal detachment in the left eye post pars plana vitrectomy (PPV) and silicone oil tamponade on October 28, 2011. Laser iridotomy was performed on January 3, 2012 due to elevated IOP after operation. Phacoemulsification and posterior chamber intraocular lens implantation in the left eye were performed on February 10, 2012. Anterior chamber tapping and transscleral

Editor: N/A.

First author: C-YY.

The authors have no conflicts of interest to disclose.

Department of Ophthalmology, Taipei City Hospital, Renai Branch, Taipei, Taiwan.

* Correspondence: Gow-Lieng Tseng, No. 10, Sec. 4, Renai Road, Daan District, Taipei City 10629, Taiwan (R.O.C.) (e-mail: daa26@tpech.gov.tw).

Copyright © 2018 the Author(s). Published by Wolters Kluwer Health, Inc. This is an open access article distributed under the terms of the Creative Commons Attribution-NonCommercial-ShareAlike 4.0 License, which allows others to remix, tweak, and build upon the work non-commercially, as long as the author is credited and the new creations are licensed under the identical terms.

Medicine (2018) 97:23(e10977)

Received: 21 February 2018 / Accepted: 7 May 2018

<http://dx.doi.org/10.1097/MD.00000000000010977>

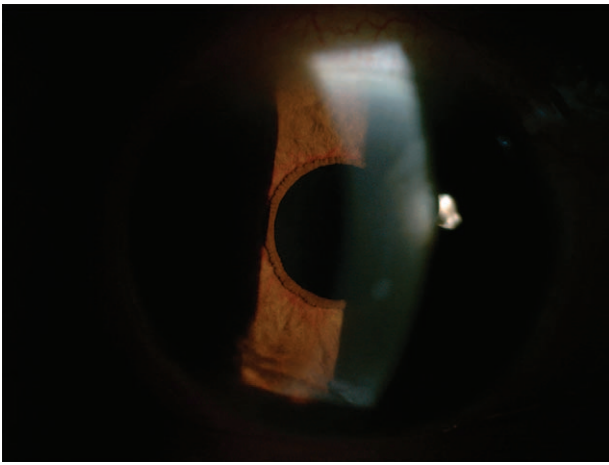


Figure 1. Grade 2 iris neovascularization developed after pars plana vitrectomy and silicone oil tamponade.

cyclophotocoagulation were performed on December 7, 2012 due to persistent ocular hypertension. However, the IOP reached 27.3 mm Hg with 4 kinds of antiglaucoma medications. The patient then came to our hospital for a second opinion.

After evaluating the retina status, we removed the silicone oil on August 1, 2013. The IOP approximated 20 mm Hg in the first 1.5 months. However, the IOP increased to 31.1 mm Hg on October 25, 2013, and grade 2 iris neovascularization developed with 4 kinds of antiglaucoma medications (Fig. 1). Under the impression of NVG due to prolonged oil tamponade, trabeculectomy with EX-PRESS Glaucoma Filtration Device (Alcon Laboratories, Fort Worth, TX) implantation at the 12 o'clock site was performed on November 23, 2013. Bleb revision and reposition of the EX-PRESS were performed on December 21, 2013 and April 18, 2015, respectively, due to bleb failure. The IOP was under control in the first 1 year, and neovascularization of iris subsided gradually (Fig. 2).

This time, the patient visited our hospital on August 1, 2017 due to visual discomfort. The IOP in the left eye measured 40 mm Hg. We added oral acetazolamide (1 tablet twice a day). However, the IOP reached 30 to 40 mm Hg for 1 month despite

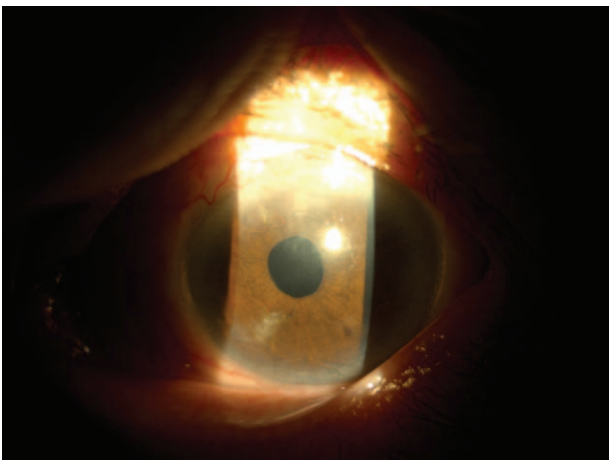


Figure 2. Neovascularization of iris subsided 1 year after trabeculectomy with EX-PRESS shunt insertion.




Figure 3. A half-layer scleral flap 3 mm × 3 mm in size was created 3 mm from the limbus at 2 o'clock.

the use of topical antiglaucoma medications. We then arranged pars plana EX-PRESS reposition on 2017/08/12. The patient has provided an informed consent for the operation and further research with publication. Also, we informed the patient regarding the general and severe complications of ocular surgery, including *endophthalmitis*, and the surgical consents were signed.

Under general anesthesia, we performed peritomy from 10 o'clock to 3 o'clock sites, opened the previous scleral flap, and retrieved the EX-PRESS shunt. A half-layer scleral flap 3 mm × 3 mm in size was created 3 mm from the limbus at 2 o'clock (Fig. 3). A piece of cotton soaked with 0.4 mg/mL mitomycin-C was then placed under the scleral flap for 4 minutes before the irrigation with a balanced salt solution. The EX-PRESS shunt was then reinserted into posterior segment through pars plana about 3.5 mm behind the limbus (Fig. 4). Finally, the flap edge and peritomy were closed by 10-0 nylon, and the postoperation images were obtained (Fig. 5).

Postoperative treatment included Rinderon-A (betamethasone disodium phosphate 0.1%, neomycin sulfate 0.35%) (1 drop 4 times a day) and betasone (betamethasone 0.05%) ointment at bedtime. Follow-up IOP was 8 mm Hg for more than 8 months after operation without any medication, and the bleb was still formed (Fig. 6).

3. Discussion

The key point of intractable NVG lies in the fibrous membrane that occupies almost all the potential space of aqueous fluid outflow pathway; the artificial outflow pathway, such as in trabeculectomy, is also easily occluded by subsequent fibrous tissue proliferation from the conjunctiva and/or sclera. Thus, although successful trabeculectomy with EX-PRESS shunt implantation could yield satisfactory outcomes in the first few months, further bleb revision and EX-PRESS shunt reposition are often unavoidable.

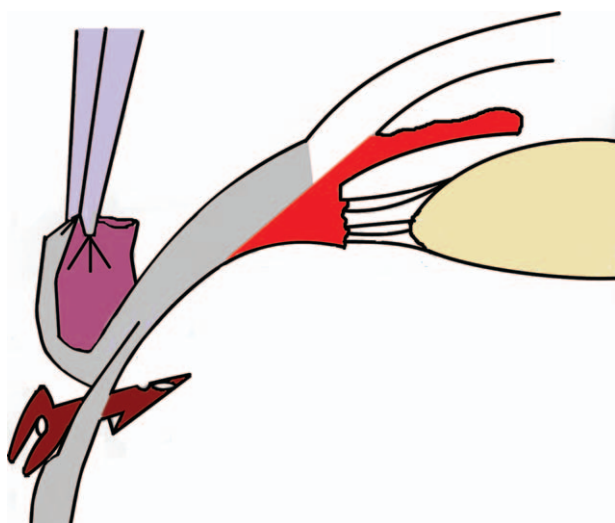


Figure 4. The EX-PRESS shunt was reinserted into posterior segment through pars plana about 3.5 mm behind the limbus.

Considering the limited role of outflow to treat the elevated IOP, we searched for another method to reduce the burden of aqueous fluid in the anterior chamber. Some surgeons may use various glaucoma devices, such as a Baerveldt, Ahmed, or Molten implant, at this point.^[6] However, these implants meet the same problem as EX-PRESS shunt. As long as these surgeries are aimed at the anterior chamber, the fibrous membrane could eventually occlude the outflow pathway in the long term. In addition, we are willing to search for an alternative method in which the EX-PRESS shunt in previous trabeculectomy could be reused as this device proves costly for many patients.

To our knowledge, the aqueous humor is secreted from the pars plicata of the ciliary body, and it is then drained into the posterior chamber through the pupil and eventually enters the anterior chamber. Currently, the points that we can obtain in this route are the ciliary body and posterior chamber. Most surgeons perform cyclodestruction, such as scleral diathermy, cryotherapy, and cyclophotocoagulation, to reduce the formation of aqueous fluid from the ciliary body, similar to our case. Despite the high success rate (75.98%) of cyclophotocoagulation

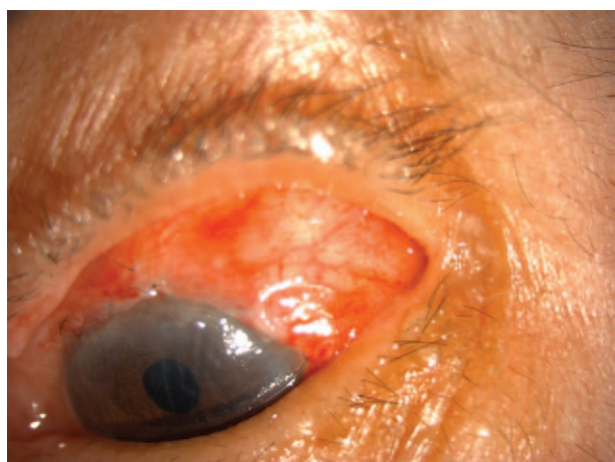

Figure 5. The flap edge and peritomy were closed by 10-0 nylon.

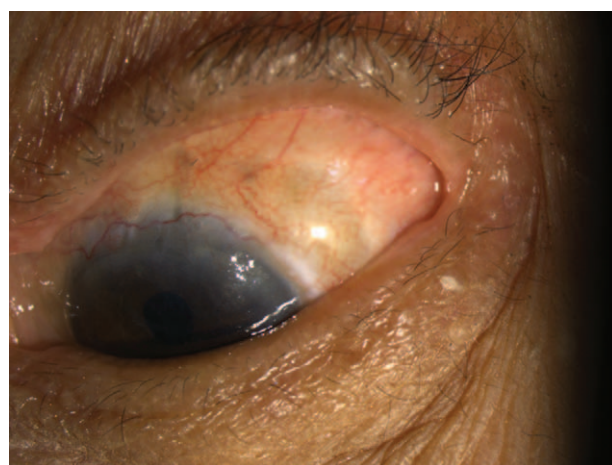


Figure 6. The bleb was formed for more than 8 months after operation.

in refractory glaucoma, postoperative atrophy of the eyeball and severe pain during and after surgery are other dilemmas that must be dealt with.^[7] Furthermore, to date, no effective method is available to manage intractable glaucoma after a successful cyclophotocoagulation.

EX-PRESS glaucoma filtration device (Alcon Laboratories, Fort Worth, TX), which was first introduced in the 1990, was first used in open-angle glaucoma surgery. This device could drain the aqueous humor from the anterior chamber into the subconjunctival space and minimize the potential injury caused by traditional trabeculectomy.^[8] To the best of our knowledge, no study reported about the posterior segment insertion of this device. The basic concept of our surgery is simple, that is, to drain out the aqueous humor from the posterior segment. However, vitreous spaces in a person naive to ocular surgery are discontinuous. Despite vitreous liquefaction with age, various barriers, including the anterior and posterior hyaloid surfaces, still remain in the space, which may impede the outflow of aqueous humor. To deal with this problem, we should break these barriers as much as possible, as in the treatment of malignant glaucoma with anterior hyaloidotomy. This method may create an alternative way for patients who failed to control IOP because of recurrent bleb failure after trabeculectomy. In addition, the patients need not to pay for another glaucoma shunt as the EX-PRESS shunt is used repeatedly.

However, our method still features several limitations. First, the candidate should be limited to patients who had received PPV. Although some surgeons advocate that advanced glaucoma could be treated by combined PPV with glaucoma tube shunt surgery, it remains a not well-established method nowadays.^[9] The effectiveness of our procedure in IOP lowering in patients who received no PPV before remains in consideration. Second, the general condition of previous trabeculectomy bleb failure may also be associated with the bleb failure we created at the scleral flap above the pars plana. However, the new route for aqueous humor outflow could lower the IOP to some extent. Further studies with a longer follow-up period and a larger sample size are still needed to confirm our results.

4. Conclusion

A variety of implant devices are invented to treat refractory NVG. However, the outcomes are unfavorable and are not only caused

by direct occlusion of fibrovascular membrane but also by contraction of the membrane with secondary synechial angle-closure. This report highlights the possible alternative site of EX-PRESS shunt implantation in patients who have undergone vitrectomy surgery.

5. What was known

1. NVG, which is one of the most aggressive types of glaucoma, could be managed either medically or surgically to control IOP and reduce neovascularization.
2. However, the tendency of NVG for fibrous membrane formation may occlude the trabecular meshwork and result in easy recurrence of this condition.

6. What this paper adds

1. Pars plana insertion of glaucoma shunt, which provides an alternative to treat refractory NVG, is useful in patients who had received PPV.
2. The outcome of this method is favorable in our case. The IOP could be maintained in an ideal range without any surgical intervention and medication in clinical practice.

Author contributions

Conceptualization: Chu-Yu Yen, Gow-Lieng Tseng.

Formal analysis: Chu-Yu Yen.

Investigation: Chu-Yu Yen.

Methodology: Chu-Yu Yen.

Supervision: Gow-Lieng Tseng.

Writing – original draft: Chu-Yu Yen.

Writing – review & editing: Gow-Lieng Tseng.

References

- [1] Weinreb RN, Aung T, Medeiros FA. The pathophysiology and treatment of glaucoma: a review. *JAMA* 2014;311:1901–11.
- [2] Shazly TA, Latina MA. Neovascular glaucoma: etiology, diagnosis and prognosis. *Semin Ophthalmol* 2009;24:113–21.
- [3] Olmos LC, Lee RK. Medical and surgical treatment of neovascular glaucoma. *Int Ophthalmol Clin* 2011;51:27–36.
- [4] Takihara Y, Inatani M, Fukushima M, et al. Trabeculectomy with mitomycin C for neovascular glaucoma: prognostic factors for surgical failure. *Am J Ophthalmol* 2009;147:912–8.
- [5] Yu TC, Tseng GL, Chen CC, et al. Surgical treatment of neovascular glaucoma with EX-PRESS glaucoma shunt: case report. *Medicine (Baltimore)* 2017;96:e7845.
- [6] He Y, Tian Y, Song W, et al. Clinical efficacy analysis of Ahmed glaucoma valve implantation in neovascular glaucoma and influencing factors: a STROBE-compliant article. *Medicine (Baltimore)* 2017;96:e8350.
- [7] Yang Y, Zhong J, Dun Z, et al. Comparison of efficacy between endoscopic cyclophotocoagulation and alternative surgeries in refractory glaucoma: a meta-analysis. *Medicine (Baltimore)* 2015;94:e1651.
- [8] Coupin A, Li Q, Riss I. Ex-PRESS miniature glaucoma implant inserted under a scleral flap in open-angle glaucoma surgery: a retrospective study. *J Fr Ophthalmol* 2007;30:18–23.
- [9] Gandhi A, Miller DM, Zink JM, et al. Analysis of long-term outcomes for combined pars plana vitrectomy (PPV) and glaucoma tube shunt surgery in eyes with advanced glaucoma. *Eye (Lond)* 2014;28:290–5.