

## A computed tomography morphometric study of occipital bone and C2 pedicle anatomy for occipital-cervical fusion

Nicolas K. K. King, Tiruchelvarayan Rajendra<sup>1</sup>, Ivan Ng, Wai Hoe Ng

Department of Neurosurgery, National Neuroscience Institute, Singapore General Hospital, Outram Road, Singapore 169608, <sup>1</sup>National Neuroscience Institute, Singapore General Hospital, Outram Road, Singapore 169608 and Gleneagles Hospital, Napier Road, Singapore 258500

E-mail: Nicolas K. K. King - [nicolas\\_kon@nni.com.sg](mailto:nicolas_kon@nni.com.sg); \*Tiruchelvarayan Rajendra - [rajspineclinic@gmail.com](mailto:rajspineclinic@gmail.com); Ivan Ng - [ivan\\_ng@nni.com.sg](mailto:ivan_ng@nni.com.sg); Wai Hoe Ng - [wai\\_hoe\\_ng@nni.com.sg](mailto:wai_hoe_ng@nni.com.sg)

\*Corresponding author

Received: 08 April 14 Accepted: 06 June 14 Published: 28 August 14

### This article may be cited as:

King NK, Rajendra T, Ng I, Ng WH. A computed tomography morphometric study of occipital bone and C2 pedicle anatomy for occipital-cervical fusion. *Surg Neurol Int* 2014;5:S380-3.

Available FREE in open access from: <http://www.surgicalneurologyint.com/text.asp?2014/5/8/380/139676>

Copyright: © 2014 King NKK. This is an open-access article distributed under the terms of the Creative Commons Attribution License, which permits unrestricted use, distribution, and reproduction in any medium, provided the original author and source are credited.

### Abstract

**Background:** Occipital-cervical fusion (OCF) has been used to treat instability of the occipito-cervical junction and to provide biomechanical stability after decompressive surgery. The specific areas that require detailed morphologic knowledge to prevent technical failures are the thickness of the occipital bone and diameter of the C2 pedicle, as the occipital midline bone and the C2 pedicle have structurally the strongest bone to provide the biomechanical purchase for cranio-cervical instrumentation. The aim of this study was to perform a quantitative morphometric analysis using computed tomography (CT) to determine the variability of the occipital bone thickness and C2 pedicle thickness to optimize screw placement for OCF in a South East Asian population.

**Methods:** Thirty patients undergoing cranio-cervical junction instrumentation during the period 2008-2010 were included. The thickness of the occipital bone and the length and diameter of the C2 pedicle were measured based on CT.

**Results:** The thickest point on the occipital bone was in the midline with a maximum thickness below the external occipital protuberance of 16.2 mm ( $\pm 3.0$  mm), which was thicker than in the Western population. The average C2 pedicle diameter was 5.3 mm ( $\pm 2.0$  mm). This was smaller than Western population pedicle diameters. The average length of the both pedicles to the midpoint of the C2 vertebral body was 23.5 mm ( $\pm 3.3$  mm on the left and  $\pm 2.3$  mm on the right).

**Conclusions:** The results of this first study in the South East Asian population should help guide and improve the safety in occipito-cervical region instrumentation. Thus reducing the risk of technical failures and neuro-vascular injury.

**Key Words:** Cervical pedicle, morphometric study, occipital bone, occipital-cervical fusion

### Access this article online

#### Website:

[www.surgicalneurologyint.com](http://www.surgicalneurologyint.com)

#### DOI:

10.4103/2152-7806.139676

#### Quick Response Code:



### INTRODUCTION

Occipital-cervical fusion (OCF) has been used to treat instability of the occipito-cervical junction and to provide

biomechanical stability after decompressive surgery. The indications for OCF have included instability resulting from trauma, decompressive cranio-cervical junction surgery, infection, tumor, rheumatological disease,

degeneration, and congenital malformation. In a recent systematic review of the different methods available for performing OCF, Winegar *et al.*<sup>[10]</sup> found that 51% were treated with wiring/rod fixation, 24% with screw/plate constructs, 19% with posterior wiring/onlay grafting, and 6% were treated with screw/rod constructs. Their study also highlighted the high rates of instrumentation failure occurring in order of decreasing frequency for the wiring/onlay bone grafting (100%), screw/plates (27%), wiring/rod (14%), and screw/rod (8%) techniques. Given these rates of failure, it is critical that sufficient care and attention is paid to minimize technical failures irrespective of the method chosen for OCF.

When OCF is performed using screws, two specific areas require detailed morphologic anatomical knowledge to prevent technical failures. These are the thickness of the occipital bone and diameter of the C2 pedicle. In each case, understanding the variation in thickness and diameter of the bony anatomy would permit the selection of the most optimal screw. Inappropriate screw placement in the occipital region can potentially lead to construct weakness as well as other reported complications which include venous sinus penetration, injury to the underlying neural structures, cerebrospinal fluid leak, and death from acute epidural hematoma.<sup>[4,5]</sup>

Although a few previous studies have looked at occipital bone thickness, there have been no studies in the South East Asian population.<sup>[3,7,11]</sup> The aim of this study was to perform a quantitative morphometric analysis using computed tomography (CT) to determine the variability of the occipital bone thickness and C2 pedicle thickness to optimize screw placement for OCF in patients from this region.

## MATERIALS AND METHODS

### Subjects

Ethics approval was obtained from our Centralised Institutional Review Board (2013/1013/A). This was a single surgeon surgical series by the senior author (TR). Thirty adult patients from a multi-ethnic South East Asian population undergoing OCF, cervical instrumentation, and cranial procedures at a single institution (Department of Neurosurgery, National Neuroscience Institute, Singapore General Hospital Campus, Singapore) during the period from 2008 to 2010 were included. Measurements of occipital bone thickness were performed in those 30 patients with a median age of 68.5 years (range: 44-79 years) for females and 50.5 years (range: 16-70 years) for males. Measurement of the C2 pedicle was performed bilaterally in 29 patients with a median age of 57 years (range: 29-82 years) for 11 females and 52 years (range: 16-74 years) for 18 males. A total of 58 cervical (C2) pedicles were measured.

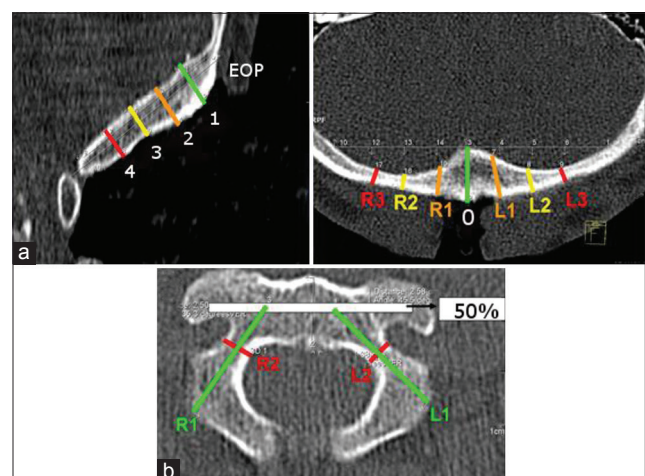
### Imaging procedure

All patients had surgical procedures performed in an operating suite containing a 24-slice intraoperative CT scanner (Somatom Sensation Open, Siemens, Germany). Non-enhanced contiguous fine slice (1.5 mm) CT data were acquired intraoperatively for all patients with the patient lying in the prone position and the head fixed in a radiolucent Mayfield clamp if an OCF was being performed. The acquired imaging was then used to define the morphology of the occipital bone and cervical pedicles.

### Measurements

CT measurements were performed on the bone windows with the dimensions as shown in Figure 1. The points selected for measurements were chosen as they conform to the most common location for the occipital plate screws as used for OCF. This midline keel and paramedian bone offers the best purchase for screws and is commonly utilized in most OCF instrumentation systems. The occipital bone thickness was measured relative to the midline, starting at a level 1 cm inferior to the external occipital protuberance (EOP). Three lateral measurements [Figure 1a] were made at 1 cm interval at either sides of the midline with intervals on the left being negative (-1, -2, and -3) and on the right being positive (1, 2, and 3). In the midline, occipital bone thickness was measured inferior to the EOP also at 1 cm intervals [Figure 1b].

The C2 pedicle parameters measured are illustrated in Figure 1c and d. The outer pedicle diameter was measured from the outer cortex at its narrowest point in the transverse plane at the pedicle isthmus [Figure 1c]. The pedicle length was measured in line with the axis of the C2 pedicle from the posterior surface to the



**Figure 1:** Illustration showing the distances measured on CT bone window from the (a) occipital region and (b) C2 vertebra. In (a), the distance is measured at 1 cm intervals from the external occipital protuberance (EOP) in the midline and at 1 cm intervals lateral to the midline. In (b), the length of the pedicle (R1, L1) to the midpoint of the vertebral body bilaterally was measured, as well as the diameter of the pedicle (R2, L2)

**Table 1: Occipital bone thickness (mm) measured at fixed intervals lateral to the midline and inferior to the external occipital protuberance**

|         | Distance (cm) lateral to midline at 1 cm below EOP |         |          |          |          |         |         | Distance (cm) inferior to EOP |          |         |
|---------|--|---------|----------|----------|----------|---------|---------|-------------------------------|----------|---------|
|         | -3   | -2      | -1       | 0        | +1       | +2      | +3      | 2                             | 3        | 4       |
| Male    | 6.2±1.8  | 7.7±2.5 | 11.4±2.8 | 16.6±3.2 | 10.5±2.9 | 7.0±2.3 | 5.6±1.4 | 11.9±3.3                      | 10.1±2.0 | 7.8±1.4 |
| Female  | 6.7±1.6  | 9.1±2.0 | 11.0±2.3 | 15.9±2.9 | 9.5±2.5  | 7.0±1.8 | 5.7±1.1 | 9.9±3.2                       | 8.4±2.5  | 6.9±2.0 |
| Overall | 6.5±1.6  | 8.4±2.3 | 11.2±2.5 | 16.2±3.0 | 9.9±2.7  | 7.0±2.0 | 5.6±1.2 | 10.8±3.3                      | 9.2±2.4  | 7.3±1.8 |

+: Right side, -: Left side, EOP: External occipital protuberance

half-way point on the vertebral body [Figure 1d]. This length would correspond to the approximate length of C2 pedicle screws that are commonly used.

**Statistical analysis**

Data were entered into SPSS version 16.0 (SPSS Inc, Chicago, IL, USA) for statistical analysis. The assumption of normality was tested using the Kolmogorov-Smirnov test. If this failed, the difference between groups was compared using the Mann-Whitney U test. To correct for multiple comparisons, the Bonferroni method was used.  $P < 0.05$  was considered significant. All values are presented as mean (mm) ± standard deviation.

**RESULTS**

**Occipital bone measurements**

The results of measurements of occipital bone thickness are shown in Table 1. There were no statistically significant differences between genders for the values of bone thickness measured in Table 1 ( $P > 0.05$ ).

There was a statistically significant difference between the overall thickness on the left side at 2 cm ( $8.4 \pm 2.3$  mm) from the midline compared to the right ( $7.0 \pm 2.0$  mm) ( $P = 0.02$ ), but there was no such difference for the lateral distances of 1 cm ( $11.2 \pm 2.5$  mm on the left side,  $9.9 \pm 2.7$  mm on the right side) and 3 cm ( $6.5 \pm 1.6$  mm on the left side,  $5.6 \pm 1.2$  mm on the right side) from the midline ( $P > 0.05$ ). Moving inferiorly down the midline from the EOP, the decreasing thickness of the occipital bone was significant ( $P < 0.01$ ) with an estimated decrease of 0.3 mm for every centimeter below the EOP. The estimated distribution of occipital bone thickness in the different axes is illustrated in Figure 2.

**C2 pedicle measurements**

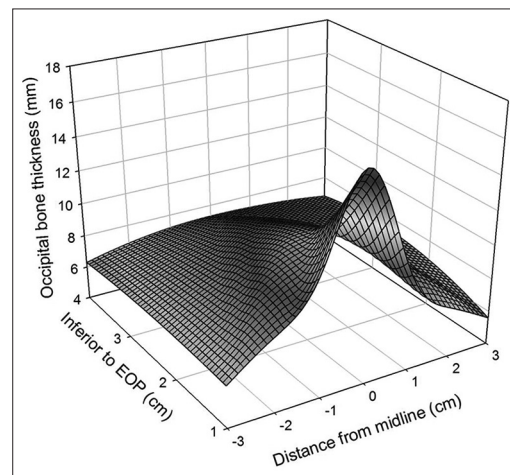
The measurements of the right and left C2 pedicles are shown in Table 2. The combined mean diameter of both left and right pedicles was significantly larger for males ( $5.6 \pm 1.7$  mm) compared to females ( $4.8 \pm 1.9$  mm) ( $P = 0.03$ ). Similarly, the combined mean length of the left and right pedicles was significantly longer for males compared to females ( $P < 0.01$ ).

The effect of laterality was also assessed on pedicle diameters for the right side ( $5.2 \pm 1.7$  mm) and left side ( $5.3 \pm 2.0$  mm) and on pedicle lengths for the right

**Table 2: C2 pedicle diameters and length**

|         | Pedicle diameter (mm) |         | Pedicle length (mm) |          |
|---------|-----------------------|---------|---------------------|----------|
|         | Left                  | Right   | Left                | Right    |
| Male    | 5.4±1.8               | 5.7±1.7 | 24.7±2.8            | 24.2±2.5 |
| Female  | 5.2±2.3               | 4.5±1.3 | 21.5±3.2            | 22.4±1.3 |
| Overall | 5.3±2.0               | 5.2±1.7 | 23.5±3.3            | 23.5±2.3 |

The length of the pedicle was measured to the midpoint (50%) of the vertebral body of C2



**Figure 2: Thickness of the occipital bone inferior to the external occipital protuberance (EOP) extrapolated from measurements performed**

side ( $23.5 \pm 3.3$  mm) and left side ( $23.5 \pm 2.3$  mm). This showed that there were no significant differences between right and left pedicle diameters and pedicle lengths ( $P > 0.05$ ).

**DISCUSSION**

In this study of occipital bone thickness in a South East Asian population, we found that the thickest point was in the midline with a maximum thickness below the EOP of 16.2 mm ( $\pm 3.0$  mm). This maximum was thicker in our population compared to those in previous studies from Turkey and the USA where the thickness ranged from 8 to 11 mm [Table 3], suggestive of regional variability. At 2 cm below the EOP, which is relevant in the clinical context as this is a common location for screw placement, it was determined in our study that the average bone thickness was 10.8 mm ( $\pm 3.3$  mm).

**Table 3: Comparison of occipital bone thickness from previously published data measured at the same locations as in this study**

|                       | Distance (cm) lateral to midline at 1 cm below EOP |         |         |          |         |         |         | Distance (cm) inferior to EOP |         |         |
|-----------------------|--|---------|---------|----------|---------|---------|---------|-------------------------------|---------|---------|
|                       | -3   | -2      | -1      | 0        | 1       | 2       | 3       | 2                             | 3       | 4       |
| Zipnick, 1996 (USA)   | -  | -       | -       | 11±2     | -       | -       | -       | 9±3                           | -       | -       |
| Ebraheim, 1996 (USA)  |  |         |         |          |         |         |         |                               |         |         |
| Male                  | 5.5±1.9  | 5.7±1.9 | 7.2±2.7 | 11.1±2.5 | 6.7±2.2 | 5.9±1.8 | 5.7±1.7 | 9.0±2.0                       | 6.8±1.4 | 6.1±1.8 |
| Female                | 4.3±1.3  | 4.3±1.3 | 5.1±1.6 | 9.5±2.2  | 5.0±1.6 | 4.4±1.2 | 4.8±1.6 | 7.8±1.7                       | 6.6±1.3 | 5.6±1.3 |
| Naderi, 2001 (Turkey) | 6.8±2.4  | 7.2±2.5 | 8.7±3.3 | 12.7±4.1 | 8.9±2.0 | 7.7±2.2 | 6.5±1.7 | 8.1±3.0                       | 7.8±1.8 | 6.2±1.9 |

+: Right side, -: Left side, EOP: External occipital protuberance

Therefore, the most common length of screw for use in our patient population would be an 8-10 mm screw for that location. Similar to the Turkish and US studies, we also found that the thickness tapered rapidly away from the midline.<sup>[3,7,11]</sup> Interestingly, there was no gender difference in occipital bone thickness. Our result would, therefore, suggest that the most suitable location for unicortical screw insertion would be below the EOP in the midline. For the paramedian screws 2 cm from the midline, the overall bone thickness ranged from 7.0 to 8.4 mm, and would correspond to the commonly used screw lengths of 6-8 mm. When the short paramedian screws are considered, there may be a risk of insufficient fixation and an alternate method of fixation should be considered such as a midline fixation or occipital buttons to avoid the increased risk of failure.

Unlike occipital bone thickness, there was a gender difference for the C2 pedicle screw diameters and lengths. The average C2 pedicle diameter ( $5.3 \pm 2.0$  mm) in our population was smaller than that reported in the Western population ( $5.6 \pm 1.2$  mm),<sup>[9]</sup> but was comparable to that from pooled results of the Asian population ( $5.2$ - $5.4$  mm).<sup>[6]</sup> A possible explanation of the difference in C2 morphology may be accounted for by the differences in average body height and weight between the South Asian and Western populations. In clinical practice, commercial instrumentation systems have screw diameters of 3.5 mm, and based on our findings, these can be used safely in our patients. The average C2 pedicle length ranged from 21.4 to 24.7 mm, and would correspond to the commonly used screw length of 22-24 mm.

The importance of these findings is that they would guide the appropriate selection of screws for placement in the South Asian population for which no data are currently available. Significant morbidity has been reported with inappropriate screw placement in the occipital region and includes construct weakness, venous sinus penetration leading to extradural hematomas, injury to the underlying neural structures, and cerebrospinal fluid leak.<sup>[4,5]</sup> Risks for C2 pedicle screws include construct weakness, perforation of the pedicle, and injury to the nerve root, spinal cord, and vertebral artery.<sup>[1,2,8]</sup>

## CONCLUSION

This first study of occipital bone thickness in the South East Asian population reveals that occipital bone thickness is greater in this population compared to the European or Western population. However, the C2 pedicle diameter was found to be smaller in diameter than the Western population. These results should help to improve the safety of OCF and contribute toward reducing technical failures by assisting the surgeon in the optimal selection of screws for this procedure.

## ACKNOWLEDGMENT

Tom Ang, Department of Diagnostic Radiology, Singapore General Hospital, Outram Road, Singapore 169608 is gratefully acknowledged.

## REFERENCES

- Bransford RJ, Russo AJ, Freeborn M, Nguyen QT, Lee MJ, Chapman JR, et al. Posterior C2 instrumentation: Accuracy and complications associated with four techniques. *Spine (Phila Pa 1976)* 2011;36:E936-943.
- Ebraheim N, Rollins JR Jr, Xu R, Jackson WT. Anatomic consideration of C2 pedicle screw placement. *Spine (Phila Pa 1976)* 1996;21:691-5.
- Ebraheim NA, Lu J, Biyani A, Brown JA, Yeasting RA. An anatomic study of the thickness of the occipital bone. Implications for occipitocervical instrumentation. *Spine (Phila Pa 1976)* 1996;21:1725-9.
- Haheer TR, Yeung AW, Caruso SA, Merola AA, Shin T, Zipnick RI, et al. Occipital screw pullout strength. A biomechanical investigation of occipital morphology. *Spine (Phila Pa 1976)* 1999;24:5-9.
- Lee SC, Chen JF, Lee ST. Complications of fixation to the occiput-anatomical and design implications. *Br J Neurosurg* 2004;18:590-7.
- Liu J, Napolitano JT, Ebraheim NA. Systematic review of cervical pedicle dimensions and projections. *Spine (Phila Pa 1976)* 2010;35:E1373-80.
- Naderi S, Usal C, Tural AN, Korman E, Mertol T, Arda MN. Morphologic and radiologic anatomy of the occipital bone. *J Spinal Disord* 2001;14:500-3.
- Ondra SL, Marzouk S, Ganju A, Morrison T, Koski T. Safety and efficacy of C2 pedicle screws placed with anatomic and lateral C-arm guidance. *Spine (Phila Pa 1976)* 2006;31:E263-7.
- Tomasino A, Parikh K, Koller H, Zink W, Tsiouris AJ, Steinberger J, et al. The vertebral artery and the cervical pedicle: Morphometric analysis of a critical neighborhood. *J Neurosurg Spine* 2010;13:52-60.
- Winegar CD, Lawrence JP, Friel BC, Fernandez C, Hong J, Maltenfort M, et al. A systematic review of occipital cervical fusion: Techniques and outcomes. *J Neurosurg Spine* 2010;13:5-16.
- Zipnick RI, Merola AA, Gorup J, Kunkle K, Shin T, Caruso SA, et al. Occipital morphology. An anatomic guide to internal fixation. *Spine (Phila Pa 1976)* 1996;21:1719-24.