




Survival Outcome in True Carcinoma of Unknown Primary (tCUP) with p16 + Cervical Metastasis

Muhammad Faisal^{1,2}  Nguyen-Son Le³ Stefan Grasl³ Johannes Pammer⁴ Stefan Janik³
Gregor Heiduschka³ Annemarie U. Schratte-Sehn⁵ Peter Franz⁶ Meinhard Königswieser⁶
Matthaeus Ch. Grasl³ Boban M. Erovic²

¹ Department of Surgical Oncology, Shaukat Khanum Memorial Cancer Hospital and Research Center, Lahore, Pakistan

² Institute of Head and Neck Diseases, Evangelical Hospital, Vienna, Austria

³ Department of Otorhinolaryngology, Head and Neck Surgery, Medical University of Vienna, Vienna, Austria

⁴ Department of Clinical Pathology, Medical University of Vienna, Vienna, Austria

⁵ Institute of Radio-Oncology, Kaiser-Franz-Josef Hospital, Vienna, Austria

⁶ Department of Otorhinolaryngology, Head and Neck Surgery, Rudolfstiftung Hospital, Vienna, Austria

Address for correspondence Boban M. Erovic MD, PD, MBA, Institute of Head and Neck Diseases, Evangelical Hospital Vienna, Hans-Sachs-Gasse 10-12, 1180 Vienna, Austria (e-mail: b.ervic@ekhwien.at).

Int Arch Otorhinolaryngol 2023;27(4):e687–e693.

Abstract

Introduction Age and lymph node ratio have been attributed as independent predictors for survival and recurrence in carcinoma of unknown primary (CUP).

Objective The purpose of this study was to analyze the prognostic value of p16 overexpression for CUP in the absence of true primary (TP).

Methods The study involved 43 patients who underwent therapeutic lymph node dissection (LND) from 2000 to 2015 after all the diagnostic work up for CUP. Immunohistochemistry for p16 overexpression was performed. Cox proportional hazard regression analysis was used to analyze the prognostic impact on 5-year overall survival (OS) and recurrence-free survival (RFS).

Results The male-to-female ratio was 5.1:1, with a median age of 62 years. The clinicopathological data, except for p16 overexpression, did not differ significantly in terms of 5-year OS and RFS. The Cox regression analysis proposed p16 positivity to be an independent prognosticator of regional recurrence-free survival (RRFS) (hazard ratio [HR] 6.180, $p = 0.21$). The median time to recurrence and death were 10 and 25 months, respectively.

Conclusion Cervical metastasis with p16 overexpression is a significant prognostic factor of improved RFS after surgery in CUP. The prognostic significance of lymph node p16 positivity should be further studied.

Keywords

- ▶ unknown primary
- ▶ neoplasm metastasis
- ▶ head and neck neoplasms

received
September 18, 2021
accepted after revision
August 22, 2022

DOI <https://doi.org/10.1055/s-0042-1759575>.
ISSN 1809-9777.

© 2023. Fundação Otorrinolaringologia. All rights reserved.
This is an open access article published by Thieme under the terms of the Creative Commons Attribution-NonDerivative-NonCommercial-License, permitting copying and reproduction so long as the original work is given appropriate credit. Contents may not be used for commercial purposes, or adapted, remixed, transformed or built upon. (<https://creativecommons.org/licenses/by-nc-nd/4.0/>)
Thieme Revinter Publicações Ltda., Rua do Matoso 170, Rio de Janeiro, RJ, CEP 20270-135, Brazil

Introduction

Carcinoma of unknown primary (CUP) is a rare disease among head and neck cancers, accounting for only 3 to 7% of cases.^{1,2} Carcinoma of unknown primary is defined as cervical metastasis without any evidence of the primary tumor despite comprehensive history, clinical examination, morphologic/metabolic imaging, examination under anesthesia (EUA) and direct biopsies.^{3,4} The primary tumor may remain undetected in 5 to 10% of cases after all the diagnostic work up.⁵ Subclinical dormancy or early spontaneous regression are the possible carcinogenic theories responsible for no identification of the primary site.^{6,7} The metastatic lymph nodes (LNs) most commonly contain squamous cell carcinoma (53–80%) followed by undifferentiated carcinomas (13–14%) and adenocarcinomas (13%).^{8–11} The rarity of the disease has led to a wide range of small retrospective studies using various diagnostic criteria and treatment strategies.¹² There is increasing evidence on the prevalence of human papillomavirus (HPV)-related squamous cell carcinoma of unknown primary (SCCUP) showing better outcomes in terms of treatment response and survival while demonstrating a weaker association with smoking and alcohol.^{13,14} In HPV-induced CUP, p16^{INK4} overexpression has been considered a surrogate marker correlated with survival outcomes, but its role as an independent predictor has remained controversial. Interestingly, p16 overexpression is not only the trademark of HPV-driven SCCUP, but it also has a strong association with cutaneous squamous cell carcinoma as well as with branchial cyst. This requires further confirmation of HPV presence by performing in-situ hybridization (ISH) or polymerase chain reaction (PCR) in SCCUP.¹⁵ The objective of the present study was to evaluate the prognostic value of p16 overexpression in cervical LNs of CUP in terms of overall and RRFs. Apart from that, age and LNR have also been incorporated to determine their role as predictors of survival in CUP.

Materials and Methods

Patient Cohort

In this multicenter, retrospective study, 94 patients with CUP of the head and neck have been treated from 2000 to 2015 at the departments of otorhinolaryngology, head and neck surgery of the Vienna General Hospital (University Hospital of the Medical University of Vienna), Kaiser-Franz-Josef Hospital (Vienna), Hanusch Hospital (Vienna), and Rudolfstiftung Teaching Hospital (Vienna). In order to analyze a homogeneous patient cohort, patients had to fulfill criteria to be included in our study. Patients had to be initially treated with lymph node dissection (LND) followed by adjuvant RT. Thus, patients with primary RT (n = 10, 10.6%), palliative therapy protocol (n = 6, 6.4%) or prematurely terminated therapy (n = 2, 2.1%) were excluded. Another exclusion criterion was the emergence of the primary tumor before completion of treatment. Patients with distant metastases at the time of diagnosis were excluded. Furthermore, sufficient documentation of the performed diagnostic methods was mandatory. Hence, 42 (45.7%) of the 94 CUP patients were

included in this study. Based on the median LNR of 0.05 in our cohort, the cut-off of 0.05 was selected to divide the sample into roughly equal sized groups.

Diagnostic Methods

The standard diagnostic algorithm of the Medical University of Vienna comprises a non-invasive and an invasive part. First, a detailed anamnesis, clinical examination including flexible nasopharyngoscopy, ultrasound of the neck, chest X-ray, and computed tomography (CT) or magnetic resonance imaging (MRI) are performed. In addition, the 18F-FDG-PET-CT has become part of the algorithm from 1999 on. Subsequently, fine-needle aspiration cytology (FNAC), panendoscopy, and diagnostic tonsillectomy are carried out.

Treatment Methods

Cervical LN metastases were initially treated with LND. Depending on the spread of LN metastases, unilateral or bilateral ND was performed. Subsequently, all patients with N2/N3 disease without extracapsular extension (ENE) were irradiated either unilaterally or bilaterally using three-dimensional conformal radiation therapy (3D-CRT), intensity-modulated radiation therapy (IMRT), or volumetric modulated arc therapy (VMAT) technique. Furthermore, chemotherapy (CTX) was applied in certain patients based on extracapsular extension of the nodal disease.

Statistical Methods

The IBM SPSS Statistics for Windows, version 24.0 (IBM Corp., Armonk, NY, USA) was used for the statistical analyses. The *t*-test was performed to analyze the distribution of the age. The Kaplan-Meier analysis was used to determine the impact of clinical variables on 5-year overall survival (OS) and 5-year regional recurrence-free survival (RFS) and corresponding *p*-values were obtained via log-rank test. Kaplan-Meier curves (→ **Figures 1** and **2**) were created in GraphPad Prism 8 (GraphPad Software Inc., La Jolla, CA, USA).

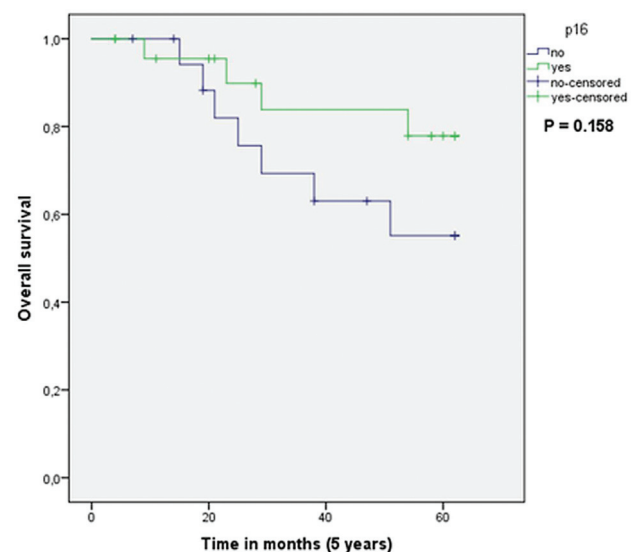


Fig. 1 Overall survival for patients having metastatic lymph nodes containing p16 overexpression.

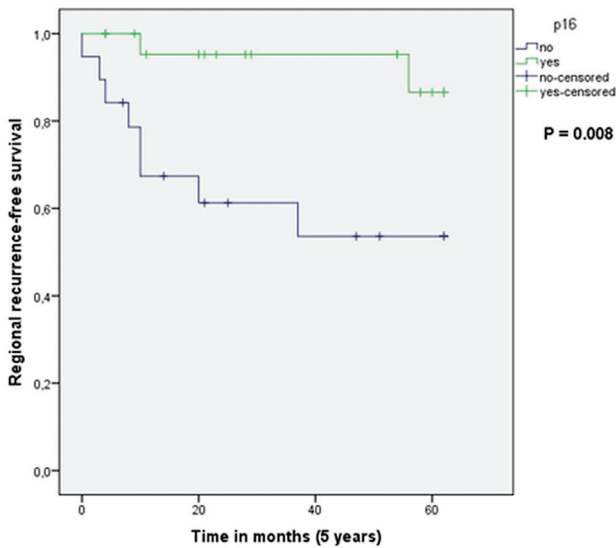


Fig. 2 Regional recurrence-free survival (RRFS) for patients having metastatic lymph nodes containing p16 overexpression.

Results

Patient Characteristics

The median age of the patients was 62.00 years (range: 44–86) with a male-to-female ratio of 5.1 to 1. Nicotine consumption with an average of 20 cigarettes per day was documented in 67.4% of the patients. More frequent or excessive consumption of alcohol was stated in 62.8% of the patients, whereas cancer family history was positive in 39.5% (► **Table 1**.)

Diagnostic Methods

Radiologically, the head and neck area were examined by using CT in 88.4% of the patients, while MRI was performed in 51.2% of the cases. The 18F-FDG-PET-CT was applied either before RT or during the examinations/follow up in 65.1% of patients.

FNAC was performed in 27.9% of the patients while panendoscopy was indicated in 90.7% of cases. Due to the lack of documentation in 4 patients, it can be assumed that all patients were examined endoscopically. Tonsillectomy was carried out in 41.9% of the patients while tonsils have already been removed in 44.2% of cases (► **Table 1**).

Details of the Cervical LN Metastases

The most commonly affected areas of the neck were levels II and III (cumulatively: 81.7%). Lymph node metastases occurred in 57.6% of patients in the territory of level II, while level III was affected in 7.6% of cases. Moreover, LNs were classified according to the American Joint Committee on Cancer (AJCC) as follows: 11.9% of the patients were staged as N1, 21.4% as N2a, 57.1% as N2b, 2.3% as N2c, and 7.1% as N3, respectively. Squamous cell carcinoma (SCC) was found in 100% of cases

In most cases, the tumor was found to be moderately-to-poorly differentiated (G2–G3, cumulatively: 94.1%). (► **Table 2**).

p16 Immunohistochemistry and Overexpression

Immunohistochemistry for p16 was performed on LN after dissection using a CINTec p16 Histology Kit (MTM Laboratories; Roche Applied Sciences, Penzberg, Germany) according

Table 1 Patient characteristics and details of diagnostic methods

	Number of patients (%)
Gender	
Male	36 (83.7%)
Female	7 (16.3%)
Age (median, years)	62.00
Smoking history	
No	14 (32.6%)
Yes	29 (67.4%)
Cigarettes per day (median)	20.00
Alcohol	
No	16 (37.2%)
Yes	27 (62.8%)
Cancer in family	
Negative	26 (60.5%)
Positive	17 (39.5%)
Imaging diagnostics	
CT head/neck	38 (88.4%)
CT thorax	27 (62.8%)
CT abdomen	25 (58.1%)
MRI	22 (51.2%)
FDG-PET-CT	28 (65.1%)
Invasive diagnostics	18 (24.7%)
Fine needle aspiration	12 (27.9%)
Panendoscopy	39 (90.7%)
Tonsillectomy	18 (41.9%)
St. p. tonsillectomy	19 (44.2%)

Abbreviations: CT, computed tomography; FDG-PET-CT, fluorodeoxyglucose positron emission tomography-computed tomography; MRI, magnetic resonance imaging; RT, radiotherapy; St.p., status post.

to the manufacturer’s protocol.¹⁶ The defined criteria for p16 overexpression was ≥ 75% positive cells and at least moderate staining intensity on immunohistochemistry. The cumulative results in our cohort showed 55.8% cases to be positive for p16 overexpression (► **Table 2**).

Clinical Outcome and Survival Analysis

Within a median follow-up time of 47.00 months, the mortality rate was 32.6%, whereas regional recurrences (RRs) occurred in 28.6% of the patients.

By using a Kaplan-Meier survival analysis, the estimated 5-year OS and RRFs were 67.4% and 71.4%, respectively (► **Figures 1, 2**). Within the 5-year observation period, the median time until death was 25.00 months, while RR occurred after a median time of 10.00 months.

The emergence of distant metastases was observed in 3 patients (7%) (► **Table 3**). The distribution of metastases localization was: lung (n = 1), bones (n = 1), and liver and bones (n = 1). Moreover, generalized metastases were found

Table 2 Details of lymph node metastases and treatment methods

	Number of patients (%)
Site of lymph node metastases	
Left	20 (47.6%)
Right	22 (52.3%)
Bilateral	
Level of lymph node metastases	
Level I	9 (14.0%)
Only Level I	6
Level II	30 (46.9%)
Only level II	15
Level III	17 (26.6%)
Only level III	2
Level IV	3 (4.7%)
Only level IV	1
Level V	4 (6.3%)
Only level V	1
Level VI	1 (1.6%)
Only Level VI	1
TNM-Classification (AJCC)	
N1	5 (11.9%)
N2a	9 (21.4%)
N2b	24 (57.1%)
N2c	1 (2.3%)
N3	3 (7.1%)
M0	42 (100.0%)
Histology	
Squamous cell carcinoma	42 (100.0%)
p16 positive	24 (55.8%)
Grading	2 (4.7%)
G1	1 (2.3%)
G1–G2	12 (27.9%)
G2	6 (14.0%)
G2–G3	20 (46.5%)
G3	2 (4.7%)
Not stated	9 (21.4%)
Treatment modality	
Lymph node extirpation (LnEX)	22 (51.2%)
Lymph node extirpation only	7 (16.3%)
Neck dissection (ND)	36 (83.7%)
Neck dissection only	21 (48.8%)
LnEx + ND	15 (34.9%)
Radiotherapy (RT)	42 (100.0%)
Ipsilateral	17 (40.4%)

Table 2 (Continued)

	Number of patients (%)
Bilateral	25 (58.1%)
Dose median ipsilateral	60.0
Dose median contralateral	52.0
Chemotherapy (CTX)	19 (44.2%)
Before RT (BCTX)	2 (10.5%)
CTX-RT	13 (68.4%)
After RT	3 (15.8%)
BCTX + CTX-RT + ACTX	1 (5.3%)

Abbreviations: AJCC 8th Edition, American Joint Committee on Cancer, N, lymph node status

Table 3 Outcome analysis

	Number of patients (%)
Outcome	
Follow-up time (median, months)	47.00
5-year OS	67.4%
Time until death (median, months)	25.00
5-year RFS	71.4%
Relapse time (median, months)	10.00
Primary tumor	6 (14.0%)
Distant metastasis	3 (7.0%)

Abbreviations: OS, overall survival; RFS, recurrence-free survival.

in two patients during the autopsy. Primary tumor has emerged in 6 patients (oropharynx = 4, hypopharynx = 1, larynx = 1) in the follow-up. The occurrence of the primary tumor has led to a 5-year OS of 55.6% ($p = 0.50$). Furthermore, distant metastases had a significantly worsening impact on the 5-year OS ($p = -0.005$). A univariate Cox-regression analysis was performed to determine the impact of potential prognosticators affecting the 5-year OS and RFS. Tumor grade, nodal disease volume, distant metastasis, and the emergence of the primary tumor in subsequent course of treatment or follow-up did not adversely affect survival. Only p16 overexpression has been documented as the potential factor improving 5-year RFS (HR = 6.180, $p = 0.021$) (**Table 4**). A LNR > 0.05 has shown adverse outcome in both OS and RFS (HR 1.725 and 1.720, respectively) when compared with LNR < 0.05.

Discussion

The prognostic value of p16 overexpression in head and neck cancers has been well documented in the background of HPV-driven oropharyngeal primary tumors presenting with cervical metastasis.^{17,18} The recent AJCC 8th edition TNM classification has demarcated HPV mediated p16 positive (+)

Table 4 Kaplan-Meier and Cox regression analyses

	Kaplan-Meier analyses				Cox regression analyses					
	% OS		% RFS		univariate (OS)			univariate (RFS)		
	5-yr	<i>p</i> val. ^a	5-yr	<i>p</i> val. ^a	HR	<i>p</i> val. ^b	95% CI	HR	<i>p</i> val. ^b	95% CI
p16 (yes vs. no)		0.158		0.008	2.359	0.172	0.688–8.092	6.180	0.021	1.309–29.189
yes	77.9		86.6							
no	55.1		53.6							
N1–2a vs. N2b–3		0.323		0.255	1.928	0.333	0.510–7.285	2.376	0.274	0.504–11.206
N1–2a	77.1		85.7							
N2b–3	61.8		63.2							
G1 vs. G2–3		0.887		0.916	1.093	0.887	0.319–3.746	1.077	0.917	0.268–4.324
G1–2	65.3		76.0							
G3	67.1		73.7							
DM (no vs. yes)		0.005		0.668	5.427	0.013	1.429–20.612	1.564	0.674	0.195–12.540
no	74.3		72.3							
yes	0.0		66.7							
ND only vs. LN only		0.470		0.107	0.472	0.483	0.058–3.842	.253	0.113	0.047–1.343
ND only	62.3		62.6							
LN-Ex only	80.0		100							
Smokers		0.456		0.863	1.650	0.462	0.435–6.259	1.126	0.864	0.289–4.382
no	76.9		76.6							
yes	59.6		66.9							

Abbreviations: CI, confidence interval; HR, hazard ratio; LN-Ex, lymph node extirpation; ND, neck dissection; OS, overall survival; RFS, recurrence-free survival; val., value; yr, year.

^aKaplan-Meier analyses

^bUnivariate Cox regression analyses

from non-HPV p16 negative (-) oropharyngeal carcinomas for better prognostic categorization.¹⁹ Despite the scarcity of randomized controlled trials and prospective studies, multiple prognostic factors have been identified from retrospective series, including HPV (p16 +) oropharyngeal SCC, patient's age, nodal disease volume, extra nodal extension, and p53 status.^{20–24} Advanced age, high nodal disease volume, p16 negativity, and macroscopic extra nodal extension (≥ 2 mm) are considered to be the predictors of poor survival.^{20,21,25,26} The most common LNs harboring metastasis in CUP usually reside at levels II (46.9%) and III (26.6%), with the majority having N2 (79%) and N3 (7%) disease. Previous studies have reported poor prognosis in the advanced nodal (N2b–N3) stage as compared to N1 and N2a combined.^{21,27} Our results have shown no significant survival difference between N1 and N2a and N2b and N3 disease (77.1% vs 61.8%, $p = 0.887$).

Distant metastasis in CUP has been reported in approximately 5 to 40% of patients within the first 2 years of treatment.²⁸ All the patients in our study who developed distant metastasis (7%) have depicted poor 5-year survival outcome ($p = 0.005$).

The detection of p16 or HPV in cervical LN metastasis helps in localizing the primary tumor site in the oropharyngeal region.^{29,30} Despite an extensive diagnostic work up, primary tumor remains undetected in 2 to 9% of patients.³¹ Therefore, we decided to evaluate the prognostic value of p16 immunopositivity in cervical LNs and other related clinicopathological factors in our cohort of CUP patients. Dixon et al. have reported a controversial association between LN positivity of p16 and survival outcome as predictor of OS. A recent study has demonstrated age and LN ratio as significant risk factors for survival and recurrence but failed to find a prognostic significance of p16 positivity in metastatic LNs. Human papillomavirus or p16 positivity are documented as the most important prognostic determinants in oropharyngeal and other head and neck squamous cell carcinomas^{13,32,33}. Similarly, Cho et al. have failed to determine a significant role of p16 in OS and DFS.³⁴ A recent analysis comprising 3 Radiation Therapy Oncology Group trials has shown p16+ rate of 19.2% in non-oropharyngeal primaries but could not find a convincing relationship between p16 and HPV.³⁵ Similarly, McDowell et al. have found p16+ cervical LNs in 31% of cutaneous SCC but could not establish significant clinical outcome.³⁶

Age and LNR have been identified as potential factors impacting survival outcome in head and neck cancer patients with high LNR adversely affecting survival in oral cavity tumors.³⁷ In our study population, age has not seemed to be a significant factor in terms of survival ($p > 0.05$). On the contrary, $LNR < 0.05$ has resulted in significantly improved OS (58% vs 43%, $p = 0.001$) and RFS (63% vs 49%, $p = 0.008$). In recent years, LNR has been attributed as an integral component of risk stratification in breast, colon, and gastric cancers. Similarly, an attempt has been made to incorporate LNR in head and neck cancers as a predictor of survival. Rudra et al. have emphasized the importance of LNR using a cutoff value of 0.20 in HNSCC. Sano et al. have also revealed a $LNR > 0.068$ as an independent prognostic factor for OS and PFS.^{38–43}

Our cohort had more than 50% of patients who were positive for p16 overexpression in LNs without true primary. This seems to be an interesting subset of patients having p16 positivity with no identifiable primary or HPV association. The results have shown improved 5-year OS and RFS in patients who were tested positive for p16 ($p = 0.008$). When subjected to Cox regression analysis, p16+ patients in our series without an identifiable primary tumor have depicted significantly improved RFS ($p = 0.021$). This finding may unfold avenues regarding this small group of p16+ and unidentifiable primary tumors depicting improved survival-related outcomes.

There is a dire need to stratify the subset of LN metastatic p16+ cases with unidentified primary. Furthermore, large scale studies may be required to prove our study results and provide an evidential statement about the prognostic significance of p16 overexpression in LNs of CUP.

Conclusions

Our study has suggested the prognostic significance of p16 overexpression in metastatic cervical LNs for true CUP. The presence has resulted in significantly improved RFS. Future large-scale studies are required for validation of our results.

Ethics Approval and Consent to Participate

Ethical exemption was granted by the ethics committee of the Medical University of Vienna.

Availability of Data and Materials

All data generated or analyzed during this study are included in this published article.

Authors' Contributions

B. E. and S.G.: conceptualization; S. J., J. P.: methodology; N. S.: software; A. S., M. G.: validation; N. S.: formal analysis; S. G.: investigation; S. J.: resources; S. G., S.J.: data curation; M. F.: writing and original draft preparation, B. E., M. F., J. P.: writing, review and editing; G. H.: visualization; B. E.: supervision.

Funding

This study was funded by the Medical University of Vienna.

Conflict of Interests

The authors have no conflict of interests to declare.

References

- 1 Miller FR, Karnad AB, Eng T, Hussey DH, Stan McGuff H, Otto RA. Management of the unknown primary carcinoma: long-term follow-up on a negative PET scan and negative panendoscopy. *Head Neck* 2008;30(01):28–34
- 2 Galloway TJ, Ridge JA. Management of Squamous Cancer Metastatic to Cervical Nodes With an Unknown Primary Site. *J Clin Oncol* 2015;33(29):3328–3337
- 3 Pavlidis N, Khaled H, Gaafar R. A mini review on cancer of unknown primary site: A clinical puzzle for the oncologists. *J Adv Res* 2015;6(03):375–382
- 4 Pavlidis N, Pentheroudakis G, Plataniotis G. Cervical lymph node metastases of squamous cell carcinoma from an unknown primary site: a favourable prognosis subset of patients with CUP. *Clin Transl Oncol* 2009;11(06):340–348
- 5 Guntinas-Lichius O, Peter Klussmann J, Dinh S, et al. Diagnostic work-up and outcome of cervical metastases from an unknown primary. *Acta Otolaryngol* 2006;126(05):536–544
- 6 Challis GB, Stam HJ. The spontaneous regression of cancer. A review of cases from 1900 to 1987. *Acta Oncol* 1990;29(05):545–550
- 7 van de Wouw AJ, Jansen RL, Speel EJ, Hillen HF. The unknown biology of the unknown primary tumour: a literature review. *Ann Oncol* 2003;14(02):191–196
- 8 Boscolo-Rizzo P, Da Mosto MC, Gava A, Marchiori C. Cervical lymph node metastases from occult squamous cell carcinoma: analysis of 82 cases. *ORL J Otorhinolaryngol Relat Spec* 2006;68(04):189–194
- 9 Koivunen P, Laranne J, Virtaniemi J, et al. Cervical metastasis of unknown origin: a series of 72 patients. *Acta Otolaryngol* 2002;122(05):569–574
- 10 Villeneuve H, Després P, Fortin B, et al. Cervical lymph node metastases from unknown primary cancer: a single-institution experience with intensity-modulated radiotherapy. *Int J Radiat Oncol Biol Phys* 2012;82(05):1866–1871
- 11 Haas I, Hoffmann TK, Engers R, Ganzer U. Diagnostic strategies in cervical carcinoma of an unknown primary (CUP). *Eur Arch Otorhinolaryngol* 2002;259(06):325–333
- 12 Müller von der Grün J, Bon D, Rödel C, Balermipas P. Patterns of care analysis for head & neck cancer of unknown primary site: a survey inside the German society of radiation oncology (DEGRO). *Strahlenther Onkol* 2018;194(08):750–758
- 13 O'Rourke MA, Ellison MV, Murray LJ, Moran M, James J, Anderson LA. Human papillomavirus related head and neck cancer survival: a systematic review and meta-analysis. *Oral Oncol* 2012;48(12):1191–1201
- 14 Dixon PR, Au M, Hosni A, et al. Impact of p16 expression, nodal status, and smoking on oncologic outcomes of patients with head and neck unknown primary squamous cell carcinoma. *Head Neck* 2016;38(09):1347–1353
- 15 Rassy E, Nicolai P, Pavlidis N. Comprehensive management of HPV-related squamous cell carcinoma of the head and neck of unknown primary. *Head Neck* 2019;41(10):3700–3711
- 16 Deng Z, Hasegawa M, Aoki K, et al. A comprehensive evaluation of human papillomavirus positive status and p16INK4a overexpression as a prognostic biomarker in head and neck squamous cell carcinoma. *Int J Oncol* 2014;45(01):67–76

- 17 Mork J, Lie AK, Glattre E, et al. Human papillomavirus infection as a risk factor for squamous-cell carcinoma of the head and neck. *N Engl J Med* 2001;344(15):1125–1131
- 18 D'Souza G, Kreimer AR, Viscidi R, et al. Case-control study of human papillomavirus and oropharyngeal cancer. *N Engl J Med* 2007;356(19):1944–1956
- 19 Lydiatt WM, Patel SG, O'Sullivan B, et al. Head and Neck cancers—major changes in the American Joint Committee on cancer eighth edition cancer staging manual. *CA Cancer J Clin* 2017;67(02):122–137
- 20 Keller LM, Galloway TJ, Holdbrook T, et al. p16 status, pathologic and clinical characteristics, biomolecular signature, and long-term outcomes in head and neck squamous cell carcinomas of unknown primary. *Head Neck* 2014;36(12):1677–1684
- 21 Axelsson L, Nyman J, Haugen-Cange H, et al. Prognostic factors for head and neck cancer of unknown primary including the impact of human papilloma virus infection. *J Otolaryngol Head Neck Surg* 2017;46(01):45
- 22 Jensen DH, Hedback N, Specht L, et al. Human papillomavirus in head and neck squamous cell carcinoma of unknown primary is a common event and a strong predictor of survival. *PLoS One* 2014;9(11):e110456
- 23 Schroeder L, Wichmann G, Willner M, et al. Antibodies against human papillomaviruses as diagnostic and prognostic biomarker in patients with neck squamous cell carcinoma from unknown primary tumor. *Int J Cancer* 2018;142(07):1361–1368
- 24 Graboyes EM, Sinha P, Thorstad WL, Rich JT, Haughey BH. Management of human papillomavirus-related unknown primaries of the head and neck with a transoral surgical approach. *Head Neck* 2015;37(11):1603–1611
- 25 Bersani C, Sivars L, Haeggblom L, et al. Targeted sequencing of tonsillar and base of tongue cancer and human papillomavirus positive unknown primary of the head and neck reveals prognostic effects of mutated FGFR3. *Oncotarget* 2017;8(21):35339–35350
- 26 Sivars L, Näsman A, Tertipis N, et al. Human papillomavirus and p53 expression in cancer of unknown primary in the head and neck region in relation to clinical outcome. *Cancer Med* 2014;3(02):376–384
- 27 Hung YH, Liu SA, Wang CC, Wang CP, Jiang RS, Wu SH. Treatment outcomes of unknown primary squamous cell carcinoma of the head and neck. *PLoS One* 2018;13(10):e0205365
- 28 Adams JR, O'Brien CJ. Unknown primary squamous cell carcinoma of the head and neck: a review of diagnosis, treatment and outcomes. *Asian J Surg* 2002;25(02):188–193
- 29 Begum S, Gillison ML, Ansari-Lari MA, Shah K, Westra WH. Detection of human papillomavirus in cervical lymph nodes: a highly effective strategy for localizing site of tumor origin. *Clin Cancer Res* 2003;9(17):6469–6475
- 30 Zhang MQ, El-Mofty SK, Dávila RM. Detection of human papillomavirus-related squamous cell carcinoma cytologically and by in situ hybridization in fine-needle aspiration biopsies of cervical metastasis: a tool for identifying the site of an occult head and neck primary. *Cancer* 2008;114(02):118–123
- 31 Le NS, Janik S, Simmel H, Erovic BM. Bilateral vs ipsilateral adjuvant radiotherapy in patients with cancer of unknown primary of the head and neck: An analysis of the clinical outcome and radiation-induced side effects. *Head Neck* 2019;41(06):1785–1794
- 32 Ang KK, Harris J, Wheeler R, et al. Human papillomavirus and survival of patients with oropharyngeal cancer. *N Engl J Med* 2010;363(01):24–35
- 33 Sedghizadeh PP, Billington WD, Paxton D, et al. Is p16-positive oropharyngeal squamous cell carcinoma associated with favorable prognosis? A systematic review and meta-analysis. *Oral Oncol* 2016;54:15–27
- 34 Cho WK, Roh JL, Cho KJ, Choi SH, Nam SY, Kim SY. Predictors of survival and recurrence after primary surgery for cervical metastasis of unknown primary. *J Cancer Res Clin Oncol* 2020;146(04):925–933
- 35 Chung CH, Zhang Q, Kong CS, et al. p16 protein expression and human papillomavirus status as prognostic biomarkers of non-oropharyngeal head and neck squamous cell carcinoma. *J Clin Oncol* 2014;32(35):3930–3938
- 36 McDowell LJ, Young RJ, Johnston ML, et al. p16-positive lymph node metastases from cutaneous head and neck squamous cell carcinoma: No association with high-risk human papillomavirus or prognosis and implications for the workup of the unknown primary. *Cancer* 2016;122(08):1201–1208
- 37 Ebrahimi A, Clark JR, Zhang WJ, et al. Lymph node ratio as an independent prognostic factor in oral squamous cell carcinoma. *Head Neck* 2011;33(09):1245–1251
- 38 Patel SG, Amit M, Yen TC, et al; International Consortium for Outcome Research (ICOR) in Head and Neck Cancer. Lymph node density in oral cavity cancer: results of the International Consortium for Outcomes Research. *Br J Cancer* 2013;109(08):2087–2095
- 39 Wang YL, Feng SH, Zhu J, et al. Impact of lymph node ratio on the survival of patients with hypopharyngeal squamous cell carcinoma: a population-based analysis. *PLoS One* 2013;8(02):e56613
- 40 Rudra S, Spiotto MT, Witt ME, Blair EA, Stenson K, Haraf DJ. Lymph node density—prognostic value in head and neck cancer. *Head Neck* 2014;36(02):266–272
- 41 Ong W, Zhao R, Lui B, et al. Prognostic significance of lymph node density in squamous cell carcinoma of the tongue. *Head Neck* 2016;38(Suppl 1):E859–E866
- 42 Prabhu RS, Hanasoge S, Magliocca KR, et al. Lymph node ratio influence on risk of head and neck cancer locoregional recurrence after initial surgical resection: implications for adjuvant therapy. *Head Neck* 2015;37(06):777–782
- 43 Sano D, Yabuki K, Takahashi H, et al. Lymph node ratio as a prognostic factor for survival in patients with head and neck squamous cell carcinoma. *Auris Nasus Larynx* 2018;45(04):846–853 [published correction appears in *Auris Nasus Larynx*. 2019 Oct;46(5):818–819]