



Case report

Holmes' or functional tremor?

Tommaso Bocci^{a,b,*}, Gianluca Ardolino^b, Laura Parenti^a, Davide Barloscio^a, Anna De Rosa^c, Alberto Priori^d, Ferdinando Sartucci^{a,e}

^a Department of Clinical and Experimental Medicine, Section of Neurophysiopathology, Pisa University Medical School, Pisa, Italy

^b Fondazione IRCCS Ospedale Maggiore Policlinico, Milan, Italy

^c Department of Clinical and Experimental Medicine, Unit of Neurology, Pisa University Medical School, Pisa, Italy

^d Department of Health Sciences, University of Milan & Ospedale San Paolo, Milan, Italy

^e Neuroscience Institute, CNR, Pisa, Italy



ARTICLE INFO

Article history:

Received 18 September 2017

Received in revised form 27 March 2018

Accepted 30 March 2018

Available online 21 April 2018

Keywords:

Holmes tremor

Rubral tremor

Functional tremor

Psychogenic tremor

Surface polmyography

Neurophysiology

ABSTRACT

Objective: Holmes tremor is a rare kind of hyperkinetic movement disorder, clinically characterized by irregular, monolateral, high-amplitude jerks, sharing a quite similar frequency with those observed in Parkinson's disease; its generation likely relies on a combined involvement of cerebello-thalamic and nigrostriatal pathways.

Methods: We report the case of a man with a combined resting-postural-kinetic tremor. Neuroimaging revealed an intracranial dermoid cyst at the right pontocerebellar angle with brainstem dislocation. We performed an extensive electrophysiological assessment from the extensor digitorum communis (EDC) and flexor carpi radialis (FCR) muscles.

Results: Both the spontaneous variability of tremor frequency and frequency entrainment argued against an organic aetiology. Polymyography revealed: 1) a paradoxical increase of tremor amplitude with mass loading; 2) jerks' synchronization between antagonistic muscles during voluntary contralateral motor performances; 3) tremor inhibition while asking the patient to make a ballistic movement.

Conclusions: We suggest a complete psychogenic genesis or, at least in part, a possible co-existence of a rubral tremor with functional traits.

Significance: Here, we propose a simple and fast test battery for an early diagnosis of functional tremor. Our results prompt further studies to re-define electrodiagnostic criteria in hyperkinetic movement disorders, possibly updating the floating border between organic and psychogenic disease.

© 2018 International Federation of Clinical Neurophysiology. Published by Elsevier B.V. This is an open access article under the CC BY-NC-ND license (<http://creativecommons.org/licenses/by-nc-nd/4.0/>).

1. Introduction

Holmes tremor (also known as rubral, thalamic or midbrain tremor) is a rare kind of hyperkinetic movement disorder, clinically characterized by irregular, monolateral, high-amplitude jerks, sharing a quite similar frequency with those observed in Parkinson's disease, usually less than 4.5 Hz; it is present at rest, exacerbated with posture and additionally intensified with action (Deuschl et al., 1996; Deuschl et al., 1998). It may be caused by mesencephalic lesions, ranging from midbrain infarctions to traumatic injury and neoplasias (Raina et al., 2016; Spengos et al., 2005); it has also been reported after thalamic stroke, likely emerging from lesions upstream of the rubral and nigral outflow system.

Probably, lesions of the red nucleus itself are not sufficient for its production (Samie et al., 1990). The latency from lesion to tremor onset is usually about two months and its generation likely relies on a combined involvement of both the dopaminergic nigrostriatal system and the cerebello-thalamo-cortical pathways; however, pathophysiologic heterogeneity may account for a variable delay, as supported by DaTSCAN SPECT studies as well as by different therapeutic responses to levodopa, with only mild to moderate improvement (Gajos et al., 2010; Raina et al., 2016). Delayed tremor onset may also suggest a secondary neural degeneration along the dentate-rubro-olivary pathways (Lekoubou et al., 2010).

Distinction between organic and functional (psychogenic) tremor still remains a challenge for neurologists, although a careful clinical evaluation is sometimes suggestive. Here, we describe a peculiar case of Holmes tremor, in a patient with a dermoid cyst at the right pontocerebellar angle, where both clinical and neurophysiological features strongly suggested a functional origin of the disorder.


* Corresponding author at: Pisa University Medical School, Department of Clinical and Experimental Medicine, Cisanello Section of Neurophysiopathology, Via Paradisa, n. 2; I-56126, Pisa, Italy.

E-mail address: bocci.tommaso@gmail.com (T. Bocci).

2. Case report

We report the case of a right-handed man referred to our attention because of a low-frequency tremor at the right hand (see Video 1). He was 43 years old at the time of first clinical evaluation; he presented with a sudden-onset, combined resting-postural-kinetic tremor. He also complained of right arm hyposthenia. The tremor worsened with posture and voluntary movements, but it was abolished with sleep. Neurological examination did not show bradykinesia, hypertonia or cerebellar signs. The tremor did not involve the head or the trunk and it was not significantly modified by mental counting.

Magnetic Resonance Imaging (MRI), performed before our examination because of the occurrence of dizziness and postural instability, revealed a bulky intracranial dermoid cyst at the right pontocerebellar angle with severe brainstem and midbrain dislocation (see Fig. 1-A). The lesion had been diagnosed two years earlier and operated about a year before, although a significant residual mass still remained. The tremor appeared six months before our examination, about six months after surgical procedure. Despite the discrepancy with MRI findings, both the spontaneous variability of tremor frequency and frequency entrainment induced by contralateral rhythmic tasks argue against a complete organic etiology



(Video 1. Frequency entrainment induced by contralateral rhythmic tasks; note also that contralateral movements completely arrest tremor for a while.)

Moreover, there was no evidence of myorhythmia, a repetitive, rhythmic and slow movement affecting cranial muscles, usually associated with lesions involving the brainstem, thalamus, or other diencephalic structures (Baizabal-Carvalho et al., 2015).

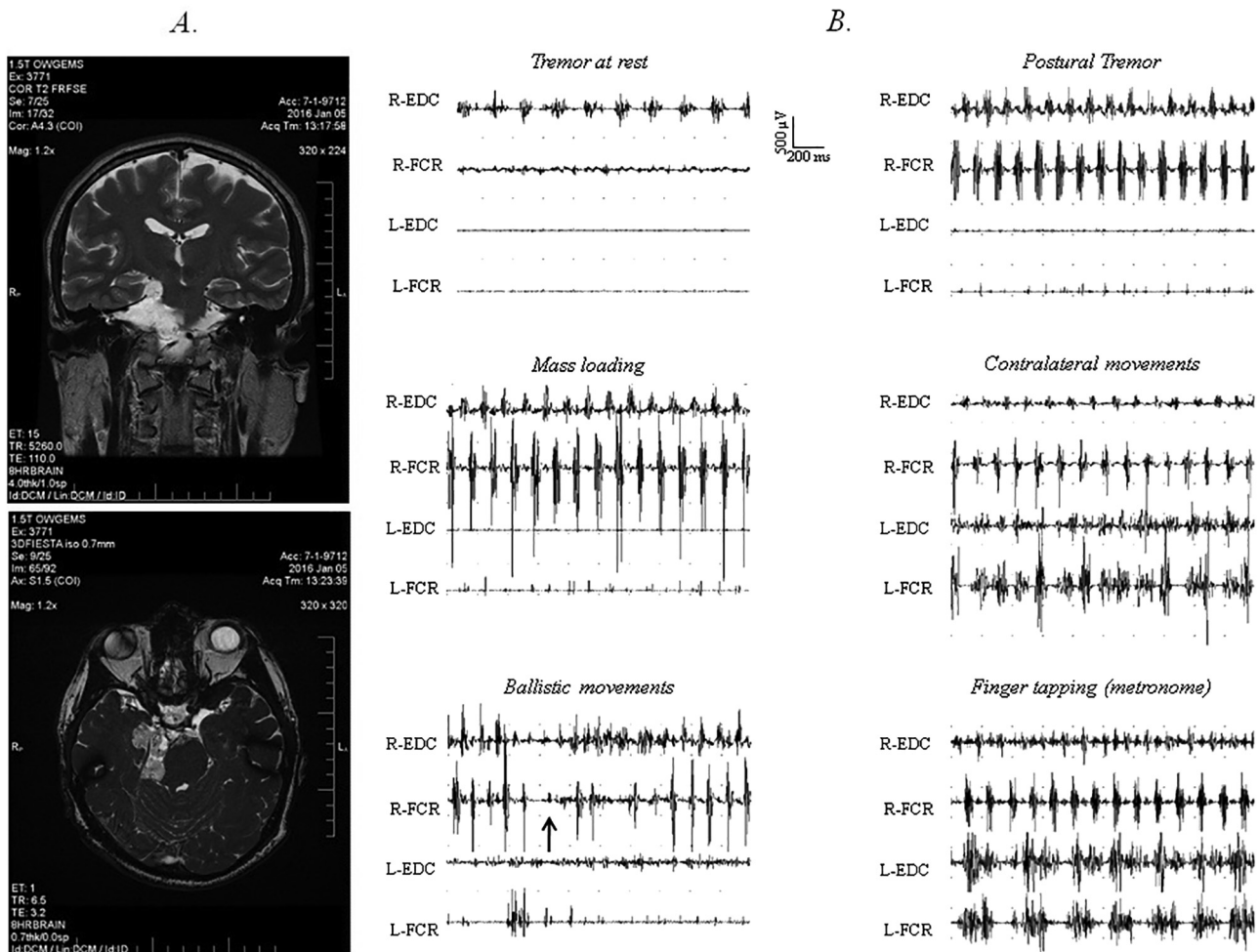


Fig. 1. Neuroimaging and surface electromyography. **A** – MRI scan revealed an intracranial dermoid cyst causing severe midbrain and pons dislocation. **B** – Surface EMG was evaluated in six different conditions: at rest or with arms outstretched at shoulder level (top traces), during mass loading or contralateral movements (at the middle), during ballistic movements or making a finger tapping by synchronizing contralateral movements with a 3 Hz metronome (bottom traces). Note the different frequency between postural and rest jerks, the increase of tremor amplitude with mass loading, as well as jerks' synchronization during voluntary contralateral movements. Both tremor inhibition and co-activation sign (black arrow) appeared while asking the patient to make a ballistic movement (R = right; L = left; EDC = extensor digitorum communis; FCR = flexor carpi radialis).

Surface polymyography from the extensor digitorum communis (EDC) and flexor carpi radialis (FCR) muscles was bilaterally performed. Recordings were made with arms relaxed, with arms outstretched at shoulder level without or with a 500 g mass attached to the wrist (“mass loading”), during voluntary contralateral motor activation and while performing ballistic movements (Deuschl et al., 1996; Schwingenschuh et al., 2016). We also performed tapping tasks asking to the patient to use the index finger of the left hand to tap in time with a metronome at rates of 1, 3 and 5 Hz (Schwingenschuh et al., 2016; Zeuner et al., 2003). For ballistic movements, the patient was instructed to reach with the index finger of the left hand the examiner’s index finger and follow it as fast as possible when the examiner changed position. The tremor was recorded and analyzed for 60 s in each condition; EMG signals were amplified, band-pass filtered (30 Hz–10,000 Hz) and sampled at 2000 Hz. Brainstem reflexes were assessed: we evaluated the recovery cycle of the blink reflex (BR) from the orbicularis oculi muscle bilaterally, using pairs of surface electrodes with the active electrode over the mid-lower eyelid and the reference a few centimeters laterally to the outer canthus.

Surface electromyography showed an alternating pattern, with a different frequency between postural and rest jerks (Fig. 1-B); this paradoxical variation has not been described before, although it may be related to a combined involvement of cerebello-thalamic and nigrostriatal pathways as occurs in rubral tremor. Frequency was about 5 Hz at rest, with a significant increase in amplitude with arms outstretched at shoulder level. Accordingly, we have analyzed the difference at the frequency domain between rest and postural tremor (5 vs. 8 Hz), as well as between the postural condition and finger tapping session (8 vs. 6.0–6.5 Hz); curiously, the difference of tremor frequencies is greater than 1.5 Hz and these frequencies have no harmonic link. Moreover, as described in functional tremor, polymyography also revealed: 1) a paradoxical increase of tremor amplitude with mass loading; 2) jerks’ synchronization between antagonistic muscles during voluntary contralateral motor performance and 3) tremor inhibition while asking to the patient to make a ballistic movement (Schwingenschuh et al., 2016; Zeuner et al., 2003). Co-activation sign was also present: together with a transient arrest during ballistic movements, a tonic discharge of antagonistic muscles approximately 300 ms before tremor onset was observed (Fig. 1-B). The BR habituation was preserved. Levodopa therapy, with a daily dose of 300 mg, was then started without any significant improvement within a six months follow-up.

3. Discussion

To our knowledge, intracranial dermoid cyst has never been reported elsewhere as a cause of rubral tremor. Diagnosis of Holmes tremor is supported both by case history and some clinical features (tremor’s frequency and increase in amplitude induced by posture). However, despite MRI, a complete organic etiology was questionable. In particular, based on clinical and neurophysiologi-

cal findings, we may suggest a functional origin of the tremor or, at least, a possible co-existence of a rubral tremor with psychogenic traits, an association never described before. Moreover, the lack of cerebellar signs and failed response to levodopa strongly support this hypothesis.

In the last twenty years, only few papers have extensively investigated the neurophysiology of functional tremor (Schwingenschuh et al., 2016; Tinazzi et al., 2014; Zeuner et al., 2003). Overall, a standardized protocol for the diagnosis of tremor does not exist so far. Tremor diagnosis should be based on a careful clinical, neurophysiological and radiological assessment; here, we propose a simple and fast test battery for an early diagnosis of functional tremor. This is of critical importance for the choice of putative pharmacological therapies. Our results prompt further studies to integrate clinical and electrodiagnostic criteria in the whole field of hyperkinetic movement disorders, exploring the floating border between organic and functional disease.

Conflict of interest statement

None.

References

- Baizabal-Carvalho, J.F., Cardoso, F., Jankovic, J., 2015. Myorhythmia: phenomenology, etiology, and treatment. *Mov. Disord.* 30, 171–179.
- Deuschl, G., Krack, P., Lauk, M., Timmer, J., 1996. Clinical neurophysiology of tremor. *J. Clin. Neurophysiol.* 13, 110–121.
- Deuschl, G., Bain, P., Brin, M., 1998. Consensus statement of the Movement Disorder Society on Tremor, Ad Hoc Scientific Committee. *Mov. Disord.* 13, 2–23.
- Gajos, A., Bogucki, A., Schinwelski, M., Sołtan, W., Rudzińska, M., Budrewicz, S., Koszewicz, M., Majos, A., Górska-Chrzastek, M., Bieñkiewicz, M., Kuśmierk, J., Sławek, J., 2010. The clinical and neuroimaging studies in Holmes tremor. *Acta Neurol. Scand.* 122, 360–366.
- Lekoubou, A., Njououguep, R., Kuate, C., Kengne, A.P., 2010. Cerebral toxoplasmosis in Acquired Immunodeficiency Syndrome (AIDS) patients also provides unifying pathophysiologic hypotheses for Holmes tremor. *BMC Neurol.* 10, 37.
- Raina, G.B., Cersosimo, M.G., Folgar, S.S., Giugni, J.C., Calandra, C., Paviolo, J.P., Tkachuk, V.A., Zuñiga Ramirez, C., Tschopp, A.L., Calvo, D.S., Pellene, L.A., Uribe Roca, M.C., Velez, M., Giannula, R.J., Fernandez Pardo, M.M., Micheli, F.E., 2016. Holmes tremor: clinical description, lesion localization, and treatment in a series of 29 cases. *Neurology* 86, 931–938.
- Samie, M.R., Selhorst, J.B., Koller, W.C., 1990. Post-traumatic midbrain tremors. *Neurology* 40, 62–66.
- Schwingenschuh, P., Saifee, T.A., Katschnig-Winter, P., Macerollo, A., Koegl-Wallner, M., Culea, V., Ghadery, C., Hofer, E., Pendl, T., Seiler, S., Werner, U., Frantl, S., Maurits, N.M., Tijssen, M.A., Schmidt, R., Rothwell, J.C., Bhatia, K.P., Edwards, M. J., 2016. Validation of “laboratory-supported” criteria for functional (psychogenic) tremor. *Mov. Disord.* 31, 555–562.
- Spengos, K., Wohrle, J.C., Tsvigoulis, G., Stouraitis, G., Vemmos, K., Zis, V., 2005. Bilateral paramedian midbrain infarct: an uncommon variant of the “top of the basilar” syndrome. *J. Neurol. Neurosurg. Psychiatry* 76, 742–743.
- Tinazzi, M., Fasano, A., Peretti, A., Bove, F., Conte, A., Dallochio, C., Arbasino, C., Defazio, G., Fiorio, M., Berardelli, A., 2014. Tactile and proprioceptive temporal discrimination are impaired in functional tremor. *PLoS One* 9, e102328.
- Zeuner, K.E., Shoge, R.O., Goldstein, S.R., Dambrosia, J.M., Hallett, M., 2003. Accelerometry to distinguish psychogenic from essential or parkinsonian tremor. *Neurology* 61, 548–550.