


CLINICAL REPORT

Novel mutations in the *PITX2* gene in Pakistani and Mexican families with Axenfeld-Rieger syndrome

Valeria Lo Faro^{1,2}  | Sorath N. Siddiqui³ | Muhammad I. Khan⁴ |
Cristina Villanueva-Mendoza⁵ | Vianney Cortés-González⁵ | Nomdo Jansonius² |
Arthur A. B. Bergen^{1,6,7} | Shazia Micheal¹

¹Department of Clinical Genetics, University Medical Center (UMC), University of Amsterdam (UvA), Amsterdam, The Netherlands

²Department of Ophthalmology, University Medical Center Groningen (UMCG), University of Groningen (RUG), Groningen, The Netherlands

³Department of Pediatric Ophthalmology and Strabismus, Al-Shifa Eye Trust Hospital, Rawalpindi, Pakistan

⁴Department of Human Genetics, Donders Institute for Brain, Cognition and Behaviour, Radboud UMC, Nijmegen, The Netherlands

⁵Department of Genetics, Asociación Para Evitar la Ceguera en México, México, México

⁶Department of Ophthalmology, Universitair Medische Centre (UMC), University of Amsterdam (UvA), Amsterdam, The Netherlands

⁷The Netherlands Institute for Neurosciences (NIN-KNAW), Amsterdam, The Netherlands

Correspondence

Arthur A. B. Bergen, Department of Clinical Genetics, University Medical Center (UMC), University of Amsterdam (UvA), Amsterdam, The Netherlands
Email: aabergen@amc.uva.nl

Funding information

This study has received funding from the European Union Horizon 2020 research and innovation program under the Marie Skłodowska-Curie grant agreement No.675033 (EGRET plus). The funder had no role in study design, data collection and analysis, decision to publish, or preparation of the manuscript.

Abstract

Purpose: Axenfeld-Rieger syndrome (ARS) is a rare autosomal dominant disorder that affects the anterior segment of the eye. The aim of this study was to examine the *PITX2* gene to identify possible novel mutations in Pakistani and Mexican families affected by the ARS phenotype.

Methods: Three unrelated probands with a diagnosis of ARS were recruited for this study. Genomic DNA was isolated from the peripheral blood of the probands and their family members. Polymerase chain reaction and Sanger sequencing were used for the analysis of coding exons and the flanking intronic regions of the *PITX2* gene. Bioinformatics tools and database (VarSome, Provean, and MutationTaster, SIFT, PolyPhen-2, and HOPE) were evaluated to explore missense variants.

Results: We identified novel heterozygous variations in the *PITX2* gene that segregated with the ARS phenotype within the families. The variant NM_153426.2(*PITX2*):c.226G > T or p.(Ala76Ser) and the mutation NM_153426.2(*PITX2*):c.455G > A or p.(Cys152Tyr) were identified in two Pakistani pedigrees, and the mutation NM_153426.2(*PITX2*):c.242_265del or p.(Lys81_Gln88del), segregated in a Mexican family.

Conclusion: Our study extends the spectrum of *PITX2* mutations in individuals with ARS, enabling an improved diagnosis of this rare but serious syndrome.

KEYWORDS

anterior segment dysgenesis, Axenfeld-Rieger, mutations, *PITX2*

This is an open access article under the terms of the Creative Commons Attribution-NonCommercial-NoDerivs License, which permits use and distribution in any medium, provided the original work is properly cited, the use is non-commercial and no modifications or adaptations are made.

© 2020 The Authors. *Molecular Genetics & Genomic Medicine* published by Wiley Periodicals, Inc.

1 | INTRODUCTION

Abnormal development of the anterior segment of the eye, which includes the cornea, iris, lens, ciliary body, trabecular meshwork, and Schlemm canal, is clinically defined as anterior segment dysgenesis disorder (ASD; OMIM 107,250). ASD shows different clinical presentation, and many subtypes have been described, including aniridia-like phenotype, iris hypoplasia, Peters anomaly, Axenfeld-Rieger syndrome (ARS; OMIM 180,500), Axenfeld and Rieger anomalies, and iridogoniodysgenesis. ARS is considered a rare syndrome, as it shows a prevalence of 1/200,000 individuals, and it includes a phenotypically heterogeneous group of disorders, where ocular developmental anomalies affect the cornea, iris, and anterior chamber angle. Specifically, the major clinical ocular phenotypes in patients affected by this syndrome include posterior embryotoxon, iridocorneal adhesions, iris stromal hypoplasia, corectopia, polycoria, and ectropion uveae. The nonocular systemic defects associated with ARS include dental (e.g., hypodontia, microdontia), craniofacial malformations (e.g., hypertelorism, prominent forehead, telecanthus), redundant periumbilical skin, and umbilical hernia (Idrees, Vaideanu, Fraser, Sowden, & Khaw, 2006; Intarak et al., 2018; Reis et al., 2012; Weisschuh, De Baere, Wissinger, & Tümer, 2011). Patients with this condition often have increased intraocular pressure (IOP) especially during childhood, and elevated IOP is associated with an increased risk of developing glaucoma. This is triggered by alterations of the iridocorneal angle drainage, causing an abnormal flow of the intraocular fluid through the anterior segment and leading to glaucoma (Protas et al., 2017; Strungaru, Hermina Strungaru, Dinu, & Walter, 2007; Tanwar, Dada, Axenfeld-Rieger, & Associated, 2010).

ARS is inherited in an autosomal dominant manner and has complete penetrance. Two loci have been reported to be associated with ARS at the chromosome regions of 4q25 for the gene Pituitary Homeobox 2 (*PITX2*, OMIM 601,542) and 6p25 for the gene encoding Forkhead Box C1 (*FOXC1*, OMIM 601,090). While mutations in the *PITX2* gene are more likely associated with ocular, dental, and umbilical anomalies, mutations in *FOXC1* appear to be more correlated with isolated ocular or ocular, heart, and/or hearing defects (D'haene et al., 2011; Hjalt & Semina, 2005; Strungaru et al., 2007).

Numerous heterozygous missense and nonsense mutations, as well as deletions and duplications, have recently been identified among the two developmental transcription factor genes, especially in Caucasian populations (Alward, 2000; Brooks et al., 2004; Seifi & Walter, 2018a; Titheradge et al., 2014; Tümer & Bach-Holm, 2009; Vieira et al., 2006; Zhang et al., 2019). In non-Caucasian patients with ARS from Mexico, mutations in the *PITX2* genes have already

been reported in the literature (Hernández-Martínez et al., 2018).

The purpose of this study was to identify the causal mutations in the *PITX2* gene in patients affected with ARS, in Pakistani and Mexican families.

2 | MATERIALS AND METHODS

2.1 | Subjects

Ethical approval for this study was obtained from the ethical committee of the Institutional Review Board of the Pediatric Glaucoma Department of Al-Shifa Trust Eye Hospitals in Rawalpindi (Pakistan) and the Genetics Department of the Association to prevent blindness in Mexico (Mexico). This study was performed in compliance with the Declaration of Helsinki. Written informed consent was obtained from all patients and their parents. Unrelated probands and their family members affected by ARS from Pakistan and Mexico were included in this study. Complete ophthalmologic examinations were performed in all individuals. For visualization of the optic disk, biomicroscopy via slit lamp was used, whereas for the iridocorneal angle, gonioscopy was performed. Measurements of visual acuity and IOP were also collected. Applanation tonometry was used to measure IOP.

2.2 | Genetic Screening

Genomic DNA of probands and their family members was extracted from EDTA blood samples using a QIAamp DNA Blood Midi Kit (Qiagen, Hilden, Germany). Primers flanking the entire coding sequence were designed using the Primer Designing Tool Primer 3 of NCBI, available at <https://www.ncbi.nlm.nih.gov/tools/primer-blast/> and used for the genetic analysis of *PITX2* (the sets of primers are available in Appendix 1). Polymerase chain reaction (PCR) was conducted on the coding exons and exon/intron junctions of the *PITX2* gene. Direct DNA sequencing of *PITX2* PCR products was performed using ABI BigDye chemistry (Applied Biosystems Inc., Foster City, CA, USA) and the ABI 3,730 Sequencer (Applied Biosystems, Inc.). DNA sequencing results were aligned against the gene reference sequence of *PITX2* (NM_153426.2). The alignment with the reference was made using CodonCode Aligner (version 6.1) (CodonCode Co., Centerville, MA, USA), and to identify pathogenic mutations, we queried the Genome Aggregation Database (gnomAD) (<http://gnomad.broadinstitute.org/>).

Alamut Visual (alamut.interactive-biosoftware.com, version 2.7.1, 2015) was used for the annotation and prediction of the functional impact of the identified variants at both the genomic and protein levels. Alamut® Visual comprises

many missense variant pathogenicity prediction tools and algorithms, such as Sorting Intolerant From Tolerant (SIFT) and Polymorphism Phenotyping (PolyPhen-2). Additionally, MutationTaster, VarSome, DEOGEN2, EIGEN, PrimateAI, Provean, HOPE, the Grantham score and PhyloP scores were consulted and evaluated to establish the effect of changed nucleotide and amino acids (Flanagan, Patch, & Ellard, 2010; Kopanos et al., 2019; Venselaar, te Beek, Kuipers, Hekkelman, & Vriend, 2010).

3 | RESULTS

Brief details of variants and phenotypic features of patients identified in our study are summarized in Table 1.

The proband (II:1), from Pakistani family 1, was a 14-year-old male patient with ARS. He was initially diagnosed with glaucoma and underwent a trabeculectomy to control IOP. The initial IOP of his right and left eye were 45 and 34 mmHg, respectively. His visual acuity in the right eye was restricted to counting fingers. He also had corectopia and corneal opacity, both bilateral. His father and younger brother also had glaucoma with high IOP, polycoria, and corneal edema. Systemic examination of all three affected individuals of the family showed typical ARS features, such as telecanthus, a thin upper lip, a lower protruding lip, and dental anomalies. In all the affected members, the protuberant umbilicus was present.

Sequence analysis of the *PITX2* gene in the proband revealed a heterozygous missense variant NM_153426.2 (*PITX2*):c.226G > T or p.(Ala76Ser), genomic position 4:111,542,484(C > A), segregating with the ARS phenotype within the family (Figure 1). The unaffected mother (I:2) has a normal DNA sequence. The PhyloP score for this particular variant was 0.76 and the amino acid conservation was corroborated by the Grantham distance of 99. This variant is absent in the publicly available GnomAD exomes and GnomAD genomes. For in silico analysis (DEOGEN2, EIGEN, MutationTaster, PrimateAI, Provean, and SIFT) the variant is predicted to be polymorphic, and according to the HOPE program, the mutant residue is larger and less hydrophobic than the wild-type residue, but was not able to destabilize the protein functionality.

In family 2, the proband (II:1) was an 11-year-old male patient from Mexico. His clinical history showed that he had photophobia since birth, and he was initially diagnosed with congenital glaucoma. He received medical treatment for glaucoma until the age of 4 when a trabeculectomy was performed on both eyes. He also had umbilical surgery at the age of 6 months. His best-corrected visual acuity for the right eye was 20/40, and for the left eye, light perception only. The IOP for the right eye was 18 mmHg, and for the left eye, it was 55 mmHg. Ophthalmic examination of his right eye

TABLE 1 DETAILS OF *PITX2* GENE VARIANTS AND PHENOTYPES OF PATIENTS WITH ARS

| Family | Probands (n) | Amino Acid | cDNA | PhyloP | Grantham distance | Clinical Features |
|--------|--------------|----------------|--------------|--------|-------------------|--|
| 1 | I:1 | Ala76Ser | c.226G > T | 0.76 | 99 | Glaucoma, corectopia, corneal opacity, polycoria, corneal edema, telecanthus, thin upper lip, lower protruding lip, protuberant umbilicus, and dental anomalies. |
| | II:1 | Ala76Ser | c.226G > T | 0.76 | 99 | |
| | II:2 | Ala76Ser | c.226G > T | 0.76 | 99 | |
| 2 | I:2 | Lys81_Gln88del | c.242_265del | / | / | Posterior embryotoxon in both eyes, iris hypoplasia in the right eye, polycoria in the left eye, and long iris processes at the anterior chamber angle in both eyes. |
| | II:1 | Lys81_Gln88del | c.242_265del | / | / | Congenital glaucoma, photophobia, corneal opacity with edema and vascularization, posterior embryotoxon, corectopia, ectropion uveae, irregular iris, facial dysmorphism, flattening of the mid-face, thin superior lip, microdontia, and missing teeth. |
| 3 | I:1 | Cys152Tyr | c.455G > A | 2.796 | 194 | Glaucoma, polycoria, corectopia, posterior embryotoxon, protuberant umbilicus, and abnormal dentition. |
| | II:1 | Cys152Tyr | c.455G > A | 2.796 | 194 | |
| | II:2 | Cys152Tyr | c.455G > A | 2.796 | 194 | |

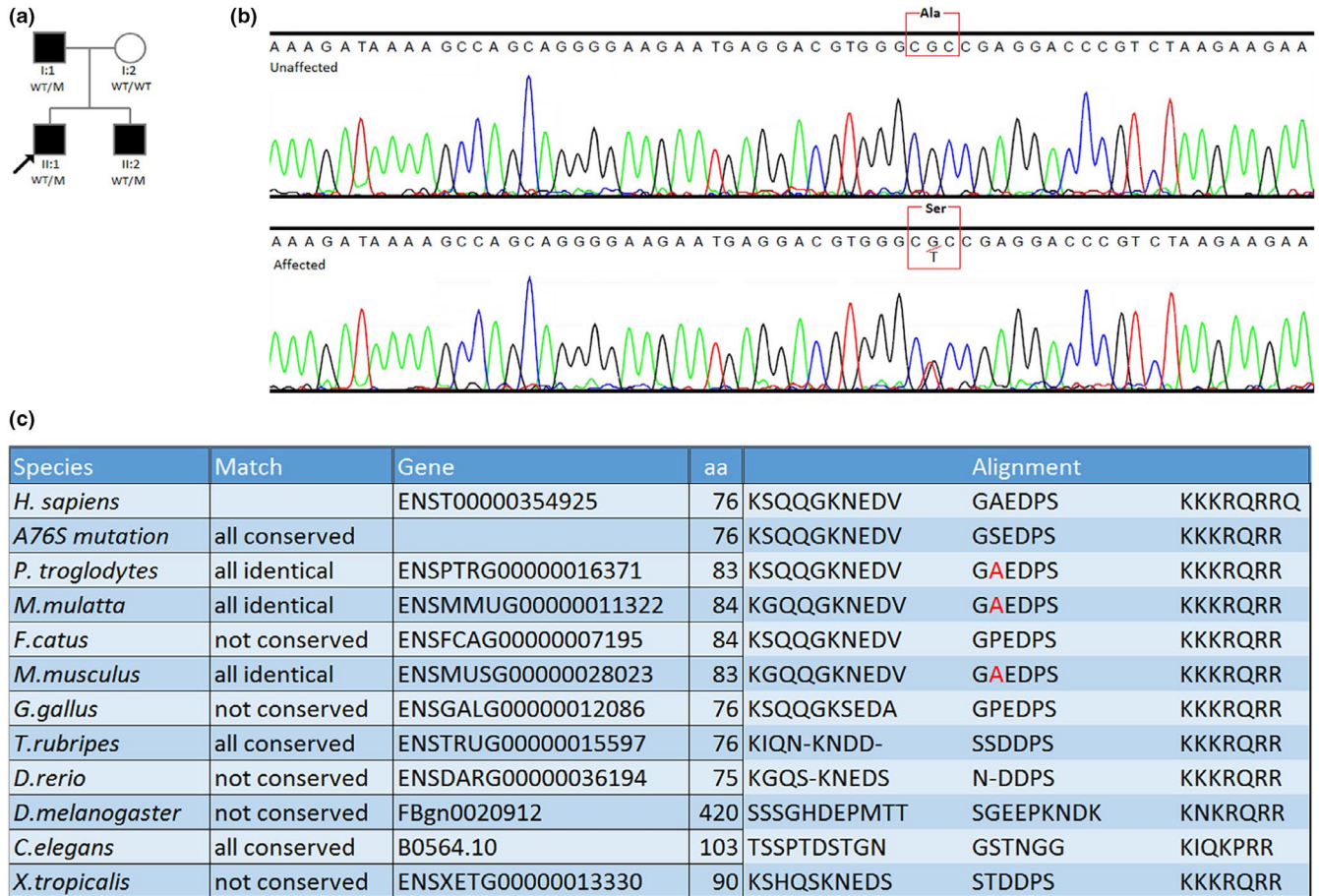


FIGURE 1 Family 1 from Pakistan with ARS. (a) Pedigree showing the segregation of the variant NM_153426.2(*PITX2*):c.226G > T or p.(Ala76Ser) in Pakistani family in the *PITX2* gene. The arrow indicates the proband. (b) Sequencing chromatogram of reverse sequence of *PITX2* for the homozygous wild-type and heterozygous carrier, with alanine replaced with serotonin in the affected member. (c) Conservation analysis of the proteins surrounding the variant p.(Ala76Ser) in various species

showed corneal opacity, a posterior embryotoxon, corectopia, ectropion uveae, and an irregular iris. The left eye was larger than the right eye, presenting with a generalized corneal opacity with edema and vascularization. Systemic examination showed facial dysmorphism, flattening of the mid-face, thin superior lip, microdontia, and absence of some teeth. His mother (I:2) had posterior embryotoxon in both eyes, iris hypoplasia in the right eye, polycoria in the left eye, and long iris processes at the anterior chamber angle in both eyes. No protuberant umbilicus was evaluated.

The proband was found to be heterozygous for the in-frame deletion pathogenic variant NM_153426.2(*PITX2*):c.242_265del or p.(Lys81_Gln88del), starting from the genomic position 4:111,542,445 in the *PITX2* gene. Segregation analysis revealed that this particular pathogenic variant was inherited from the affected mother (I:2) (Figure 2). In silico analysis (VarSome, Provean, and MutationTaster) of the pathogenic variant predicted it to be disease causing and deleterious. The identified pathogenic variant is absent in the GnomAD exomes and GnomAD genomes.

Family 3 was from Pakistan, comprising the proband and her affected sister and father. The proband (II:1) was diagnosed with an ARS phenotype with anterior segment abnormalities (polycoria, corectopia, posterior embryotoxon) and glaucoma with high IOP (36 and 48 mmHg for the right and the left eye, respectively). All three affected individuals had a protuberant umbilicus and abnormal dentition. A novel heterozygous missense pathogenic variant c.455G > A or p.(Cys152Tyr), genomic position 4:111539780C > T, was identified in the proband (II:1) by direct DNA sequencing (Figure 3). This pathogenic variant segregated with the disease phenotype in the affected younger sister (II:2) and their father (I:1). This particular pathogenic variant, NM_153426.2(*PITX2*):c.455G > A or p.(Cys152Tyr), is considered by SIFT to be deleterious, by Polyphen-2 to be damaging, and by MutationTaster to be disease causing. The PhyloP score was 2.796, and the Grantham distance was 194, indicating nucleotide and amino acid conservation. The tools show that the cysteine amino acid is conserved among different species (Figure 3). Another in silico analysis of the pathogenic variant predicts it to be disease causing (DEOGEN2,



FIGURE 2 Family 2 from Mexico with ARS. (a) Pedigree showing the segregation of the deletion NM_153426.2(*PITX2*):c.242_265del or p.(Lys81_Gln88del). The arrow indicates the proband. (b) Sequencing chromatogram reverse sequence of *PITX2* showing the region of loss of the seven codons in affected heterozygous members and marked in red in the DNA sequence. (c) Multiple sequence alignment of *PITX2* region surrounding the mutation p.(Lys81_Gln88del) in orthologous species

EIGEN, MutationTaster, PrimateAI, Provean, and SIFT). The identified variant was absent in GnomAD exomes and GnomAD genomes. According to the HOPE prediction, the mutant residue is larger, leading to bumps. The hydrophobicity of the wild-type and mutant residue differs, so the hydrophobic interactions, either in the core of the protein or on the surface, are lost.

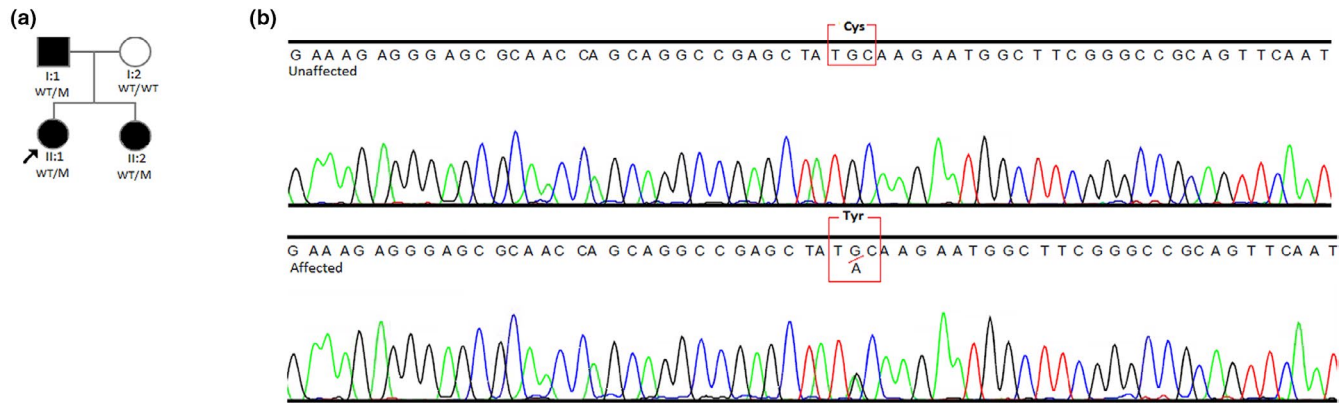
4 | DISCUSSION

In this study, we reported three novel heterozygous variations in the *PITX2* gene segregating in three pedigrees with ARS from Pakistan and Mexico. Bioinformatics tools were used to identify these variations: NM_153426.2(*PITX2*):c.226G > T or p.(Ala76Ser), NM_153426.2(*PITX2*):c.242_265del or p.(Lys81_Gln88del), and NM_153426.2(*PITX2*):c.455G > A, or p.(Cys152Tyr).

The first identified variant is missense and located near the homeodomain region in the *PITX2* protein; the second is a pathogenetic variant resulting in an in-frame deletion

of seven-conserved amino acids in the homeodomain, and the third mutation affects the coding region at 3' to the homeobox. The three identified novel variations are absent in GnomAD Browser. To the best of our knowledge, the variations in *PITX2* identified in this study have not previously been reported (Tümer & Bach-Holm, 2009).

The *PITX2* gene, located on 4q25, encodes proteins involved in the regulation of procollagen lysyl hydroxylase and a transcription factor of the paired-like homeodomain family, which plays an important role in the development of eyes, heart, brain, limb, umbilicus, and teeth. Many of these tissues are derived from neural crest cells, implying that some of the clinical features of ARS are probably due to a failure of the migration and differentiation processes during embryonic development. Consequently, pathogenic changes in *PITX2* gene cause defects in the development of the abovementioned tissues. Specifically, for the eye, *PITX2* mutations are associated with a vast range of eye diseases, such as ARS, Peters anomaly, iris hypoplasia, aniridia, and ring dermoid (Evans & Gage, 2005; Footz, Idrees, Acharya, Kozłowski, & Walter, 2009). Moreover,



(c)

| Species | Match | Gene | aa | Alignment | |
|------------------------|---------------|--------------------|-----|---------------|------------------------|
| <i>H. sapiens</i> | | ENST00000354925 | 152 | RKRERNQQ | AELCKNGFG PQFNGLM |
| <i>C152Y mutation</i> | not conserved | | 152 | RKRERNQQ | AELYKNGFG PQFNGL |
| <i>P. troglodytes</i> | all identical | ENSPTRG00000016371 | 159 | RKRERNQQ | AELCKNGFG PQFNGL |
| <i>M. mulatta</i> | all identical | ENSMMUG00000011322 | 160 | RKRERNQQ | AELCKNGFG PQFNGL |
| <i>F. catus</i> | all identical | ENSFCAG00000007195 | 160 | RKRERNQQ | AELCKNGFG PQFNGL |
| <i>M. musculus</i> | all identical | ENSMUSG00000028023 | 159 | RKRERNQQ | AELCKNGFG PQFNGL |
| <i>G. gallus</i> | all identical | ENSGALG00000012086 | 151 | RKRERNQ- | AELCKNGFG PQFNGL |
| <i>T. rubripes</i> | all identical | ENSTRUG00000015597 | 150 | RKRERNQQ | AELCKNGFG PQFNGL |
| <i>D. rerio</i> | all identical | ENSDARG00000036194 | 149 | RKRERNQQ | AELCKNGFG PQFNGL |
| <i>D. melanogaster</i> | not conserved | FBgn0020912 | 501 | RKRERNAMNAAVA | AADFKSGFG TQF--- |
| <i>C. elegans</i> | not conserved | B0564.10 | 179 | RKRERNY- | --VIDNGQGTTKVT AQS LDP |
| <i>X. tropicalis</i> | all identical | ENSXETG00000013330 | 166 | RKRERNQQ | AELCKNGFG PQFNGL |

FIGURE 3 Family 3 from Pakistan with ARS. (a) Pedigree showing the segregation of the mutation NM_153426.2(*PITX2*):c.455G > A or p.(Cys152Tyr) in the *PITX2* gene. The arrow indicates the proband. (b) Sequencing chromatogram of the forward sequence of the wild-type fragment of the DNA in unaffected individual and heterozygous sequence in the affected individual. (c) Multiple sequence alignment of *PITX2* region surrounding the mutation p.(Cys152Tyr) in various species

patients affected by ARS show a higher risk of developing glaucoma during their lifetime. The expected risk can be estimated to be approximately 50%, which highlights the urgency of developing effective prevention actions, especially in countries where access to the health care system can still represent a challenge (Cella et al., 2006; Idrees et al., 2006).

The *PITX2* gene encodes multiple protein isoforms that have different N-termini according to their roles during development. In contrast, the C-terminus shows an identical sequence of DNA, resulting in a highly conserved region. *PITX2* presents two conserved regions: the homeobox and the Orthopedia Aristaless and Rax (OAR) domains. The homeobox encodes a 60-amino acid conserved homeodomain, assuring the functionality of the gene, the localization of *PITX2* into the nucleus, the DNA binding, and the protein–protein interaction. Similarly, the OAR domain, located within the C-terminus, mediates the protein–protein interactions as well as the self-inhibitory interactions with the N-terminus. The homeodomain recognizes the bicoid motive of promoters of genes involved in tooth differentiation, such as *DLX2*. Thus,

mutations in the *PITX2* gene are likely to be associated with dental anomalies (Datson et al., 1996; Semina et al., 1996).

Usually, mutations in *PITX2* involved in ARS can show variability in terms of expressions of the phenotype regarding the ocular anterior segment abnormalities, even within families carrying the same variant (Kamińska, Sokołowska-Oracz, Pawluczyk-Dyjećńska, & Szaflik, 2007; Tümer & Bach-Holm, 2009). In the families that we investigated, the affected members showed a similar manifestation of the syndrome.

Most of the alterations reported in the literature on the *PITX2* gene are point mutations, such as missense, nonsense, and splice-site recognition, lying in the homeodomain and C-terminal region of the protein. The point mutations could act via a loss-of-function or gain-of-function mechanism causing dysfunction in the DNA binding process and in transcriptional transactivation (Brooks et al., 2004; Phillips, 2002; Seifi et al., 2016; Tümer & Bach-Holm, 2009).

Studying genotype–phenotype correlations in this syndrome is challenging since there is not a direct correlation between the position of the mutation and the severity of the

ARS manifestation. Previous studies showed that the severity of this syndrome can be directly correlated with the residual function retained by the Pitx2 protein, which depends on the effect that the mutant allele exerts. Functional analysis showed that *PITX2* mutations can have a gain-of-function effect or diminish the capacity to bind DNA and act as a transcription and transactivation factor. Specifically, mutations with a hypomorphic allele are able to retain some functionalities. For example, these mutations can still transactivate genes like *DLX2*, which is important for tooth development, and the patients that carry them do not report dental malformations. On the other hand, patients carrying a gain-of-function mutation in the *PITX2* gene can present ARS with tooth anomalies, due to the inability to transactivate the *DLX2* promoter (Espinoza, Cox, Semina, & Amendt, 2002; Kozlowski & Walter, 2000; Saadi et al., 2006; Tümer & Bach-Holm, 2009).

Currently, bioinformatics tools show a high predictive value in estimating the potential pathogenicity and alteration effects of missense variants in *PITX2*. In particular, the sensitivity and specificity were demonstrated to be > 93% (Seifi & Walter, 2018b). In silico analysis performed for the heterozygous missense variant reported in our study, p.(Ala76Ser), predicted it to be polymorphic, meaning that this variant does not destabilize the *PITX2* product.

A number of studies have reported that *PITX2* proteins can create homodimeric aggregates. This mechanism was suggested to explain the dominant-negative model associated with mutations in patients with ARS. In fact, it is important that the dosage of *PITX2* expression is well regulated because variations (increase or decrease) of its product can impair the regulation of other genes involved in its pathway (Maciolek, Alward, Murray, Semina, & McNally, 2006; Priston et al., 2001; Saadi, Kuburas, Engle, & Russo, 2003; Saadi et al., 2001). The heterozygous pathogenic variant, p.(Lys81_Gln88del) is the first in-frame deletion reported in the literature that involves seven amino acids located in the homeodomain region. It could exert its effects through binding with other *PITX2* interactors, presumably producing heterodimers instead of homodimers, via a dominant-negative effect. However, as an in-frame deletion, the stability and functionality of the products might vary.

The *PITX2* gene exerts its effect on transactivation through the C-terminus region, which shows both an inhibitory and a stimulatory function. Footz et al. ascertained that mutations located in the proximal inhibitory domain might carry out their pathogenic effects altering the transactivation process (Footz et al., 2009). Similarly, the pathogenic variant identified in this report, p.(Cys152Tyr), located in the HD-proximal inhibitory domain of the C-terminus, might change the affinity of *PITX2* binding with the other interactors in a cell-specific context, and cause altered responsiveness to them.

In addition to previously reported cases of ARS that were caused by deletion variants in the *PITX2* gene in Caucasian populations, our study identified an in-frame deletion variant responsible for the syndrome. However, this variant does not seem to produce a different clinical manifestation to the ones extensively investigated in Caucasian patients in other studies. Furthermore, the novel variants identified in the Pakistani families with ARS confirm the pathogenic role of the *PITX2* gene in relation to this syndrome (Micheal et al., 2016).

In conclusion, we investigated the segregation of three newly discovered variants in affected and unaffected family members of Mexican and Pakistani patients, using bioinformatics tools to ascertain their pathogenic role in ARS syndrome. Our study extends the range of *PITX2* variants in individuals with ARS, leading to an improved diagnosis of this syndrome.

CONFLICT OF INTEREST

The authors report that they have no competing interests.

ORCID

Valeria Lo Faro  <https://orcid.org/0000-0003-4931-7327>

REFERENCES

- Alward, W. L. M. (2000). Axenfeld-Rieger syndrome in the age of molecular genetics. *American Journal of Ophthalmology*, 130(1), 107–115. [https://doi.org/10.1016/S0002-9394\(00\)00525-0](https://doi.org/10.1016/S0002-9394(00)00525-0)
- Brooks, B. P., Moroi, S. E., Downs, C. A., Wiltse, S., Othman, M. I., Semina, E. V., & Richards, J. E. (2004). A novel mutation in the *PITX2* gene in a family with Axenfeld-Rieger syndrome. *Ophthalmic Genetics*, 25(1), 57–62. <https://doi.org/10.1076/opge.25.1.57.29002>
- Cella, W., de Vasconcellos, J. P. C., de Melo, M. B., Kneipp, B., Costa, F. F., Longui, C. A., & Costa, V. P. (2006). Structural assessment of *PITX2*, *FOXC1*, *CYP1B1*, and *GJA1* genes in patients with Axenfeld-Rieger syndrome with developmental glaucoma. *Investigative Ophthalmology & Visual Science*, 47(5), 1803–1809.
- Datson, N. A., Semina, E., van Staaldunin, A. A., Dauwerse, H. G., Meershoek, E. J., Heus, J. J., ... van Ommen, G. J. (1996). Closing in on the Rieger syndrome gene on 4q25: Mapping translocation breakpoints within a 50-kb region. *American Journal of Human Genetics*, 59(6), 1297–1305.
- D'haene B., Meire, F., Claerhout, I., Kroes, H. Y., Plomp, A., Arens Y. H., ... Wuyts, W. (2011). Expanding the spectrum of *FOXC1* and *PITX2* mutations and copy number changes in patients with anterior segment malformations. *Investigative Ophthalmology & Visual Science*, 52, 324. <https://doi.org/10.1167/iovs.10-5309>.
- Espinoza, H. M., Cox, C. J., Semina, E. V., & Amendt, B. A. (2002). A molecular basis for differential developmental anomalies in Axenfeld-Rieger syndrome. *Human Molecular Genetics*, 11(7), 743–753. <https://doi.org/10.1093/hmg/11.7.743>
- Evans, A. L., & Gage, P. J. (2005). Expression of the homeobox gene *Pitx2* in neural crest is required for optic stalk and ocular anterior segment development. *Human Molecular Genetics*, 14(22), 3347–3359. <https://doi.org/10.1093/hmg/ddi365>

- Flanagan, S. E., Patch, A.-M., & Ellard, S. (2010). Using SIFT and PolyPhen to Predict Loss-of-Function and Gain-of-Function Mutations. *Genetic Testing and Molecular Biomarkers*, *14*(4), 533–537. <https://doi.org/10.1089/gtmb.2010.0036>
- Footz, T., Idrees, F., Acharya, M., Kozlowski, K., & Walter, M. A. (2009). Analysis of Mutations of the PITX2 Transcription Factor Found in Patients with Axenfeld-Rieger Syndrome. *Investigative Ophthalmology & Visual Science*, *50*, 2599. <https://doi.org/10.1167/iovs.08-3251>.
- Hernández-Martínez, N., González-del Angel, A., Alcántara-Ortigoza, M. A., González-Huerta, L. M., Cuevas-Covarrubias, S. A., & Villanueva-Mendoza, C. (2018). Molecular characterization of Axenfeld-Rieger spectrum and other anterior segment dysgeneses in a sample of Mexican patients. *Ophthalmic Genetics*, *39*(6), 728–734. <https://doi.org/10.1080/13816810.2018.1547911>
- Hjalt, T. A., & Semina, E. V. (2005). Current molecular understanding of Axenfeld-Rieger syndrome. *Expert Reviews in Molecular Medicine*, *7*(25), 1–17. <https://doi.org/10.1017/S1462399405010082>
- Idrees, F., Vaideanu, D., Fraser, S. G., Sowden, J. C., & Khaw, P. T. (2006). A review of anterior segment dysgeneses. *Survey of Ophthalmology*, *51*(3), 213–231. <https://doi.org/10.1016/j.survo.ophthal.2006.02.006>
- Intarak, N., Theerapanon, T., Ittiwut, C., Suphapeetiporn, K., Porntaveetus, T., & Shotelersuk, V. (2018). A novel PITX2 mutation in non-syndromic orodental anomalies. *Oral Diseases*, *24*(4), 611–618.
- Kamińska, A., Sokołowska-Oracz, A., Pawluczyk-Dyjeńska, M., & Szaflik, J. P. (2007). Variability of clinical manifestations in the family with Axenfeld-Rieger syndrome. *Klinika Oczna*, *109*(7–9), 321–326.
- Kopanos, C., Tsiolkas, V., Kouris, A., Chapple, C. E., Albarca Aguilera, M., Meyer, R., & Massouras, A. (2019). VarSome: The human genomic variant search engine. *Bioinformatics*, *35*(11), 1978–1980. <https://doi.org/10.1093/bioinformatics/bty897>
- Kozlowski, K., & Walter, M. A. (2000). Variation in residual PITX2 activity underlies the phenotypic spectrum of anterior segment developmental disorders. *Human Molecular Genetics*, *9*(14), 2131–2139. <https://doi.org/10.1093/hmg/9.14.2131>
- Maciolek, N. L., Alward, W. L. M., Murray, J. C., Semina, E. V., & McNally, M. T. (2006). Analysis of RNA splicing defects in PITX2 mutants supports a gene dosage model of Axenfeld-Rieger syndrome. *BMC Medical Genetics*, *11*(7), 59. <https://doi.org/10.1186/1471-2350-7-59>
- Micheal, S., Siddiqui, S. N., Zafar, S. N., Venselaar, H., Qamar, R., Khan, M. I. & den Hollander, A. I. (2016). Whole exome sequencing identifies a heterozygous missense variant in the PRDM5 gene in a family with Axenfeld-Rieger syndrome. *Neurogenetics*, *17*, 17–23. <https://doi.org/10.1007/s10048-015-0462-0>
- Phillips, J. C. (2002). Four novel mutations in the PITX2 gene in patients with Axenfeld-Rieger syndrome. *Ophthalmic Research*, *34*(5), 324–326. <https://doi.org/10.1159/000065602>
- Priston, M., Kozlowski, K., Gill, D., Letwin, K., Buys, Y., Levin, A. V., ... Héon, E. (2001). Functional analyses of two newly identified PITX2 mutants reveal a novel molecular mechanism for Axenfeld-Rieger syndrome. *Human Molecular Genetics*, *10*(16), 1631–1638. <https://doi.org/10.1093/hmg/10.16.1631>
- Protas, M. E., Weh, E., Footz, T., Kasberger, J., Baraban, S. C., Levin, A. V., ... Gould, D. B. (2017). Mutations of conserved non-coding elements of PITX2 in patients with ocular dysgenesis and developmental glaucoma. *Human Molecular Genetics*, *26*(18), 3630–3638. <https://doi.org/10.1093/hmg/ddx251>
- Reis, L. M., Tyler, R. C., Volkmann Kloss, B. A., Schilter, K. F., Levin, A. V., Lowry, R. B., ... Semina, E. V. (2012). PITX2 and FOXC1 spectrum of mutations in ocular syndromes. *European Journal of Human Genetics*, *20*(12), 1224–1233. <https://doi.org/10.1038/ejhg.2012.80>
- Saadi, I., Kuburas, A., Engle, J. J., & Russo, A. F. (2003). Dominant negative dimerization of a mutant homeodomain protein in Axenfeld-Rieger syndrome. *Molecular and Cellular Biology*, *23*(6), 1968–1982. <https://doi.org/10.1128/MCB.23.6.1968-1982.2003>
- Saadi, I., Semina, E. V., Amendt, B. A., Harris, D. J., Murphy, K. P., Murray, J. C., & Russo, A. F. (2001). Identification of a Dominant Negative Homeodomain Mutation in Rieger Syndrome. *Journal of Biological Chemistry*, *276*(25), 23034–23041. <https://doi.org/10.1074/jbc.M008592200>
- Saadi, I., Toro, R., Kuburas, A., Semina, E., Murray, J. C., & Russo, A. F. (2006). An unusual class of PITX2 mutations in Axenfeld-Rieger syndrome. *Birth Defects Research Part A: Clinical and Molecular Teratology*, *76*, 175–181. <https://doi.org/10.1002/bdra.20226>
- Seifi, M., Footz, T., Taylor, S. A. M., Elhady, G. M., Abdalla, E. M., & Walter, M. A. (2016). Novel PITX2 gene mutations in patients with Axenfeld-Rieger syndrome. *Acta Ophthalmologica*, *94*(7), e571–e579. <https://doi.org/10.1111/aos.13030>
- Seifi, M., & Walter, M. A. (2018a). Axenfeld-Rieger syndrome. *Clinical Genetics*, *93*(6), 1123–1130. <https://doi.org/10.1111/cge.13148>
- Seifi, M., & Walter, M. A. (2018b). Accurate prediction of functional, structural, and stability changes in PITX2 mutations using in silico bioinformatics algorithms. *PLoS ONE*, *13*(4), e0195971. <https://doi.org/10.1371/journal.pone.0195971>
- Semina, E. V., Reiter, R., Leysens, N. J., Alward, W. L., Small, K. W., Datson, N. A., ... Murray, J. C. (1996). Cloning and characterization of a novel bicoid-related homeobox transcription factor gene, RIEG, involved in Rieger syndrome. *Nature Genetics*, *14*(4), 392–399. <https://doi.org/10.1038/ng1296-392>
- Strungaru, M. H., Hermina Strungaru, M., Dinu, I., & Walter, M. A. (2007). Genotype-Phenotype Correlations in Axenfeld-Rieger Malformation and Glaucoma Patients with FOXC1 and PITX2 Mutations. *Investigative Ophthalmology & Visual Science*, *48*, 228. <https://doi.org/10.1167/iovs.06-0472>.
- Tanwar, M., Dada, T., Axenfeld-Rieger, D. R., Associated, S. (2010). Axenfeld-Rieger Syndrome Associated with Congenital Glaucoma and Cytochrome P4501B1 Gene Mutations. *Case Reports in Medicine*, *2010*, 1–6. <https://doi.org/10.1155/2010/212656>
- Titheradge, H., Togneri, F., McMullan, D., Brueton, L., Lim, D., & Williams, D. (2014). Axenfeld-Rieger syndrome: Further clinical and array delineation of four unrelated patients with a 4q25 microdeletion. *American Journal of Medical Genetics. Part A*, *164A*(7), 1695–1701. <https://doi.org/10.1002/ajmg.a.36540>
- Tümer, Z., & Bach-Holm, D. (2009). Axenfeld-Rieger syndrome and spectrum of PITX2 and FOXC1 mutations. *European Journal of Human Genetics*, *17*(12), 1527–1539. <https://doi.org/10.1038/ejhg.2009.93>
- Venselaar, H., te Beek, T. A. H., Kuipers, R. K. P., Hekkelman, M. L., & Vriend, G. (2010). Protein structure analysis of mutations causing inheritable diseases. An e-Science approach with life scientist friendly interfaces. *BMC Bioinformatics*, *11*(1), <https://doi.org/10.1186/1471-2105-11-548>

- Vieira, V., David, G., Roche, O., de la Houssaye, G., Boutboul, S., Arbogast, L., ... Rossi, A. (2006). Identification of four new PITX2 gene mutations in patients with Axenfeld-Rieger syndrome. *Molecular Vision*, *1*(12), 1448–1460.
- Weisschuh, N., De Baere, E., Wissinger, B., Tümer, Z. (2011) Clinical utility gene card for: Axenfeld–Rieger syndrome. *European Journal of Human Genetics*, *19*(3), 1–3. <https://doi.org/10.1038/ejhg.2010.163>
- Zhang, L., Peng, Y., Ouyang, P., Liang, Y., Zeng, H., Wang, N., ... Shi, J. (2019). A novel frameshift mutation in the PITX2 gene in a family with Axenfeld-Rieger syndrome using targeted exome sequencing. *BMC Medical Genetics*, *20*(1), 105. <https://doi.org/10.1186/s12881-019-0840-9>

SUPPORTING INFORMATION

Additional supporting information may be found online in the Supporting Information section.

How to cite this article: Lo Faro V, Siddiqui SN, Khan MI, et al. Novel mutations in the *PITX2* gene in Pakistani and Mexican families with Axenfeld-Rieger syndrome. *Mol Genet Genomic Med.* 2020;8:e1215. <https://doi.org/10.1002/mgg3.1215>