

Case Report

Inadvertent macular burns and consecutive psychological depression secondary to Alexandrite laser epilation: A case report



Lokman Balyen

Abstract

Unwanted hair is an important aesthetic problem in many cultures. Laser epilation devices have become commonly available at the present time. Nowadays, laser hair removal is widely practiced as a cosmetic procedure, however, some ocular complications may occur. The retina is the most vulnerable to laser-related injury which can lead to serious visual impairment. Laser epilation can cause serious complications and medical costs if not performed carefully and appropriately. The use of laser hair removal devices by unskilled aestheticians who is untrained and do not have the proper protective equipment at the beauty centers, can cause serious ophthalmological and psychological disorders and thus substantial labour productivity loss and economic loss. Therefore, the protective eyewear must be used by both the aesthetician and the patient during the procedure of laser epilation. In this way, we can improve the safety of both patients and aestheticians and at the same time ensure their healths. I reported the case of a 49-year-old female with a unilateral maculopathy responsible for an acute visual field defect and consecutive psychological depression secondary to Alexandrite laser epilation. This report is important to raise the awareness of ophthalmology and dermatology society and public about risks of their misuse.

Keywords: Laser epilation, Safety eyewear, Maculopathy, Psychological depression

© 2018 The Author. Production and hosting by Elsevier B.V. on behalf of Saudi Ophthalmological Society, King Saud University. This is an open access article under the CC BY-NC-ND license (<http://creativecommons.org/licenses/by-nc-nd/4.0/>). <https://doi.org/10.1016/j.sjopt.2018.03.006>

Introduction

Unwanted hair is an important aesthetic problem in many cultures. Particularly facial hypertrichosis pose a tremendous psychological burden for women. It can generally cause psychological, mental problems, lack of self-confidence and low self-esteem. Frankly if we take into account the psychological problems caused by unwanted hair and also point out the complications arising from laser hair removal and thus substantial labour productivity loss, economic loss and medical costs, we are facing a serious public health problem in worldwide. Nowadays, laser hair removal is widely practiced as a cosmetic procedure.¹ Melanin in the hair matrix absorbs light in the wavelengths of 600–1100 nm; thus, long-pulse ruby (694 nm), long-pulse Alexandrite (755 nm), long-pulse diode (810 nm), long-pulse Nd:YAG (1,064 nm), and intense pulsed light (IPL) (590–1200 nm) photothermally damage hair

follicles.² In terms of efficacy and safety, the long-pulse alexandrite (755 nm) is one of the most popular systems.² The most common side effects of laser hair removal are skin reactions such as pain, transient erythema, perifollicular edema, burns, blisters, permanent scarring, hyperpigmentation or hypopigmentation, premature graying of hair.^{2–4} Thermal, mechanical, and photochemical damage to ocular structures (corneal burns, iris atrophy, uveitis, pupillary distortion, posterior synechiae, cataract, and retinal burns) is another serious potential complication resulting from laser hair removal, eventually leading to common symptoms such as pain, conjunctival hyperemia, photophobia, blurred vision, and visual field defect.^{5–7} Therefore, special eye shields should be worn when using laser epilation devices and periorbital laser epilation should be avoided.²

In the literature, there are only a few reports on retinal complications after laser epilation of facial hair. I reported a

Received 8 May 2017; received in revised form 8 March 2018; accepted 27 March 2018; available online 11 April 2018.

Kafkas University, Faculty of Medicine, Department of Ophthalmology, Kars, Turkey
e-mail address: lbalyen@hotmail.com



Peer review under responsibility of Saudi Ophthalmological Society, King Saud University



Production and hosting by Elsevier

Access this article online:
www.saudiophthaljournal.com
www.sciencedirect.com

case of unilateral maculopathy responsible for an acute visual field defect, pain, photophobia, and psychological depression began to develop after Alexandrite laser exposure and aimed to draw attention to and to raise awareness about potential dangers of its improper use.

Case report

A 49-year-old female patient was admitted to the outpatient clinic with complaints of pain, photophobia, hyperemia and decreased visual acuity in the left eye after inadvertent exposure Alexandrite laser epilation of the face area 4 days ago at a beauty center. She stated that she took protective goggles off her face for short time period during laser epilation procedure and that both eyes exposed to the laser beam. Afterward, a sudden pain began to develop in the left eye. On ophthalmological examination, her best-corrected visual acuity was 20/20 with $-1.50\text{Ds}/-1.00\text{Dcyl}\times 39^\circ$ in the right eye (OD) and 20/200 with $-2.00\text{Ds}/-0.75\text{Dcyl}\times 116^\circ$ in the left eye(OS). Anterior segment was normal in both eyes with slit-lamp examination. On fundus examination, about $\frac{1}{4}$ disc area in size yellowish-white color a laser burn zone was observed in the superior foveal region, involving the central foveola of the left eye, while the right eye was normal (Fig. 1). In the red free fundus photography of the left eye was observed oval area of central hyperfluorescence (Fig. 2a). In the late phase of the left eye fundus fluorescein angiography (FFA), area of central hypofluorescence with a hyperfluorescent ring was observed, but there was no leakage and the right eye was normal (Fig. 2b). In optical coherence tomography (OCT) of the left eye, the IS/OS band and the external limiting membrane (ELM) line were found to be defective under the fovea. An irregularly shaped oval hyper-reflective region extending from the retinal pigment epithelium surface into the retina was observed and no intraretinal or subretinal fluid and hemorrhage accumulation were observed (Fig. 3). No corneal burns, iris atrophy, uveitis, pupillary distortion, posterior synechiae, cataract formation, intraretinal or subretinal fluid and hemorrhage accumulation, choroidal neovascularization were observed. She had no systemic diseases. Her medical treatment consisted of topical steroids and cyclopentolate and nonsteroid anti-inflammatory ophthalmic drops and systemic nonsteroid anti-inflammatory drugs (pill) for about 2 months. There was

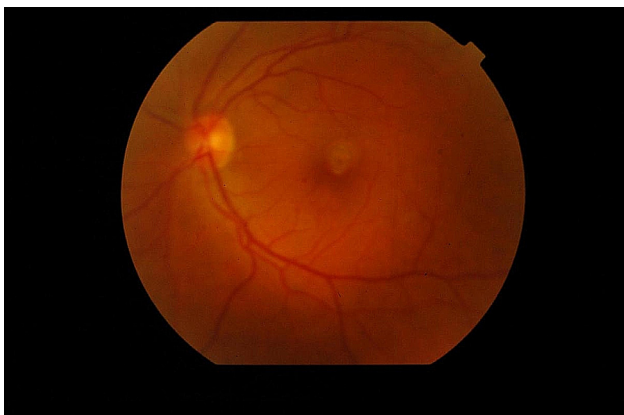


Fig. 1. Color fundus photography demonstrating yellowish-white color a laser burn zone in the central of the left eye.

no change in visual acuity and fundus findings at 3 months of observation. The patient did not come to the ophthalmology clinic for ophthalmic examination anymore and unfortunately, the patient was diagnosed with psychological depression in the psychiatric clinic due to laser-induced eye damage and decreased visual acuity and thus was receiving antidepressant drug treatment and getting psychotherapy.

Discussion

Unwanted hair especially has become a serious public health issue for the last few decades. Laser epilation is the most long-lasting and permanent and gentlest, thus increasingly popular method of hair removal from the face, leg, arm, nasal cavity, ear, and other areas. It uses a beam of laser light to target the melanin in hair follicles. Lasers have become widely used in various sectors such as scientific, social settings, and industrial as well as cosmetic.⁸ There are different types of laser epilation, including the alexandrite, diode, or long-pulsed Nd:YAG lasers and intense pulsed light (IPL) devices.^{1,9} The retina is most vulnerable to laser-related injury, because of the concentration of visible and near-infrared radiation on the retina. Photochemical, photomechanical, and photothermal mechanisms plays a role in the etiology of retinal injury after laser exposure.¹⁰ The main factors that can affect the severity of retinal injury are duration, wavelength and amount of laser exposure and the location of the lesion. The severity and persistence of retinal damage is tightly related to the closeness of laser influence to the macula. Retinal or vitreous hemorrhages, macular holes and edema are parameters that determine the severity of retinal damage. The foveal lesions generally cause irreversible visual acuity loss, however parafoveal lesions that affect the fovea via inflammation and oedema may be reversible and perimacular, paracentral, mid-peripheral, and peripheral retinal burns may not result in visual field defect.⁸

In our case, the degree of retinal damage was relatively limited, probably due to the very short exposure time of the eye to the laser beam. However, the injury had affected the visual acuity and was irreversible, owing to the foveal localization of the lesion. Recently, Wang et al.¹¹ have reported a case presented with immediate vision loss in the eye after accidentally Alexandrite laser exposure during laser hair removal without appropriate eye protection. In this case, there was subretinal hemorrhage associated with choroidal neovascularization and similarly to our case, the visual field defect was irreversible. However, a patient with inadvertent foveal injury and subsequent macular edema, hemorrhage, intra- and subretinal edema, and gradually decreasing visual acuity secondary to Alexandrite laser exposure has been reported and the case was successfully treated with an intravitreal Ozurdex implant as a result of its rapid antiedematous effect.¹² Likewise, Anaya-Alaminos et al.¹³ have described a case of foveal injury related to an alexandrite laser hair removal procedure. Milani et al.¹⁴ reported a patient with bilateral macular lesion secondary to a laser device (i.e. Nd:YAG laser) except to alexandrite laser. Also with it, in the literature, other side effects such as corneal burns, iris atrophy, anterior uveitis, pupillary distortion, posterior synechiae, and cataract have been reported following laser epilation procedures.¹⁵

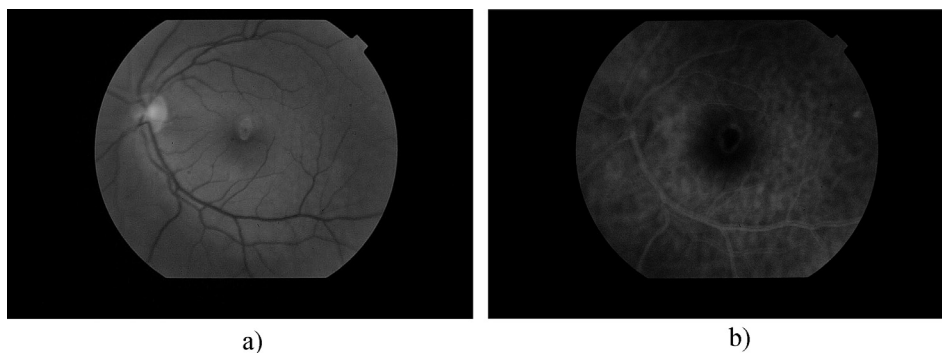


Fig. 2. (a) Red free fundus photography demonstrating oval area of central hyperfluorescence; (b) Late phase FFA demonstrating area of central hypofluorescence with a hyperfluorescent ring, but there was no leaking.

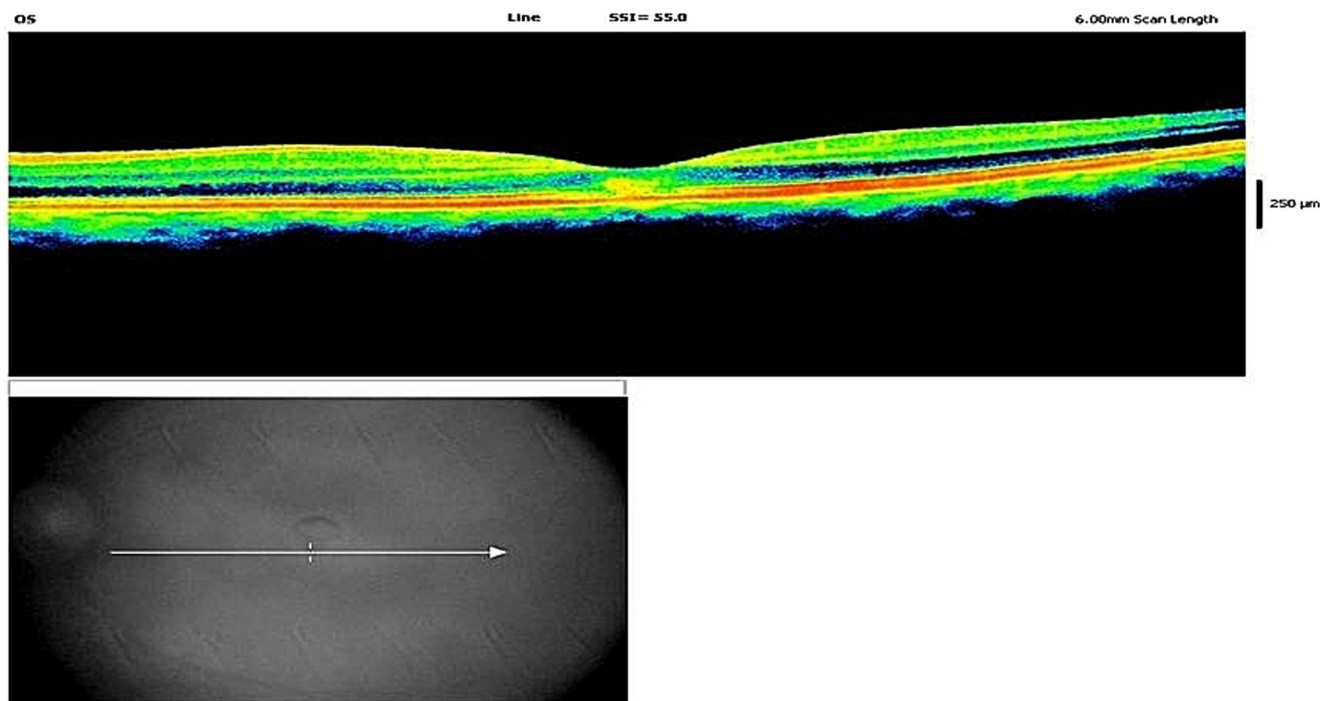


Fig. 3. OCT demonstrating the IS/OS band and the ELM line are found to be defective under the fovea.

In this report, the person applying the laser was untrained and not an expert. Moreover the place of application was not a hospital. The patient was not informed about the procedure of laser epilation. She was not referred to any ophthalmologist after the complication. When we consider the clinical situation of our case, we see that the situation is extremely grave both ophthalmologically and psychologically and so we are facing serious public health in the world. The diagnosis of depression was made by consultant psychiatrist. According to Beck depression inventory, the patient was in severe psychological depression secondary to the decrease of visual acuity and was receiving psychological depression treatment and getting psychotherapy.

The present report has been showing that laser epilation is not very innocent and must merely be undertaken very carefully by the experts; protective eyewear must be used; especially periorbital laser epilation may be extremely hazardous; the procedure should be performed in hospitals; the patients must be completely informed about the risks

of laser epilation and the procedure; and when any eye pain or an abnormal situation occurs during laser epilation, the process must be stopped at once and the patient must be immediately referred to an ophthalmologist. In addition, in order to reduce the morbidity rates, it is necessary to take necessary serious legal precautions against the unconscious use of laser epilation devices and the beauty centers need to undergo very serious supervision.

Consequently, due to the increasing use of lasers in cosmetic settings, progressively, this causes unintentional accidents at the beauty centers, so aestheticians' adequately and effectively education and patient's protection are very important. Generally, the laser epilation threatens both skin and eye health. Especially laser-induced eye complications are very serious and irreversible. Therefore both estheticians and patients must be very careful and knowledgeable in this regard. So the protective goggles must be used by both the aesthetician and the patient during laser epilation. Laser hair removal procedures must be carried out by well-trained and

professional experts. In this perspective, it is of utmost importance that aesthetic experts are made aware of laser-induced hazards. The use of laser hair removal devices by unskilled aestheticians who is untrained and do not have the proper protective equipment at the beauty centers, can cause serious ophthalmological and psychological disorders and therefore substantial labour productivity loss and economic loss. In this context, educating and raising the awareness of society about laser-induced hazards is quite important. In this way, we can improve the safety of both patients and aestheticians and at the same time ensure their healths. I think that this report is important to raise the awareness of ophthalmology and dermatology society and public about potential dangers of misuse of laser hair removal devices.

Acknowledgment

The author wishes to thank Assistant Professor Fatih Kara who works at the Faculty of Medicine of the Kafkas University.

Conflict of interest

The authors declared that there is no conflict of interest.

References

1. Asiri MS, Alharbi M, Alkadi T, Abouammoh M, Al-Amry M, ALZahrani Y, et al. Ocular injuries secondary to alexandrite laser-assisted hair removal. *Can J Ophthalmol* 2017;52, e71–e5.
2. Gan SD, Graber EM. Laser hair removal: a review. *Dermatol Surg* 2013;39:823–38.
3. Elkin Z, Ranka MP, Kim ET, Kahanowicz R, Whitmore WG. Iritis and iris atrophy after eyebrow epilation with alexandrite laser. *Clin Ophthalmol* 2011;5:1733–5.
4. Blanco G, Soparkar CN, Jordan DR, Patrinely JR. The ocular complications of periocular laser surgery. *Curr Opin Ophthalmol* 1999;10:264–9.
5. Parver DL, Dreher RJ, Kohanim S, Zimmerman P, Garrett G, Devisetty L, et al. Ocular injury after laser hair reduction treatment to the eyebrow. *Arch Ophthalmol* 2012;130:1330–4.
6. Parver DL. Ocular phototoxicity. In: Huang D, Kaiser PK, Lowder CY, Traboulsi EI, editors. *Retinal imaging*. Philadelphia: Mosby Elsevier; 2006. p. 421–6.
7. Balyen L. Laser pointer maculopathy: a case report. *MN Oftalmoloji* 2018;25(1):53–5.
8. Barkana Y, Belkin M. Laser eye injuries. *Surv Ophthalmol* 2000;44:459–78.
9. Yalçındağ FN, Uzun A. Anterior uveitis associated with laser epilation of eyebrows. *J Ophthalmic Inflamm Infect* 2013;3:45.
10. Youseff PN, Sheibani N, Albert DM. Retinal light toxicity. *Eye (Lond)* 2011;25:1–14.
11. Wang R, Wykoff CC, Christie L, Croft DE, Major Jr JC, Fish RH, et al. Choroidal neovascularization secondary to alexandrite laser exposure. *Retin Cases Brief Rep* 2016;10:244–8.
12. Bulut MN, Çallı Ü, Göktaş E, Bulut K, Kandemir B, Özürtürk Y. Use of an intravitreal dexamethasone implant (ozurdex) in a case with accidental foveal photocoagulation by alexandrite laser. *Case Rep Ophthalmol* 2016;7:130–4.
13. Anaya-Alaminos R, Munoz-Avila JI, Gonzalez-Gallardo MC, Mora-Horna ER, Garcia-Serrano JL, Ramirez-Garrido MV. Accidental foveal photocoagulation secondary to alexandrite laser. *Eur J Ophthalmol* 2014;24:808–10.
14. Milani P, Pierro L, Pece A, Marino V, Scialdone A. Retinal photoreceptor focal disruption secondary to accidental Nd:YAG laser exposure. *Int Ophthalmol* 2011;31:409–12.
15. Karabela Y, Eliaçık M. Anterior uveitis following eyebrow epilation with alexandrite laser. *Int Med Case Rep J* 2015;8:177–9.