

## Inflammation and infection

## A case of giant hemorrhagic hydrocele testis

Yuumi Tokura<sup>a,\*</sup>, Minoru Kobayashi<sup>b</sup>, Takao Kamai<sup>a</sup><sup>a</sup> Department of Urology, Dokkyo Medical University, 880 Kitakobayashi, Mibu, Shimotsuga, Tochigi 321-0293, Japan<sup>b</sup> Department of Urology, Utsunomiya Memorial Hospital, 1-3-16 Ohdori, Utsunomiya, Tochigi 320-0811, Japan

## ARTICLE INFO

## Keywords:

Giant hydrocele testis

Hemorrhage

Inflammation

## Introduction

Hydrocele is a common disease in urological practice caused by various conditions such as intra-scrotal malignancy, inflammation, trauma, and filariasis, otherwise idiopathic etiology. The present case came with rarity for its giant size and hemorrhagic fluid content which needed discrimination from malignancy.

## Case presentation

A 63-year-old man presented with a painless left scrotal swelling. Ultrasonography revealed intra-scrotal fluid retention and scrotal puncture collected 200ml of straw colored fluid, leading to a diagnosis of hydrocele testis.

Three months later, he received next aspiration of 360 ml for scrotal re-swelling. He came back 4 months later with much larger scrotal swelling extending to left inguinal area. Two additional aspirations were performed one week apart to collect somehow hemorrhagic fluid of 700 ml and 850 ml, respectively. Each aspiration was incomplete due to catheter clogging with blood clot, leaving nearly half of the initial bulk in appearance. MRI revealed a giant cystic space spanning a diameter of 16cm that contained hemorrhagic fluid with linear septal structures and floating nodular structures suggestive of blood clots (Fig. 1). There was no structure like mural nodules alongside the scrotal wall. The left testis was flattened by this large cystic lesion. Although the patient had no history of testicular trauma or exposure of asbestos, the presence of septa and solid component as well as hemorrhage raised a possibility of malignancy such as mesothelioma of the tunica vaginalis. However, cytological examination of hydrocele fluid was negative. The hyaluronic acid level of hydrocele fluid was 25,600ng/ml, which was far below the proposed cut-off level of 100,000 ng/ml for pleural effusion of malignant mesothelioma. Collectively, we did not

obtain data that is strongly suggestive of malignancy. Therefore, excision of the hydrocele sac was planned through scrotal approach. Intraoperative findings showed a well vascularized and thickened hydrocele sac, which was lined with denatured blood clots and filled with bloody fluid (Fig. 2). Left testis appeared normal. Intraoperative pathological diagnosis of the frozen section of tunica vaginalis was negative for malignancy and thus conventional hydrocelectomy was completed. The post-operative course was uneventful. The final histopathological diagnosis was chronic inflammation accompanied with hemorrhage, no evidence of malignancy (Fig. 3).

## Discussion

Hydrocele is a common disease in urological practice caused by various conditions such as intra-scrotal malignancy, inflammation, trauma, and filariasis, otherwise idiopathic etiology. The present case came with rarity for its giant size and hemorrhagic fluid content. Despite a paucity of available reports on giant hydrocele, it has been defined as a hydrocele having more than 1000 ml of contents. Giant hydrocele is primarily due to a sense of shame of visiting a clinic, resulting in discomfort and impairing patients' mobility. It also causes clinical symptoms including psychological stigma, voiding difficulty, sexual disability, and infertility attributed to arrest of spermatogenesis probably due to the direct effect of pressure on the testicular parenchyma or blood flow.<sup>3</sup>

When we encounter a case of hydrocele testis that contains hemorrhagic fluid, possibility of malignancy such as malignant mesothelioma of the tunica vaginalis, paratesticular rhabdomyosarcoma, and testicular tumor should be considered. Malignant mesothelioma of the tunica vaginalis is a rare and highly aggressive tumor, often accompanied with a hydrocele.<sup>1</sup> Even when it is suspected, preoperative confirmation by several diagnostic measures is difficult, and cytology of

\* Corresponding author.

E-mail address: [yuumi.ando@gmail.com](mailto:yuumi.ando@gmail.com) (Y. Tokura).

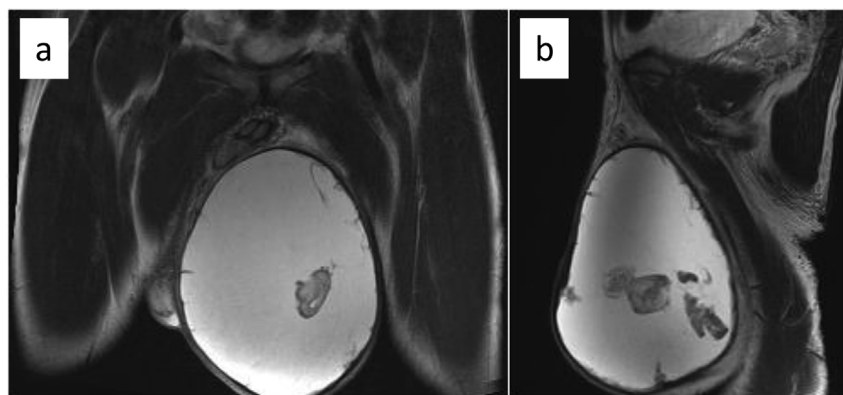


Fig. 1. T2-weighted MRI of the left scrotum (a: coronal image, b: sagittal image). The fluid content showed high intensity related to hemorrhage. The irregular-shaped nodular structure with low intensity floating in the fluid was suggestive of blood clots.

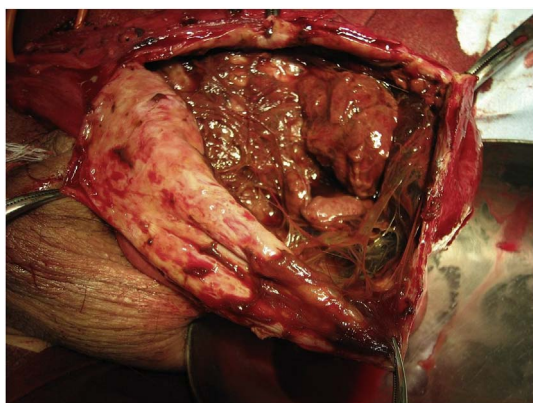


Fig. 2. Intraoperative figure of the opened hydrocele sac. The hydrocele sac was thickened and well vascularized. It contained bloody fluid and a lot of denatured blood clots.

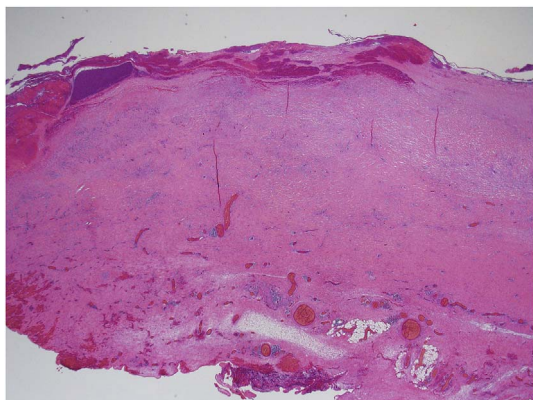


Fig. 3. Histopathological specimen of the hydrocele sac (HE staining, original magnification: x 12.5). Focal accumulations of lymphocytes and histiocyte were seen in the thickened fibrous tissue of the hydrocele sac, which was attached with fibrin and blood clots on its surface.

hydrocele fluid may be the only method for accurate diagnosis. Haga et al. suggested the feasibility of monitoring serum hyaluronic acid level to evaluate clinical course of this disease.<sup>2</sup> This may imply the usefulness of direct measurement of hyaluronic acid concentration in hydrocele fluid to facilitate preoperative diagnosis as is the case with malignant pleural mesothelioma. It is of note, however, that hydrocele

testis rarely exhibits hemorrhagic fluid content without the presence of malignancy like our case. Hirano et al. tabulated 13 cases of giant hydrocele testis reported in Japan, of which 8 cases showed dark-brown fluid or cholesterol crystal in hydrocele fluid, suggestive of old hemorrhage.<sup>3</sup> On the other hand, abdominoscrotal hydrocele (ASH) is an uncommon form of hydrocele in which scrotal hydrocele extends through the inguinal canal, deep inguinal ring and into the abdominal cavity. ASH often presents with a giant hydrocele, which occasionally leads to pressure related complications including hydronephrosis, appendicitis, testicular dysmorphism, deep vein thrombosis, leg edema, testicular torsion, adverse effect on spermatogenesis, testicular up-migration, and spontaneous rupture.<sup>4,5</sup> Hemorrhage was also reported as a rare event in ASH. Estevão-Costa et al. reported a case of hemorrhagic abdominoscrotal hydrocele in childhood and commented that hemorrhage might have led to tense scrotal swelling.<sup>5</sup> Likewise in our case, it was assumed that acute hemorrhage due to chronic inflammation in the tunica vaginalis or otherwise simply the result of repeated punctures caused rapid accumulation of reactive fluid to make a giant manifestation as hydrocele.

## Conclusion

Hemorrhagic fluid of hydrocele is not necessarily a sign of malignancy. Intralesional hemorrhage is liable to be a causative event of giant hydrocele. To exclude possible malignancy and avoid unnecessary orchiectomy, cytology and measurement of hyaluronic acid level in hydrocele fluid as well as MRI are recommended.

## Conflicts of interest

The authors declare no conflict of interest.

## References

1. Chekol SS, Sun CC. Malignant mesothelioma of the tunica vaginalis testis: diagnostic studies and differential diagnosis. *Arch Pathol Lab Med.* 2012;136:113–117.
2. Haga K, Shinohara N, Harabayashi T, Demura T, Koyanagi T. Is serum hyaluronic acid level useful for evaluating the clinical course of malignant mesothelioma of the tunica vaginalis? *BJU Int.* 1999;84:729–730.
3. Hirano S, Kawaguchi S, Mikawa I, Motoi I, Masuda S. Giant hydrocele: two case reports. *Hinyokika Kyo.* 1991;37:195–198.
4. Amodeo A, Liguori G, Trombetta C, Calgaro A, Patel HR, Belgrano E. A giant heterogeneous abdominoscrotal mass: haemorrhagic hydrocele. *J Radiol Case Rep.* 2009;3:16–20.
5. Estevão-Costa J, Morgado H, Soares-Oliveira M, Campos M, Carvalho JL. Hemorrhagic abdominoscrotal hydrocele. A challenging entity. *J Pediatr Surg.* 2005;40:731–733.