

CASE REPORT

Rhinocerebral mucormycosis in a 5-month heart transplant recipient

Gabriel Pedemonte-Sarrias, Juan Ramon Gras-Cabrerizo, Fernando Rodríguez-Álvarez¹,
Joan Ramon Montserrat-Gili

Departments of Otorhinolaryngology/Head and Neck Surgery and ¹Ophthalmology, Santa Creu and Sant Pau Hospital, Autonomous University of Barcelona, Barcelona, Spain

Address for correspondence:

Dr. Gabriel Pedemonte-Sarrias,
Department of Otorhinolaryngology, Head and Neck Surgery, Santa Creu and Sant Pau Hospital, Autonomous University of Barcelona, Barcelona, Spain.
E-mail: gabrielpedemonte@gmail.com

Received: 18-12-2013

Accepted: 04-12-2015

ABSTRACT

Mucormycosis is an opportunistic acute fungal infection with a high mortality rate seen in immunocompromised patients. It is extremely rare in heart transplant recipients. Rhinocerebral mucormycosis (RM) is the most frequently observed presentation. We report a case of RM in a heart transplant recipient 5-month after the procedure, with a fatal outcome.

Key words: Diabetes mellitus, fungal infection, heart transplant recipient, immunocompromised, rhinocerebral mucormycosis

INTRODUCTION

Mucormycosis, also known as zygomycosis, is an opportunistic and lethal mycological infection caused by a fungus of the order *Mucorales*. The genera most frequently involved are *Rhizopus*, *Absidia* and *Mucor*. It is mostly observed in immunocompromised patients such as those with hematological malignancy or those who have solid organ transplantation (SOT) or bone marrow transplants. Clinical manifestations include rhinocerebral, pulmonary, gastrointestinal, cutaneous and disseminated infections. Rhinocerebral mucormycosis (RM) is the most common form. The infection usually starts in the middle nasal meatus and spreads to the paranasal sinuses, the orbit and the intracranial structures by direct extension or through blood vessels.^[1]

Early diagnosis, initiating prompt surgical and medical therapy and correcting the underlying conditions play a vital role in eliminating this infection, but mortality remains high.

Mucormycosis is uncommon in SOT recipients and most cases have been reported after liver or renal transplantation.^[2] We report an unusual case of RM in a 5-month heart transplant recipient.

CASE REPORT

A 52-year-old male patient was transferred to our department from another center for retroorbital pain, headache and decreased vision accuracy in the left eye for the past 36 h. Five months earlier, he had undergone orthotopic heart transplantation under the bicaval technique due to ischemic heart failure. His medical history was significant for type II diabetes mellitus, poorly controlled by insulin. He also had hypertension and dyslipidemia (both under treatment) and nondialysis-dependent chronic kidney disease. His baseline immunosuppressive regimen consisted of prednisone, tacrolimus and mycophenolic acid and he was also taking prophylactic antibiotics: Cotrimoxazole, valganciclovir and isoniazid with pyridoxine.

Physical examination on admission showed that the patient was alert, orientated, afebrile and his vital signs were stable. Anterior rhinoscopy, endoscopy with 0° rigid endoscope and examination of the oral cavity were unremarkable. Although the nasal exploration was normal, in view of the symptoms and the previous transplant, two samples endoscopically directed, one of the nasal fossa by swabbing and the second of the middle meatus were

Access this article online

Quick Response Code:



Website:

www.jomfp.in

DOI:

10.4103/0973-029X.174635

This is an open access article distributed under the terms of the Creative Commons Attribution-NonCommercial-ShareAlike 3.0 License, which allows others to remix, tweak, and build upon the work non-commercially, as long as the author is credited and the new creations are licensed under the identical terms.

For reprints contact: reprints@medknow.com

How to cite this article: Pedemonte-Sarrias G, Gras-Cabrerizo JR, Rodríguez-Álvarez F, Montserrat-Gili JR. Rhinocerebral mucormycosis in a 5-month heart transplant recipient. J Oral Maxillofac Pathol 2015;19:375-8.

collected. Blood tests showed glucose levels of 248 mg/dL (13.8 mmol/L) and creatinine of 3.63 mg/dL. Computed tomography (CT) scan revealed soft tissue opacification of left anterior ethmoid sinus and inflammatory changes in the apex of the left orbit [Figure 1a].

The metabolic derangement was treated, intravenous antibiotics (piperacillin/tazobactam 2000/250 mg 8 hourly) was started and insulin was administered on a sliding scale. On the second day of hospitalization, the patient's clinical status worsened dramatically. Left eye movements were limited in all directions (frozen eye) and the left pupil was mydriatic. Signs of central retinal artery occlusion were found on the left funduscopy: Edema and papillary pallor, posterior pole retinal edema and arteriolar sclerosis [Figure 1b]. A second nasal 0° rigid endoscope showed necrotic tissue in the left middle meatus and the middle turbinate [Figure 1c]. The microbiological study showed a *Rhizopus* fungus. The lactophenol cotton blue preparation revealed a sporangium located on the columella at the apical end of the sporangiophore [Figure 1d]. Following the confirmation of RM, intravenous liposomal amphotericin B 300 mg/day was started. Immunosuppressive therapy was decreased, mycophenolic acid was stopped and tacrolimus was reduced. The magnetic resonance imaging showed that infection had progressed in the apex of the left orbit, involving the cavernous sinus. We proposed extensive surgical treatment

via left paralateral rhinotomy with orbital exenteration and total ethmoidectomy. The patient declined the treatment and died 8 days later.

DISCUSSION

Mucormycosis is an infrequent invasive acute fungal infection in SOT recipients. Its incidence has increased over the last 20 years due to increasing use of immunosuppressive drugs.^[3] It appears most frequently in the first 6 months after transplantation due to the higher immunosuppression. The incidence ranges from 0.4% to 16% depending on the SOT type and is 0%–0.6%^[2] in heart transplant recipients. Other significant predisposing conditions to mucormycosis in SOT recipients are poorly controlled diabetes mellitus and renal failure.^[4] Several studies have shown a significant association between diabetes mellitus and RM.^[5] Roden *et al.* found rhinocerebral infection of mucormycosis in 66% of patients with diabetes.^[3] The fungus spreads quickly in a medium of elevated glucose and acid pH^[6] and it is unusual in patients with metabolically controlled diabetes.^[7] The main protection against hyphae is neutrophils, but low serum pH decreases their pathogenic and chemotactic capacity.^[8] Our patient had three predisposing conditions: Immunosuppression for SOT, poorly controlled diabetes mellitus and renal failure.

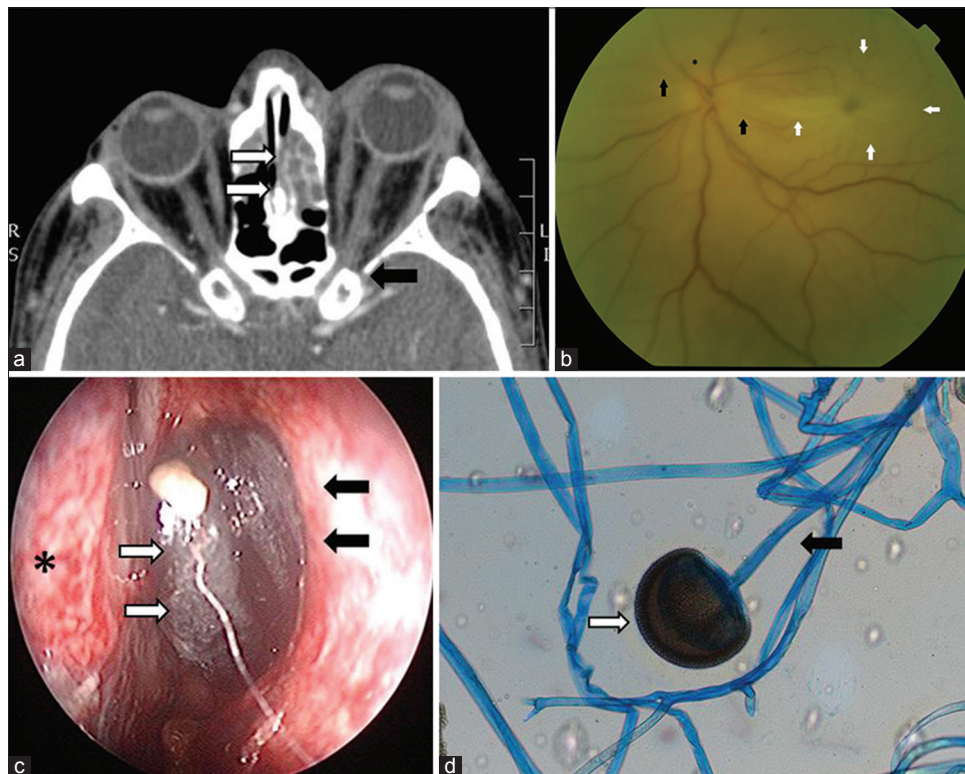


Figure 1: (a) Computed tomography scan showed soft tissue opacification of left ethmoid sinus (white arrows) and inflammatory changes in the apex of the left orbit (black arrows). (b) Fundus of the left eye with edema and papillary pallor (*), posterior pole retinal edema (white arrows) and arteriolar sclerosis (black arrows). (c) Left nasal endoscopy with 0° rigid endoscope, showing black necrotic eschar (white arrows) through the left middle meatus and the middle turbinate (black arrows). Nasal septum (*). (d) Lactophenol cotton blue culture showing *Rhizopus* fungus. Sporangium (white arrow). Sporangiophore (black arrow) (lactophenol cotton blue stain, x1000)

Three main ways of transmission of mucormycosis in transplant recipients have been reported: Inhalation in approximately 70%, ingestion in 2% and percutaneous introduction in 13%.^[9]

The most common form is RM and it usually occurs through inhalation of spores.^[9] Infection begins with the involvement of the paranasal sinus and the palate. It then extends to the orbit and periorbital area where it can produce the orbital apex syndrome with ophthalmoplegia, ptosis, mydriasis and decreased visual accuracy. Finally, it disseminates to the cavernous sinus and then to the meninges and brain.^[10]

Clinical presentation of the disease usually involves symptoms of sinusitis and periorbital cellulitis with facial pain and decreased vision. Advanced stages include meningitis, cerebral abscess and multiple cranial nerve palsies.^[11] Ophthalmoplegia with loss of vision may also be present, indicating progressive orbital involvement. Oral cavity examination can reveal gingival or palatal eschar.

A nasal endoscopy and a biopsy or a culture of the infected area are essential for the definitive diagnosis. A culture gives us more information about the species of *Mucorales*, but it has a higher rate of false negatives than the biopsy.^[11] The absence of black necrotic eschar does not exclude the possibility of mucormycosis. Bhansali *et al.* and Yohai *et al.* reported nasal ulceration or necrosis in 48%^[12] and 78%^[7] respectively in RM. In our case, the initial nasal endoscopy was unremarkable, but we performed a middle meatus culture in view of the high suspicion of RM and the culture revealed a fungus of the order *Mucorales*.

Imaging studies are not specific for RM. The contrast-enhanced sinus CT is helpful to delimit the extension of RM and reveal signs of invasion. Magnetic resonance is more sensitive than CT to evaluate intradural and intracranial involvement, the cavernous sinus thrombosis and thrombosis of the cavernous portions of the internal carotid artery.^[2]

Treatment is a combination of aggressive surgical debridement and systemic antifungal therapy. Radical resection removing all necrotic tissue should be done and various debridements are usually required. Lateral rhinotomy, orbital exenteration and occasionally intracranial surgery are performed depending on the extension of RM. Orbital exenteration is necessary when the orbit is infected with limited eye movements in all directions (frozen eye) and loss of vision.^[13] The surgery that we proposed to our patient was a left paralateral rhinotomy with orbital exenteration and total ethmoidectomy removing all the unviable tissue.

Amphotericin B is the drug of selection, but it is limited because of its renal and systemic toxic effect. Liposomal amphotericin B is less nephrotoxic. This lipid formulation improves circulation time and concentration in the infected

area of the associated amphotericin B.^[14] The duration of the treatment is not explicitly established. Rectification of underlying conditions is also necessary. The correction of ketoacidosis is important. Survival rates in diabetic patients with RM are higher than those in patients with other predisposing factors such as renal failure, hematologic malignancies or autoimmune diseases.^[8] Immunosuppressive therapy should also be decreased.^[15]

Prognosis of RM is poor. Despite the aggressive surgical and antifungal therapy, the mortality rate remains high, ranging from 32% to 75% in reported series.^[7] Patients with the lowest chance of survival are those who are immunocompromised. A delay in diagnosis and treatment, brain involvement, hemiparesis, bilateral sinus involvement and facial necrosis is also associated with poor survival.^[11]

CONCLUSION

RM is a rare and aggressive fungal infection in heart transplant recipients and carries a high mortality rate. Early diagnosis and correction of underlying factors is fundamental. Imaging studies and nasal endoscopy should be performed in patients with predisposing factors. Treatment is wide surgical debridement in combination with systemic antifungal therapy.

Financial support and sponsorship

Nil.

Conflicts of interest

There are no conflicts of interest.

REFERENCES

- Ribes JA, Vanover-Sams CL, Baker DJ. Zygomycetes in human disease. *Clin Microbiol Rev* 2000;13:236-301.
- Petrikkos G, Skiada A, Lortholary O, Roilides E, Walsh TJ, Kontoyiannis DP. Epidemiology and clinical manifestations of mucormycosis. *Clin Infect Dis* 2012;54 Suppl 1:S23-34.
- Roden MM, Zaoutis TE, Buchanan WL, Knudsen TA, Sarkisova TA, Schaufele RL, *et al.* Epidemiology and outcome of zygomycosis: A review of 929 reported cases. *Clin Infect Dis* 2005;41:634-53.
- Chakrabarti A, Chatterjee SS, Das A, Panda N, Shivaprakash MR, Kaur A, *et al.* Invasive zygomycosis in India: Experience in a tertiary care hospital. *Postgrad Med J* 2009;85:573-81.
- Lanternier F, Dannaoui E, Morizot G, Elie C, Garcia-Hermoso D, Huerre M, *et al.* A global analysis of mucormycosis in France: The RetroZygo Study (2005-2007). *Clin Infect Dis* 2012;54 Suppl 1:S35-43.
- Anand VK, Alemar G, Griswold JA Jr. Intracranial complications of mucormycosis: An experimental model and clinical review. *Laryngoscope* 1992;102:656-62.
- Bhansali A, Bhadada S, Sharma A, Suresh V, Gupta A, Singh P, *et al.* Presentation and outcome of rhino-orbital-cerebral mucormycosis in patients with diabetes. *Postgrad Med J*

- 2004;80:670-4.
8. Gonzalez CE, Rinaldi MG, Sugar AM. Zygomycosis. *Infect Dis Clin North Am* 2002;16:895-914, vi.
 9. Singh N, Gayowski T, Singh J, Yu VL. Invasive gastrointestinal zygomycosis in a liver transplant recipient: Case report and review of zygomycosis in solid-organ transplant recipients. *Clin Infect Dis* 1995;20:617-20.
 10. Bodenstein NP, McIntosh WA, Vlantis AC, Urquhart AC. Clinical signs of orbital ischemia in rhino-orbitocerebral mucormycosis. *Laryngoscope* 1993;103:1357-61.
 11. Tarrand JJ, Lichterfeld M, Warraich I, Luna M, Han XY, May GS, *et al.* Diagnosis of invasive septate mold infections. A correlation of microbiological culture and histologic or cytologic examination. *Am J Clin Pathol* 2003;119:854-8.
 12. Yohai RA, Bullock JD, Aziz AA, Markert RJ. Survival factors in rhino-orbital-cerebral mucormycosis. *Surv Ophthalmol* 1994;39:3-22.
 13. Ferry AP, Abedi S. Diagnosis and management of rhino-orbitocerebral mucormycosis (phycomycosis). A report of 16 personally observed cases. *Ophthalmology* 1983;90:1096-104.
 14. Walsh TJ, Hiemenz JW, Seibel NL, Perfect JR, Horwith G, Lee L, *et al.* Amphotericin B lipid complex for invasive fungal infections: Analysis of safety and efficacy in 556 cases. *Clin Infect Dis* 1998;26:1383-96.
 15. Uçkay I, Chalandon Y, Sartoretti P, Rohner P, Berney T, Hadaya K, *et al.* Invasive zygomycosis in transplant recipients. *Clin Transplant* 2007;21:577-82.