



# Evaluation of Paraspinal Musculature in Small Breed Dogs with and without Atlantoaxial Instability Using Computed Tomography

Annina Müller<sup>1,2</sup> Franck Forterre<sup>2</sup> Beatriz Vidondo<sup>3</sup> Michael H. Stoffel<sup>4</sup>  
 Ángel Hernández-Guerra<sup>5</sup> Ioannis N. Plessas<sup>6</sup> Martin J. Schmidt<sup>7</sup> Christina Precht<sup>8</sup>

<sup>1</sup>Tierarztpraxis Emmevet AG, Hasle-Rüegsau, Switzerland

<sup>2</sup>Division of Small Animal Surgery, Department of Clinical Veterinary Medicine, Vetsuisse Faculty, University of Bern, Bern, Switzerland

<sup>3</sup>Department of Clinical Research and Veterinary Public Health, Veterinary Public Health Institute, Vetsuisse Faculty, University of Bern, Liebefeld, Switzerland

<sup>4</sup>Division of Veterinary Anatomy, Vetsuisse Faculty, University of Bern, Bern, Switzerland

<sup>5</sup>Department of Veterinary Medicine and Surgery, Universidad Cardenal Herrera-CEU, CEU Universities, Valencia, Spain

<sup>6</sup>Davies Veterinary Specialists Limited, Manor Farm Business Park, Higham Gobion, Herts, United Kingdom

<sup>7</sup>Clinic for Small Animals, Department of Veterinary Clinical Sciences, Justus-Liebig-University Giessen, Giessen, Germany

<sup>8</sup>Division of Clinical Radiology, Department of Clinical Veterinary Medicine, Vetsuisse Faculty, University of Bern, Bern, Switzerland

Address for correspondence Annina Müller, Dr. med. vet. Division of Small Animal Surgery, Department of Clinical Veterinary Medicine, Vetsuisse Faculty, University of Bern, Länggassstrasse 128, 3012 Bern, Switzerland (e-mail: annina.mueller\_16@hotmail.com).

Vet Comp Orthop Traumatol 2022;35:305–313.

## Abstract

**Objective** The aim of this study was to evaluate differences in paraspinal musculature between dogs with and without atlantoaxial instability (AAI) using computed tomography scans.

**Study Design** Retrospective multicentre study evaluating transverse reconstructed computed tomography scans of 83 small breed dogs (34 with and 49 without AAI) for the cross-sectional paraspinal musculature area at three levels (Occiput/C1, mid-C1, mid-C2). Ratio of moments, dorsal-to-ventral muscle-area ratios (d-v-ratio) and ratios of the dorsal and ventral musculature to C2 height (d-C2-ratio and v-C2-ratio) were evaluated for differences between groups using multivariate analysis of variance ( $p < 0.05$ ) taking the head-neck position into account.

**Results** Dogs with AAI showed a significantly lower d-v-ratio at levels 2 and 3, d-C2-ratio at level 2 and ratio of moments at all levels. When head-neck positions were analysed separately, ratio of moments was significantly lower in affected dogs at level 1 and 2. Also lower was d-C2-ratio at level 2, but only in flexed positioning. The head-neck position had a significant influence on ratio of moments and d-v-ratio at all three levels and on d-C2-ratio at level 1.

**Conclusion** Significant changes in muscle area were observed only for the hypaxial muscles at the C1 level, indicating a limited role of muscular adaption in AAI patients. Our results confirm an altered ratio of moments in dogs with AAI. The head-neck position has a significant impact and should be taken into account when evaluating spinal musculature.

## Keywords

- ▶ craniovertebral junction
- ▶ muscle cross-sectional area
- ▶ ratio of moments
- ▶ cervical spine
- ▶ head-neck position

received

May 27, 2021

accepted after revision

April 4, 2022

published online

June 7, 2022

DOI <https://doi.org/>

10.1055/s-0042-1748860.

ISSN 0932-0814.

© 2022. The Author(s).

This is an open access article published by Thieme under the terms of the Creative Commons Attribution-NonDerivative-NonCommercial-License, permitting copying and reproduction so long as the original work is given appropriate credit. Contents may not be used for commercial purposes, or adapted, remixed, transformed or built upon. (<https://creativecommons.org/licenses/by-nc-nd/4.0/>)

Georg Thieme Verlag KG, Rüdigerstraße 14, 70469 Stuttgart, Germany

## Introduction

Atlantoaxial instability (AAI) is a common condition among small breed dogs. It is in many cases a congenital condition with the first clinical signs occurring before the age of 1 year, whereas older dogs often show signs of AAI after trauma. The resulting instability leads to a dorsal dislocation of the dens axis causing compression of the cervical spinal cord. The clinical signs range from neck pain to tetraplegia and in severe cases even respiratory paralysis and death.<sup>1-6</sup> Atlantoaxial instability is frequently diagnosed in combination with other craniovertebral junction (CVJ) anomalies.<sup>6</sup>

The atlantoaxial joint is a pivot joint that allows the head and first cervical vertebra to rotate around the longitudinal axis of the dens.<sup>7</sup> The surrounding ligaments, muscles and fasciae play an important role in the stabilization of the atlantoaxial joint. The dorsal atlantoaxial ligament and the alar ligaments prevent overrotation, while the transverse ligament limits the dorsal displacement of the dens axis during flexion of the head.<sup>5,8,9</sup> Furthermore, the joint is stabilized by paraspinal muscles that insert on the cranial cervical vertebrae or the occiput. They are divided in epaxial and hypaxial musculature and most of the muscles that span the atlantoaxial joint control the movement of the head (►Table 1). They include the *Musculus obliquus capitis caudalis*, which has the biggest impact on the joint and acts as its rotator.<sup>7</sup>

The pathogenesis of AAI is still not fully understood. Many studies have shown that a lack of ligamentous support, usually in combination with congenital malformations, plays an important role and facilitates the dislocation of the dens.<sup>4,8-10</sup> The role of the musculature in the pathogenesis of AAI is yet to be evaluated as studies about the subject are scarce. If the joint is unstable due to lack of ligamentous support, other supportive structures such as musculature experience an increased load, which could lead to a chronic compensatory hypertrophy of the musculature.<sup>11</sup> Quantifying the extent of hypertrophy is possible by examining the increase in cross-sectional area of the muscle in computed tomography (CT) imaging.<sup>12-14</sup>

The aim of this study was to evaluate whether there is a difference in cross-sectional paraspinal muscle surface area and ratio of moments between small breed dogs with and without AAI using CT scans. We hypothesized that there are differences in ratio of moments between dogs with and without AAI and that the paraspinal muscle cross-sectional area is increased in dogs with AAI due to compensatory mechanisms and the chronicity of the disease.

## Materials and Methods

### Patient Selection

Medical records of four different institutions (University of Bern Switzerland, Davies Veterinary Specialists United

**Table 1** Overview of considered epaxial and hypaxial musculature at the three different levels

Level	Epaxial musculature	Hypaxial musculature
1	<i>M. longissimus capitis</i>	<i>M. longus capitis</i>
	<i>M. semispinalis capitis</i>	<i>Mm. rectus capitis ventralis</i>
	<i>M. rectus capitis dorsalis major</i>	<i>Mm. rectus capitis lateralis</i>
	<i>M. rectus capitis dorsalis minor</i>	
	<i>M. obliquus capitis cranialis</i>	
2	<i>M. longissimus</i>	<i>M. longus colli</i>
	<i>M. spinalis et semispinalis cervicis</i>	<i>M. longus capitis</i>
	<i>M. semispinalis capitis</i>	<i>Mm. rectus capitis ventralis</i>
	<i>M. rectus capitis dorsalis major</i>	<i>Mm. rectus capitis lateralis</i>
	<i>M. rectus capitis dorsalis minor</i>	
	<i>M. obliquus capitis cranialis</i>	
	<i>M. obliquus capitis caudalis</i>	
<i>Mm. intertransversarii dorsales cervicis</i>		
3	<i>M. longissimus</i>	<i>M. longus colli</i>
	<i>M. spinalis et semispinalis cervicis</i>	<i>M. longus capitis</i>
	<i>M. semispinalis capitis</i>	<i>Mm. rectus capitis ventralis</i>
	<i>Mm. multifidi</i>	<i>Mm. rectus capitis lateralis</i>
	<i>M. rectus capitis d. major</i>	
	<i>M. obliquus cap. cranialis</i>	
	<i>M. obliquus cap. caudalis</i>	
	<i>Mm. intertransversarii dorsales cervicis</i>	

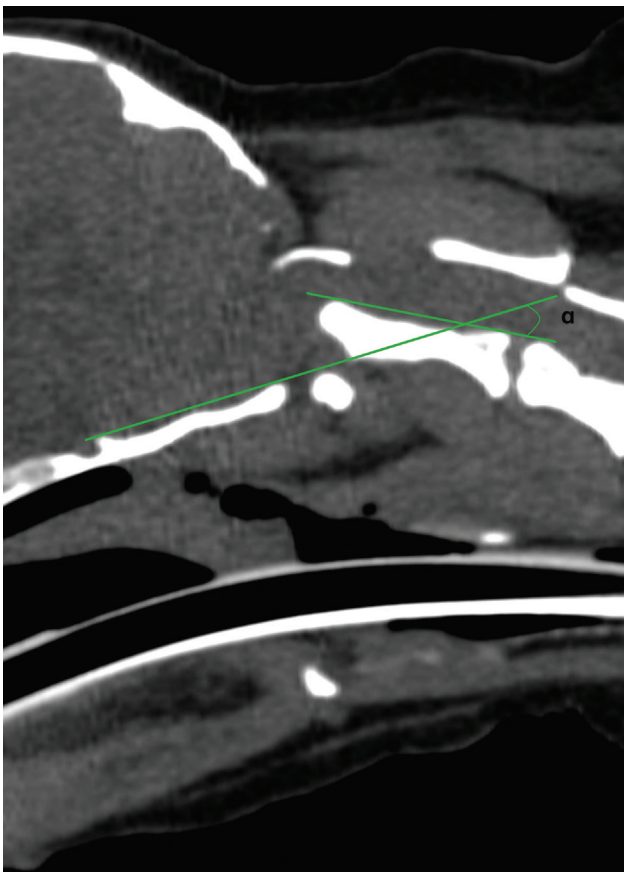
Kingdom, Justus-Liebig-University Giessen Germany and University Cardenal Herrera-CEU Spain) were retrospectively searched for toy and small breed dogs with CT scans of the craniocervical region presented between 2009 and 2020. Data retrieved from medical records included signalment, clinical signs and the CT scans of the craniocervical region. Dogs with clinical signs and radiologically confirmed AAI were assigned to the AAI-group. The control group consisted of dogs without clinical or radiological findings of AAI or any other cervical spinal disease. Computed tomography scans in those dogs had been performed to evaluate health issues unrelated to the CVJ, such as rhinitis or tracheal collapse.

Regarding the age, the patients were divided into two groups; dogs  $\leq 1$  year and dogs  $> 1$  year of age. Regarding head-neck position, the patients were divided into two categories: extended for head-neck positions  $< 25$  degrees and flexed for positions  $\geq 25$  degrees. The angle of the head-neck position for each patient was measured according to Upchurch and colleagues ( $\rightarrow$ Fig. 1).<sup>15</sup> Head-neck positions were included in our statistical analysis to avoid bias caused by different positioning of the patients during CT.

### Imaging and Image Review

The CT scans were performed at different institutions without a standardized protocol.

The scans had to include the atlantooccipital joint and the first two vertebrae. If this region was not entirely visible on



**Fig. 1** Method of measuring the angle of the head position according to Upchurch and colleagues.<sup>15</sup>

the CT scans, only the available levels were analysed. The CT scans were reviewed by a single observer, a graduated veterinarian after training (A.M.) under the supervision of a board-certified veterinary radiologist (C.P.) using the DICOM viewer IMPAX EE (IMPAX EE, Agfa Healthcare, Belgium). The reviewer was blinded to group information.

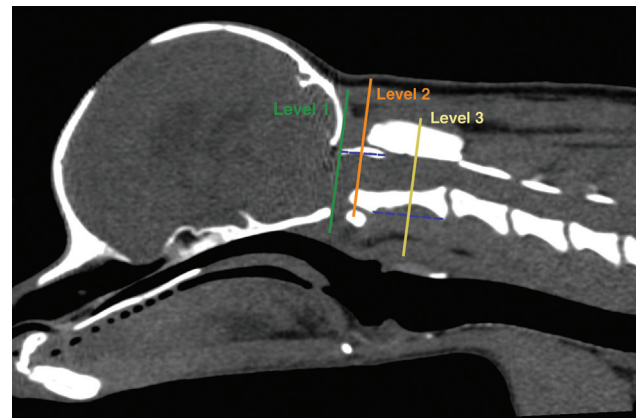
### Measurements

Every measurement was performed at three different anatomical levels on transverse reconstructed CT scans in the soft tissue window. The exact position of the level was determined on sagittal reconstructions ( $\rightarrow$ Fig. 2). Level 1 was defined as the connection line between basion and opisthion, traversing across the base of the occiput (also known as the McRae's line). Level 2 was set at the centre of the dorsal arch of the atlas. Level 3 was set at the centre of the vertebral body of the axis. Level 2 and 3 were planned parallel to level 1 to minimize the variations caused by obliquity. To normalize for differences in body weight and size, we used ratios to describe muscle cross-sectional area. At each level, the following measurements were performed on transverse reconstructed CT scans.

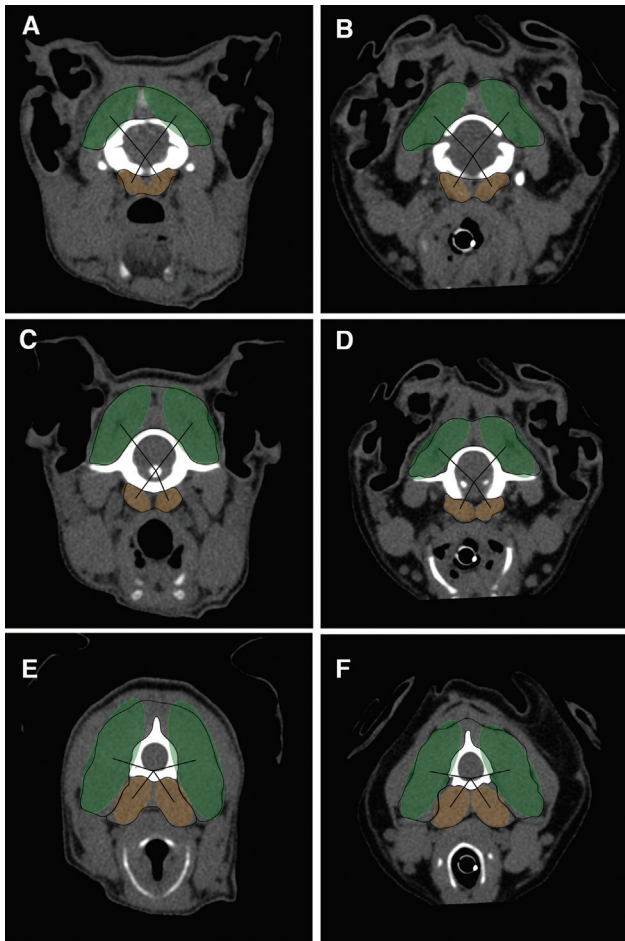
### Muscle Cross-Sectional Area Ratio (d-v-Ratio)

The paraspinal musculature was outlined using the integrated freehand tool and the area was calculated by the DICOM viewer program. At each level, only muscle groups that could clearly be identified on consecutive images were considered ( $\rightarrow$ Table 1). Cross-sectional area of the left- and right-hand side musculature was summarized to epaxial and hypaxial musculature respectively ( $\rightarrow$ Fig. 3). The area ratio between the epaxial and hypaxial musculature cross-sectional area was calculated using the following equation:

$$\text{Area ratio} = \frac{\text{Epaxial (dorsal) musculature area}}{\text{Hypaxial (ventral) musculature area}}$$



**Fig. 2** Sagittal reconstructed computed tomography scan showing the localization of the three different levels where measurements were performed. The blue dotted lines illustrate which landmarks were used to determine the centre of the atlas and axis respectively.



**Fig. 3** Transverse reconstructed computed tomography scans of a patient from the control (A, C, E) and atlantoaxial instability (B, D, F) group, respectively, at levels 1 (A and B), 2 (C and D) and 3 (E and F) illustrating the cross-sectional muscle area used to calculate the d-ratio, the d-C2 ratio and the v-C2 ratio.

**Ratio of Epaxial and Hypaxial Muscle Cross-Sectional Area to the Height of C2 (d-C2-Ratio and v-C2-Ratio)**

To normalize muscle cross-sectional area to the size of the dog, a ratio between the muscle cross-sectional area and the height of the vertebral body C2 was calculated. The muscle cross-sectional area was measured as described under section ‘Muscle Cross-Sectional Area Ratio (d-v-Ratio)’. It was set in relation to the height of the vertebral body of C2, measured at the narrowest level of the vertebral body of C2, perpendicular to the spinal canal. The ratio was calculated for epaxial (dorsal) and hypaxial (ventral) musculature separately using the following formulas, resulting in two separate values:

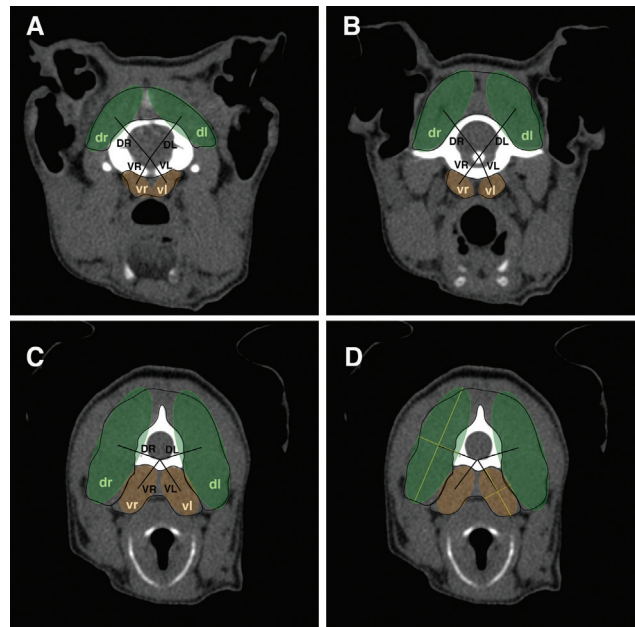
$$\text{Ratio of epaxial [dorsal] musculature area to height of C2} = \frac{\text{Epaxial paraspinal musculature area}}{\text{Height of C2}}$$

$$\text{Ratio of hypaxial [ventral] musculature area to height of C2} = \frac{\text{Hypaxial paraspinal musculature area}}{\text{Height of C2}}$$

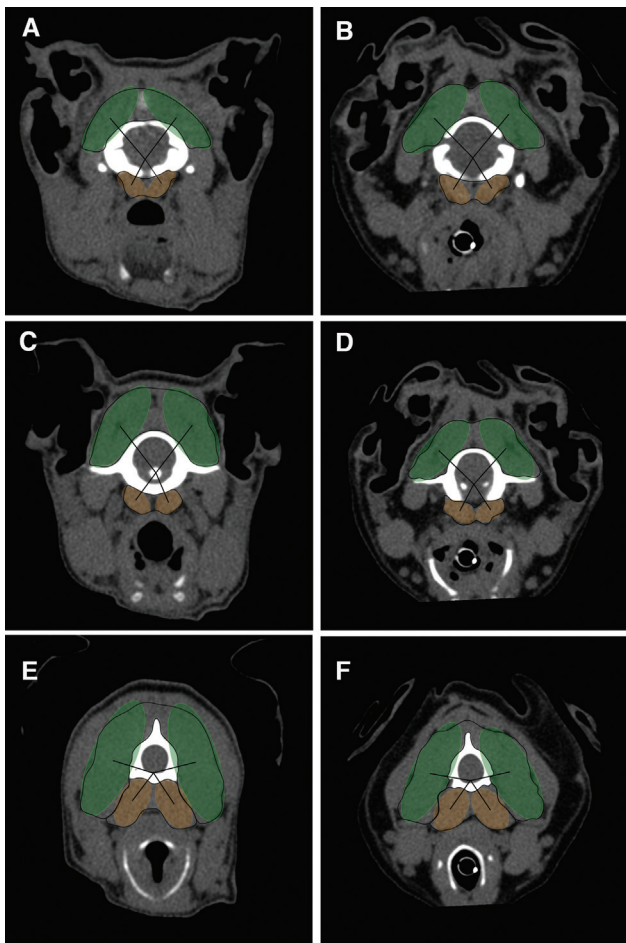
**Ratio of Moments**

The ratio of dorsal-to-ventral moments was calculated as described previously by Hartmann and colleagues<sup>16</sup> to evaluate estimated moments exerted on the dens axis. The dens is assumed to be the centre of the force transmission in our area of interest since it works as the central rotation point in the movement of the atlantoaxial joint. It was therefore used as central reference point to describe the lever arms of each muscle group instead of the centre of the intervertebral disc. Using a line parallel to the vertebral body, the dens was projected from its anatomical localization onto the levels cranial and caudal to the dens (level 1 and 3). If the dens was fractured or not identifiable due to hypoplasia, the reference point was set at the location where the dens was to be expected. According to Hartmann and colleagues, four ellipsoid models were applied over the epaxial and hypaxial left and right muscle area. The assumptive centre of the muscle area was assumed to be the centre of the ellipsoid models. It was determined by fitting points to the four apexes of the ellipsoid model and by then connecting the points with two perpendicular lines. A line was drawn from these assumptive centres to the centre of the dens or its level respectively (→Figs. 4 and 5).<sup>16</sup> The following formula was used to calculate the ratio of moments:

$$\text{Ratio of moments} = \frac{(\text{dr} \times \text{DR}) + (\text{dl} \times \text{DL})}{(\text{vr} \times \text{VR}) + (\text{vl} \times \text{VL})}$$



**Fig. 4** Transverse reconstructed computed tomography scans with area measurements of the epaxial (green) and hypaxial (orange) musculature at level 1 (A), 2 (B) and 3 (C). (dr, dorsal right; dl, dorsal left; vr, ventral right; vl, ventral left). D: The oval shapes represent the assumptive muscle area for calculations (green for epaxial musculature, orange for hypaxial musculature). Black lines show the distance from the assumptive muscle centre to the approximate location of the dens axis (DR, dorsal right; DL, dorsal left; VR, ventral right; VL, ventral left). Yellow lines show how the assumptive centre of the musculature was measured.



**Fig. 5** Transverse reconstructed computed tomography scans of a patient from the control (A, C, E) and atlandoaxial instability (B, D, F) group, respectively, at levels 1 (A and B), 2 (C and D) and 3 (E and F) illustrating the ratio of moments.

### Statistical Analysis

All statistical analyses were performed using NCSS 2021 Statistical Software (NCSS; LCC, Kaysville, Utah, United States). For all data, descriptive statistics were performed and the normality of the variables was first visualized using histograms and then tested using Shapiro–Wilk and D’Agostino–Pearson Omnibus test. To test for differences between the groups for the four main variables (ratio of moments, d-v-ratio, d-C2-ratio, v-C2-ratio) and adjusting for age, gender and head-neck position, the multivariate analysis of variance (MANOVA) was used. Breed could be tested for Yorkshire Terriers only as other breeds were not sufficiently represented in our sample to test for their influence. There was not enough data available to test for the difference between institutions. In the final MANOVA model, we only included groups and head-neck positions as the other variables did not show significant differences between the groups.

Additionally, in the absence of evidence of an influence of age, gender and breed in our sample, MANOVAs for differences between the two groups (AAI and control) for the three main variables were performed for each extended and flexed head-neck position separately.

All analyses were performed for each level separately and the level of significance was set at a value of  $p < 0.05$ .

### Results

Computed tomography scans of a total of 83 dogs were analysed with 34 dogs in the AAI group and 49 dogs in the control group, after excluding the datasets of 4 dogs of the control group due to poor image quality. Twenty-six dogs from the control group had been euthanized for medical reasons unrelated to this study before CT examination.

In the AAI group, the most frequent breed was Yorkshire Terrier ( $n = 14$ ), followed by Chihuahua ( $n = 10$ ), Maltese ( $n = 3$ ), Bichon Frisé ( $n = 1$ ), Toy Poodle ( $n = 1$ ), Miniature Pinscher ( $n = 1$ ), Havanese dog ( $n = 1$ ), Cavalier King Charles Spaniel ( $n = 1$ ), Pug ( $n = 1$ ) and Italian Greyhound ( $n = 1$ ). There were 17 female and 17 male patients in the AAI group. The mean age  $\pm$  standard deviation [SD] was  $3.17 \pm 2.94$  years. Most of the dogs ( $n = 27$ ) were examined and scanned at the University of Bern and seven dogs in other institutions (Davies Veterinary Specialists, United Kingdom ( $n = 3$ ), Justus-Liebig-University Giessen, Germany ( $n = 1$ ) and University Cardenal Herrera-CEU, Spain ( $n = 3$ )). Fifteen dogs were scanned in flexed and 19 dogs in extended head-neck position.

In the control group, the breeds included Yorkshire Terrier ( $n = 18$ ), Chihuahua ( $n = 16$ ), Papillon ( $n = 8$ ), Maltese ( $n = 2$ ), Miniature Pinscher ( $n = 2$ ), Shih Tzu ( $n = 2$ ) and Japanese Chin ( $n = 1$ ). Twenty-seven patients were female and 22 were male. The mean age  $\pm$  SD was  $5.2 \pm 4.17$  years. The dogs in the control group were significantly ( $p < 0.001$ ) older than in the AAI group. All dogs were scanned at the University of Bern. Eight dogs were scanned in flexed, and 41 dogs in extended head-neck position.

There was no evidence of a difference between the two age groups or the gender on variables obtained to describe the muscle cross-sectional area, or between measurements obtained from euthanized dogs compared with dogs under anaesthesia.

The results of the analysis of differences between AAI and control groups adjusted for age, gender and head-neck position are presented in **Table 2**. The d-v-ratio was significantly smaller in the affected dogs at level 2 ( $p = 0.044$ ) and level 3 ( $p = 0.016$ ). The d-C2-ratio was significantly lower in affected dogs at level 2 ( $p = 0.046$ ). There was no significant difference of the v-C2-ratio between groups. The affected dogs showed a significantly lower mean ratio of moments compared with the control group at level 1 ( $p < 0.001$ ), level 2 ( $p < 0.001$ ) and level 3 ( $p = 0.012$ ).

The influence of the head-neck position was significant for the ratio of moments at all levels ( $p < 0.001$ ,  $p < 0.001$  and  $p = 0.012$  respectively) as well as for d-v-ratio ( $p < 0.001$  for all levels). It showed significance for d-C2-ratio at level 1 ( $p = 0.011$ ), but not for level 2, at which the difference between groups for d-C2-ratio was significant.

The results of the separate analysis for the extended and flexed head-neck position, respectively, are presented in **Tables 3** and **4**. The d-C2-ratio showed a significant

**Table 2** Count (c = control / a = AAI-affected), mean and standard deviation at each level and *p*-values for differences between groups as well as head-neck positions (MANOVA model taking group and head-neck position into account)

Variable	Level	Count (c/a)	Mean ± SD control	Mean ± SD AAI	<i>p</i> -Value for differences between groups	<i>p</i> -Value for differences between head-neck positions
Dorsal-to-ventral ratio	1	49/34	4.04 ± 0.82	3.61 ± 0.70	Not significant	< 0.001
	2	48/34	4.18 ± 0.79	3.39 ± 0.71	0.044	< 0.001
	3	47/28	3.55 ± 0.56	3.07 ± 0.54	0.016	< 0.001
Dorsal muscle CSA to height of C2	1	48/33	143.42 ± 60.04	120.54 ± 47.24	Not significant	0.011
	2	47/33	163.88 ± 66.19	124.55 ± 44.54	0.046	Not significant
	3	46/27	258.12 ± 126.31	220.59 ± 73.99	Not significant	Not significant
Ventral muscle CSA to height of C2	1	48/33	35.67 ± 14.70	33.45 ± 9.78	Not significant	Not significant
	2	47/33	40.24 ± 16.84	36.78 ± 9.42	Not significant	Not significant
	3	46/27	73.13 ± 35.02	72.06 ± 19.60	Not significant	Not significant
Ratio of moments	1	49/34	7.83 ± 2.43	4.40 ± 2.04	< 0.001	< 0.001
	2	48/34	7.24 ± 1.95	4.04 ± 1.75	< 0.001	< 0.001
	3	47/28	5.07 ± 1.14	4.21 ± 1.03	0.012	0.012

Abbreviations: AAI, atlantoaxial instability; CSA, cross-sectional area; MANOVA, multivariate analysis of variance; SD, standard deviation. Note: Cross-sectional area is referred to as CSA. *p*-values >0.05 are not shown.

decrease for dogs with AAI at level 2 ( $p = 0.046$ ) in flexed head-neck position. The ratio of moments was significantly lower for dogs with AAI in both extended and flexed head-neck position at level 1 ( $p < 0.001$  for both) and level 2

( $p < 0.001$  and  $p = 0.008$  respectively). No significant differences between groups in all other measurements of the muscle area ratios were detected when head-neck positions were analysed separately.

**Table 3** Count (c = control / a = AAI-affected), mean and standard deviation at each level and *p*-values for differences between groups in flexed head position (MANOVA model with group only)

Variable	Level	Count (c/a)	Mean ± SD control	Mean ± SD AAI	<i>p</i> -Value for differences between groups
Dorsal-to-ventral ratio	1	8/15	3.46 ± 0.61	3.23 ± 0.61	Not significant
	2	7/15	3.47 ± 0.99	2.83 ± 0.57	Not significant
	3	7/10	3.33 ± 0.62	2.67 ± 0.43	Not significant
Dorsal muscle CSA to height of C2	1	8/14	115.17 ± 20.60	92.71 ± 17.93	0.046
	2	7/14	151.99 ± 49.28	94.26 ± 20.40	Not significant
	3	7/9	209.91 ± 51.17	173.76 ± 31.33	Not significant
Ventral muscle CSA to height of C2	1	8/14	34.09 ± 8.24	30.13 ± 7.13	Not significant
	2	7/14	45.82 ± 17.46	34.54 ± 5.96	Not significant
	3	7/9	64.84 ± 19.90	67.64 ± 13.86	Not significant
Ratio of moments	1	8/15	6.74 ± 2.25	3.17 ± 1.61	0.001
	2	7/15	5.68 ± 2.20	2.81 ± 1.46	0.008
	3	7/10	4.82 ± 1.54	3.43 ± 0.79	Not significant

Abbreviations: AAI, atlantoaxial instability; CSA, cross-sectional area; MANOVA, multivariate analysis of variance; SD, standard deviation. Note: *p*-Values >0.05 are not shown.

**Table 4** Count (c = control / a = AAI-affected), mean and standard deviation at each level and *p*-values for differences between groups in extended head position (MANOVA model with group only)

Variable	Level	Count (c/a)	Mean ± SD control	Mean ± SD AAI	<i>p</i> -Values
Dorsal-to-ventral ratio	1	41/19	4.16 ± 0.81	3.91 ± 0.64	Not significant
	2	41/19	4.28 ± 0.72	3.83 ± 0.44	Not significant
	3	40/18	3.59 ± 0.56	3.30 ± 0.47	Not significant
Dorsal muscle CSA to height of C2	1	40/19	137.92 ± 38.07	141.04 ± 51.86	Not significant
	2	40/19	155.09 ± 48.51	146.85 ± 44.58	Not significant
	3	39/18	241.76 ± 77.97	244.00 ± 78.55	Not significant
Ventral muscle CSA to height of C2	1	40/19	33.06 ± 8.44	35.89 ± 10.88	Not significant
	2	40/19	36.86 ± 12.47	38.43 ± 11.20	Not significant
	3	39/18	67.63 ± 21.94	74.26 ± 21.94	Not significant
Ratio of moments	1	41/19	8.08 ± 2.48	5.36 ± 1.83	< 0.001
	2	41/19	7.49 ± 1.86	5.01 ± 1.29	< 0.001
	3	40/18	5.12 ± 1.10	4.64 ± 0.89	Not significant

Abbreviations: AAI, atlantoaxial instability; CSA, cross-sectional area; MANOVA, multivariate analysis of variance; SD, standard deviation.  
Note: *p*-Values >0.05 are not shown.

As supplementary material, the absolute measures of the epaxial (dorsal) and hypaxial (ventral) muscle area measurements are presented in ►**Supplementary Table S1** (online only).

## Discussion

This study compared cross-sectional paraspinal muscle surface area and ratio of moments of small breed dogs with and without AAI using CT scans with the aim to evaluate the role of the paraspinal musculature in AAI.

The ratio of moments showed a significant decrease in dogs with AAI at all levels. Analysing the flexed and extended head-neck positions separately, the ratio of moments was significantly lower for dogs with AAI at level 1 (Occiput/C1) and 2 (mid-C1). This may be explained by the dorsal luxation of the axis and/or dorsal angulation of the dens due to disruption of the ligaments of the atlantoaxial joint.<sup>8,9</sup> The dorsal dislocation of the dens axis as the central reference point of forces leads to a decreased length of the lever arms of the epaxial musculature and increased length of the ventral musculature resulting in a lower ratio of moments. The d-v-ratio was significantly lower in dogs with AAI at level 2 (mid-C1) and 3 (mid-C2). Interpreted in combination with the d-C2-ratio, which was significantly smaller in affected dogs at level 2, the results indicate a decrease in epaxial musculature cross-sectional area in dogs with AAI. However, when analysing head-neck positions separately, a significantly lower d-C2-ratio was observed at level 2 in a flexed head-neck position only. Therefore, our hypothesis of an increased paraspinal muscle cross-sectional area in dogs with AAI due to compensatory hypertrophy is not supported.

To our knowledge, no previous studies have assessed the changes in paraspinal musculature cross-sectional area around the atlantoaxial joint in small breed dogs with AAI.

Literature on the topic is limited. A theory for the lack of compensatory mechanisms or increase in paraspinal musculature cross-sectional area was found in human literature. A similar situation occurs in patients with acute and chronic low back pain, where instability of the lumbar spine plays a role in the pathogenesis.<sup>17</sup> In acute low back pain, there is evidence of a reduction in cross-sectional area for the multifidus muscle.<sup>18,19</sup> The mechanism seems to be of neural origin, where reduced muscle activation leads to disuse and therefore atrophy of the muscle. In an experimental study in pigs, it was shown that atrophy after disc lesions occurs as early as 3 days after injury.<sup>20</sup> In subacute or chronic low back pain, muscle atrophy tends to recover to a certain degree but structural inflammatory-related changes such as fibrosis, fatty infiltration and slow-to-fast muscle fibre transition are commonly described. However, only the multifidus muscle showed a consistent decrease in cross-sectional area. Similar to our study, results for the other muscles varied and did not show final evidence of a measurable change in muscle cross-sectional area.<sup>18</sup>

Whether the pathogenesis of AAI in patients in our study was acute or chronic remains unknown. Despite the usually acute clinical onset, changes such as distended or missing atlantoaxial ligaments make a chronic course of the disease likely, which is also assumed to be the case for the patients in our study. One sign consistent with an acute event is a longitudinal tear in the tectorial membrane.<sup>21</sup> The tectorial membrane is formed by the fibrous layer of the joint capsule and extends dorsally between the arch of the atlas and the axis as the dorsal atlantoaxial membrane.<sup>9</sup> In our CT scan-based study, the tectorial membrane could not be evaluated. A prospective study of AAI cases with repetitive magnetic resonance imaging studies would be necessary to draw conclusions on imaging-based evaluation of an acute or chronic pathogenesis of AAI and the evolution of muscle cross-sectional area and composition over time.

The head-neck position was an important factor for both the measurement of the ratio of moments and the muscle cross-sectional area ratios. Results for the multivariate analysis showed a significant influence of the head-neck position on the ratio of moments and d-v-ratio at all levels and d-C2-ratio at level 1. This supports the results of a recent study, which has shown the importance of standardized head-neck positioning for diagnostic imaging of the CVJ.<sup>22</sup> If the head-neck positions were analysed separately, a significantly decreased d-C2-ratio was observed at level 2 in a flexed head-neck position. This observation may be indicating a lower epaxial muscle cross-sectional area due to excessive stretching of the dorsal muscle segment in dogs with an unstable atlantoaxial transition rather than a true atrophy. In addition, the sample size of dogs in flexed head position (affected and control) was rather small and might have affected the validity of these results. For future studies examining the musculature of the cranial cervical spine, it is advisable to use a standardized head-neck position.

When considering the statistical results of the three different levels, it becomes evident that most of the significant changes are shown at level 1 and 2. These levels are measured at the McRae line and centrally in the dorsal arch of the atlas, respectively, and therefore closest to the centre of forces. At level 3, most variables show no or only little significance. In human lower back pain, a similar effect can be seen. Changes in musculature cross-sectional area shortly after a disc injury in the lumbar spine area occur mostly at the affected segment and become generalized after many months only.<sup>18,20</sup>

The success of AAI therapy depends on the formation of fibrous connective tissue around the atlantoaxial joint, especially when a conservative approach, such as external stabilization and cage rest, is chosen.<sup>4,23,24</sup> Muscle strengthening as well is a suggested therapy option in dogs with AAI, and understanding factors such as development of muscle atrophy, or imbalance of strength between epaxial and hypaxial muscles could help to further guide therapy.

There are several limitations to this study, mostly due to its retrospective nature. First, the distribution of the patients' age was not matched. Age affects muscle mass and muscle quality in older dogs. They show muscle loss and an increased fat content of the musculature as compared with younger dogs.<sup>25</sup> Yet the significance of the results remained unchanged when the age was taken into account in the statistical analysis. No standardized imaging protocol was used in this multicentre study. The main issue arising from this shortcoming is the variability in head-neck positioning and its possible influence on the CVJ. To address this issue, we included the factor head-neck-position in our statistical analysis.

The choice of analysing CT scans was made due to CT being a reliable tool for the evaluation of paraspinal musculature cross-sectional area and ratio of moments along with the availability of a larger number of patients.<sup>14,16,26</sup> For future research, it might be of interest to analyse the composition and quality of the musculature as well, preferably in magnetic resonance imaging studies. Increased fat content of the

musculature is a common finding in dogs as well as humans with chronic spinal disease and it is likely that dogs with AAI have lower quality musculature as well.<sup>18,27</sup> Evaluating this might provide interesting insights into management options and possibly highlight the importance of muscle strengthening further.

In conclusion, our study showed that the role of musculature in the pathogenesis of AAI is limited. We could not demonstrate a consistent change in paraspinal musculature cross-sectional area for small breed dogs with AAI compared with unaffected individuals, but instead confirm an altered ratio of moments in those dogs in the area of the atlantoaxial joint. The study further emphasizes the importance of standardized imaging protocols including standardized head-neck position when examining the CVJ.

#### Authors' Contributions

A.M., C.P., and F.F. contributed to the conception of the study, study design, acquisition of data, data analysis and interpretation. B.V. contributed to the study analysis and interpretation. M.H.S. contributed to the conception of the study and the evaluation of data. A.M.H., I.N.P., and M.J.S. contributed to the acquisition of data. All authors revised and approved the manuscript before submitting.

#### Funding

None.

#### Conflict of Interest

None declared.

#### References

- Denny HR, Gibbs C, Waterman A. Atlanto-axial subluxation in the dog: a review of thirty cases and an evaluation of treatment by lag screw fixation. *J Small Anim Pract* 1988;29(01):37-47
- Fossum TW. *Small Animal Surgery*. Elsevier Health Sciences 2018. Accessed April 17, 2022 at: <https://books.google.ch/books?id=kIBUDwAAQBAJ>
- Geary JC, Oliver JE, Hoerlein BF. Atlanto axial subluxation in the canine. *J Small Anim Pract* 1967;8(10):577-582
- Havig ME, Cornell KK, Hawthorne JC, McDonnell JJ, Selcer BA. Evaluation of nonsurgical treatment of atlantoaxial subluxation in dogs: 19 cases (1992-2001). *J Am Vet Med Assoc* 2005;227(02):257-262
- Slanina MC. Atlantoaxial instability. *Vet Clin North Am Small Anim Pract* 2016;46(02):265-275
- Waschk MA, Vidondo B, Carrera I, et al. Craniovertebral junction anomalies in small breed dogs with atlantoaxial instability: a multicentre case-control study. *Vet Comp Orthop Traumatol* 2019;32(01):33-40
- Salomon FV, Geyer H, Gille U. *Anatomie für die Tiermedizin*. 3., aktualisierte und erweiterte Auflage. Enke Verlag 2015
- Planchamp B, Bluteau J, Stoffel MH, Precht C, Schmidli F, Forterre F. Morphometric and functional study of the canine atlantoaxial joint. *Res Vet Sci* 2020;128:76-85
- Reber K, Bürki A, Vizcaino Reves N, et al. Biomechanical evaluation of the stabilizing function of the atlantoaxial ligaments under shear loading: a canine cadaveric study. *Vet Surg* 2013;42(08):918-923
- Parry AT, Upjohn MM, Schlegl K, Kneissl S, Lamb CR. Computed tomography variations in morphology of the canine atlas in dogs with and without atlantoaxial subluxation. *Vet Radiol Ultrasound* 2010;51(06):596-600



- 11 Terena SML, Fernandes KPS, Bussadori SK, Deana AM, Mesquita-Ferrari RA. Systematic review of the synergist muscle ablation model for compensatory hypertrophy. *Rev Assoc Med Bras* (1992) 2017;63(02):164–172
- 12 Boström AF, Lappalainen AK, Danneels L, Jokinen TS, Laitinen-Vapaavuori O, Hielm-Björkman AK. Cross-sectional area and fat content in dachshund epaxial muscles: an MRI and CT reliability study. *Vet Rec Open* 2018;5(01):e000256
- 13 Brumitt J, Cuddeford T. Current concepts of muscle and tendon adaptation to strength and conditioning. *Int J Sports Phys Ther* 2015;10(06):748–759
- 14 Cain B, Jones JC, Holásková I, Freeman L, Pierce B. Feasibility for measuring transverse area ratios and asymmetry of lumbosacral region paraspinal muscles in working dogs using computed tomography. *Front Vet Sci* 2016;3:34
- 15 Upchurch JJ, McGonnell IM, Driver CJ, Butler L, Volk HA. Influence of head positioning on the assessment of Chiari-like malformation in Cavalier King Charles spaniels. *Vet Rec* 2011;169(11):277–277
- 16 Hartmann K, Düver P, Kaiser S, Fischer C, Forterre F. CT-scan based evaluation of dorsal-to-ventral ratios of paraspinal musculature in chondrodystrophic and non-chondrodystrophic dogs. *Front Vet Sci* 2020;7:577394
- 17 Ohtori S, Miyagi M, Inoue G. Sensory nerve ingrowth, cytokines, and instability of discogenic low back pain: a review. *Spine Surg Relat Res* 2018;2(01):11–17
- 18 Hodges PW, Danneels L. Changes in structure and function of the back muscles in low back pain: different time points, observations, and mechanisms. *J Orthop Sports Phys Ther* 2019;49(06):464–476
- 19 Park MS, Moon SH, Kim TH, et al. Paraspinal muscles of patients with lumbar diseases. *J Neurol Surg A Cent Eur Neurosurg* 2018; 79(04):323–329
- 20 Hodges P, Holm AK, Hansson T, Holm S. Rapid atrophy of the lumbar multifidus follows experimental disc or nerve root injury. *Spine* 2006;31(25):2926–2933
- 21 Forterre F, Precht C, Riedinger B, Bürki A. Biomechanical properties of the atlantoaxial joint with naturally-occurring instability in a toy breed dog. A comparative descriptive cadaveric study. *Vet Comp Orthop Traumatol* 2015;28(05):355–358
- 22 Planchamp B, Forterre F, Vidondo B, Beugger A, Müller A, Precht C. Influence of the head neck position on imaging measurements used to assess the craniovertebral junction in small breed dogs: a Cadaveric study. *Vet Comp Orthop Traumatol* 2021;34(04): 268–278
- 23 Beaver DP, Ellison GW, Lewis DD, Goring RL, Kubilis PS, Barchard C. Risk factors affecting the outcome of surgery for atlantoaxial subluxation in dogs: 46 cases (1978-1998). *J Am Vet Med Assoc* 2000;216(07):1104–1109
- 24 Stalin C, Gutierrez-Quintana R, Faller K, Guevar J, Yeaman C, Penderis J. A review of canine atlantoaxial joint subluxation. *Vet Comp Orthop Traumatol* 2015;28(01):1–8
- 25 Sutherland-Smith J, Hutchinson D, Freeman LM. Comparison of computed tomographic attenuation values for epaxial muscles in old and young dogs. *Am J Vet Res* 2019;80(02):174–177
- 26 Mitsiopoulos N, Baumgartner RN, Heymsfield SB, Lyons W, Gallagher D, Ross R. Cadaver validation of skeletal muscle measurement by magnetic resonance imaging and computerized tomography. *J Appl Physiol* (1985) 1998;85(01):115–122
- 27 Lerer A, Nykamp SG, Harriss AB, Gibson TWG, Koch TG, Brown SHM. MRI-based relationships between spine pathology, intervertebral disc degeneration, and muscle fatty infiltration in chondrodystrophic and non-chondrodystrophic dogs. *Spine J* 2015;15(11):2433–2439