

Epidermoid cyst of the facial skin: an investigative case report

SAGE Open Medical Case Reports
Volume 10: 1–6
© The Author(s) 2022
Article reuse guidelines:
sagepub.com/journals-permissions
DOI: 10.1177/2050313X221089756
journals.sagepub.com/home/sco



Shivani Jain¹ , Ramesh Ram Fry², Jaspreet Kaur¹,
Anusha Sidhwa², Nityanand Jain³  and Mara Pilmane³ 

Abstract

Orofacial epidermoid cysts are rare entities that present as encapsulated, subepidermal painless masses, usually slow growing and asymptomatic. They are mostly limited to the floor of the mouth, tongue, lips, palate or jaws. Herein, we present an atypical case of epidermoid cyst originating from the left cheek facial epidermis in a 27-year-old male patient. The cyst presented as a swelling that was slowly progressing in size since the past 1 year with no discharge. Complete excision of the mass was done, and the cyst cavity was found to be filled with a cheesy-white, granular, semi-solid proteinaceous exudate which completely occluded the punctum. The patient post-operatively revealed persistent mechanical trauma due to incorrect workplace habits he developed, which led to the formation of the epidermoid cyst. Patient education was done and was advised to use proper workplace instrumentation.

Keywords

Epidermoid cyst, oral cavity, cheesy exudate, facial skin, cystic malformations.

Date received: 28 December 2021; accepted: 8 March 2022

Introduction

Epidermoid cysts are slow growing firm, smooth, freely movable, and painless masses presenting at the subcutaneous-dermal level with an intact skin surface and no apparent drainage point.¹ These cysts are anatomically confined and can develop in any part of the body, but are most frequently reported on the face, neck, scalp, genitalia and trunk.² In the orofacial region (7% of all reported cases), they are localized usually on the floor of the mouth and/or on the tongue, lips, palate, jaws and cheek.³ Furthermore, most cases reported in craniofacial region are in the midline, or above or below the mylohyoid muscle,^{4–6} presenting as sublingual or submental swelling, respectively.

The cysts usually remain asymptomatic with/without localized inflammation. However, upon gaining large enough size, they can decrease the quality of life due to distortion of anatomical shape and appearance. In most sporadic cases, cysts tend to develop due to mechanical trauma or blunt injury to the soft tissue. However, in majority of the reported cases, the exact cause remains unknown. Herein, we present a case of epidermoid cyst with occluded punctum and no discharge, which developed due to persistent mechanical injury to the facial skin because of incorrect occupational habits developed at the workplace.

Case report

A 27-year-old male patient working as an electrician, complained of swelling in the left cheek region for the past 1 year, which had been slowly progressing in size with no discharge. On examination, a single, localized, dome-shaped 3 × 3 cm swelling was noted (Figure 1). Superio-inferiorly, the swelling extended from below the zygomatic arch to approximately 1 cm above the lower border of the mandible. Antero-superiorly, the swelling extended from the corner of the mouth to approximately 1.5 cm away from the tragus of the ear.

Upon further examination, the swelling was found to be firm, non-tender, movable and not fixed to the underlying

¹Department of Oral and Maxillofacial Surgery, Genesis Institute of Dental Sciences and Research, Firozpur, India

²Department of Oral and Maxillofacial Surgery, MM College of Dental Sciences and Research, Ambala, India

³Department of Morphology, Institute of Anatomy and Anthropology, Riga Stradiņš University, Riga, Latvia

Corresponding Author:

Nityanand Jain, Department of Morphology, Institute of Anatomy and Anthropology, Riga Stradiņš University, Dzirciema street 16, Riga LV-1007, Latvia.

Email: nityapkl@gmail.com



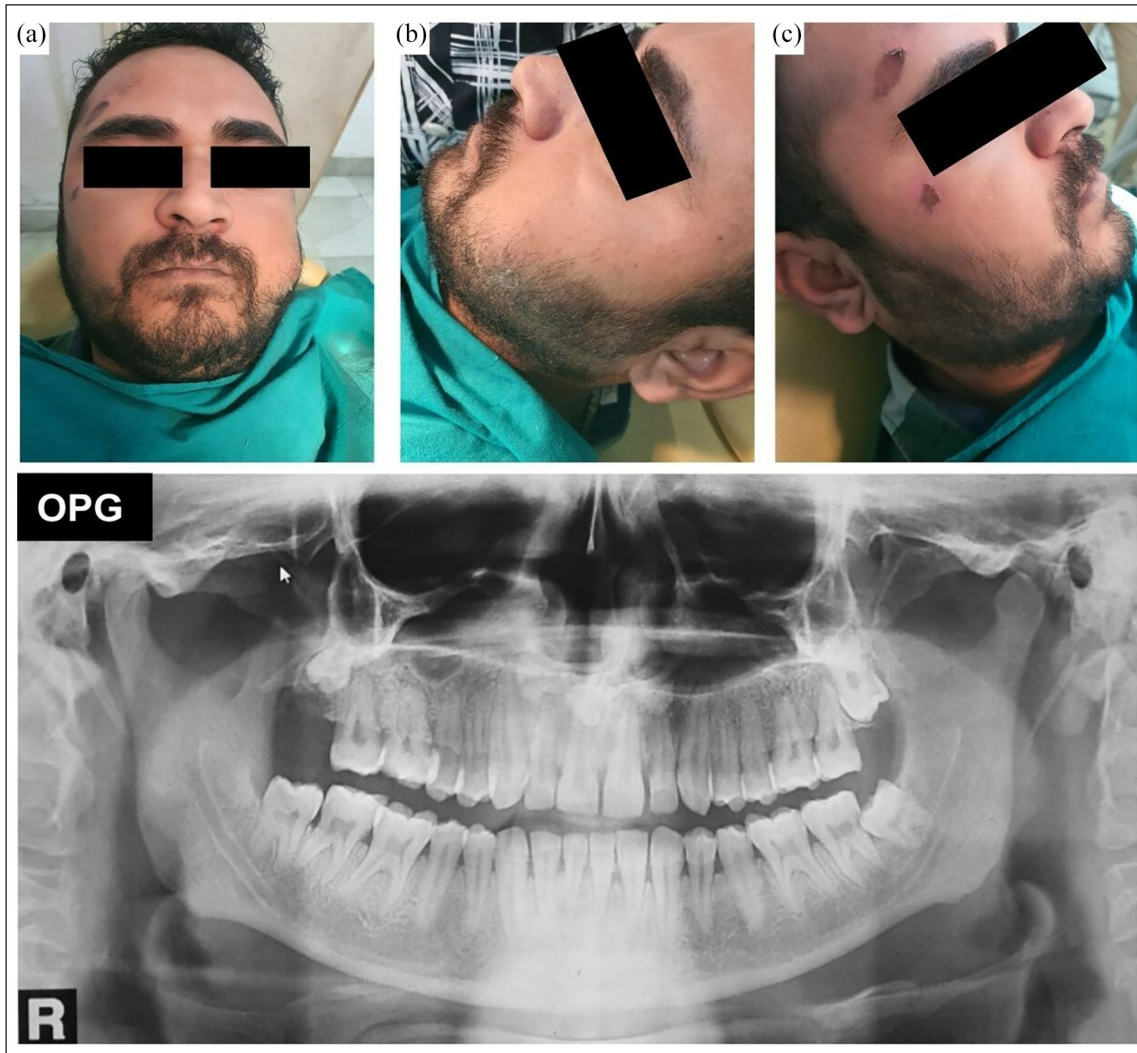

Figure 1. Patient profile during initial check-up at the time of examination. (a) Front profile; (b) left-side profile and (c) right-side profile. Note the presence of approximately 3×3 cm round swelling in the left cheek region. The orthopantomogram (OPG) of the patient showing no remarkable osteo-pathology or bone involvement. The normal bone morphology is intact and complete dentition can be visualized.

and adjacent tissues. The covering skin was non-erythematous with non-draining indurated sinus along the central region. Medical and family history were unremarkable for any congenital conditions. Lymph node examination revealed no palpable submandibular or submental nodes.

Intraoral examination revealed complete dentition with no appreciable intraoral swelling. Orthopantomogram (OPG) revealed absence of bone involvement or osteo-pathology, with intact labial, buccal and lingual cortices (Figure 1). Based on the patient presentation and oral examination, buccal space infection was suspected. Differential diagnosis included periodontal abscess, lymphadenitis, infected epidermoid or sebaceous cyst, hemangioma and/or antibioma.

Aspiration of the swelling contents was performed using a wide-bore needle. Because of the thick consistency of the swelling contents, the contents were non-retrievable from the pathological site (Figure 2). A complete excision of the

mass was planned for this patient. Total anaesthesia was obtained intraorally using inferior alveolar and long buccal nerve block with lidocaine (1:80,000 adrenaline). Extraorally local infiltration was given around the lesion. A horizontal stab incision was given. Cheesy, keratinous material extruded through a well-defined cyst wall (Figure 2).

Next, a blunt dissection was carried out to remove the complete cyst wall lining. The socket was irrigated with 0.9% NaCl physiological solution and wound closure was done in layers. A sample of the biopsy soft tissue was sent for histopathological evaluation. Microscopic examination revealed the presence of a cyst lining with keratinized stratified squamous epithelium (Figure 3). Partially degenerative material consisting of connective tissue, blood vessels, adipose cells and keratin pearls filled the cyst cavity (Figure 3). Dense fibrous connective tissue with no skin adnexa, muscle, cartilage or bone tissue was seen surrounding the cyst

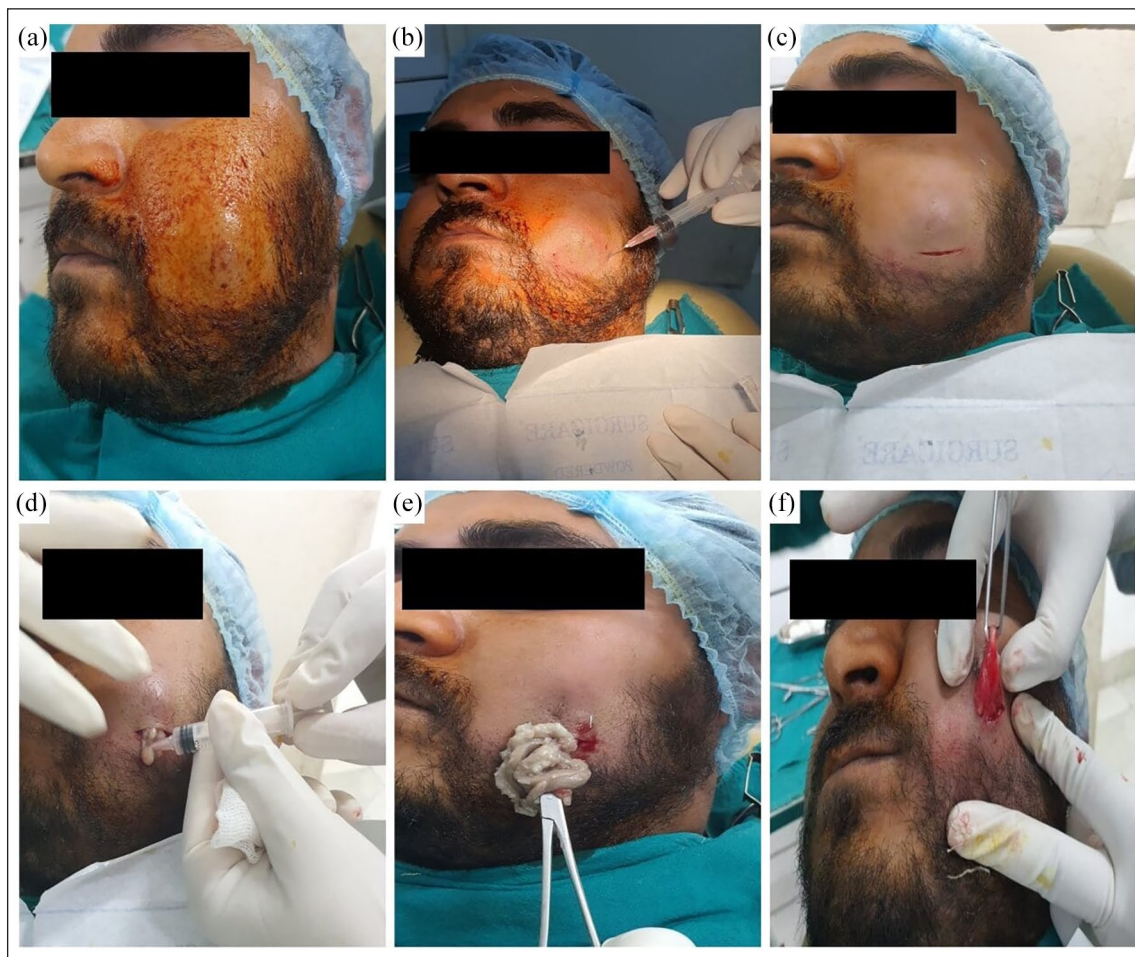

Figure 2. Preparation of incision site, collection of exudate and complete removal of cyst. (a) Under aseptic condition (using betadine solution) the facial hair were trimmed; (b) aspiration did not yield any results due to the cheesy thick swelling contents; (c) horizontal stab incision was given; (d and e) Cheesy, keratinous, granular, paste-like semi-solid discharge from the swelling site and (f) complete removal of cyst wall lining.

wall, thereby confirming the diagnosis of epidermoid cyst. No inflammatory infiltration was noted in the sample.

A compression dressing was given extraorally, which was changed every third day for 2 weeks. Standard surgical post-operative medication regimen was followed. Sutures were removed 7 days post-operatively. Follow-up was done for 2 months after last dressing change to evaluate the healing of the wound. Post-operative healing was found to be uneventful and satisfactory.

To identify the potential cause for the formation of the cyst at this atypical location, the patient was repeatedly questioned (both pre- and post-operatively) for any pathological site stress/trauma. The patient consistently denied any trauma to the site of injury. Only when the final diagnosis was provided post-operatively, the patient revealed when at work, he would regularly hold his instruments (like screwdriver) between the cheek and shoulder or the wall (or any other supporting structure) while he would place the screws in the sockets. This habitual use of cheek skin as support caused

stretching and entangling of facial hair follicles (skin trauma), thereby leading to cyst formation. The patient was advised to discontinue this practice of holding instruments and was recommended the use of proper instrument holding stands to prevent future episodes at other bodily locations and to prevent recurrence.

Discussion

Epidermoid cysts are indolent, slow growing, usually asymptomatic, benign nodules that can occur anywhere on the body, though rarely in the orofacial region. The pathophysiology of these cysts depends upon their origin – congenital or acquired/sporadic. Whereas in case of congenital cysts, epidermal rests undergo sequestration and implantation during the embryonal period, in case of sporadic cysts, occlusion of hair follicle, mechanical pressure or trauma, blunt penetrating injury, and surgical implantation/displacement of epithelial tissue into the jaw mesenchyme cause cyst

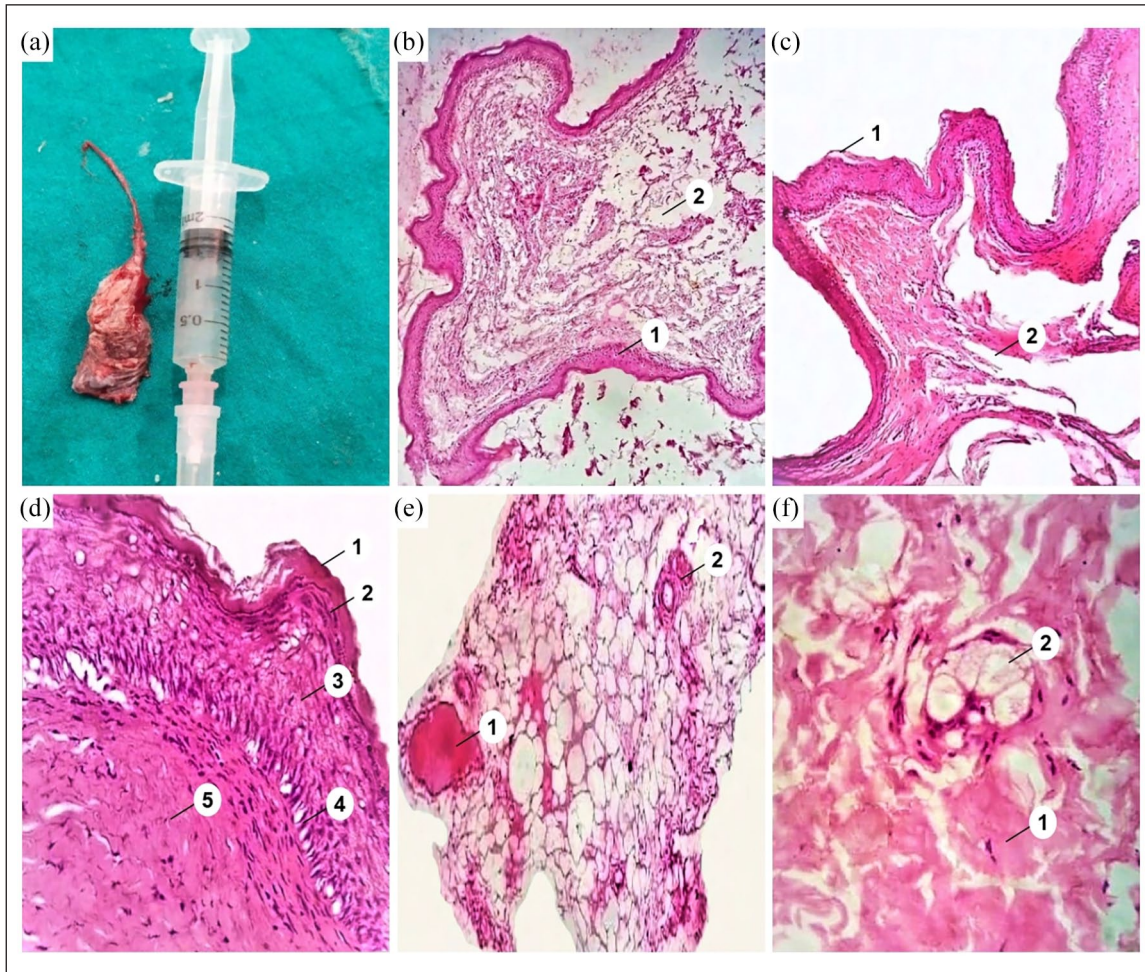


Figure 3. Histopathological examination of the excised cystic tissue. (a) Macroscopic view of the cyst tissue measuring 3×2.1 cm that was sent for microscopic examination. The microphotographs of the excised cystic tissue were stained using hematoxylin and eosin (H&E); (b and c) the cystic wall covered by keratinized stratified squamous epithelium (marked as 1) and the cyst cavity showing connective tissue and degenerative material (marked as 2). Original magnification, $100\times$; (d) layers of the keratinized stratified squamous epithelium of the cystic wall including keratinized layer (marked as 1), well-defined granular layer (marked as 2), prickle cell layer (marked as 3) and basal cell layer (marked as 4). Dense connective tissue is seen in the subepithelium (marked as 5). Original magnification, $200\times$; (e) cystic cavity showing keratin pearl (marked as 1) and blood vessel (marked as 2). Original magnification, $100\times$; and (f) laminated keratinous material (the cheesy-white exudate) can be visualized inside the cystic cavity (marked as 1) along with some adipose tissue (marked as 2). Original magnification, $100\times$.

formation.^{1,2,7} In the literature, only a handful of reports confirmed localized trauma as a cause of development of orofacial epidermoid cyst.^{8–11}

In most acquired cases, epidermal cells from follicular infundibulum or eccrine sweat ducts¹² escape and penetrate the deeper cutaneous layers where they multiply and cause peeling of keratin layers. This makes the presence of keratin flakes within the cyst cavity a characteristic finding in case of epidermoid cysts. Another hallmark feature is the punctum or draining sinus which is a keratin-filled orifice on the skin surface through which the cyst lining communicates with the cyst surface.⁷ Most cysts present with a single central punctum, although multiple orifices have also been reported.¹

For accurate diagnosis, the first and foremost step is collection of accurate medical and dental history from the patient, especially episodes of trauma/injury/pressure at the complaint site. However, in a large number of cases, accurate and complete patient history is difficult to collect.¹³ First, patients usually have irrational fears of embarrassment and judgement that causes distortion of medically relevant events. Furthermore, face-to-face interactions during history taking tends to tilt the balance of doctor-patient conversation dynamics in favour of the doctor, thereby putting the doctors in an authority position¹³ and making the patient reluctant in sharing the complete episodes. Second, the sharing of medically important points with the doctors can be environment-dependent. It has been suspected that

there are differences in patient history and complaints in clinical and surgical departments.¹³ Third, the intensity and cause of trauma associated with formation of orofacial epidermoid cysts in the previously reported cases have been non-noticeable to most patients. For example, lip biting and minor trauma during masticatory activity have been suspected causes in patients who developed intraoral epidermoid cysts.^{8–11} Finally, in most of the developing countries, lack of proper storage and safety equipment at construction sites can lead to establishment of improper and unsafe workplace practices which over time become habitual and may not feel unusual for the patients.^{14,15} In the present case, indeed, we suspect that a combination of all these above factors led to the patient's reluctance in providing an accurate medical history.

The next step in examination procedure would be to perform a fine-needle aspiration (FNA) of the cyst. However, as in the present case, the occlusion of the punctum due to extremely thick cystic contents could render FNA ineffective. Excisional biopsy should be done during surgical cyst removal, though some authors have recommended the use of diagnostic techniques like ultrasound, computed tomography (CT) and magnetic resonance imaging (MRI) in narrowing the differential diagnosis before performing biopsy. However, biopsy is essential to assess complete excision of the cyst wall and avoid misdiagnosis. In cases of orofacial cysts with relatively easy access (especially extraoral ones), the use of such diagnostic techniques may prove to be expensive and difficult to access in a dental facility. However, in cases of hard-to-reach cystic locations or swellings proving difficult to evaluate, the use of CT/MRI is encouraged.^{16–18}

Surgical excision or enucleation is the gold standard for providing relief to the patient. Complete cyst wall should be removed and confirmed by histopathological analysis. In addition, the cyst should be excised without opening, since the contents can cause irritating effects on the surrounding skin and fibrovascular tissue.¹⁸ Furthermore, cyst rupturing can lead to a localized inflammatory reaction due to the strong chemotactic affinity shown by the polymorphonuclear cells (PMNCs) towards the keratinous cystic material.¹ This could lead to false impression of infection and establishment of an inaccurate diagnosis. Another risk associated with incomplete removal of cyst wall is the increased chance of recurrence and the potential of the cyst to become malignant.

Conclusion

In this case report, we present an atypical presentation of epidermoid cyst having an occluded punctum with no discharge on the facial skin. The constant denial of patient of trauma made the diagnosis of epidermoid cyst difficult to establish. Proper history taking including the inclusion of details regarding occupational habits and practices is crucial

for proper management of the epidermoid cysts to prevent recurrence and malignancy.

Acknowledgements

The authors are extremely grateful of the patient for consenting to publish this case report for scientific publication, dissemination, and educational purposes. The support of Riga Stradins University (RSU) is greatly acknowledged.

Declaration of conflicting interests

The author(s) declared no potential conflicts of interest with respect to the research, authorship and/or publication of this article.

Ethical approval

Due to the purely descriptive nature of the study, the ethical approval was waived by the institute for reporting the present case. Furthermore, no medical experiments were performed and standard clinical protocols for patient treatment and management were followed.

Funding

The author(s) received no financial support for the research, authorship, and/or publication of this article.

Informed consent

Written and oral informed consent to publish photos and patient case description was obtained from the patient.

ORCID iDs

Shivani Jain  <https://orcid.org/0000-0002-0648-745X>

Nityanand Jain  <https://orcid.org/0000-0002-7918-7909>

Mara Pilmane  <https://orcid.org/0000-0001-9804-4666>

References

1. Jeyaraj P and Sahoo NK. An unusual case of a recurrent seborrhoeic/epidermal inclusion cyst of the maxillofacial region. *J Maxillofac Oral Surg* 2015; 14(Suppl. 1): 176–185.
2. Zito PM and Scharf R. Epidermoid Cyst. *Treasure Island, FL: StatPearls Publishing*, 2021, <https://www.ncbi.nlm.nih.gov/books/NBK499974/> (accessed 31 October 2021).
3. Noffke CE. Implantation-type epidermoid cyst of the mandible. *Dentomaxillofac Radiol* 1999; 28(6): 383–385.
4. Jham BC, Duraes GV, Jham AC, et al. Epidermoid cyst of the floor of the mouth: a case report. *J Can Dent Assoc* 2007; 73(6): 525–528.
5. Louis PJ, Hudson C and Reddi S. Lesion of floor of the mouth. *J Oral Maxillofac Surg* 2002; 60(7): 804–807.
6. Veselinović D, Krsić D, Stefanović I, et al. Orbital dermoid and epidermoid cysts: case study. *Srp Arh Celok Lek* 2010; 138(11-12): 755–759.
7. Hoang VT, Trinh CT, Nguyen CH, et al. Overview of epidermoid cyst. *Eur J Radiol Open* 2019; 6: 291–301.
8. Gutmann J, Cifuentes C, Gandulfo P, et al. Intradermal nevus associated with epidermoid cyst in the mucous membrane of the cheek. *Oral Surg Oral Med Oral Pathol* 1978; 45(1): 76–82.

9. Rajayogeswaran V and Eveson JW. Epidermoid cyst of the buccal mucosa. *Oral Surg Oral Med Oral Pathol* 1989; 67(2): 181–184.
10. Wang WC, Lin LM, Shen YH, et al. Concurrent extravasation mucocele and epidermoid cyst of the lower lip: a case report. *Kaohsiung J Med Sci* 2005; 21(10): 475–479.
11. Costa FW, Carvalho FS, Chaves FN, et al. Epidermoid cyst arising in the buccal mucosa: case report and literature review. *Acta Stomatol Croat* 2015; 49(1): 65–73.
12. Choi JE, Kwon IH, Seo SH, et al. Pathogenesis of plantar epidermal cyst: three-dimensional reconstruction analysis. *Ann Dermatol* 2016; 28(1): 133–135.
13. Redelmeier DA, Tu JV, Schull MJ, et al. Problems for clinical judgement: 2. Obtaining a reliable past medical history. *CMAJ* 2001; 164(6): 809–813.
14. Kheni NA, Dainty ARJ and Gibb A. Health and safety management in developing countries: a study of construction Smes in Ghana. *Construct Manag Econ* 2008; 26(11): 1159–1169.
15. Gardner B, Lally P and Wardle J. Making health habitual: the psychology of ‘habit-formation’ and general practice. *Br J Gen Pract* 2012; 62(605): 664–666.
16. Erol K, Erkan KM, Tolga D, et al. Epidermoid cyst localized in the palatine tonsil. *J Oral Maxillofac Pathol* 2013; 17(1): 148.
17. Gulia SP, Lavanya M, Kamidi V, et al. Epidermoid cyst of the tonsil: an incidental finding. *Case Reports* 2015; 2(12): 777–779.
18. Bouatay R, Jellali S, Abdejelil N, et al. Epidermoid cyst of the tonsil: a rare finding. *Pan Afr Med J* 2019; 34: 4.