

Long-term efficacy of high doses of intravenous immunoglobulins in generalized scleromyxoedema: Case report

Federica Arginelli¹, Franco Rongioletti²,
Giampiero Girolomoni³, Giovanni Pellacani¹,
Davide Guardoli¹ and Andrea Conti¹

Abstract

Scleromyxoedema is a rare disease with a progressive and disabling course involving dermal deposition of mucin and fibroblast proliferation; it is characterized clinically by a diffuse papular eruption, skin thickening, oedema and decreased skin flexibility, especially of the face and hands. Current therapy options are based on evidence from a limited number of case reports. The clinical manifestations and treatment of a 64-year-old man affected by scleromyxoedema with severe skin involvement of the face, arms and hands, decreased mouth opening and hypomotility of the fingers are reported. Dysphagia, asthenia and immunoglobulin G lambda monoclonal gammopathy were also present. Previous treatment with topical and systemic corticosteroids, psoralen plus ultraviolet A radiation therapy, plasmapheresis, extracorporeal photochemotherapy, hydroxychloroquine and cyclophosphamide had been unsuccessful. Treatment with intravenous immunoglobulins at a dosage of 2 g/kg monthly was started. Considerable improvements were observed after seven cycles of therapy, with recovery of skin elasticity, an increase in facial mimic movement, restoration of joint function and improvement in the modified Rodnan score. There were no observed side-effects. The patient remains in remission on monthly maintenance intravenous immunoglobulins, 2 years after initial treatment.

³Department of Medicine, University of Verona, Verona, Italy

Corresponding author:

Andrea Conti, Dermatology Unit, Department of Head and Neck Surgery, Azienda Ospedaliero-Universitaria Policlinico di Modena, 71 Via del Pozzo, Modena 41122, Italy.

Email: a.conti.dermo@gmail.com

¹Dermatology Unit, Department of Head and Neck Surgery, Azienda Ospedaliero-Universitaria Policlinico di Modena, Modena, Italy

²Dermatology Section, University of Genoa and San Martino University Hospital, Genoa, Italy



Keywords

High-dose intravenous immunoglobulin, modified Rodnan score, scleromyxoedema

Introduction

Scleromyxoedema is a rare disease involving dermal deposition of mucin and fibroblast proliferation; it is characterized clinically by a diffuse papular eruption, skin thickening, oedema and decreased skin flexibility, especially of the face and hands, with a progressive and disabling disease course.¹⁻⁴ Patients with scleromyxoedema can also have systemic manifestations.⁵ Many treatments have been proposed for scleromyxoedema, including corticosteroids, retinoids, cyclophosphamide, plasmapheresis, bortezomib, melphalan, thalidomide, chloroquine, extracorporeal photopheresis and photochemotherapy such as psoralen plus ultraviolet A radiation therapy (P-UVA), cyclosporine and autologous stem-cell transplantation. High doses of intravenous immunoglobulins have been proposed as a therapy, based on multiple case reports that support the efficacy and safety of such treatment.⁵⁻⁷

Case report

A 64-year-old man presented to the Department of Dermatology, University-Hospital of Modena and Reggio Emilia, Modena, Italy, in November 2012 with scleromyxoedema, with severe involvement of the skin of the face, arms and hands, decreased mouth opening and hypomotility of the fingers (Figure 1). Dysphagia, asthenia and monoclonal gammopathy of immunoglobulin G lambda-type were also present.

The patient had previously been treated with topical and systemic corticosteroids, P-UVA therapy, plasmapheresis, extracorporeal photochemotherapy, hydroxychloroquine and cyclophosphamide, without any benefit.

Disease severity was assessed using a modified Rodnan score, which evaluates skin thickness and papular involvement.^{8,9} Skin thickness is rated by clinical palpation using a 0–3 point scale (0, normal skin; 1, mild thickness; 2, moderate thickness; 3, severe thickness with inability to pinch the skin into a fold) for 17 surface anatomical areas: face, anterior chest; abdomen; fingers; forearms; upper arms; thighs; lower legs; dorsum of hands and feet bilaterally. Papular involvement is rated according to the presence of papules (0, no papules; 1, presence of papules) in each of same 17 anatomical areas. The patient's total score was 53 out of a maximum score of 182*. Treatment with intravenous immunoglobulins at a dosage of 2 g/kg administered over 5 days once a month was started.

After the first infusion cycle, a substantial improvement was observed. After seven cycles of therapy, recovery of skin elasticity, an increase in facial mimic movement and restoration of joint function was observed (Figure 2).

The modified Rodnan score dropped from 53 to 31. No side-effects were observed. After 2 years, the patient remains in clinical remission on maintenance therapy with intravenous immunoglobulins (2 g/kg once per month).

The patient gave consent for their case to be published.

*Minimum score 0 and maximum score 182 (i.e. when all body sites show the highest score obtained by the following sum: $[18 \times 3] + [42 \times 3] + 1 + 1 = 182$. 18 corresponds to the total sum of the scores for face, neck, trunk; 42 corresponds to the total sum of the scores of upper and lower limbs). Total score is multiplied by the degree of skin thickening, papules and erythema. The first "1" indicates presence of itching, second "1" indicates the presence of paresthesiae

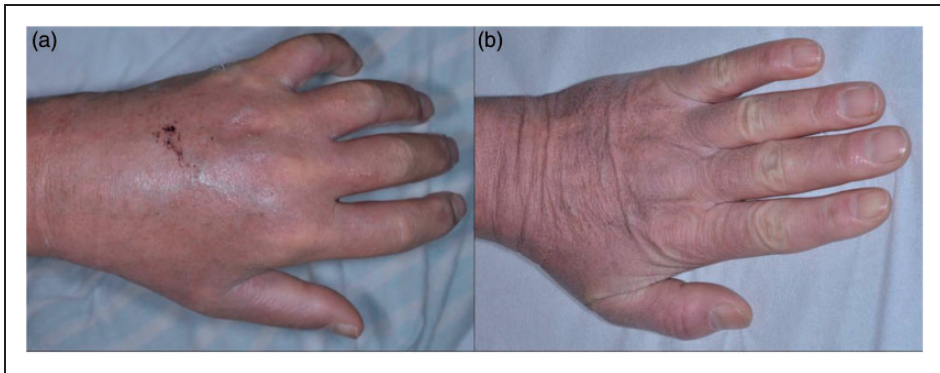


Figure 1. (a) Left hand of a patient with scleromyxoedema before treatment, showing oedema, stiffness, erythema and ulceration. (b) The same hand after 3 months' high-dose intravenous immunoglobulin therapy, showing resolution of the oedema, erythema and ulceration, good mobility and visible skin folds and wrinkles.

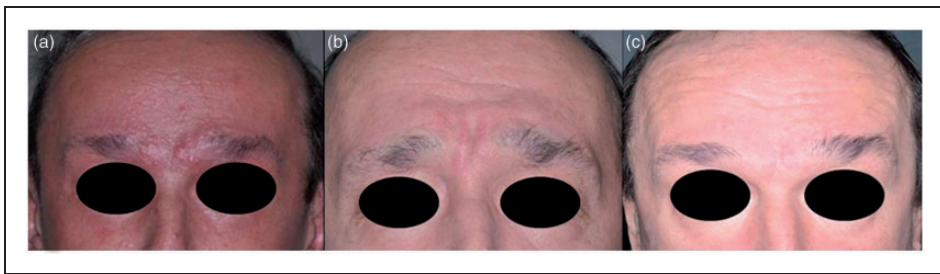

Figure 2. Face of a patient with scleromyxoedema: (a) before treatment, showing severe erythema, papules and plaques, especially on the glabella, thinning of the eyebrows and reduced mobility; (b) after 3 months' high-dose intravenous immunoglobulin therapy, showing improvement in erythema and oedema and improved mobility; (c) after 5 months' high-dose intravenous immunoglobulin therapy, showing further improvements in erythema and mobility, with disappearance of the papules and plaques on the glabella.

Discussion

Scleromyxoedema is a progressive disease with a disabling and unpredictable course; in a few cases it is fatal due to heart or kidney failure.^{4,10} The aetiology of scleromyxoedema is still unknown. Therapeutic management is based on data from reported cases. P-UVA therapy, hydroxychloroquine and cyclophosphamide pulsed therapy were all unsuccessful in the patient presented here. A considerable improvement was obtained with intravenous immunoglobulin 2 g/kg, administered over 5 days once a month.

The use of intravenous immunoglobulins as a treatment for scleromyxoedema has been well documented.^{5,11,12} The action of intravenous immunoglobulins is not yet completely understood, but they seem to act through an immunomodulatory mechanism blocking Fc receptors on splenic macrophages, inhibiting complement, modulating cytokines, neutralizing autoantibodies, blocking CD95 and inhibiting apoptosis.^{6,13,14} Side-effects are rare and normally mild.^{15,16} Some patients require maintenance intravenous immunoglobulin

therapy; others need only a few infusions to obtain permanent remission.^{5,15}

In the patient presented here, the efficacy of intravenous immunoglobulin therapy was demonstrated in a reduction in the modified Rodnan score. The patient is in clinical remission 2 years after initial treatment, with the disappearance of erythema, oedema and skin stiffness and the recovery of articular motility, facial mimic movement and improved swallowing.

This case supports the contention that intravenous immunoglobulins are effective therapies with a favourable safety profile in the long-term treatment of scleromyxoedema, especially for patients in whom other therapeutic options have failed. If the response is not permanent, maintenance infusions are required.

Declaration of conflicting interest

The authors declare that there are no conflicts of interest.

Funding

Editorial assistance was provided by Ray Hill on behalf of HPS—Health Publishing and Services Srl and funded by Pfizer Italia.

References

- Montgomery H and Underwood LJ. Lichen myxedematosus; differentiation from cutaneous myxedemas or mucoid states. *J Invest Dermatol* 1953; 20: 213–236.
- Heymann WR. Scleromyxedema. *J Am Acad Dermatol* 2007; 57: 890–891.
- Rongioletti F and Rebora A. Updated classification of papular mucinosis, lichen myxedematosus, and scleromyxedema. *J Am Acad Dermatol* 2001; 44: 273–281.
- Rongioletti F. Lichen myxedematosus (papular mucinosis): new concepts and perspectives for an old disease. *Semin Cutan Med Surg* 2006; 25: 100–104.
- Gholam P, Hartmann M and Enk A. Arndt–Gottron scleromyxoedema: successful therapy with intravenous immunoglobulins. *Br J Dermatol* 2007; 157: 1058–1060.
- Manousaridis I, Loeser C, Goerdts S, et al. Managing scleromyxedema with intravenous immunoglobulin: acute worsening of scleromyxedema with biclonal gammopathy. *Acta Dermatovenereol Alp Pannonica Adriat* 2010; 19: 15–19.
- Serdar ZA, Altunay IK, Yasar SP, et al. Generalized papular and sclerodermoid eruption: scleromyxedema. *Indian J Dermatol Venereol Leprol* 2010; 76: 592.
- Clements PJ, Lachenbruch PA, Seibold JR, et al. Skin thickness score in systemic sclerosis: an assessment of interobserver variability in 3 independent studies. *J Rheumatol* 1993; 20: 1892–1896.
- Clements P, Lachenbruch P, Siebold J, et al. Inter and intraobserver variability of total skin thickness score (modified Rodnan TSS) in systemic sclerosis. *J Rheumatol* 1995; 22: 1281–1285.
- De Simone C, Castriota M, Carbone A, et al. Cardiomyopathy in scleromyxedema: report of a fatal case. *Eur J Dermatol* 2010; 20: 852–853.
- Fleming KE, Virmani D, Sutton E, et al. Scleromyxedema and the dermatoneuro syndrome: case report and review of the literature. *J Cutan Pathol* 2012; 39: 508–517.
- Rongioletti F, Merlo G, Cinotti E, et al. Scleromyxedema: a multicenter study of characteristics, comorbidities, course, and therapy in 30 patients. *J Am Acad Dermatol* 2013; 69: 66–72.
- Körber A, Franckson T, Grabbe S, et al. Successful therapy of scleromyxoedema Arndt–Gottron with low-dose intravenous immunoglobulin. *J Eur Acad Dermatol Venereol* 2007; 21: 553–554.
- Wojas-Pelc A, Błaszczak M, Glińska M, et al. Tumorous variant of scleromyxedema. Successful therapy with intravenous immunoglobulins. *J Eur Acad Dermatol Venereol* 2005; 19: 462–465.
- Rey JB and Luria RB. Treatment of scleromyxedema and the dermatoneuro syndrome with intravenous immunoglobulin. *J Am Acad Dermatol* 2009; 60: 1037–1041.
- Hamrock DJ. Adverse events associated with intravenous immunoglobulin therapy. *Int Immunopharmacol* 2006; 6: 535–542.