

Efficiency of two protocols for maxillary molar intrusion with mini-implants

Juliana Volpato Curi Paccini¹, Flávio Augusto Cotrim-Ferreira², Flávio Vellini Ferreira², Karina Maria Salvatore de Freitas³, Rodrigo Hermont Cançado³, Fabrício Pinelli Valarelli³

DOI: <http://dx.doi.org/10.1590/2177-6709.21.3.056-066.oar>

Objective: The aim of this study was to compare the efficiency of two protocols for maxillary molar intrusion with two or three mini-implants. **Methods:** Twenty five maxillary first molars extruded for loss of their antagonists in adult subjects were selected. The sample was divided into two groups, according to the intrusion protocol with two or three mini-implants. Group 1 consisted of 15 molars that were intruded by two mini-implants. Group 2 consisted of 10 molars intruded by three mini-implants. Changes with treatment were analyzed in lateral cephalograms at the beginning and at the end of intrusion of maxillary molars. **Results:** Results showed that there was no difference in efficiency for the two intrusion protocols. It was concluded that extruded maxillary molars can be intruded with two or three mini-implants with similar efficiency.

Keywords: Corrective Orthodontics. Tooth intrusion. Bone screws.

Objetivo: o objetivo do presente estudo foi comparar a eficiência de dois protocolos de intrusão de molares superiores com dois e três mini-implantes. **Métodos:** foram selecionados 25 primeiros molares superiores extruídos por perda de seus antagonistas, de pacientes adultos. A amostra foi dividida em dois grupos, de acordo com o protocolo de intrusão, com dois ou três mini-implantes: o Grupo 1 consistiu de 15 molares que sofreram intrusão com dois mini-implantes; o Grupo 2 foi constituído por 10 molares intruídos por três mini-implantes. As alterações com o tratamento foram analisadas em telerradiografias em norma lateral ao início e ao final da intrusão dos molares superiores. **Resultados:** os resultados mostraram que não houve diferença na eficiência dos dois protocolos de intrusão. Concluiu-se que molares superiores extruídos podem ser intruídos, com eficiência semelhante, por meio de dois ou três mini-implantes.

Palavras-chave: Ortodontia corretiva. Intrusão dentária. Parafusos ósseos.

¹MSc, Universidade Cidade de São Paulo (UNICID), Department of Orthodontics, São Paulo, São Paulo, Brazil.

²Professor, Universidade Cidade de São Paulo (UNICID), Department of Orthodontics, São Paulo, São Paulo, Brazil.

³Professor, Faculdade Ingá, Department of Orthodontics, Maringá, Paraná, Brazil.

How to cite this article: Paccini JVC, Cotrim-Ferreira FA, Ferreira FV, Freitas KMS, Cançado RH, Valarelli FP. Efficiency of two protocols for maxillary molar intrusion with mini-implants. *Dental Press J Orthod.* 2016 May-June;21(3):56-66. DOI: <http://dx.doi.org/10.1590/2177-6709.21.3.056-066.oar>

Submitted: June 25, 2015 - **Revised and accepted:** November 26, 2015

» The authors report no commercial, proprietary or financial interest in the products or companies described in this article.

» Patients displayed in this article previously approved the use of their facial and intraoral photographs.

Contact address: Karina Maria Salvatore de Freitas
Av. Colombo, 9.727 Km 130 - Maringá, PR, Brazil. CEP: 87070-810
E-mail: kmsf@uol.com.br

INTRODUCTION AND STATEMENT OF THE PROBLEM

One of the most difficult movements in orthodontic mechanics requiring efficient anchorage to achieve success is tooth intrusion. This movement is usually necessary when a tooth has extruded, especially due to absence of the antagonist tooth. Extrusion can cause several problems, such as occlusal interferences and consequent functional problems.¹⁻⁴ It is, therefore, necessary to correct this condition to further promote prosthetic rehabilitation of the antagonist tooth.

There are several intra- and extraoral areas to be used as anchorage. Conventional methods present some inconvenience, including esthetic implications, anchorage loss and the need for patient's compliance, greatly compromising the success of intrusion mechanics.^{2,5,6} It is extremely necessary to differentiate the intrusion of maxillary first molars from the extrusion of adjacent teeth, which can occur when proper anchorage is not used, representing a relative intrusion and not a true one.^{3,6}

The use of miniscrews and the possibility to obtain absolute anchorage has provided new perspectives for Orthodontics. It created a stable point within the oral cavity, so that movements are performed in a more controlled and predictable way, with minimal need for patient's compliance.^{3,4} Currently, there are mini-implants available in a wide variety of sizes, allowing their insertion in several locations of the maxilla and mandible.⁷ Mini-implants remained in the dental market due to several advantages, such as the absence of complex surgical procedures, low cost and great patient acceptance.⁸

Currently, intrusive mechanics of maxillary molars anchored in mini-implants uses several protocols.^{3,9-12} However, there is a concern regarding the best protocol to perform molar intrusion with maximum efficiency and the ideal number of mini-implants to be used during this mechanics.

The aim of this study was to compare the dental and skeletal changes produced by intrusion of maxillary first molars anchored in mini-implants, using two different protocols, and to evaluate the efficiency of these protocols based on the ratio between the amount and duration of intrusion.

MATERIAL AND METHODS

This study was approved by the Ethics Research Committee of Universidade Cidade de São Paulo (UNICID) (protocol 13599774).

Sample size calculation was based on an alpha significance level of 5% (0.05) and a beta of 20% (0.20) to achieve 80% power test to detect a mean difference of 0.78 mm with standard deviation of 0.6 for maxillary molar intrusion.²⁴ Thus, sample size calculation revealed the need for 10 individuals in each group.

This study was retrospective, and sample selection followed the following criteria: presence of at least an extruded maxillary first molar due to loss of the antagonist tooth, patients with no growth potential, absence of chronic systemic problems, presence of lateral cephalograms from the beginning of orthodontic treatment and from the end of intrusion, presence of completed files with information concerning the procedure for intrusion of maxillary first molars and absence of endodontic treatment in the intruded molar. None of the individuals in the sample had previous orthodontic treatment or periodontal disease in the beginning of treatment.

According to these criteria for selecting the sample, 19 patients (four males, 15 females) were selected, 13 with unilateral and six with bilateral extrusion, thereby totaling 25 first molars which had undergone mechanical intrusion, anchored in mini-implants and associated with fixed appliances. All patients were treated by graduate students supervised by the same professor at FACSETE, Porto Velho, Rondônia, Brazil. Thus, the sample was divided into two groups, according to the protocol of two or three mini-implants used for molar intrusion.

» Group 1 (G1): Composed of 15 maxillary first molars which were intruded by two mini-implants, one on the buccal side and one on the palatal side (Fig 1).

» Group 2 (G2): Composed of 10 maxillary first molars which were intruded by three mini-implants, two on the buccal side and one on the palatal side (Fig 2).

In patients of G1, elastomeric chains (Dental Morelli Ltda, Sorocaba, São Paulo, Brazil) were anchored in the mini-implants, passing through the occlusal surface of first molar crown (Fig 1). In patients of G2, elastomeric chains (Dental Morelli Ltda, Sorocaba, São Paulo, Brazil) were placed as follows: from the two mini-implants placed buccally to the tube of the first molar band, and from the mini-implant placed palatally to the button soldered on the first molar band, on the palatal side (Fig 2). Intrusion mechanics

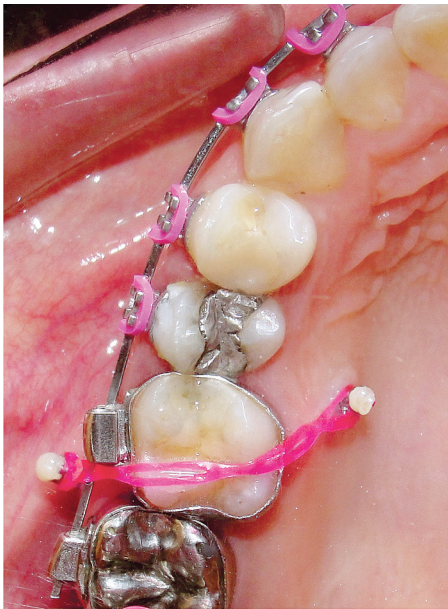

Figure 1 - First molar intrusion in Group 1.

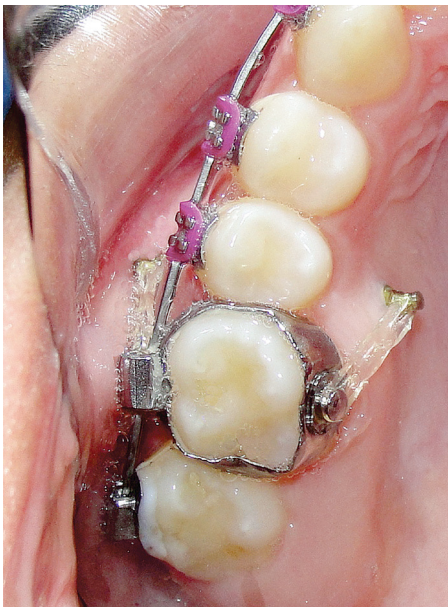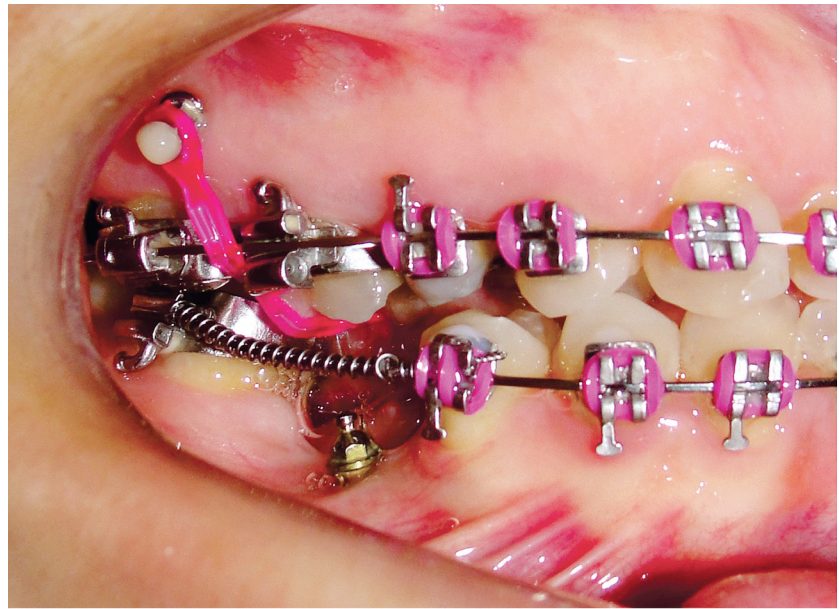
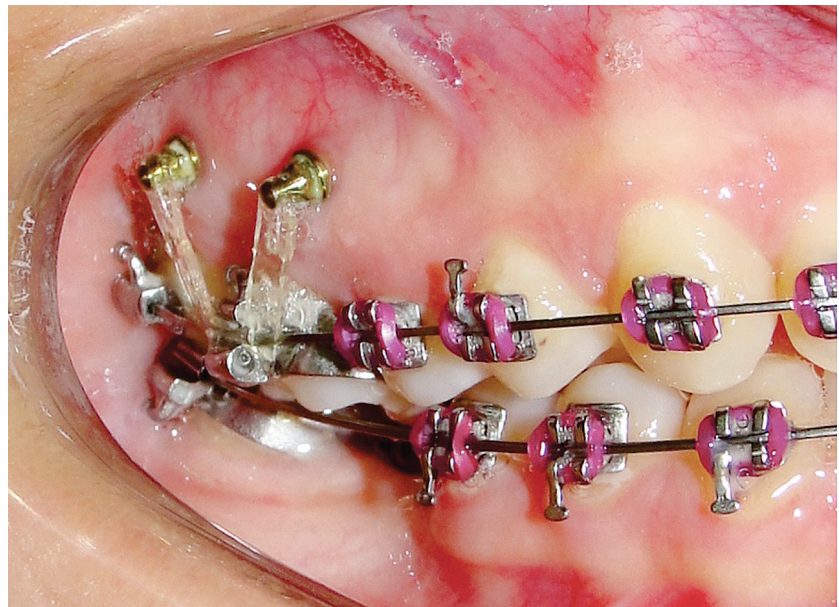


Figure 2 - First molar intrusion in Group 2.



was applied immediately after mini-implant placement, with approximately 150 g of force being applied to each mini-implant.^{13,14,15} This force was measured by a tensiometer (50-500 g, Dental Morelli Ltda, Sorocaba, São Paulo,

Brazil). The elastomeric chains were changed every four weeks and intrusion force was checked at each appointment. Retention of the intruded molars was performed with ligature wires (0.010-in).

Simultaneously to intrusion of maxillary first molars, the cases were treated with preadjusted appliances (Roth prescription, slot 0.022 x 0.028-in, Dental Morelli Ltda. Sorocaba, SP, Brazil). Patients received self-drilling mini-implants (S.I.N. Implant System, São Paulo, São Paulo, Brazil), with dimensions of 1.4 x 6 x 1 mm for the buccally installed and 1.4 x 8 x 3 mm for the palatally installed mini-implants.¹⁶

The mean initial age of patients was 34.25 years (SD = 8.22, minimum 22.66, maximum 46.99) for Group 1 and 39.47 years (SD = 8.12, minimum 21.07, maximum 47.44) for Group 2. Mean intrusion duration was 0.81 years (SD = 0.35, minimum 0.41, maximum 1.64) for Group 1 and 1.17 years (SD = 0.48, minimum 0.75, maximum 2.14) for Group 2.

METHODS

Initial and final lateral cephalograms were not taken by the same equipment. Therefore, in order to increase reliability of results, correction of the magnification factor of each cephalogram was performed.¹⁷

Cephalograms were scanned in Microtek ScanMaker i800 (9600 x 4800 dpi, Microtek International, Inc., Carson, CA, USA) connected to a microcomputer Compaq Pavilion B6000BR board Intel Dual Core E5300 2.6 GHz, 2 GB memory RAM. Images were transferred to Dolphin Imaging Premium 5.10 software (Dolphin Imaging & Management Solutions, Chatsworth, CA, USA), through which points were marked by the same examiner and measurements were processed. The examiner was blinded regarding the group of each patient.

For better identification of maxillary first molars in the lateral cephalograms, clinical and cephalometric characteristics were associated: presence of restorations, level of extrusion, crown angulation and general characteristics of maxillary first molars as well as adjacent and antagonist teeth. Patients who had bilateral extrusions were measured twice separately.

Skeletal, dental and soft tissue variables were used, as shown in Figure 3. In initial and final cephalograms, the centroid point was built in the crown of the intruded first molar, and a vertical line was drawn perpendicular to the palatal plane, touching the centroid point. This way, the amount of intrusion of the maxillary first molar was measured. The centroid point is less influenced by potential side effects because it is a point on the longitudinal axis. Moreover, the palatal plane was used as a reference to measure intrusion of maxillary teeth⁶ (Fig 4).

To evaluate the efficiency of the two studied intrusion protocols, the following formula was used:

$$\text{Efficiency} = \frac{\text{Amount of intrusion}}{\text{Intrusion time}}$$

With this formula, an efficiency value for molar intrusion was determined for each group separately.

Statistical analysis

To evaluate intraexaminer error, 15 randomly selected radiographs were remeasured after a month interval. Dependent t-test was applied to estimate systematic error. For evaluation of the random error, Dahlberg's formula was used.

In order to check for comparability between Groups 1 and 2 regarding the initial age, independent t-test was applied. Fisher exact test was used to evaluate intergroup comparability in relation to sex and type of malocclusion at the beginning of the study.

Independent t-test was used to compare variables between Groups 1 and 2 at the initial stage and during the intrusion period. The independent t-test was also used to compare intrusion duration between groups as well as intrusion efficiency. All statistical analyses were performed with Statistica for Windows software (Statsoft, Tulsa, Oklahoma, USA). Results were considered significant for $p < 0.05$.

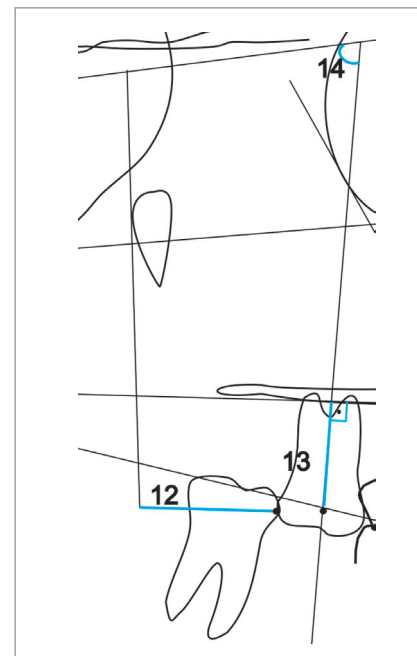
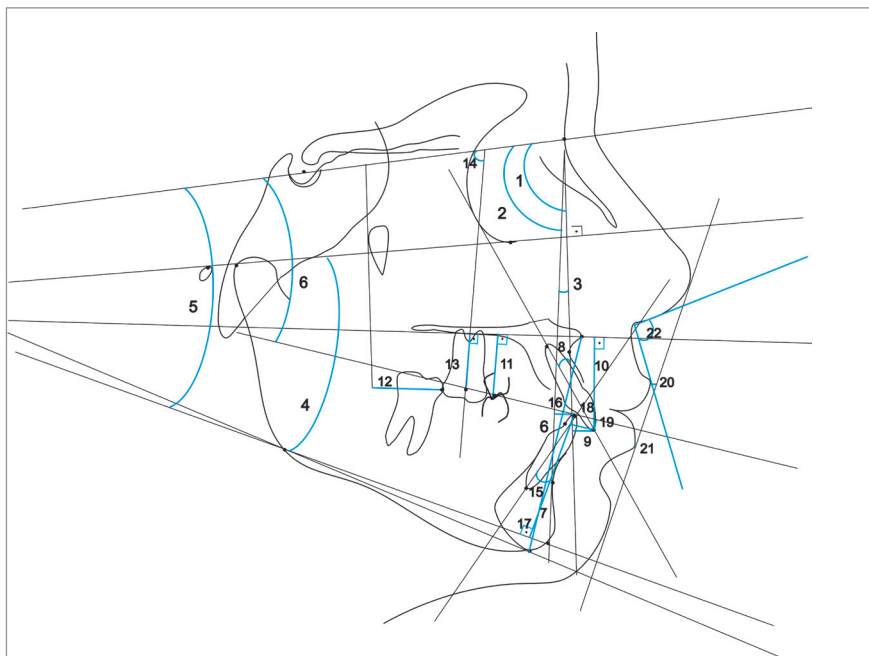


Figure 3 - Cephalometric variables: 1) SNA, 2) SNB, 3) ANB, 4) FMA, 5) SN.GoGn, 6) SN.Ocl, 7) LAFH, 8) U1.NA, 9) U1-NA, 10) U1-PP, 11) U5-PP, 12) U6-PTV, 13) U6-PP, 14) U6.SN, 15) L1.NB, 16) L1-NB, 17) L1-GoGn, 18) Overjet, 19) Overbite, 20) UL-E, 21) LL-E, 22) Nasolabial Angle.

Figure 4 - Cephalometric variables relative to the maxillary first molar: 12) U6-PTV, 13) U6-PP, 14) U6.SN.

RESULTS

No systematic error was detected and random errors varied from 0.18 mm (UL-E) to 0.47 mm (U6-PTV) in linear measurements and from 0.21° (FMA) to 0.95° (ANB). The groups were compatible regarding age, sex and type of malocclusion (Tables 1, 2 and 3). Table 4 showed that groups were also cephalometrically

compatible at the beginning of treatment. During treatment/intrusion phase, only the variable LL-E showed statistically significant difference between groups (Table 5).

There was statistically significant difference for the time of intrusion, but there was no significant difference regarding the efficiency of intrusion between the two groups (Table 6).

Table 1 - Intergroup comparability of initial age (independent t-test).

Variable (Years)	Group 1		Group 2		P Value
	Mean	SD	Mean	SD	
Initial age	34.25	8.22	39.47	8.12	0.131

Table 2 - Intergroup comparability of sex distribution (Fisher exact test).

Sex / Group	Female	Male	Total
Group 1	12	3	15
Group 2	8	2	10
Total	20	5	25
Fisher Exact Test		DF=1	p = 1.000

Table 3 - Intergroup comparability of type of malocclusion (Fisher exact test).

Type of malocclusion	Group 1 (n = 15)	Group 2 (n = 10)
Class I	8	3
Class II	7	7
Fisher Exact Test	DF=1	p = 0.413

Table 4 - Intergroup comparison of cephalometric variables at the initial stage (T₁) (independent t-tests).

Variables	Group 1		Group 2		p value
	Mean	SD	Mean	SD	
Maxillary Component					
SNA (degrees)	85.18	3.20	85.56	3.81	0.7897
Mandibular Component					
SNB (degrees)	81.43	3.75	81.48	2.20	0.9681
Maxillomandibular Relationship					
ANB (degrees)	3.77	2.41	4.08	4.75	0.8328
Vertical Component					
FMA (degrees)	27.51	4.96	27.76	6.03	0.9119
SN.GoGn (degrees)	29.98	5.63	30.60	4.55	0.7744
SN.Ocl (degrees)	6.08	7.05	7.96	3.67	0.4477
LAFH (mm)	63.24	5.32	60.12	6.98	0.2174
Maxillary Dentoalveolar Component					
U1.NA (degrees)	26.01	8.00	23.61	8.19	0.4747
U1-NA (mm)	4.80	2.77	3.15	2.76	0.1572
U1-PP (mm)	26.98	3.26	24.88	3.06	0.1196
U5-PP (mm)	23.82	2.68	22.11	4.10	0.2177
U6-PTV (mm)	19.65	2.75	19.47	3.53	0.8853
U6-PP (mm)	21.58	2.83	19.79	3.17	0.1530
U6.SN (degrees)	80.81	5.30	81.00	6.92	0.9376
Mandibular Dentoalveolar Component					
L1.NB (degrees)	27.33	5.94	22.34	5.94	0.0514
L1-NB (mm)	5.83	2.22	3.98	2.26	0.0548
L1-GoGn (mm)	37.45	2.47	37.11	3.94	0.7944
Dental Relationships					
Overjet (mm)	3.84	1.11	4.32	2.71	0.5437
Overbite(mm)	2.99	0.94	3.49	2.38	0.4717
Soft Tissue Component					
UL-E (mm)	-3.75	2.43	-4.24	3.84	0.6965
LL-E (mm)	-1.21	2.40	-1.65	2.96	0.6835
Nasolabial angle (degrees)	100.56	7.45	103.48	11.60	0.4495

Table 5 - Intergroup comparison of cephalometric changes during treatment/intrusion (T_2-T_1) (independent t -ests).

Variables	Group 1		Group 2		p value
	Mean	SD	Mean	SD	
Maxillary Component					
SNA (degrees)	0.06	1.42	0.36	1.43	0.6104
Mandibular Component					
SNB (degrees)	-0.09	1.27	0.48	0.90	0.2295
Maxillomandibular Relationship					
ANB (degrees)	0.13	0.99	-0.11	1.33	0.6134
Vertical Component					
FMA (degrees)	-0.47	1.60	-1.24	0.98	0.1863
SN.GoGn (degrees)	0.34	1.27	-0.57	1.20	0.0864
SN.Ocl (degrees)	4.81	3.66	3.44	3.39	0.3539
LAFH (mm)	-0.16	2.11	0.16	1.80	0.6978
Maxillary Dentoalveolar Component					
U1.NA (degrees)	2.33	4.98	2.13	7.76	0.9368
U1-NA (mm)	0.52	1.88	-0.12	1.97	0.4215
U1-PP (mm)	-0.59	3.23	1.73	9.32	0.3808
U5-PP (mm)	-1.39	1.90	-1.31	1.67	0.9183
U6-PTV (mm)	-0.08	2.66	0.50	2.62	0.5963
U6-PP (mm)	-1.79	1.28	-2.12	1.25	0.5253
U6.SN (degrees)	1.17	3.29	-0.42	5.02	0.3458
Mandibular Dentoalveolar Component					
L1.NB (degrees)	2.51	2.80	0.21	4.07	0.1059
L1-NB (mm)	0.33	0.95	0.15	1.13	0.6761
L1-GoGn (mm)	-0.75	1.18	-0.37	1.42	0.4780
Dental Relationships					
Overjet (mm)	0.55	1.32	-0.51	2.23	0.1484
Overbite(mm)	-1.49	1.24	-1.57	2.46	0.9117
Soft Tissue Component					
UL-E (mm)	0.30	1.98	-0.13	2.24	0.6188
LL-E (mm)	1.11	1.02	-0.65	2.65	0.0275*
Nasolabial angle (degrees)	-1.07	8.92	-4.44	8.73	0.3601

* Statistically significant for $p < 0.05$.

Table 6 - Intergroup comparison of intrusion duration and efficiency (independent t -ests).

Variables	Group 1		Group 2		P Value
	Mean	SD	Mean	SD	
Intrusion duration (years)	0.81	0.35	1.17	0.48	0.045*
Intrusion efficiency	-2.18	1.14	-1.86	1.07	0.489

* Statistically significant for $p < 0.05$

DISCUSSION

An important criterion for sample selection was to include only patients with no growth potential. In a growing patient, vertical maxillary growth and development could possibly result in a relative molar intrusion, i.e., it would be questionable whether an actual intrusion occurred or presented as a result of alveolar process growth.⁶

Patients with systemic diseases, such as diabetes, osteoporosis, heart disease, clotting disorders and metabolic bone disorders, were excluded from the sample, as these factors could influence root resorption and stability of mini-implant and consequently in treatment/intrusion time.¹⁸ Endodontically treated teeth were also excluded from the sample, since they could present an injury in healing process or root resorption, and these factors could influence the amount of intrusion.^{18,19}

The study sample consisted of two lateral cephalograms of each patient. Lateral cephalograms for evaluation of skeletal and dental changes produced by intrusion mechanics are widely used in the literature, including assessment of maxillary molar intrusion.^{4,20,21} Dolphin Imaging software computerized method also minimized errors in the determination of cephalometric values.²² Several authors have used this software in other studies, thus ensuring its reliability.²²

Groups were compatible regarding initial age (Table 1), sex distribution (Table 2), type of malocclusion (Table 3) and cephalometry at the beginning of treatment (Table 4). This allows comparability of groups, excluding factors influencing the results.

The sample was retrospectively selected, and there was probably some influence of the amount of intrusion required regarding the choice of protocols with two or three mini-implants. This possibly generated a difference between groups regarding the amount of intrusion achieved, being higher in the group in which the three mini-implant protocol was used (Table 5). This fact also explains the longer intrusion duration of this group (Table 6). However, to minimize this difference, intrusion efficiency was compared, which is the amount of intrusion achieved divided by intrusion duration, thus allowing intergroup comparison.

Cephalometric changes

During treatment/intrusion phase, there was no difference in skeletal and dental changes, except for the

variable LL-E that showed a statistically significant difference between groups (Table 5).

According to specific first molar variables, i.e. U6-PTV, U6-PP and U6.SN, it was observed that both G1 and G2 showed a significant reduction in U6-PP during treatment, demonstrating effectiveness of the intrusion mechanics. In G1, mean intrusion of the maxillary first molar of 1.79 mm was obtained; while for G2, the mean intrusion of the first molar was of 2.12 mm. Mean molar intrusion was similar between groups (Table 5, Figs 5 and 6). Molar intrusion was finished when the tooth was leveled with adjacent teeth. Therefore, the amount of intrusion ranged from 0.6 to 5 mm, which was reasonable considering the different amount of overeruption of the tooth in each patient. The amount of intrusion varied in the literature according to the clinical needs. Carrillo et al²³ achieved 1.2 to 2.3 mm, Heravi et al²⁴ ranged from 1.5 to 4.5 mm and Al-Fraidi and Zawawi²⁵ achieved 4 mm in their studies.

There was also intrusion of second maxillary premolars in both groups (mean of 1.39 and 1.31 mm for Groups 1 and 2, respectively); however, without significant difference between them (Table 5). Intrusion of premolars and molars was caused by intrusion mechanics with mini-implant anchorage. Since a leveling arch was used in fixed appliances in maxillary premolars and molars, this result was already expected. If the orthodontic mechanics of leveling and alignment was being held without intrusive force in the maxillary first molar region, premolars would probably extrude.²⁶ In the work by Yao et al,³ there was a mean intrusion of first molars and second premolars of 3 mm and 2 mm, respectively.³ These results corroborate the present study, since they show that the intrusion mechanics of the first molar also provides intrusion of the second premolar.

Both protocols in this study used forces from buccally and palatally placed mini-implants to prevent the overerupted molar from tipping either labio-palatally or mesio-distally as it was intruded. There was a small variation, in both groups, in mesiodistal angulation and anteroposterior movement of maxillary molars (U6.SN and U6-PTV, respectively, Table 5). This evinced a purely intrusive mechanics, without molar angulation that could camouflage the vertical positioning of these teeth.²⁷

The method used in this study for molar intrusion produced an excellent control of labio-palatal maxillary molar position during intrusion with elastomeric chains attached to the mini-implants.

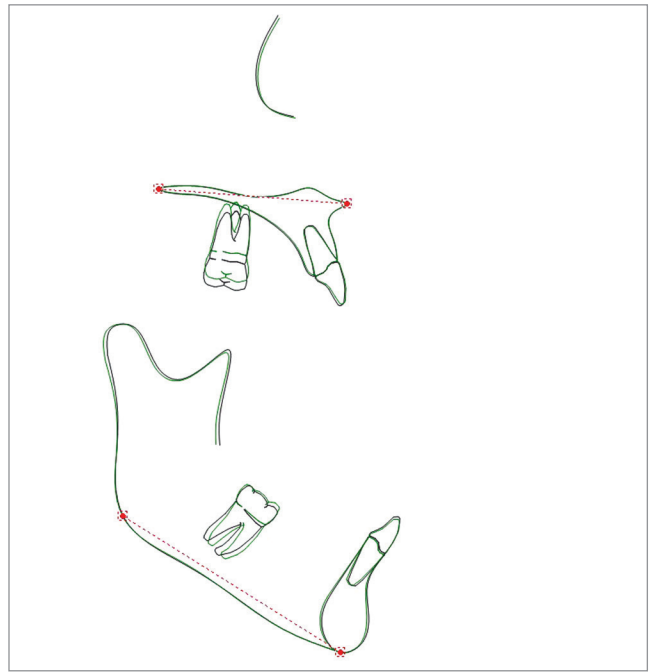
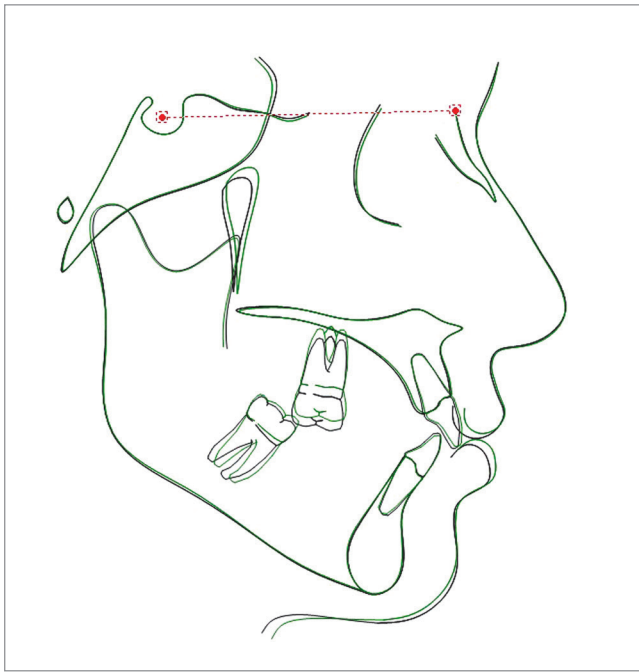


Figure 5 - Initial and final average tracings superimposition of Group 1.

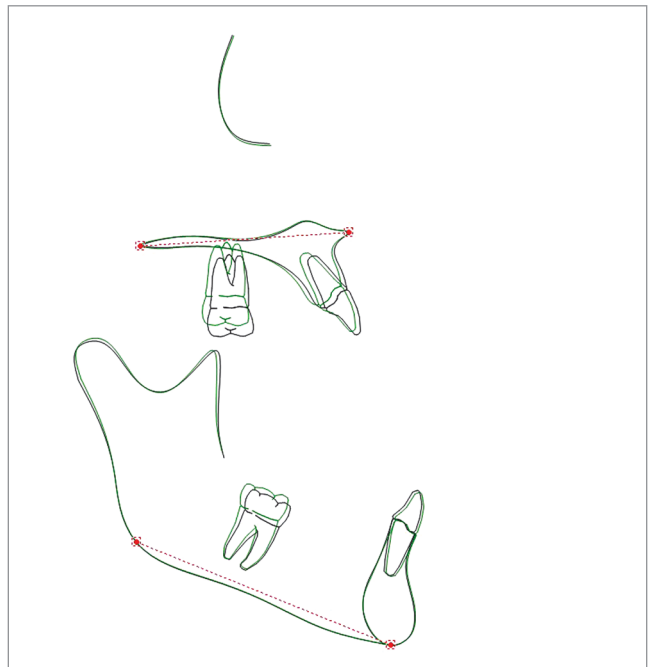
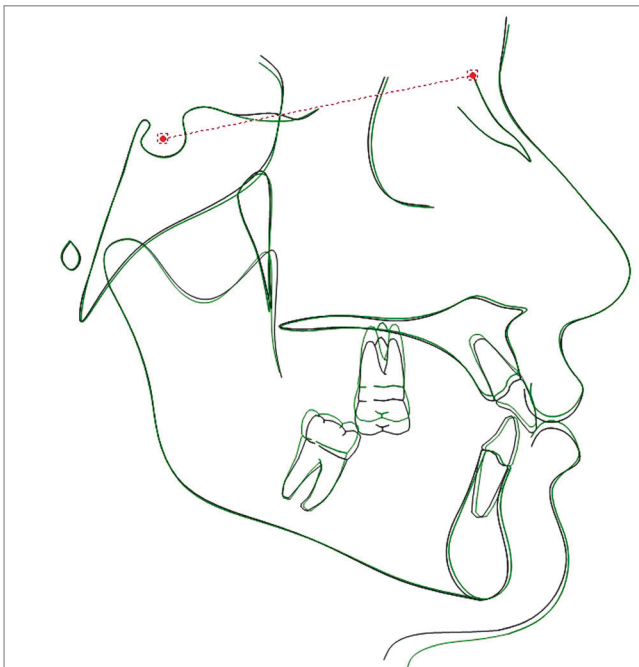


Figure 6 - Initial and final average tracings superimposition of Group 2.

There is no agreement in the literature on the optimum force to be used for molar intrusion. Some authors suggest forces ranging from 30 to 100 g,^{24,28} whereas others have recommended using greater force for intrusion (150 to 500 g).^{29,30} In this study, approximately 150 g of force was delivered from a short length of elastomeric chain. Force was carefully measured to ensure that it did not exceed the desired force level.

Regarding intrusion duration, there was statistically significant difference between groups, indicating that Group 2, the protocol with three mini-implants, showed longer intrusion duration, when compared to Group 1, the protocol with two mini-implants. However, these results are influenced by the greater or lesser need for intrusion in each case, as described above.

Maybe it is interesting that the tooth with the greatest need for intrusion has three mini-implants placed, so as to increase reinforcement of anchorage.

There was no significant difference regarding intrusion efficiency between the two groups (Table 6).

CONCLUSION

Protocols of maxillary molar intrusion with two or three mini-implants presented the same efficiency of skeletal anchorage.

Authors contribution

Conception or design of the study: JVCP, FACF, FVF. Data acquisition, analysis or interpretation: JVCP, KMSF, RHC, FPV. Writing of the article: JVCP, KMSF, RHC. Critical revision of the article: KMSF, FACF, FVF, FPV. Final approval of the article: KMSF, FACF, RHC, FVF, FPV. Obtained funding: JVCP, FACF, FVF. Overall responsibility: JVCP.

REFERENCES

1. Cheng SJ, Tseng IY, Lee JJ, Kok SH. A prospective study of the risk factors associated with failure of mini-implants used for orthodontic anchorage. *Int J Oral Maxillofac Implants*. 2004 Jan-Feb;19(1):100-6.
2. Melsen B. Limitation in adults Orthodontics. In: Melsen B, editor. *Current controversies in Orthodontics*. Chicago: Quintessence; 1991. p. 147-80.
3. Yao CC, Lee JJ, Chen HY, Chang ZC, Chang HF, Chen YJ. Maxillary molar intrusion with fixed appliances and mini-implant anchorage studied in three dimensions. *Angle Orthod*. 2005 Sept;75(5):754-60.
4. Yao CC, Wu CB, Wu HY, Kok SH, Chang HF, Chen YJ. Intrusion of the overerupted upper left first and second molars by mini-implants with partial-fixed orthodontic appliances: a case report. *Angle Orthod*. 2004 Aug;74(4):550-7.
5. Chun YS, Lim WH. Bone density at interradicular sites: implications for orthodontic mini-implant placement. *Orthod Craniofac Res*. 2009 Feb;12(1):25-32.
6. Ng J, Major PW, Flores-Mir C. True molar intrusion attained during orthodontic treatment: a systematic review. *Am J Orthod Dentofacial Orthop*. 2006 Dec;130(6):709-14.
7. Chen CH, Chang CS, Hsieh CH, Tseng YC, Shen YS, Huang IY, et al. The use of microimplants in orthodontic anchorage. *J Oral Maxillofac Surg*. 2006 Aug;64(8):1209-13.
8. Brandão LBC, Mucha JN. Rate of mini-implant acceptance by patients undergoing orthodontic treatment - A preliminary study with questionnaires. *Dental Press J Orthod*. 2008 Sept-Oct;13(5):118-27.
9. Lee SJ, Jang SY, Chun YS, Lim WH. Three-dimensional analysis of tooth movement after intrusion of a supraerupted molar using a mini-implant with partial-fixed orthodontic appliances. *Angle Orthod*. 2013 Mar;83(2):274-9.
10. Grenga V, Bovi M. Corticotomy-enhanced intrusion of an overerupted molar using skeletal anchorage and ultrasonic surgery. *J Clin Orthod*. 2013 Jan;47(1):50-5; quiz 64.
11. Sawhney C, Kumar S. Technique tips--modified transpalatal appliance: a simple non-invasive technique for maxillary molar intrusion. *Dent Update*. 2012 Apr;39(3):228.
12. Lee M, Shuman J. Maxillary molar intrusion with a single miniscrew and a transpalatal arch. *J Clin Orthod*. 2012 Jan;46(1):48-51.
13. Bae SM, Park HS, Kyung HM, Kwon OW, Sung JH. Clinical application of micro-implant anchorage. *J Clin Orthod*. 2002 May;36(5):298-302.
14. Park HS, Bae SM, Kyung HM, Sung JH. Micro-implant anchorage for treatment of skeletal Class I bialveolar protrusion. *J Clin Orthod*. 2001 July;35(7):417-22.
15. Lin JC, Liou EJ. A new bone screw for orthodontic anchorage. *J Clin Orthod*. 2003 Dec;37(12):676-81.
16. Crismani AG, Bertl MH, Celar AG, Bantleon HP, Burstone CJ. Miniscrews in orthodontic treatment: review and analysis of published clinical trials. *Am J Orthod Dentofacial Orthop*. 2010 Jan;137(1):108-13.
17. Janson G, Valarelli FP, Henriques JF, de Freitas MR, Cançado RH. Stability of anterior open bite nonextraction treatment in the permanent dentition. *Am J Orthod Dentofacial Orthop*. 2003 Sept;124(3):265-76; quiz 340.
18. Abuabara A. Biomechanical aspects of external root resorption in orthodontic therapy. *Med Oral Patol Oral Cir Bucal*. 2007 Dec 1;12(8):E610-3.
19. Chung KR, Kim SH, Kang YG, Nelson G. Orthodontic miniplate with tube as an efficient tool for borderline cases. *Am J Orthod Dentofacial Orthop*. 2011 Apr;139(4):551-62.
20. Erverdi N, Keles A, Nanda R. The use of skeletal anchorage in open bite treatment: a cephalometric evaluation. *Angle Orthod*. 2004 Jun;74(3):381-90.
21. Moon CH, Wee JU, Lee HS. Intrusion of overerupted molars by corticotomy and orthodontic skeletal anchorage. *Angle Orthod*. 2007 Nov;77(6):1119-25.
22. Thurzo A, Javorka V, Stanko P, Lysy J, Suchancova B, Lehotska V, et al. Digital and manual cephalometric analysis. *Bratisl Lek Listy*. 2010;111(2):97-100.
23. Carrillo R, Rossouw PE, Franco PF, Opperman LA, Buschang PH. Intrusion of multiradicular teeth and related root resorption with mini-screw implant anchorage: a radiographic evaluation. *Am J Orthod Dentofacial Orthop*. 2007 Nov;132(5):647-55.
24. Heravi F, Bayani S, Madani AS, Radvar M, Anbiaee N. Intrusion of supra-erupted molars using miniscrews: clinical success and root resorption. *Am J Orthod Dentofacial Orthop*. 2011 Apr;139(4 Suppl):S170-5.
25. Al-Fraid AA, Zawawi KH. Clinical showcase. Selective intrusion of overerupted upper first molars using a temporary anchorage device: case report. *J Can Dent Assoc*. 2010;76:a9.
26. Armbruster P, Sheridan JJ, Nguyen P. An Essix intrusion appliance. *J Clin Orthod*. 2003 Aug;37(8):412-6.
27. Romeo A, Esteves M, García V, Bermúdez J. Movement evaluation of overerupted upper molars with absolute anchorage: an in-vitro study. *Med Oral Patol Oral Cir Bucal*. 2010 Nov 1;15(6):e930-5.
28. Melo AC, Jawonski ME, Largura LZ, Thomé G, Souza JR, Silva MA. Upper molar intrusion in rehabilitation patients with the aid of microscrews. *Aust Orthod J*. 2008 May;24(1):50-3.
29. Umemori M, Sugawara J, Mitani H, Nagasaka H, Kawamura H. Skeletal anchorage system for open-bite correction. *Am J Orthod Dentofacial Orthop*. 1999 Feb;115(2):166-74.
30. Park YC, Lee SY, Kim DH, Jee SH. Intrusion of posterior teeth using mini-screw implants. *Am J Orthod Dentofacial Orthop*. 2003 Jun;123(6):690-4.