



Since January 2020 Elsevier has created a COVID-19 resource centre with free information in English and Mandarin on the novel coronavirus COVID-19. The COVID-19 resource centre is hosted on Elsevier Connect, the company's public news and information website.

Elsevier hereby grants permission to make all its COVID-19-related research that is available on the COVID-19 resource centre - including this research content - immediately available in PubMed Central and other publicly funded repositories, such as the WHO COVID database with rights for unrestricted research re-use and analyses in any form or by any means with acknowledgement of the original source. These permissions are granted for free by Elsevier for as long as the COVID-19 resource centre remains active.



CJC Open ■ (2022) 1–4

## Case Report

# A Case of Recurrent Myocarditis After COVID-19 Vaccination, Due to Acute Myeloid Leukemia

Isabelle Dobronyi, MD,<sup>a</sup> Danielle Porter, PharmD,<sup>b</sup> Idan Roifman, MD,<sup>a</sup> Ady Orbach, MD,<sup>a</sup> and Bradley H. Strauss, MD<sup>a</sup>

<sup>a</sup> Division of Cardiology, Schulich Heart Program, Sunnybrook Health Sciences Centre, University of Toronto, Toronto, Ontario, Canada

<sup>b</sup> Department of Pharmacy, Schulich Heart Program, Sunnybrook Health Sciences Centre, University of Toronto, Toronto, Ontario, Canada

## ABSTRACT

A 25-year-old man presented with chest pain and an elevated troponin level following COVID-19 vaccination. Despite initial response to nonsteroidal anti-inflammatory drugs, he developed a recurrent and relapsing course requiring multiple readmissions. Cardiac magnetic resonance imaging confirmed myocarditis. Due to progressing macrocytic anemia, he was eventually diagnosed with acute myeloid leukemia, thought to be the underlying driver of his recurrent and persistent myocarditis.

## RÉSUMÉ

Nous relatons le cas d'un homme de 25 ans qui présentait une douleur thoracique et un taux élevé de troponine après avoir reçu un vaccin contre la COVID-19. Malgré la réponse initiale du patient aux anti-inflammatoires non stéroïdiens, le tableau clinique a évolué sur un mode récurrent et récidivant, et nécessité plusieurs réhospitalisations. L'imagerie par résonance magnétique cardiaque a permis de confirmer la présence d'une myocardite. Dans un contexte d'anémie macrocytaire évolutive, le patient a finalement reçu un diagnostic de leucémie myéloblastique aiguë, considérée comme le facteur sous-jacent de la myocardite récurrente et persistante dont il était atteint.

A 25-year-old man presented with chest pain and an elevated troponin level following COVID-19 vaccination. Despite initial response to nonsteroidal anti-inflammatory drugs, he developed a recurrent and relapsing course requiring multiple readmissions. Cardiac magnetic resonance imaging (CMR) confirmed myocarditis. Due to progressing macrocytic anemia, he was eventually diagnosed with acute myeloid leukemia, thought to be the underlying driver of his recurrent and persistent myocarditis.

developed chest tightness radiating to his arm, and he was diagnosed at a separate hospital with suspected vaccine-associated myopericarditis, based on symptoms, timing, and an elevated troponin level (Table 1). A COVID-19 nasopharyngeal polymerase chain reaction (PCR) test was negative. An echocardiogram was normal, and no further imaging was done. The case was reported to Health Canada. The patient was prescribed 3 months of colchicine and 1 month of aspirin, and the symptoms completely resolved after approximately 3 weeks of therapy.

## Initial Presentation With Myopericarditis (May 2021)

The patient was otherwise healthy, with no allergies, history of vaccine complications, or personal or family history of any cardiac disease or malignancy. Seven days after his first dose of the COVID-19 vaccine (Pfizer-BioNTech), he

## Myopericarditis Recurrence (July 2021)

Eight weeks following the initiation of colchicine, and approximately 5 weeks after his last symptoms, he experienced recurrent chest pains, biochemical evidence of myopericarditis, and mild leukopenia (Table 1). His hemoglobin, platelets, and blood film were normal, and a COVID-19 nasopharyngeal PCR test was negative. A transthoracic echocardiogram (TTE) was normal. CMR imaging showed a reduced left ventricular ejection fraction of 47%, a hyperintense T2 signal, and multifocal subepicardial late gadolinium enhancement, mainly in the anterolateral wall (Fig. 1). The native T1 mapping confirmed elevated T1 values in the mid and apical slices, confirming acute myocarditis (Supplemental Fig. S1). Despite another 7-day course of high-dose nonsteroidal anti-inflammatory drugs (NSAIDs), his

Received for publication June 3, 2022. Accepted October 2, 2022.

**Ethics Statement:** The research reported has adhered to the relevant ethical guidelines.

Corresponding author: Dr Bradley Strauss, Reichmann Chair in Cardiovascular Research, Schulich Heart Centre, Sunnybrook Health Sciences Centre, 2075 Bayview Ave., Suite D4-08, Toronto, ON M4N 3M5, Canada. Tel.: +1-416-480-6066; fax: +1-416-480-6066.

E-mail: [bradley.strauss@sunnybrook.ca](mailto:bradley.strauss@sunnybrook.ca)

See page 4 for disclosure information.

<https://doi.org/10.1016/j.cjco.2022.10.001>

2589-790X/© 2022 The Authors. Published by Elsevier Inc. on behalf of the Canadian Cardiovascular Society. This is an open access article under the CC BY-NC-ND license (<http://creativecommons.org/licenses/by-nc-nd/4.0/>).

**Novel Teaching Points**

- With refractory symptoms despite an adequate NSAID trial, steroids can be beneficial but must be tapered slowly, guided by symptoms and biomarkers (erythrocyte sedimentation rate, C-Reactive protein, troponin).
- If myopericarditis following vaccination is recurrent, relapsing, or persistent, despite conservative treatment, further diagnostic workup is warranted. Endomyocardial biopsy may be of value in this situation. Vaccine-induced myopericarditis remains a diagnosis of exclusion.

chest pain persisted, and his biomarker levels increased (Table 1). Although no treatment guidelines have been developed for COVID-19 vaccine-associated myopericarditis, case reviews have indicated that NSAIDs, with or without colchicine, are reasonable first-line options, with corticosteroids reserved for refractory cases.<sup>1</sup> Guidelines recommend slow tapering of corticosteroids, especially as the dose approaches 15 mg, and only if the patient is asymptomatic, with negative biomarkers.<sup>2</sup> He was started on prednisone, with tapering guided by the outpatient cardiologist.

Diagnostic workup included a computed tomography coronary angiogram, autoimmune serology with an extended antibody panel for myositis, testing for infectious causes, and urine toxicology screening. These tests revealed no alternative cause for myocarditis, and the patient was advised to avoid future COVID-19 mRNA vaccines, based on the presumption that his myocarditis was vaccine-associated. At discharge, he was asymptomatic, with decreasing biomarker levels.

**Myocarditis Fails to Resolve and Anemia Develops (September 2021)**

When prednisone was decreased to 5 mg, his chest pain recurred, his biomarker levels increased, and he was readmitted (Table 1). A COVID-19 nasopharyngeal PCR test was negative. Repeat CMR imaging showed a left ventricular ejection fraction of 42%, with sub-epicardial and mid-myocardial late gadolinium enhancement in the inferior, inferolateral, and, less prominently, anterolateral walls, again confirming myocarditis (Supplemental Fig. S2). At this point, endomyocardial biopsy (EMB) was discussed but not performed, as the relapse was felt to be related to the pace of the prednisone tapering, and the presumed etiology was still the COVID-19 vaccine. Prednisone was increased to 30 mg, with

a more gradual tapering, guided by symptoms and biomarkers, which both improved at the time of discharge (Table 1). A macrocytic anemia and an elevated ferritin level were new findings (Table 1). Thyroid-stimulating hormone, reticulocytes, platelets, hemolytic panel, blood film, liver profile, and hemochromatosis gene (HFE) testing were normal, and abdominal ultrasound showed no hepatosplenomegaly nor lymphadenopathy. The anemia and abnormal ferritin were therefore attributed to inflammation and/or myelosuppression from prolonged colchicine use. He was referred to the outpatient hematology team for further investigation, including possible bone marrow biopsy should the abnormalities persist.

**Chronic Myocarditis Leads to a New Diagnosis (December 2021)**

With prednisone reduction to 15 mg, he was admitted with another recurrence of symptoms and elevated biomarker levels (Table 1). A COVID-19 nasopharyngeal PCR test remained negative (December 6 and 9). His hemoglobin level had declined by approximately 20 points since his last admission, and by > 45 points since the initial diagnosis of myocarditis (Table 1). The combination of clinical and biochemical progression despite treatment raised concern for a primary hematologic disorder. A bone marrow biopsy was diagnostic for acute myeloid leukemia (AML) with 25% blasts. Cytogenetics, next-generation sequencing, and genetic testing, including *FLT3*, *JAK2*, *NPM1*, *TPMT*, and *KMT2A*, showed wildtype, with a normal male karyotype. He was started on induction chemotherapy with 3 + 7 (daunorubicin and cytarabine) with gemtuzumab ozogamicin. The potential for cardiotoxicity with daunorubicin raised concerns that chemotherapy could worsen myocardial dysfunction, particularly if the etiology was solely vaccine-associated, so regular TTE follow-up was recommended. Prior to induction chemotherapy, he tested positive for COVID-19 on routine screening (December 21, strain not typed), but was only mildly symptomatic. He received sotrovimab to prevent severe disease given his immunosuppression with only one dose of the COVID-19 vaccine. Following AML treatment, his chest pain resolved, his troponin level normalized (Table 1), and a repeat TTE was normal.

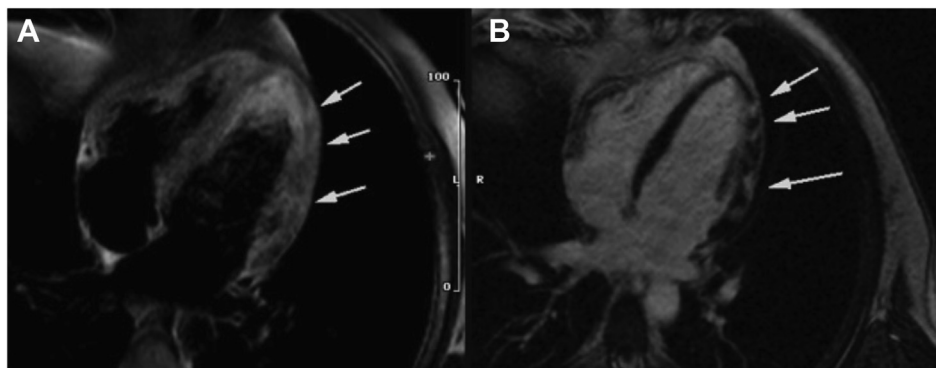
**Discussion**

The key question in this case is the underlying etiology of myocarditis. Vaccine-associated myocarditis was the lead candidate in the differential diagnosis, owing to similarities to

**Table 1. Biomarker trends**

Timeline event	Troponin, ng/L	ESR, mm/h	CRP, mg/L	Hemoglobin, g/L	MCV, fL	Ferritin, ug/L	Leukocytes, ×10 <sup>9</sup> /L
First presentation (May 19, 2021)	395	—	—	148	93	—	2.9
Myocarditis recurrence (July 20, 2021)	630	21	11	146	91.2	277	3.1
Readmission (September 26, 2021)	852	41	41	121	103.2	827	3.2
Chronic myocarditis (December 6, 2021)	232	45	19	102	114.5	714	3
Day 1 induction chemotherapy (December 22, 2021)	11	—	—	88	115.7	—	4.1
Post-induction chemotherapy (January 28, 2021)	15	—	—	124	96.9	—	7

CRP, C-reactive protein; ESR, erythrocyte sedimentation rate; MCV, mean corpuscular volume.



**Figure 1.** (A) T2-weighted imaging showing increased signal intensity in patchy distribution in the anterolateral wall. (B) Late gadolinium enhancement in the anterolateral wall.

concurrent reports of adverse effects from mRNA COVID-19 vaccines in the medical literature and general media. We tried to remain wary of the risk for confirmation bias and the availability heuristic in this context. Cases of COVID-19 vaccine-associated myopericarditis in Canada are consistently reported to have occurred more often in males, in those aged 12-29 years, within a week of vaccination, and following the second dose.<sup>3</sup> Symptoms generally begin within a week of vaccination, and disease has tended to be mild.<sup>1</sup>

The ongoing complexity of our patient's course seemed unusual, and still, no reports have been made of recurrent vaccine-associated myopericarditis without a subsequent dose of COVID-19 vaccine. These factors prompted consideration of alternative causes. The working hypothesis of solely vaccine-associated myocarditis seemed unlikely, and in September 2021, clinical worsening was accompanied by new hematologic changes. Our patient had hematologic lab abnormalities earlier in the course of his illness (Table 1), but these were mild, nonspecific, and originally attributed to systemic inflammation or colchicine-related myelosuppression. Although AML is an established cause for myocarditis, it is rare. Only 3 cases in the literature describe initial myocarditis leading to the diagnosis of AML in adults.<sup>4-6</sup> Those patients also presented with chest pain, elevated troponin level, and imaging findings of myocarditis, but their initial bloodwork immediately raised suspicion for an acute myeloproliferative disorder. In our described case, the hematologic abnormalities up until the time of the failed steroid taper (September 2021) were not deemed significant enough to perform a bone marrow biopsy (Table 1).

EMB was considered at this point, but it was not pursued for several reasons, including an improvement in symptoms after prednisone was increased, clinical suspicion of recurrence being treatment-driven, mildness of cardiac dysfunction without clinical heart failure, negative serologic autoimmune panels, and the plan for further hematologic investigations. Luk et al. suggest performing EMB in suspected vaccine-associated myocarditis when another specific cause of myocarditis is being considered for which a disease-specific therapy exists, or if the patient is unstable or has unexpected deterioration despite usual care.<sup>1</sup> Few biopsy-confirmed myocarditis cases in the pandemic have been reported, but reviews to date suggest that EMB may be normal or nonspecific.<sup>1</sup>

The pathophysiology of COVID-19 vaccine-associated myocarditis is not well established. Thurner et al. have suggested that mRNA COVID-19 vaccines, like the COVID-19 virus itself, induce myocarditis through upregulation of cytokines, and in particular interleukin-1 (IL-1).<sup>7</sup> IL-1 release is normally curbed by endogenous IL-1 receptor antagonist (IL-1Ra). A higher prevalence of autoantibodies targeting IL-1Ra was identified in 12 of 40 EMB-confirmed cases of myocarditis following mRNA COVID-19 vaccination.<sup>7</sup> These antibodies against IL-1Ra suppressed IL-1Ra activity *in vitro* and appeared to lower IL-1Ra levels *in vivo*, leading to the hypothesis that the COVID-19 mRNA vaccine causes myocardial damage by impairing the body's innate moderation of IL-1, thus leading to unchecked inflammation.<sup>7</sup> Similarly, abnormal clonal myeloid cells in AML release pro-inflammatory cytokines, typically IL-1.<sup>8</sup> In addition, AML has been shown to specifically cause direct myocardial damage through leukemic infiltration, localized hemorrhage, or both, and it is frequently subclinical.<sup>4,6</sup> Our hypothesis remains that the COVID-19 mRNA vaccine acted as a trigger for myocarditis in the setting of immunologic dysfunction from occult leukemia, and subsequent progression to fulminant AML precipitated his recurrence and steroid resistance. The vaccine may have heightened the effect of an already dysregulated cytokine system, particularly with subclinical cardiac infiltration from yet-undetected abnormal myeloid cells. If so, this case is the first reported of vaccine-associated myocarditis recurring due to underlying AML. Similar to other case reports of myocarditis in AML, the patient's symptoms and biomarkers resolved with chemotherapy, further supporting the theory that the malignancy was driving active cardiac inflammation at that time.<sup>4-6</sup> This case highlights that recurrent and persistent disease in suspected COVID-19 vaccine-associated myopericarditis should prompt investigation for an alternative or concurrent inflammatory trigger.

This case also demonstrates the potential risk of restricting subsequent mRNA vaccine doses in patients with myopericarditis following COVID-19 vaccination. Our patient contracted COVID-19, and although he managed to avoid complication, was at high risk for severe infection due to immunosuppression and single vaccine dose. At present, Public Health Canada recommends that additional doses of a COVID-19 mRNA vaccine be deferred in individuals 12

years and older with a history of confirmed myocarditis after vaccination, but that they “may choose to receive another dose of vaccine after discussing the risk and benefit with their healthcare provider.”<sup>3</sup> More data are needed to provide guidance to patients with a history of confirmed myopericarditis following vaccination.

### Funding Sources

The authors have no funding sources to declare.

### Disclosures

The authors have no conflicts of interest to disclose.

### References

1. Luk A, Clarke B, Dahdah N, et al. Myocarditis and pericarditis after COVID-19 mRNA vaccination: practical considerations for care providers. *Can J Cardiol* 2021;37:1629-34.
2. Adler Y, Charron P. The 2015 ESC guidelines on the diagnosis and management of pericardial diseases. *Eur Heart J* 2015;36:2873-4.
3. Government of Canada. COVID-19 vaccine: Canadian immunization guide, <https://www.canada.ca/en/public-health/services/publications/healthy-living/canadian-immunization-guide-part-4-active-vaccines/page-26-covid-19-vaccine.html>. Accessed July 20, 2022.
4. Agrawal K, Miles L, Agrawal N, Khan A. Atypical presentation of acute myeloid leukemia. *World J Oncol* 2018;9:29-34.
5. Snavely C, Habboushe J. Myopericarditis as a presenting feature of acute myeloid leukemia. *J Emerg Med* 2020;59:183-5.
6. Burkeen CG, Pottinger D, Iragavarapu C, Ramlal R, Hildebrandt G. Myocarditis concurrent with sweet syndrome: a presentation of acute myeloid leukemia. *Case Rep Hematol* 2021;2021:6621007.
7. Thurner L, Kessel C, Fadle N, et al. IL-1RA antibodies in myocarditis after SARS-CoV-2 vaccination [e-pub ahead of print]. *N Engl J Med* <https://doi.org/10.1056/NEJMc2205667>. Accessed September 24, 2022.
8. Soyfer EM, Fleischman AG. Inflammation in myeloid malignancies: from bench to bedside. *J Immunother Precis Oncol* 2021;4:160-7.

### Supplementary Material

To access the supplementary material accompanying this article, visit *CJC Open* at <https://www.cjopen.ca/> and at <https://doi.org/10.1016/j.cjco.2022.10.001>.