

## Subconjunctival sustained-release dexamethasone implant as an adjunct to trabeculectomy for primary open angle glaucoma

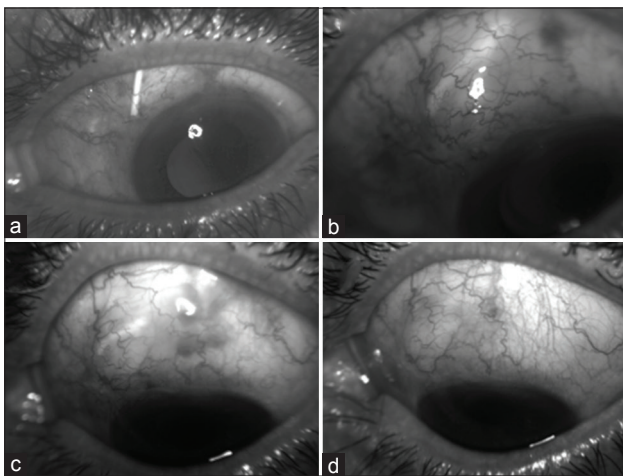
Sir,

In the present study, we described the first case series of intraoperative positioning of subconjunctival dexamethasone implant as adjunctive antiscarring agent in patients undergone trabeculectomy for primary open angle glaucoma (POAG).

The rationale of subconjunctival dexamethasone implant injection was to reduce the postsurgical over-scarring at the site of the bleb, by limiting the first acute inflammatory reaction that represents the *primus movens* for conjunctival healing.

Three eyes of three consecutive patients (three female) with a mean age of  $61 \pm 14.5$  years taking a maximum tolerated dose of intraocular pressure (IOP)-lowering medication for POAG with a recorded IOP of  $\geq 18$  mmHg, glaucomatous damage on visual field and underwent trabeculectomy: All patients underwent a limbus-based conjunctival flap with one circumferential and one radial incision, antimetabolite sponge application, and scleral rectangular flap which was sutured with 10-0 nylon suture, sclerostomy with punch a peripheral iridectomy. Before the conjunctival suture with 9-0 vicryl was performed, a subconjunctival apposition without fixation of 0.7 mg sustained-release dexamethasone implant (Ozurdex, Allergan, Inc., Irvine, USA) was obtained. The implant was softly leaned on the sclera posterior to the flap.

After 7 days, 1 month, and 2 months, the implant seemed to fragment reducing progressively its dimensions and was no more detectable after 2 months in all eyes [Fig. 1].



**Figure 1:** Patient with primary open angle glaucoma undergone trabeculectomy and subconjunctival apposition of 0.7 mg sustained-release dexamethasone implant at day 1 (a), day 7 (b), month 1 (c), and month 2 (d). The implant seemed to fragment reducing progressively its dimensions and was no more detectable after 2 months

After 2 months, IOP not quite significantly ( $P = 0.056$ , nonparametric Mann–Whitney U-test) decreased from  $19.3 \pm 2.3$  mmHg (median: 18, interquartile range [IQR]: 4) at baseline to  $15.7 \pm 0.6$  mmHg (median: 16, IQR: 1) without any glaucoma medication. In all eyes, IOP was  $\leq 16$  mmHg (range: 15–16).

After 2 months in all the cases, conjunctival scarring at the site of the filtering bleb was not observed. No ocular adverse event or postoperative complications were observed.

Corticosteroids have long been used as inflammation modulators of posttrabeculectomy conjunctival healing with significantly success rates, since they act on vascular permeability, as well as white blood cell chemotaxis and function.<sup>[1]</sup>

First evidence of steroids effects in glaucoma surgery came from Starita *et al.*,<sup>[2,3]</sup> who investigated the effects of topical and systemic steroids in a randomized prospective trial. They found that topical steroids significantly improved trabeculectomy outcome as compared to the group without steroids at 5 and 10 years.

There are studies about the intraoperative subconjunctival injection of triamcinolone acetonide (TA) after bleb-forming filtration surgery.<sup>[4]</sup> TA injections appeared to be safe in both studies, with no significant adverse events, even if results of a randomized controlled trial about long-term clinical benefits in patients receiving intrableb TA against whom receiving topical steroids only, have not been published yet. The rationale of intraoperative subconjunctival corticosteroid injection was to find a more direct, sustained, and convenient mode of steroid delivery in the operated patients; moreover, the bulk of injected TA would also serve as a barrier between the inflamed conjunctiva and sclera, to avoid adherence in between. In this view, Ozurdex implant would be even more effective than TA, lasting longer and interposing a bigger volume in the conjunctival layers.

Subconjunctival implant appears to be well tolerated by operated eyes. However, use of Ozurdex has been associated with several adverse events including posterior subcapsular cataract and a higher risk of eye infections;<sup>[5]</sup> reasonably, the most threatening glaucoma surgery success is eye pressure increase that may need supplementary IOP lowering medical therapy after trabeculectomy. Effective success of surgery should therefore be taken only several weeks after the operation, when the insert is completely reabsorbed.

Limitations of this study were the small sample size and the absence of a control group.

The data of this pilot study showed that no serious side effects were noted, subconjunctival Ozurdex was well tolerated and that a controlled study is required to establish the efficacy of this easy to perform the technique.

### Financial support and sponsorship

Nil.

### Conflicts of interest

There are no conflicts of interest.

**Claudio Furino, Francesco Boscia<sup>1</sup>,  
Maria Vittoria Cicinelli, Alessandra Sborgia,  
Giovanni Alessio**

Department of Ophthalmology, University of Bari, Bari, <sup>1</sup>Department of Ophthalmology, Eye Clinic, University of Sassari, Sassari, Italy

Correspondence to: Dr. Claudio Furino,  
Department of Ophthalmology, University of Bari, Piazza Giulio  
Cesare 11, 70124 Bari, Italy.  
E-mail: claudiofurino@gmail.com

## References

1. Nuzzi R, Vercelli A, Finazzo C, Cracco C. Conjunctiva and subconjunctival tissue in primary open-angle glaucoma after long-term topical treatment: An immunohistochemical and ultrastructural study. *Graefes Arch Clin Exp Ophthalmol* 1995;233:154-62.
2. Starita RJ, Fellman RL, Spaeth GL, Poryzees EM, Greenidge KC, Traverso CE. Short- and long-term effects of postoperative corticosteroids on trabeculectomy. *Ophthalmology* 1985;92:938-46.
3. Araujo SV, Spaeth GL, Roth SM, Starita RJ. A ten-year follow-up on a prospective, randomized trial of postoperative corticosteroids after trabeculectomy. *Ophthalmology* 1995;102:1753-9.
4. Giangiacomo J, Dueker DK, Adelstein E. The effect of preoperative subconjunctival triamcinolone administration on glaucoma filtration. I. Trabeculectomy following subconjunctival triamcinolone. *Arch Ophthalmol* 1986;104:838-41.
5. London NJ, Chiang A, Haller JA. The dexamethasone drug delivery system: Indications and evidence. *Adv Ther* 2011;28:351-66.

This is an open access article distributed under the terms of the Creative Commons Attribution-NonCommercial-ShareAlike 3.0 License, which allows others to remix, tweak, and build upon the work non-commercially, as long as the author is credited and the new creations are licensed under the identical terms.

### Access this article online

Quick Response Code:	Website:
	<a href="http://www.ijo.in">www.ijo.in</a>
	DOI: 10.4103/0301-4738.181735

**Cite this article as:** Furino C, Boscia F, Cicinelli MV, Sborgia A, Alessio G. Subconjunctival sustained-release dexamethasone implant as an adjunct to trabeculectomy for primary open angle glaucoma. *Indian J Ophthalmol* 2016;64:251-2.