



Contents lists available at ScienceDirect

International Journal of Surgery Case Reports

journal homepage: www.casereports.com

Trigger finger following partial flexor tendon laceration: Magnetic resonance imaging-assisted diagnosis



Jose Couceiro*, Javier Fraga, Marcos Sanmartin

Hand Surgery Unit, Orthopaedics Department, POVISA Hospital, Calle Salamanca, 5, 36211 Vigo, Spain

ARTICLE INFO

Article history:

Received 8 December 2014

Received in revised form 18 February 2015

Accepted 2 March 2015

Available online 4 March 2015

Keywords:

Partial tendon laceration

Magnetic resonance

Diagnosis

ABSTRACT

INTRODUCTION: Post-traumatic trigger finger is considerably rarer than normal trigger finger. The diagnosis is usually made on a clinical basis. This can be obscured; however, by concurrent pathological conditions. We report a case of post-traumatic trigger finger in which diagnosis was aided by magnetic resonance imaging (MRI).

PRESENTATION OF CASE: Our patient is a 32-year-old male who had a previous laceration with a subsequent surgery for infectious tenosynovitis. The MRI showed the impinging tendon tag. Surgical excision of the tag successfully solved the case.

DISCUSSION: The use of imaging studies for the diagnosis of post-traumatic trigger finger has been previously reported, the authors described a variation on the contour of the pulley system. The full lacerated tendon tag can be seen on our patient's MRI.

CONCLUSION: On this case, the use of MRI was a useful aid for the differential diagnosis of post-traumatic trigger finger.

© 2015 The Authors. Published by Elsevier Ltd. on behalf of Surgical Associates Ltd. This is an open access article under the CC BY-NC-ND license (<http://creativecommons.org/licenses/by-nc-nd/4.0/>).

1. Introduction

Trigger finger is a common condition, and the most frequent cause is stenosing tenosynovitis. Post-traumatic trigger finger is considerably more rare [1–4]. The triggering in these cases is caused by the impingement of the lacerated tendon tag against the pulley system. Diagnosis is usually made on a clinical basis; this can be more challenging when other pathological conditions such as concurrent infections are suspected. We present a case of trigger finger involving a partially lacerated flexor digitorum superficialis that was diagnosed using magnetic resonance imaging (MRI).

2. Case report

Our patient was a 32-year-old male who presented three months after a laceration of the left index finger in the area of the proximal interphalangeal crease; he reported having it stitched in an emergency room. The patient underwent a previous operation for suspected infectious tenosynovitis of the flexor tendon sheath.

On exam, the patient exhibited diffuse pain on palpation of the volar surface of the finger; he had pain with finger flexion but showed no redness and maintained full finger motion. Two-point discrimination was 6 mm on both sides of the digit. Clicking with digit flexion was observed in the area of the middle phalanx. Scars

from the previous intervention were observed on the fingertip and the palm of the hand, but the area of the previous traumatic laceration appeared to have not been explored.

Differential diagnosis included subacute infectious tenosynovitis of the flexor tendon sheath and triggering following a partial flexor tendon laceration that was left unexplored during the previous surgery.

To assist in the diagnosis, an MRI of the finger was obtained. The impinging tendon tag was observed on the sagittal images (Fig. 1).

The patient underwent surgery (Fig. 2), and a standard Brunner approach was performed. An area of bulging was observed at the level of the C1 and A3 pulleys, and these pulleys were opened longitudinally along the ulnar border. A partial laceration that comprised approximately 25% of the ulnar slip of the flexor digitorum superficialis tendon was observed (Fig. 3). This tendon tag appeared to have been impinging on the proximal border of the A3 pulley. The tendon tag was excised, and the pulleys were left open (Fig. 4). This solved the impingement problem. Three months after surgery, the patient had returned to work and had no further recurrence of symptoms.

3. Discussion

The use of imaging studies in the diagnosis of triggering secondary to partial flexor tendon lacerations has been previously reported. Fujiwara [1] reported a case that was diagnosed with the use of ultrasound and concluded that identifying thickening of a

* Corresponding author. Tel.: +34 676230437; fax: +34 986413144.
E-mail address: couceirox@gmail.com (J. Couceiro).

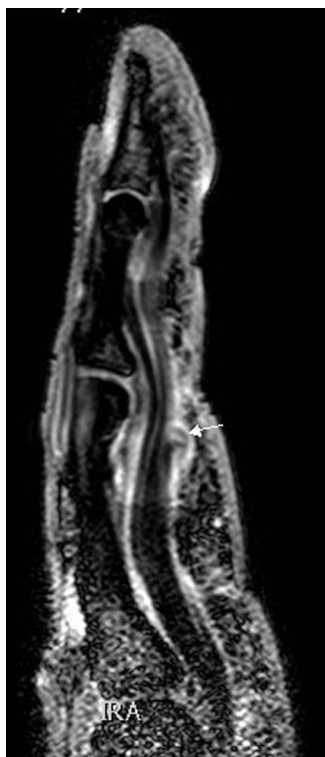

Fig. 1. Magnetic resonance T2 weighed sagittal image showing the impinging flexor tendon tag (arrow).

tendon or pulley was useful in the diagnosis of partial flexor tendon lacerations.

More recently, Okano et al. [3] reported a case in which MRI was used for the diagnosis; the contour of the flexor tendon was noted to be irregular on the ulnar side, and during surgery, they encountered a partial laceration of the flexor digitorum superficialis.

In our case, the patient had a previous surgery by another physician for a suspected infectious tenosynovitis. It was unclear whether he initially presented with one or more of the Kanavel signs [5], at his first visit to our clinic, he exhibited a diffuse pain at the volar aspect of the affected digit apart from the clicking that made us suspect a partially lacerated flexor tendon. It was this incomplete history and the possibility of a mistreated ongoing infection, that prompted us to request imaging studies of the

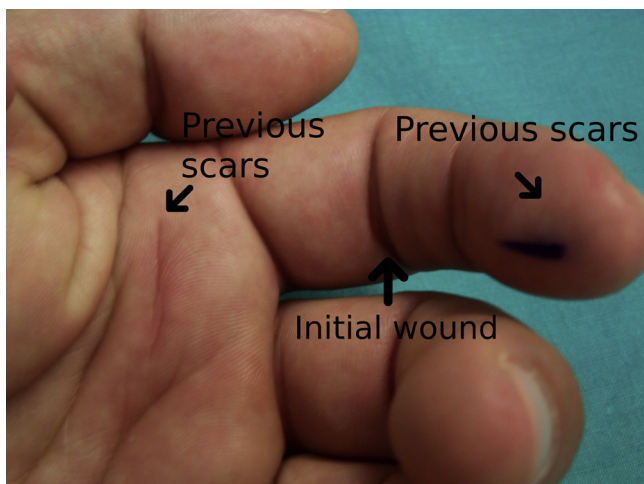


Fig. 2. Preoperative image: the sites of the previous surgical scars and the initial wound are shown.

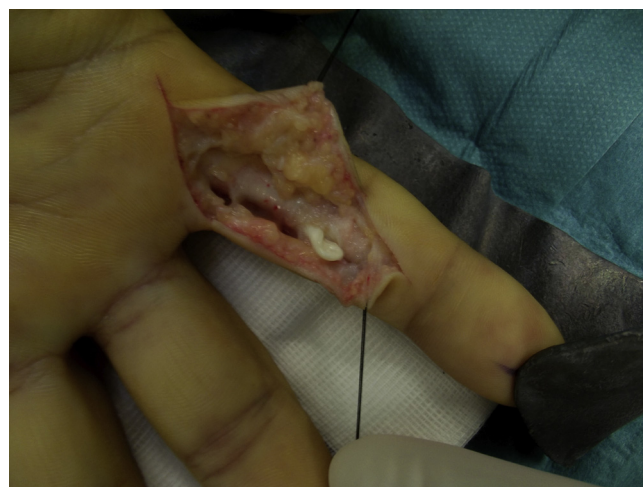

Fig. 3. Intraoperative image of the partially lacerated ulnar FDS slip before debridement.

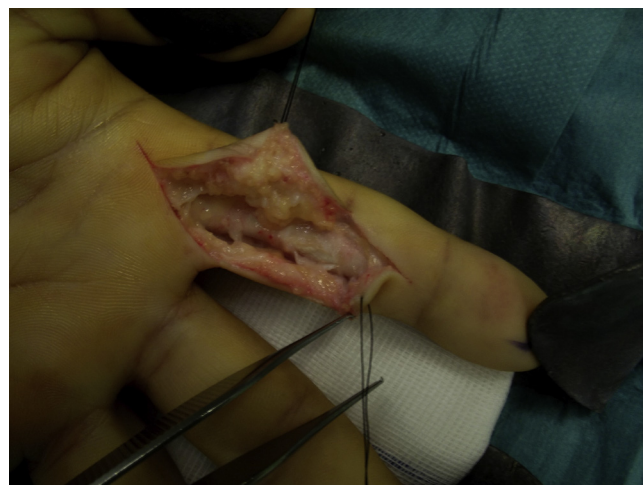

Fig. 4. The pulley system was left open on the ulnar side following the tendon tag excision.

injured digit. Between the ultrasound and the MRI, we opted for the latter one. The ultrasound imaging is operator dependent, and we felt that our radiology department had a much greater experience diagnosing musculoskeletal conditions with the use of MRI. Instead of a variation in the contour as described by Okano et al. [3], we were able to observe the fully lacerated tendon tag.

4. Conclusion

Triggering secondary to partial laceration of a flexor tendon is usually diagnosed clinically. In our view, the routine use of MRI to obtain a diagnosis is not justified; however, the MRI proved to be very useful in the setting of confounding factors, such as a previous surgery and a suspected history of infection.

Conflict of interest

None.

Funding

None.

Ethical approval

Case report, no ethical approval needed.

Consent

Informed consent was obtained from the patient.

Author contribution

All of the authors have contributed to the development of the case report.

Guarantor

Jose Couceiro.

References

- [1] M.A. Fujiwara, A case of trigger finger following partial laceration of flexor digitorum superficialis and review of the literature, *Arch. Orthop. Trauma Surg.* 125 (July (6)) (2005) 430–432, Epub 2005 April 30.
- [2] R. Haidar, B. Harfouche, M. Koudeih, Trigger finger after partial flexor tendon laceration: two case reports and review of the literature, *J. Hand Surg. Eur. Vol. 34* (October (5)) (2009) 690–691.
- [3] T. Okano, N. Hidaka, H. Nakamura, Partial laceration of the flexor tendon as an unusual cause of trigger finger, *J. Plast. Surg. Hand Surg.* 45 (September (4–5)) (2011) 248–251.
- [4] M. Tohyama, T. Tsujio, I. Yanagida, Trigger finger caused by an old partial flexor tendon laceration: a case report, *Hand Surg.* 10 (July (1)) (2005) 105–108.
- [5] M.V. Stevanovic, F. Sharpe, Acute infections of the hand, in: *In Green's Operative Hand Surgery*, Churchill Livingstone, 2005, pp. 57–92.

Open Access

This article is published Open Access at scimedirect.com. It is distributed under the [IJSCR Supplemental terms and conditions](#), which permits unrestricted non commercial use, distribution, and reproduction in any medium, provided the original authors and source are credited.