

[ CASE REPORT ]

## Osimertinib Treatment Was Unsuccessful for Lung Adenocarcinoma with G719S, S768I, and T790M Mutations

Shingo Nasu, Takayuki Shiroyama, Satomu Morita, So Takata, Hiromune Takada, Kentaro Masuhiro, Ayako Tanaka, Naoko Morishita, Hidekazu Suzuki, Norio Okamoto and Tomonori Hirashima

### Abstract:

Epidermal growth factor receptor (*EGFR*) T790M mutations are the most frequent mechanism of resistance to first- and second-generation tyrosine kinase inhibitors, and osimertinib is an effective treatment for patients with both *EGFR*-activating mutations and T790M resistance mutations. We describe the case of a 68-year-old woman with lung adenocarcinoma with G719S, S768I, and T790M mutations in which osimertinib treatment was unsuccessful. The patient died of disease progression one month after discontinuing osimertinib treatment. This case suggests that osimertinib may be ineffective for treating patients with uncommon mutations such as G719S when the patient has also acquired a T790M resistance mutation.

**Key words:** *EGFR* exon 18G719S, osimertinib, S768I, T790M, uncommon mutation

(Intern Med 57: 3643-3645, 2018)

(DOI: 10.2169/internalmedicine.0923-18)

### Introduction

*EGFR* T790M mutations are the most frequent mechanism of drug resistance to first- and second-generation tyrosine kinase inhibitors (EGFR-TKIs) (1). Osimertinib is a third-generation, irreversible EGFR-TKI that is selective for both sensitive *EGFR* and T790M resistance mutations. It has been shown to be significantly more effective than platinum therapy plus pemetrexed in patients with T790M-positive advanced non-small-cell lung cancer who show disease progression during first-line EGFR-TKI therapy (2). Thus, osimertinib is for EGFR-TKI-treated patients who have acquired *EGFR* T790M mutations (3).

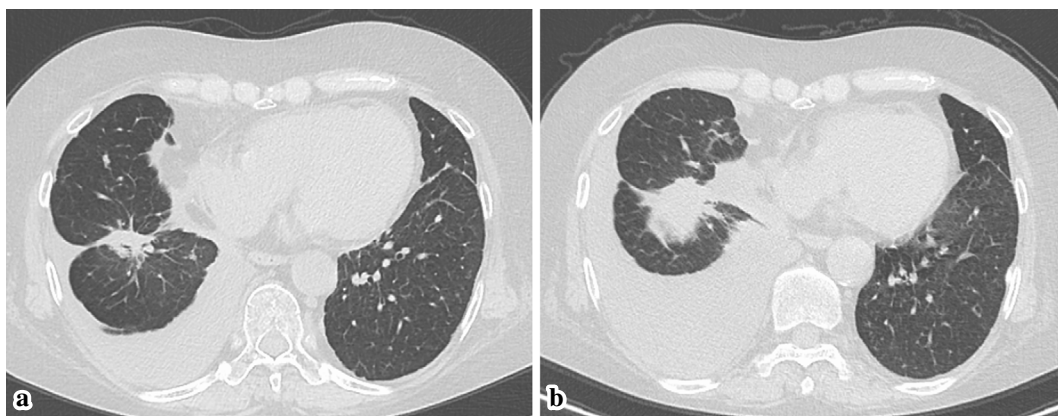
However, uncommon *EGFR* mutations - other than exon 19 or L858R constitute - account for 10% of *EGFR* mutation-positive cases, and the effect of osimertinib in cases involving uncommon mutations when the patient has also acquired a T790M resistance mutation is unknown due

to their rarity.

We experienced a case involving a patient with an *EGFR* exon 18G719S mutation as well as S768I and T790M mutations, for whom osimertinib treatment was ineffective.

### Case Report

A 68-year-old woman presented to our hospital 3 years previously with cough and dyspnea of 2 months and 1 month induration, respectively. She was a smoker (41 pack-years) and had been diagnosed with adenocarcinoma of the right lower lobe of the lung with ipsilateral hilar lymphadenopathy and bilateral intrapulmonary metastasis (cT2aN1M1a, stage IV). A histological examination of a biopsy specimen revealed adenocarcinoma, and the analysis of the *EGFR* mutation status indicated an *EGFR* exon 18G719S mutation. At the time of the diagnosis, afatinib was not available for clinical use in Japan; thus, the patient was treated with gefitinib for 3 months. The treatment was changed to erlotinib due to grade 3 adverse events (in-



**Figure.** Chest computed tomography (CT) of the patient (a) before and (b) after treatment with osimertinib. CT showed the progression of the primary lesion and pleural effusion after osimertinib treatment.

creased aspartate aminotransferase and alanine aminotransferase levels). After receiving erlotinib treatment for 20 months followed by carboplatin/pemetrexed treatment for 1 month, headache appeared. Leptomeningeal metastasis was diagnosed based on magnetic resonance imaging (MRI) and cerebrospinal fluid (CSF) tests. Adenocarcinoma was confirmed based on the analysis of the CSF. A molecular analysis of EGFR in the CSF sample only showed an exon 18G719S mutation. After 2 months of afatinib treatment, the patient's general condition and MRI findings improved. Although she was treated with afatinib for 9 months, computed tomography (CT) showed worsening left-sided pleural effusion.

To evaluate the mechanisms of resistance, bronchoscopic re-biopsy of the primary lesion was performed using the cobas<sup>®</sup> EGFR Mutation Test v2 (Roche Molecular Systems, Pleasanton, USA). The results showed the emergence of an EGFR T790M+S768I mutation in addition to the original mutation. Thus, treatment with osimertinib (80 mg once daily) was initiated. After 1 month of osimertinib treatment, the patient was fatigued and anorexic. CT showed the progression of the primary lesion and pleural effusion (Figure), and MRI of the brain revealed the emergence of brain metastasis and ventricular enlargement. She was found to have disease progression and osimertinib treatment was discontinued. The patient died due to disease progression at one month after the discontinuation of osimertinib.

## Discussion

We herein report the first case of a patient with an EGFR exon 18G719S mutation and S768I and T790M resistance mutations who did not exhibit a durable response to osimertinib in clinical practice. G719X mutations are detected in 3.1% of EGFR mutations. S768I accounts for 1.1% of cases and can occur with G719X mutations (4). At the time of the initial diagnosis and disease progression after carboplatin/pemetrexed treatment, only the G719S mutation was detected. Thus, the patient acquired the additional EGFR mutations

(T790M and S768I) during afatinib treatment. In the AURA extension and AURA2 trials, it was not specified whether only G719S was detected at the initial diagnosis; however, three patients had G719X, S768I and T790M mutations. There are no previous case reports of triple-mutant G719S+S768I+T790M cancer. Regarding treatment, the clinical effects of uncommon EGFR mutations on the efficacy of EGFR TKIs are heterogeneous; however, NSCLC patients with classical EGFR mutations (such as exon 19 or L858R) have been reported to exhibit good responses to EGFR-TKIs (5). Lung cancers harboring the G719X or S768I mutations appeared to have lower sensitivity to third-generation TKIs than to second-generation TKIs *in vitro* (6). In a clinical trial, afatinib was more effective for cases with uncommon mutations, especially G719X, L861Q, and S768I mutations (7). However, patients with uncommon mutations were excluded from the FLAURA trial, a clinical trial of osimertinib for untreated EGFR-mutated NSCLC (8).

In the AURA extension and AURA2 trials, there were 13 patients (1.9%) with rare EGFR mutations and T790M mutations. Three of the 13 patients had G719X, S768I, and T790M mutations. Among these 3 patients, partial responses were confirmed in 1 patient, and 2 patients had a best objective response of stable disease when treated with osimertinib (9).

The response of our patient was different from that of the patients in the clinical trials. The difference in the response might be due to the G719X mutation; among G719X mutations, G719C and G719S mutations were reportedly associated with lower levels of autophosphorylation in comparison to G719A mutations (10). However, the reason remains unclear because the details of the G719X mutations in these two studies are not available. Recently, the coexistence of different resistance mechanisms, such as SCLC transformation has been reported, and a combination of additional resistance mechanisms might have influenced our case (11). As the preclinical and clinical data are insufficient, further studies are necessary to evaluate the effects of osimertinib on uncommon mutations with T790M mutations.

In conclusion, we encountered a patient with an *EGFR* exon 18G719S mutation who had also acquired the S768I and T790M resistance mutations, and osimertinib was not an effective treatment.

**The authors state that they have no Conflict of Interest (COI).**

## References

1. Yu HA, Arcila ME, Rekhtman N, et al. Analysis of tumor specimens at the time of acquired resistance to EGFR TKI therapy in 155 patients with *EGFR*-mutant lung cancers. *Clin Cancer Res* **19**: 2240-2247, 2013.
2. Mok TS, Wu Y-L, Ahn M-J, et al. Osimertinib or platinum-pemetrexed in *EGFR* T790M-positive lung cancer. *N Engl J Med* **376**: 629-640, 2017.
3. Novello S, Barlesi F, Califano R, et al. Metastatic non-small-cell lung cancer: ESMO Clinical Practice Guidelines for diagnosis, treatment and follow-up. *Ann Oncol* **27** (Suppl): v1-v27, 2016.
4. Kobayashi Y, Mitsudomi T. Not all epidermal growth factor receptor mutations in lung cancer are created equal: perspectives for individualized treatment strategy. *Cancer Sci* **107**: 1179-1186, 2016.
5. Wu JY, Yu CJ, Chang YC, Yang CH, Shih JY, Yang PC. Effectiveness of tyrosine kinase inhibitors on "uncommon" epidermal growth factor receptor mutations of unknown clinical significance in non-small cell lung cancer. *Clin Cancer Res* **17**: 3812-3821, 2011.
6. Kobayashi Y, Togashi Y, Yatabe Y, et al. *EGFR* exon 18 mutations in lung cancer: molecular predictors of augmented sensitivity to afatinib or neratinib as compared with first- or third-generation TKIs. *Clin Cancer Res* **21**: 5305-5313, 2015.
7. Yang JC, Sequist LV, Geater SL, et al. Clinical activity of afatinib in patients with advanced non-small-cell lung cancer harbouring uncommon *EGFR* mutations: a combined post-hoc analysis of LUX-Lung 2, LUX-Lung 3, and LUX-Lung 6. *Lancet Oncol* **16**: 830-838, 2015.
8. Soria J-C, Ohe Y, Vansteenkiste J, et al. Osimertinib in untreated *EGFR*-mutated advanced non-small-cell lung cancer. *N Engl J Med* **378**: 113-125, 2018.
9. Jenkins S, Chih-Hsin Yang J, Jänne PA, et al. *EGFR* mutation analysis for prospective patient selection in two phase II registration studies of osimertinib. *J Thorac Oncol* **12**: 1247-1256, 2017.
10. Furuyama K, Harada T, Iwama E, et al. Sensitivity and kinase activity of epidermal growth factor receptor (*EGFR*) exon 19 and others to *EGFR*-tyrosine kinase inhibitors. *Cancer Sci* **104**: 584-589, 2013.
11. Minari R, Bordi P, Del Re M, et al. Primary resistance to osimertinib due to SCLC transformation: issue of T790M determination on liquid re-biopsy. *Lung Cancer* **115**: 21-27, 2018.

The Internal Medicine is an Open Access journal distributed under the Creative Commons Attribution-NonCommercial-NoDerivatives 4.0 International License. To view the details of this license, please visit (<https://creativecommons.org/licenses/by-nc-nd/4.0/>).