

Original paper

Computed tomography urography with iterative reconstruction algorithm in congenital urinary tract abnormalities in children – association of radiation dose with image quality

Przemysław Bombiński^{1A,B,C,D,E,F}, Michał Brzewski^{1A,E}, Stanisław Warchoł^{2B}, Agnieszka Biejat^{1B},
Marcin Banasiuk^{3C}, Marek Gołębiowski^{4A,E}

¹Department of Paediatric Radiology, Medical University of Warsaw, Poland

²Department of Paediatric Surgery and Urology, Medical University of Warsaw, Poland

³Department of Paediatric Gastroenterology and Nutrition, Medical University of Warsaw, Poland

⁴^{1st} Department of Clinical Radiology, Medical University of Warsaw, Poland

Abstract

Purpose: To assess the extent to which a radiation dose can be lowered without compromising image quality and diagnostic confidence in congenital urinary tract abnormalities in children by using a CT scanner with an iterative reconstruction algorithm.

Material and methods: 120 CT urography image series were analysed retrospectively. Image series were divided into four study groups depending on effective radiation dose (group 1: 0.8–2 mSv; group 2: 2–4 mSv; group 3: 4–6 mSv; group 4: 6–11 mSv). Objective and subjective image quality were investigated. In objective analysis, measurements of attenuation and standard deviation (SD) in five regions of interest (ROIs) were performed in 109 excretory image series, and image noise was evaluated. In subjective analysis, two independent radiologists evaluated 138 kidney units for subjective image quality and diagnostic confidence.

Results: There were no significant differences in image noise in objective evaluation between the following study groups: 2 vs. 3 and 3 vs. 4 in all ROIs (with the only exception in spleen SD measurement between study groups 2 vs. 3), while there was significantly more image noise in group 2 in comparison to group 4. For all other ROIs in all study groups, there was more image noise on lower dose images. There were no significant differences in pairwise comparisons between study groups in subjective image quality. Diagnostic confidence was not significantly different between all study groups.

Conclusions: Low-dose CT urography can be a valuable method in congenital urinary tract abnormalities in children. Despite poorer image quality, diagnostic confidence is not significantly compromised in examinations performed with lower radiation doses.

Key words: radiation dosage, congenital anomalies of kidney and urinary tract (CAKUT), children, diagnostic techniques – urological, multidetector computed tomography, radiology.

Correspondence address:

Przemysław Bombiński, MD, Department of Paediatric Radiology, Medical University of Warsaw, 63A Żwirki i Wigury St., 02-091 Warsaw, Poland,
e-mail: przebom@op.pl

Authors' contribution:

A Study design · B Data collection · C Statistical analysis · D Data interpretation · E Manuscript preparation · F Literature search · G Funds collection

Introduction

Intravenous urography (IVU) has been displaced by other modalities in diagnostic imaging in children and can only be performed in cases of restricted access to computed tomography urography (CTU) or magnetic resonance urography (MRU) [1]. MRU has become a method of choice in the diagnosis of congenital anomalies of kidneys and urinary tracts (CAKUT) in children [1-3]; however, there is a role for CTU in case MRU is not available [1,3,4].

High radiation doses in CT examinations are a major concern, especially in children. Several techniques to reduce the radiation dose, according to the ALARA (As Low As Reasonably Achievable) principle, have been proposed [5-11]. This will include the following: limitation of study phases and scan region; reduction of acquisition parameters (kV and mAs settings); and using dose-reduction techniques, such as automatic tube current modulation or implementation of split-bolus protocols and iterative reconstruction techniques. However, dose reduction may be at the cost of decreased image quality.

According to the guidelines of the European Society of Paediatric Radiology (ESPR) and European Society of Urogenital Radiology (ESUR), a reference value of effective dose for paediatric CTU examinations should be kept at a level of around 2 mSv, with a maximum of 6 mSv [1,12]. In adults, the maximum value is higher – approximately 10 mSv.

According to the same guidelines, indications for CTU in children include trauma, urolithiasis, vascular disease, tumours, and complicated infections [1]. There may be a role for CTU in CAKUT in children. The advantages of CTU over MRU include shorter time of examination, no need or much shorter time of sedation [3,13] and easier access to CT scanners in some regions.

The purpose of this study was to investigate if lower-dose CTU scans have as good image quality and diagnostic confidence as the higher dose in the diagnosis of CAKUT in children.

Material and methods

Study design

This is a single-institution, retrospective cohort study comparing the image quality and diagnostic confidence between four decreasing levels of radiation dosage in CTU examinations performed due to suspected CAKUT in children. CTUs were performed between 2011 and 2016 in selected patients as a successive imaging examination (following ultrasonography and dynamic or static renal scintigraphy, which were performed in all analysed patients, and voiding cystourethrography in selected patients). There was no access to MRU. CTU was the only option to precisely assess the anatomy of the urinary tracts if there was no correlation between the results of men-

tioned imaging modalities and/or due to planned surgical treatment (i.e. qualification to surgical repair, suspected complications or follow-up during treatment). In most cases, indications for CTUs were determined in collaboration with a urologist, a nephrologist, and a radiologist.

Our study was accepted by the institutional Ethics Review Board.

CTU protocol

CTUs were performed with the same 64-MDCT scanner (Brilliance CT 64, Philips Healthcare, Best, Netherlands). The standard CTU protocol included acquisition made from the diaphragm or the top of the kidney to the symphysis pubis. Delayed phases were performed 10-45 min after intravenous (IV) administration of contrast material (CM) (92% of studies – between 15 and 30 min) with use of Iomeron 300 (iomeprol) in a standard dose of 1 ml/kg of body weight.

The CT scanner had an iterative reconstruction algorithm (iDose4), and the fourth reconstruction level was implemented in all analysed examinations [14]. Scanning parameters (including tube voltage kV and tube current mAs) were different, depending on the standard department's CT protocols adequate to patients' weight. Automatic tube current modulation was a standard; however, in some cases kV and mAs settings that were lower than standard were kept constant to obtain greater dose reduction.

Image evaluation was performed on a diagnostic workstation (IntelliSpace Portal, Philips, Netherlands). Only CTUs with single excretory image series were evaluated. Split-bolus technique was not a subject of investigation, and these image series were not included in the analysis.

Radiation exposure assessment

All results were analysed depending on the effective radiation dose. Volume CT dose index (CTDI) and dose length product (DLP) were recorded from the study dose summary, and the effective radiation dose (E) was calculated according to Thomas *et al.* [15] – DLP was multiplied by a conversion coefficient for the abdomen/pelvis region. Image series were divided into four study groups depending on the effective radiation dose (group 1: 0.8-2 mSv; group 2: 2-4 mSv; group 3: 4-6 mSv; group 4: 6-11 mSv). Objective and subjective image quality was evaluated between study groups.

Objective image analysis

Attenuation in Hounsfield units and the standard deviation (SD) in five standardised 1 cm² regions of interest (ROIs) in similar anatomic locations were recorded [16-24] (Ao, upper part of spleen, upper peripheral part of right hepatic lobe, left iliopsoas muscle at L5 level, and background noise measurements made in air in front of the

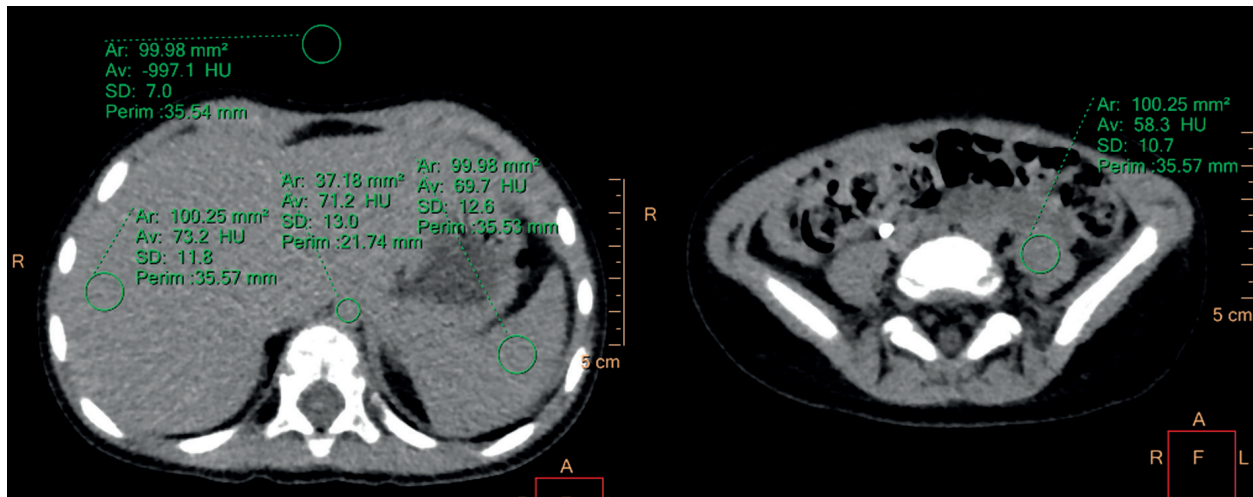


Figure 1. Measurement of attenuation in Hounsfield units and the standard deviation in five standardized ROIs (aorta, spleen, right hepatic lobe, left iliopsoas muscle at L5 level, air in front of the patient) in objective image analysis

patient) (Figure 1). If the anatomical structure was smaller than 1 cm², the ROI area was adapted to this structure. The mean of three consecutive measurements for every ROI was analysed.

Image noise and signal-to-noise ratio (SNR) were evaluated. Increased mean value of the SD in the ROIs was assessed as noise, reducing image quality. The SNR was calculated according to the following formula:

$$\text{SNR} = \text{HU}_0 / \text{SD}_0$$

where *HU*₀ is the mean attenuation and *SD*₀ is the mean SD in a specific ROI.

Subjective image analysis

Criteria for subjective image analysis were based on previously reported abdominal CT studies [16-24]. Subjective image quality and diagnostic confidence were evaluated. Subjective image quality was defined as the presence of image noise and beam-hardening streak artefacts and was rated on a five-point scale (1 – unacceptable quality, non-diagnostic; 2 – poor quality, affecting the interpretation; 3 – moderate quality, not affecting the interpretation; 4 – good; 5 – excellent). Diagnostic confidence was defined as reader confidence in visualisation of anatomical structures (calyces, pelvis, megaureter) and was evaluated on a five-point scale (1 – unacceptable, non-diagnostic; 2 – poor, affecting the interpretation; 3 – acceptable, diagnostic; 4 – good; 5 – excellent). For both scales, grades 1 and 2 were deemed non-diagnostic in clinical practice. The evaluation of all collecting systems was performed independently by two radiologists (P.B and A.B., with 7 years and 17 years of experience in paediatric CT, respectively), who were blinded to the group information. All discrepancies were discussed, and consensus was achieved [16,17].

The left and right kidneys were evaluated separately. In the case of collecting system duplication (suspected on ultrasonography or scintigraphy and confirmed in CTU), both systems were also evaluated separately.

In all cases the grade of hydronephrosis was assessed in ultrasonography according to the grading system described in the ESPR guidelines [25] and was compared between the study groups.

CTU examinations performed with use of diuretic (furosemide), and all kidneys with impaired renal function (i.e. < 40% of split renal function at DMSA scintigraphy) were excluded from this analysis.

Statistical analysis

Continuous variables were tested by the Shapiro-Wilk test for normality. Data were expressed as median and interquartile range (IQR). The Kruskal-Wallis test was used to test differences between groups and Dunn's test for pairwise comparisons. Statistical analysis was performed using Statistica 12 (Tulsa, USA). For all studies, a *p*-value of < 0.05 was defined as statistically significant.

Results

Patient population

A total of 233 urinary tract examinations were assessed for eligibility. Fifty-seven were excluded due to not matching indication (i.e. evaluation of urinary tract injury, renal cysts, or tumours), and 56 due to use of split-bolus protocol. A total of 120 image series were included for the final analysis. There were 44 girls and 76 boys, median age 1.85 years, IQR 0.5-6.0 years, range 1 month – 17 years (Table 1). There was no significant difference in terms of age (*p* = 0.08) between study groups. Indications for 120 CTUs are presented in Table 1.

Objective image evaluation

From the number of 120 image series, seven were excluded because the scan range did not include all analysed

Table 1. Characteristics of patients in four study groups. Data shown as median (IQR)

	Group 1 (0.8-2 mSv) <i>n</i> = 34	Group 2 (2-4 mSv) <i>n</i> = 42	Group 3 (4-6 mSv) <i>n</i> = 21	Group 4 (6-11 mSv) <i>n</i> = 23	<i>p</i>
Sex (M : F)	23 : 11	27 : 15	14 : 7	12 : 11	0.66
Age (years)	5.3 (0.7-8.5)	1.4 (0.5-3.3)	2.3 (0.5-5.2)	2.0 (0.4-4.6)	0.08
Age (range)	0.2-13.9	0.2-15.1	0.2-10.7	0.1-17.0	
Indications					
Hydronephrosis, <i>n</i> = 53 (44%)	15	18	13	7	
Megaureter, <i>n</i> = 26 (22.5%)	8	8	4	6	
Upper urinary tract duplication, <i>n</i> = 23 (19%)	5	9	3	6	
Post-operative follow-up (assessment of outcomes and/or diagnostics of complications), <i>n</i> = 12 (10%)	4	4	1	3	
Abnormalities of kidney structure, shape, and location, <i>n</i> = 4 (3%)	1	2	–	1	
Ureterocele, <i>n</i> = 2 (1.5%)	1	1	–	–	

ROIs, and four were excluded due to severe motion artefacts. The final analysis included 109 CTUs.

SD and SNR values were compared between all study groups (Figure 2). There were no significant differences in SD and SNR values between the following study groups: 2 vs. 3 and 3 vs. 4 in all ROIs (with the only exception in spleen SD measurement between study groups 2 vs. 3; $p = 0.038$). However, there were significant differences between groups 2 and 4 in all ROIs (significantly higher SD and lower SNR values in group 2).

For all other ROIs in all study groups, there was more image noise (significantly higher SD and lower SNR values) on lower-dose images.

Subjective image evaluation

From 120 image series, 35 were excluded due to use of diuretic (furosemide) and four due to severe motion artefacts. In the remaining 77 image series, 165 kidney units were evaluated – 27 of them were assessed as having impaired renal function (< 40% at DSMA) and excluded. The remaining 138 kidney units were included for the final analysis.

There was no significant difference in terms of age ($p = 0.35$) and grade of hydronephrosis ($p = 0.7$) between kidney units in all study groups.

There were 28 kidneys with low-grade HN (grade 1 or 2) and 35 kidneys with high-grade HN (grade 3-5).

There were no significant differences in pairwise comparisons in subjective image quality between the study groups. None of the kidney units was rated as grade 1 or 2, thus all were deemed diagnostic in clinical practice.

Median diagnostic confidence score was 5 (IQR: 5-5) in all study groups (Table 2), making the diagnostic confidence not significantly different between all study groups ($p = 0.22$).

Discussion

We have shown that in comparison to higher-dose CTUs, lower-dose CTUs have poorer image quality, but similar capability to visualise anatomical structures of collecting systems in children with suspected CAKUT (Figure 3).

We have noticed a significant difference in objective image noise between study groups 2 vs. 4; however, image noise was similar in groups 2 vs. 3 (the only exception was a significant difference in spleen SD measurement) and 3 vs. 4. For all other comparisons between study groups, there was more image noise on lower-dose images. However, our analysis of subjective image quality and diagnostic confidence did not reveal significant differences between the study groups.

The development of new CT techniques in the last few years, such as improved spatial resolution, shorter scan times, volumetric scanning, and implementation of iterative reconstruction techniques [3-14,16-24,26-28], allowed for significant reduction in radiation dose. The currently accepted maximum dose level for CTUs in children is 6 mSv [12]; however, this level was determined based on the data available in the literature prior to 2009, i.e. just before the implementation of iterative algorithms in clinical use. Advances in iterative algorithms have already been described in many publications and allow a significant reduction in radiation dose without affecting image quality [7,9,10,14,18-21,23,28]. In the case of abdominal CT in children, the dose reduction is up to 32-75% [7,23,29]. Our analysis was performed with the use of a CT scanner with implemented iterative reconstruction technique (iDose4). Given our results, we suggest reducing the cut-off dose for CTUs in children to the level of 2 mSv because this will not affect subjective image quality and diagnostic confidence in comparison to higher-dose CTUs.

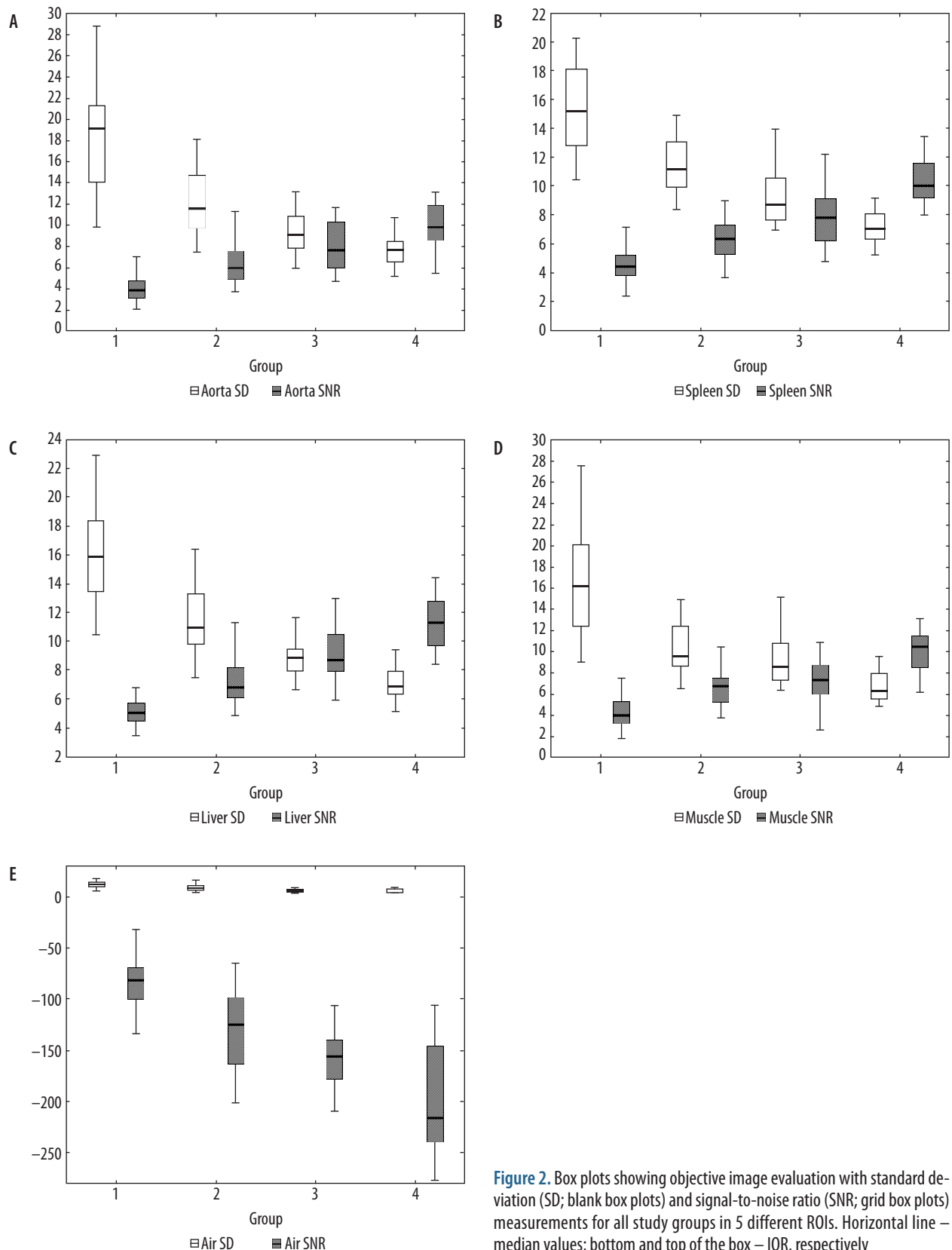


Figure 2. Box plots showing objective image evaluation with standard deviation (SD; blank box plots) and signal-to-noise ratio (SNR; grid box plots) measurements for all study groups in 5 different ROIs. Horizontal line – median values; bottom and top of the box – IQR, respectively

In our study, objective image evaluation was performed according to previously reported abdominal CT studies [16-24]. However, ROIs were placed in locations not adjacent to collecting systems. This was performed to make our analysis independent of unwanted CM in-

fluence. It has been reported that excreted CM can create beam hardening – streak artefact, limiting evaluation of adjacent structures [30,31]. Also, non-uniform opacification as well as layering effect of CM in the collecting system could affect measurements of HU and SD, making

Table 2. Subjective image evaluation – characteristics of kidney units and scores for subjective image quality and diagnostic confidence evaluated on a 5-point scale. Data shown as median (IQR)

	Group 1 (0.8-2 mSv)	Group 2 (2-4 mSv)	Group 3 (4-6 mSv)	Group 4 (6-11 mSv)
No. of kidney units, $n = 138$	30	52	22	34
Age of patients* (years)	4.9 (0.5-7.8)	0.8 (0.5-6.0)	1.9 (0.5-4.2)	1.1 (0.8-3.6)
HN				
Low grade	7	12	4	5
High grade	7	14	7	7
Subjective image quality	3 (3-4)	4 (3-4)	4 (3-5)	3 (3-4)
Diagnostic confidence	5 (5-5)	5 (5-5)	5 (5-5)	5 (5-5)

*Age of patients was evaluated separately for each kidney unit.

objective image noise assessment unreliable. These parameters, however, were taken into consideration in subjective image quality evaluation.

There are several parameters providing information about radiation dose from CT examinations, such as CTDIvol, DLP, SSDE [32], and effective dose (E), which was found to be the most reliable for dose measurement [12,33]. There are normalised region-specific coefficients, which are different for adult and paediatric patients [15,34]

and can be used to calculate the effective dose from DLP. Additionally, this parameter allows us to compare different imaging modalities, i.e. X-ray examinations, CT, or scintigraphy [35]. We have decided to calculate an effective radiation dose according to Thomas *et al.* [15] because this method was also used to establish a reference value of effective dose for paediatric CTU examinations [12]. In recent publications there has been an increasing role of SSDE because this parameter considers the real size of the patient [3 2].

Only kidneys with preserved renal function ($\geq 40\%$ at DSMA) were evaluated in our study. This is a substantial limitation in comparison to MRU, which may be utilised in patients with impaired renal function [36]. However, exclusion of non-functioning kidneys allowed us to analyse a statistically uniform group of kidney units. Also, use of furosemide was an exclusion criterion because diuretics have an impact on CM distribution throughout the urinary tract [37].

In our study four image series were excluded from the final analysis due to severe motion artefacts. Although this affects image quality, but is an independent factor not connected to the study protocol and radiation dose.

There were limitations to our study. First, scanning parameters were different between patients and CT protocols and were not compared directly. We compared the final dose, which was evaluated on the basis of the study dose summary provided by the scanner. In children, contrary to most CT protocols in adults, scanning parameter settings must be suited to the patients' size. CTUs were

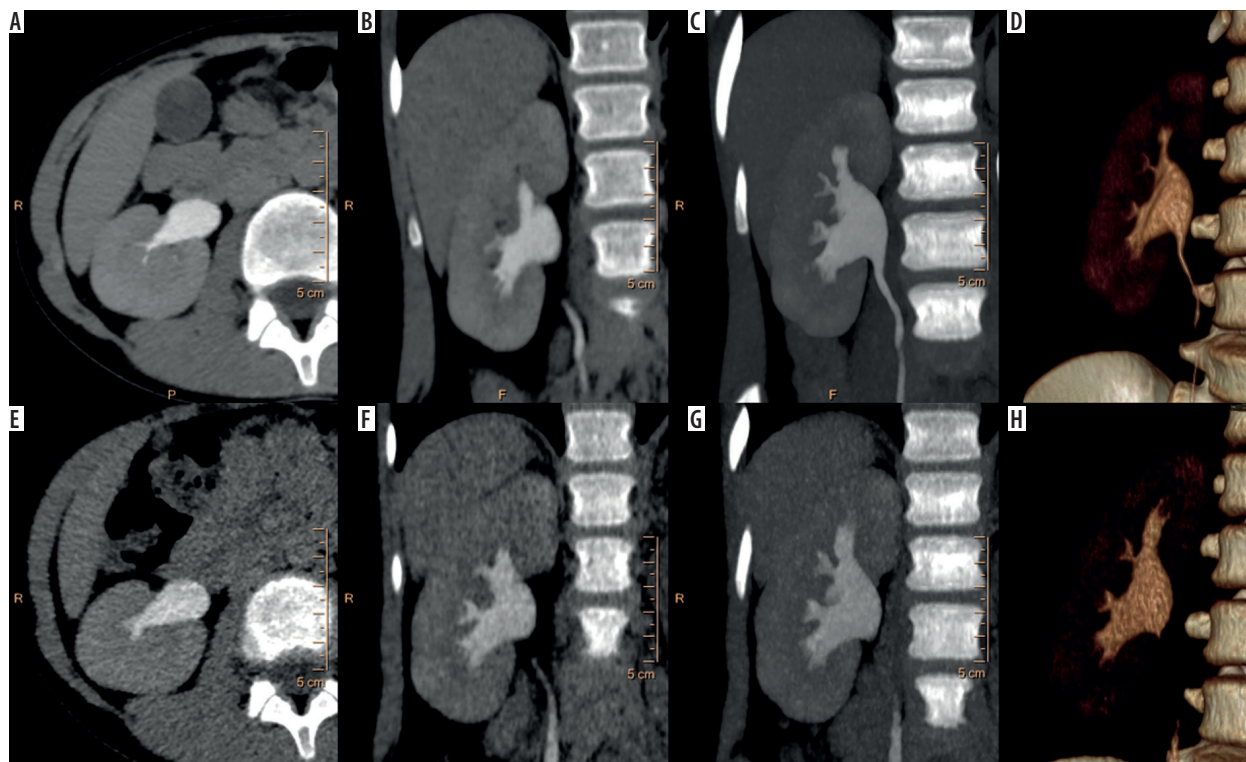


Figure 3. A-D) Higher-dose CTU (100 kV, 150 mAs, $E = 6.5$ mSv) performed in a 10-year-old girl with suspected CAKUT. E-H) – Follow-up study performed 6 months later with lower-dose protocol (80 kV, 40 mAs, $E = 0.9$ mSv), with more prominent image noise, but non-diminished diagnostic confidence

performed with our standard CT protocols depending on the weight of the patient. However, with increasing experience, lower scanning parameters were implemented into standard protocols to obtain greater dose reduction. Modern CT scanners display expected CTDI and DLP values before scanning and allow for correction of the settings to obtain lower effective dose. Second, distention of the urinary tract was not evaluated, except for a comparison between study groups in terms of degree of hydronephrosis - a significant difference in the number of hydronephrotic kidney units could have an impact on subjective image evaluation. Third, it was not obligatory to visualise all segments of the normal, non-distended ureters. Contrary to CTUs in children, CTUs in adults are performed

to visualise urothelial cancers, and appropriate distention of the ureters is mandatory [37].

Conclusions

Higher image noise of lower-dose CTUs does not affect their diagnostic confidence in diagnosis of suspected CAKUT in children. We suggest reducing the cut-off dose for CTUs in children performed with iterative reconstruction algorithms to the level of 2 mSv.

Conflict of interest

The authors report no conflict of interest.

References

- Riccabona M, Avni FE, Dacher JN, et al. ESPR uro-radiology task force and ESUR paediatric working group: imaging and procedural recommendations in paediatric uro-radiology, part III. Minutes of the ESPR uro-radiology task force minisymposium on intravenous urography, uro-CT and MR-urography in childhood. *Pediatr Radiol* 2010; 40: 1315-1320.
- Battal B, Kocaoglu M, Akgun V, et al. Split-bolus MR urography: synchronous visualization of obstructing vessels and collecting system in children. *Diagn Interv Radiol* 2015; 21: 498-502.
- Darge K, Higgins M, Hwang TJ, et al. Magnetic resonance and computed tomography in pediatric urology: an imaging overview for current and future daily practice. *Radiol Clin North Am* 2013; 51: 583-598.
- Bombiński P, Warchoła S, Brzewski M, et al. Lower-dose CT urography (CTU) with iterative reconstruction technique in children – initial experience and examination protocol. *Pol J Radiol* 2014; 8: 137-144.
- Strauss KJ, Goske MJ, Kaste SC, et al. Image gently: ten steps you can take to optimize image quality and lower CT dose for paediatric patients. *AJR Am J Roentgenol* 2010; 194: 868-873.
- Nivelstein RAJ, van Dam IM, van der Molen AJ. Multidetector CT in children: current concepts and dose reduction strategies. *Pediatric Radiology* 2010; 40: 1324-1344.
- Aurumskjöld ML, Söderberg M, Stålhammar F, et al. Evaluation of an iterative model-based reconstruction of pediatric abdominal CT with regard to image quality and radiation dose. *Acta Radiol* 2017 Jan 1: 284185117728415.
- Jin M, Sanchez TR, Lamba R, et al. Accuracy and Radiation Dose Reduction of Limited-Range CT in the Evaluation of Acute Appendicitis in Pediatric Patients. *Am J Roentgenol* 2017; 209: 643-647.
- Imai R, Miyazaki O, Horiuchi T, et al. Ultra-Low-Dose Fetal CT With Model-Based Iterative Reconstruction: A Prospective Pilot Study. *AJR Am J Roentgenol* 2017; 208: 1365-1372.
- Sun J, Yu T, Liu J, et al. Image quality improvement using model-based iterative reconstruction in low dose chest CT for children with necrotizing pneumonia. *BMC Med Imaging* 2017; 17: 24.
- Chen XF, Jiang F, Li L, et al. Application of low-dose dual-source computed tomography angiography in children with complex congenital heart disease. *Exp Ther Med* 2017; 14: 1177-1183.
- Damasio MB, Darge K, Riccabona M. Multi-detector CT in the paediatric urinary tract. *Eur J Radiol* 2013; 82: 1118-1125.
- Chung EM, Soderlund KA, Fagen KE. Imaging of the Pediatric Urinary System. *Radiol Clin North Am* 2017; 55: 337-357.
- Arapakis I, Efstathopoulos E, Tsitsia V, et al. Using “iDose4” iterative reconstruction algorithm in adults’ chest-abdomen-pelvis CT examinations: effect on image quality in relation to patient radiation exposure. *Br J Radiol* 2014; 87: 20130613.
- Thomas KE, Wang B. Age-specific effective doses for paediatric MSCT examinations at a large children’s hospital using DLP conversion coefficients: a simple estimation method. *Pediatr Radiol* 2008; 38: 645-656.
- Dahlman P, van der Molen AJ, Magnusson M, et al. How much dose can be saved in three-phase CT urography? A combination of normal-dose corticomedullary phase with low-dose unenhanced and excretory phases. *AJR Am J Roentgenol* 2012; 199: 852-860.
- Quaia E. Comparison between 80 kV, 100 kV and 120 kV CT protocols in the assessment of the therapeutic outcome in HCC. *Liver Pancreat Sci* 2016; DOI: 10.15761/LPS.1000101.
- van der Molen AJ, Miclea RL, Geleijns J, et al. A Survey of Radiation Doses in CT Urography Before and After Implementation of Iterative Reconstruction. *AJR Am J Roentgenol* 2015; 205: 572-577.
- Zhou Z, Chen H, Wei W, et al. Low kilovoltage peak (kVp) with an adaptive statistical iterative reconstruction algorithm in computed tomography urography: evaluation of image quality and radiation dose. *Am J Trans Res* 2016; 8: 3883-3892.
- Gervaise A, Osemont B, Louis M, et al. Standard dose versus low-dose abdominal and pelvic CT: comparison between filtered back projection versus adaptive iterative dose reduction 3D. *Diagn Interv Imaging* 2014; 95: 47-53.
- Buls N, Van Gompel G, Van Cauteren T, et al. Contrast agent and radiation dose reduction in abdominal CT by a combination of low tube voltage and advanced image reconstruction algorithms. *Eur Radiol* 2015; 25: 1023-1031.
- Guimarães LS, Fletcher JG, Harmsen WS, et al. Appropriate patient selection at abdominal dual-energy CT using 80 kV: relationship

- between patient size, image noise, and image quality. *Radiology* 2010; 257: 732-742.
23. Berlin SC, Weinert DM, Vasavada PS, et al. Successful dose reduction using reduced tube voltage with hybrid iterative reconstruction in pediatric abdominal CT. *Am J Roentgenol* 2015; 205: 392-399.
 24. Lee S, Jung SE, Rha SE, et al. Reducing radiation in CT urography for hematuria: Effect of using 100 kilovoltage protocol. *Eur J Radiol* 2012; 81: e830-834.
 25. Riccabona M, Avni FE, Blickman JG, et al. Imaging recommendations in paediatric urology: minutes of the ESPR workgroup session on urinary tract infection, fetal hydronephrosis, urinary tract ultrasonography and voiding cystourethrography, Barcelona, Spain, June 2007. *Pediatr Radiol* 2008; 38: 138.
 26. Johnston JH, Podberesky DJ, Yoshizumi TT, et al. Comparison of radiation dose estimates, image noise, and scan duration in pediatric body imaging for volumetric and helical modes on 320-detector CT and helical mode on 64-detector CT. *Pediatr Radiol* 2013; 43: 1117-1127.
 27. Pelc NJ. Recent and future directions in CT imaging. *Ann Biomed Eng* 2014; 42: 260-268.
 28. Silva AC, Lawder HJ, Hara A, et al. Innovations in CT dose reduction strategy: application of the adaptive statistical iterative reconstruction algorithm. *AJR* 2010; 194: 191-199.
 29. Khawaja RD, Singh S, Otrakji A, et al. Dose reduction in pediatric abdominal CT: use of iterative reconstruction techniques across different CT platforms. *Pediatr Radiol* 2015; 45: 1046-1055.
 30. Jung SC, Kim SH, Cho JY. A comparison of the use of contrast media with different iodine concentrations for multidetector CT of the kidney. *Korean J Radiol* 2011; 12: 714-721.
 31. Sussman SK, Illescas FE, Opalacz JP, et al. Renal streak artifact during contrast enhanced CT: comparison of high versus low osmolality contrast media. *Abdom Imaging* 1993; 18: 180-185.
 32. Imai R, Miyazaki O, Horiuchi T, et al. Local diagnostic reference level based on size-specific dose estimates: assessment of pediatric abdominal/pelvic computed tomography at a Japanese national children's hospital. *Pediatr Radiol* 2015; 45: 345-353.
 33. ICRP 2007. The 2007 Recommendations of the International Commission on Radiological Protection. ICRP Publication 103. *Ann ICRP* 2007; 37 (2-4).
 34. Shrimpton PC. Assessment of patient dose in CT. NRPBPE/1/2004. NRPB, Chilton 2004.
 35. Hamza Y, Sulieman A, Abuderman A, et al. Evaluation of patient effective doses in CT urography, intravenous urography and renal scintigraphy. *Radiat Prot Dosimetry* 2015; 165: 452-456.
 36. Cerwinka WH, Damien Grattan-Smith J, Kirsch AJ. Magnetic resonance urography in pediatric urology. *J Pediatr Urol* 2008; 4: 74-82.
 37. Silverman S, Leyendecker J, Amis E. What is the current role of CT urography and MR urography in the evaluation of the urinary tract? *Radiology* 2009; 250: 309.