

ORIGINAL ARTICLE

Initial experience of single port laparoscopic totally extraperitoneal hernia repair: nearly-scarless inguinal hernia repair

Ji Hoon Kim, Seung Man Park, Jin Jo Kim, Yoon Suk Lee

Department of Surgery, Incheon St. Mary's Hospital, The Catholic University of Korea School of Medicine, Incheon, Korea

Purpose: In the early 1990's laparoscopic hernioplasty gained popularity worldwide. Thereafter, laparoscopic surgeons have attempted to improve cosmesis using single port surgery. This study aims to introduce and assess the safety and feasibility of single port laparoscopic total extraperitoneal (TEP) hernia repair with a nearly-scarless umbilical incision. **Methods:** Sixty three single port laparoscopic TEP hernia repairs were performed in sixty patients from June 2010 to March 2011 at Incheon St. Mary's Hospital, with the use of a glove single-port device and standard laparoscopic instruments. Demographic and clinical data, intraoperative findings, and postoperative course were reviewed. **Results:** Of the 63 hernias treated, 31 were right inguinal hernias, 26 were left inguinal hernias and 3 were both inguinal hernias. There was one conversion to conventional three port laparoscopic transabdominal preperitoneal hernioplasty. Mean operative time was 62 minutes (range, 32 to 150 minutes). There were no intraoperative complications. Postoperative complications occurred in two cases (wound seroma and urinary retention) and were successfully treated conservatively. Mean hospital stay was 2.15 days. **Conclusion:** Single port laparoscopic TEP hernia repair is safe and feasible. Umbilical incision provides an excellent cosmetic outcome. Prospective randomized studies comparing single port and conventional three port laparoscopic TEP repairs with short-term outcome and long-term recurrence rate are needed for confirmation.

Key Words: Single port, SILS, LESS, TEP, Inguinal hernia

INTRODUCTION

Inguinal hernioplasty is one of the most frequent general surgery operations. Many operative versions have been reported. Tension-free inguinal hernioplasty was first reported in 1989 [1]. The approach has since become the standard procedure worldwide. As a minimally in-

vasive laparoscopic surgery technique, laparoscopic hernia repair was introduced in the early 1990s [2,3], and has also become popular worldwide. The debate concerning conventional tension-free inguinal hernioplasty and laparoscopic inguinal hernia repair has been spirited. Several studies reported a trend towards an increase in hernia recurrence following laparoscopic hernia repair compared

Received July 15, 2011, Revised August 25, 2011, Accepted August 31, 2011

Correspondence to: Seung Man Park
Department of Surgery, Incheon St. Mary's Hospital, The Catholic University of Korea School of Medicine, 665 Bupyeong 6-dong, Bupyeong-gu, Incheon 403-720, Korea
Tel: +82-32-280-5609, Fax: +82-32-280-5988, E-mail: parksm@catholic.ac.kr

© Journal of the Korean Surgical Society is an Open Access Journal. All articles are distributed under the terms of the Creative Commons Attribution Non-Commercial License (<http://creativecommons.org/licenses/by-nc/3.0/>) which permits unrestricted non-commercial use, distribution, and reproduction in any medium, provided the original work is properly cited.

with conventional hernia repair, but this difference was not significant [4,5]. Yet, in the hands of surgeons experienced with laparoscopic hernia repair, the recurrence rate is similar for both procedures [6]. Laparoscopic hernia repair has been reported to be superior to conventional inguinal hernioplasty with respect to reduced postoperative pain, earlier return to work, and a better cosmetic outcome [4,5].

In recent years, various kinds of single port laparoscopic surgery have been reported including appendectomy and cholecystectomy [7,8]. Various ingenious single port laparoscopic surgical variations are being attempted in various surgeries including hernia repair. However, few reports of single port laparoscopic total extraperitoneal (TEP) hernioplasty have been published.

The present study chronicles the introduction and experience with single port laparoscopic TEP hernia repair.

METHODS

During the 10 months following June 2010, 63 cases of single port laparoscopic TEP hernia repair of inguinal hernias in 60 patients were performed at Incheon St. Mary's Hospital, The Catholic University of Korea School of Medicine. The operation was performed by one surgeon whose experience includes over 100 cases of conventional three port laparoscopic TEP hernia repair and more than 70 cases of single port laparoscopic appendectomy. Patient demographics, clinical data, intraoperative findings, and postoperative course were prospectively collected. This study was approved by the hospital's Institutional Review Board. All patients underwent surgery after providing informed consent.

Surgical technique

Under endotracheal general anesthesia, each patient was placed in the supine position with both arms adducted. A monitor was placed on the side of the hernia, with the surgeon and camera operator standing on the opposite side. Each patient was placed in a Trendelenburg position and the opposite side of the hernia site was tilted down. In 30 early cases, we used oblique incision to hernia

site. But, in 30 late cases, we used vertical incision because of cosmetic effect and approach to bilateral hernia. A single 2 to 2.5 cm-long incision was made on the midline, beginning from the deepest part of the umbilicus and extending to 0.5 to 1.5 cm of the periumbilicus. The subcutaneous layer was dissected down to the anterior rectus sheath and the anterior rectus sheath was incised transversely, approximately 2.5 cm long. After the splitting of the rectus muscle, our previously described glove single-port device [7,8] was inserted in front of the posterior rectus sheath (Figs. 1, 2). Carbon dioxide was insufflated to 12 mmHg. The preperitoneal dissection was performed using a rigid, 30-degree, 5 mm laparoscope and two Blunt dissectors (Ethicon Endo-Surgery Inc., Cincinnati, OH, USA). Almost all the procedures were performed using the same method with conventional laparoscopic TEP repair using a standard laparoscopic instrument.

Direct hernia was completely reduced with gentle traction. Transversalis fascia ('pseudo-sac') was anchored on the pubic bone by titanium tacks (Tacker, Covidien plc, Dublin, Ireland) to prevent seroma formation. Dissection of all possible hernia sites was performed to eliminate the possibility of missed hernias.

In the case of an indirect hernia, the sac was separated from the cord structure by the spread technique. In case of right indirect hernia, an Endo Grasp (Covidien plc) held in the left hand was used to grasp the sac and push it to the lateral side, and the right hand was used to dissect the cord structures by pushing the medial side, keeping dissection close to the sac (Fig. 3). The sac was isolated by a repeat of this motion. In the case of a left hernia, the procedure was mirror imaged to the right side. In a large scrotal type of hernia, the sac was incised beyond the internal ring and closed with vicryl Endo-loop (Sejong Medical Co., Paju, Korea). After completion of sac dissection and isolation (Fig. 4), the cord structures were freed from the peritoneum (parietalisation).

Afterwards, a surgical glove was detached and a 13 × 9 cm Parietex (Covidien plc) mesh was inserted through a single incision. After the mesh was positioned properly, two tacks were placed in the Cooper's ligament and the anterolateral abdominal wall. The space was deflated, with care taken not to displace the mesh. The anterior rectus

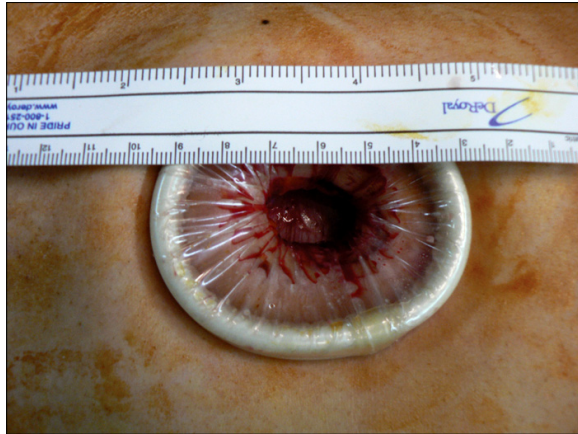


Fig. 1. Appearance of wound retractor placed in incision. Ruler indicates 2 cm diameter of incision. Retractor was ALEXIS XS (Applied Medical Resources Co., Rancho Santa Margarita, CA, USA).

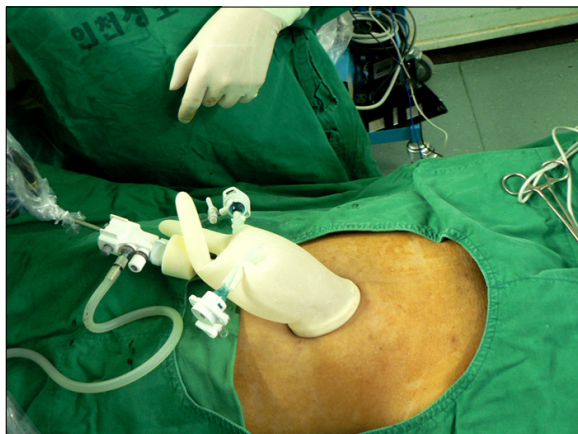


Fig. 2. Photograph of glove single port, which was composed of wound retractor and surgical glove.

sheath was closed using continuous 2-0 Vicryl sutures. The single skin incision was closed with subcuticular sutures.

RESULTS

Single port laparoscopic TEP hernia repair was successfully completed in 60 patients. Patient demographics and hernia characteristics are summarized in Table 1. The overall mean age of the patients was 58.5 years (range, 24 to 85 years) and mean body mass index was 23.3 kg/m² (range, 17.6 to 27.6 kg/m²).

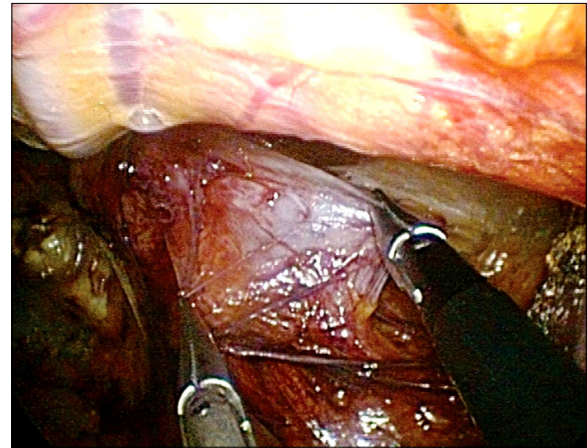


Fig. 3. Sac dissection was performed by spread technique.

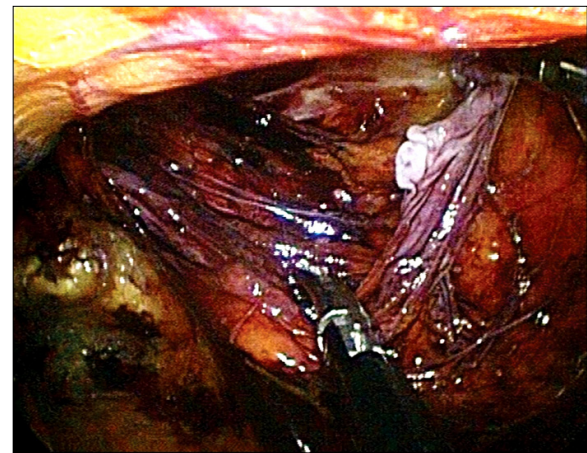


Fig. 4. Completion of sac isolation.

Operative and post-operative data are summarized in Table 2. Mean operative time was 62.0 minutes (range, 32 to 150 minutes). Mean operative time of indirect hernia was 65.2 minutes and direct hernia was 52.6 minutes. Mean operative time of both inguinal hernia was 77 minutes. None of the patients experienced intraoperative complications. There was one conversion to conventional transabdominal pre-peritoneal (TAPP) hernioplasty due to omental incarceration, which was severely adhered to the sac. Two postoperative complications occurred: one wound seroma and one urinary retention. Both were treated conservatively. Mean post-operative hospital stay was 2.15 days.

Table 1. Patient demographics and hernia characteristics

| Variable | Value |
|-------------------------------------|------------------|
| Number of patients | |
| Male | 58 |
| Female | 2 |
| Mean age, yr (range) | 58.5 (24-85) |
| Mean BMI, kg/m ² (range) | 23.3 (17.6-27.6) |
| Site of hernias (60 patients) | |
| Right | 31 |
| Left | 26 |
| Both | 3 |
| Type of hernias (n = 63) | |
| Indirect | 40 |
| Direct | 23 |

BMI, body mass index.

Table 2. Summary of operative and post-operative data

| Variable | Value |
|--|---------------|
| Operative time, min (range) | 62.0 (32-150) |
| Indirect | 65.2 (33-150) |
| Direct | 52.6 (32-80) |
| Both | 77 (66-90) |
| Conversion to conventional TEP repair | 1 |
| Intraoperative complication | 0 |
| Spermatic cord injury | 0 |
| Inferior epigastric vessel injury | 0 |
| Bowel injury | 0 |
| Morbidity, n (%) | 2 (3.3%) |
| Seroma | 1 |
| Urinary retention | 1 |
| Mean postoperative hospital stay (day) | 2.15 |

TEP, total extraperitoneal.

DISCUSSION

The two most common techniques in laparoscopic hernia repair are TAPP and TEP hernia repair. The TAPP approach is considered to be easier to perform than TEP repair. There is no difference in terms of recurrence, time to normal activity and time to work between the two procedures. However, the TAPP approach carries the potential risks of visceral injury, intestinal obstruction and port-site hernia [4,9-12]. One study reported that the risk of intestinal obstruction following TAPP procedure was 1.14 per 1,000 person-years and 0.28 after TEP procedure [13]. In case of single port laparoscopic TAPP hernia repair, completely scarless-transumbilical single incision is possible [14]. However, in case of TEP, completely tran-

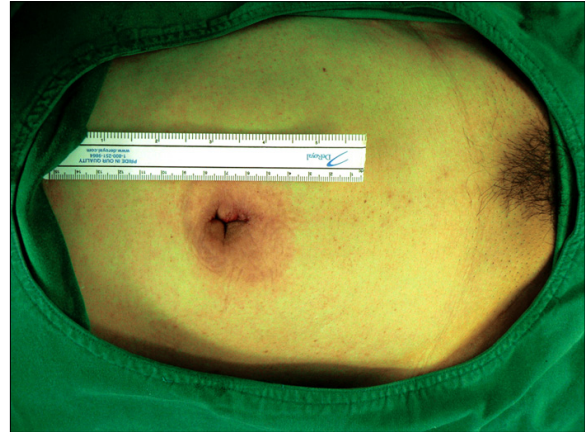

Fig. 5. Scar of single port total extraperitoneal hernioplasty at post-operation.

sumbilical incision is technically challenging due to the difficulty in approaching the anterior portion of posterior rectus sheath. For that reason, although we used the umbilicus as a single port access, a portion of the incision (0.5 to 1.5 cm) was extended outside of the umbilicus. However, the umbilical portion of the incision was invisible and the operative scar was nearly invisible (Fig. 5). In our opinion, our unique umbilical incision is cosmetically superior to the previously reported 2.5 to 3 cm-long infraumbilical incision [15-17]. In this study, there was 3.3% minor morbidity: one case of wound seroma and one case of urinary retention. In the case of wound seroma, we divided the sac due to large scrotal hernia. The seroma was completely resolved on an out-patient basis after five rounds of aspiration. In the case of the urinary retention, the patient had suffered from benign prostate hyperplasia. After 3 days of urinary drainage, voiding was acceptable. Another study reported a 2.1% incidence of hematoma or seroma, and incidence of urinary retention of 0.2% [18]. Still, more cases are needed to accurately establish the morbidity rate in single port TEP hernioplasty.

Many surgeons perform single port surgery using an articulating instrument. However, we did not use an articulating instrument due to the restricted operating space of the TEP procedure, and operational difficulty of the articulating instrument.

Presently, single port TEP repair is performed with the same method and instrument as used for conventional TEP repair. Despite this similarity, intraoperative compli-

cations, morbidity, recovery, pain and recurrence could differ. Large scale, controlled randomized trials are needed to establish the short-term and long-term outcomes between single port and conventional laparoscopic TEP repair.

We report the safe use of single port laparoscopic TEP hernioplasty. With the improvement of the single port laparoscopic instrument, single port TEP hernia repair should become more comfortable and less time-consuming to perform.

In conclusion, single port TEP repair is feasible and safe. Umbilical incision provides excellent cosmetic outcomes. A prospective randomized study comparing single port TEP with conventional TEP is necessary to establish the safety and long-term results of single port TEP hernioplasty.

CONFLICTS OF INTEREST

No potential conflict of interest relevant to this article was reported.

REFERENCES

- Lichtenstein IL, Shulman AG, Amid PK, Montllor MM. The tension-free hernioplasty. *Am J Surg* 1989;157:188-93.
- Spaw AT, Ennis BW, Spaw LP. Laparoscopic hernia repair: the anatomic basis. *J Laparoendosc Surg* 1991;1:269-77.
- Corbitt JD Jr. Laparoscopic herniorrhaphy. *Surg Laparosc Endosc* 1991;1:23-5.
- Memon MA, Cooper NJ, Memon B, Memon MI, Abrams KR. Meta-analysis of randomized clinical trials comparing open and laparoscopic inguinal hernia repair. *Br J Surg* 2003;90:1479-92.
- Malangoni MA, Rosen MJ. Hernias. In: Townsend CM Jr, Beauchamp RD, Evers BM, Mattox KL, editors. *Sabiston textbook of surgery: the biologic basis of modern surgical practice*. 18th ed. Philadelphia: Saunders Elsevier; 2007. p.1165-7.
- Lowham AS, Filipi CJ, Fitzgibbons RJ Jr, Stoppa R, Wantz GE, Felix EL, et al. Mechanisms of hernia recurrence after preperitoneal mesh repair. Traditional and laparoscopic. *Ann Surg* 1997;225:422-31.
- Lee YS, Kim JH, Moon EJ, Kim JJ, Lee KH, Oh SJ, et al. Comparative study on surgical outcomes and operative costs of transumbilical single-port laparoscopic appendectomy versus conventional laparoscopic appendectomy in adult patients. *Surg Laparosc Endosc Percutan Tech* 2009;19:493-6.
- Hong TH, You YK, Lee KH. Transumbilical single-port laparoscopic cholecystectomy: scarless cholecystectomy. *Surg Endosc* 2009;23:1393-7.
- McCormack K, Wake BL, Fraser C, Vale L, Perez J, Grant A. Transabdominal pre-peritoneal (TAPP) versus totally extraperitoneal (TEP) laparoscopic techniques for inguinal hernia repair: a systematic review. *Hernia* 2005;9:109-14.
- Leibl BJ, Jäger C, Kraft B, Kraft K, Schwarz J, Ulrich M, et al. Laparoscopic hernia repair--TAPP or/and TEP? *Langenbecks Arch Surg* 2005;390:77-82.
- Goswami R, Babor M, Ojo A. Mesh erosion into caecum following laparoscopic repair of inguinal hernia (TAPP): a case report and literature review. *J Laparoendosc Adv Surg Tech A* 2007;17:669-72.
- Lange B, Langer C, Markus PM, Becker H. Mesh penetration of the sigmoid colon following a transabdominal preperitoneal hernia repair. *Surg Endosc* 2003;17:157.
- Bringman S, Blomqvist P. Intestinal obstruction after inguinal and femoral hernia repair: a study of 33,275 operations during 1992-2000 in Sweden. *Hernia* 2005;9:178-83.
- Macdonald ER, Ahmed I. "Scarless" laparoscopic TAPP inguinal hernia repair using a single port. *Surgeon* 2010;8:179-81.
- Surgit O. Single-incision Laparoscopic surgery for total extraperitoneal repair of inguinal hernias in 23 patients. *Surg Laparosc Endosc Percutan Tech* 2010;20:114-8.
- Agrawal S, Shaw A, Soon Y. Single-port laparoscopic totally extraperitoneal inguinal hernia repair with the TriPort system: initial experience. *Surg Endosc* 2010;24:952-6.
- He K, Chen H, Ding R, Hua R, Yao Q. Single incision laparoscopic totally extraperitoneal inguinal hernia repair. *Hernia* 2011;15:451-3.
- Dulucq JL, Wintringer P, Mahajna A. Laparoscopic totally extraperitoneal inguinal hernia repair: lessons learned from 3,100 hernia repairs over 15 years. *Surg Endosc* 2009;23:482-6.