

# IMMUNOLOGIC REJECTION OF DIETHYLNITROSAMINE-INDUCED HEPATOMAS IN STRAIN 2 GUINEA PIGS

## PARTICIPATION OF BASOPHILIC LEUKOCYTES AND MACROPHAGE AGGREGATES\*

BY HAROLD F. DVORAK,† ANN M. DVORAK, AND WINTHROP H. CHURCHILL§

(From the Departments of Pathology, Massachusetts General Hospital, Harvard Medical School, and Tufts University School of Medicine, and the Department of Medicine, Robert B. Brigham Hospital, Boston, Massachusetts 02114)

(Received for publication 15 November 1972)

An association has been established between cell-mediated hypersensitivity and specific resistance to tumors in many species including man (1-10). Humoral immunity is apparently less important in the rejection of solid neoplasms and may actually enhance tumor growth (3, 8, 9). Tumor resistance requires lymphocytes sensitized against tumor-specific transplantation antigens, but the means by which these cells effect tumor cell destruction *in vitro* or *in vivo* is not yet established.

The mechanisms that have been proposed for immunologic tumor rejection are largely based on model systems in which defined cell populations or their products are incubated with tumor cells *in vitro*. Evidence has been presented that "killer" lymphocytes exert a direct cytopathic effect requiring contact with tumor target cells (11-13) and alternatively that lymphocytes act less directly, either by secreting cytotoxic mediators such as lymphotoxin (13-15) or by attracting and stimulating the function of other immunologically nonspecific cells, particularly macrophages (16). As useful as these models have been in elucidating the potential capabilities of lymphocytes and macrophages, they may not reflect the actual mechanism(s) by which the sensitized host rejects tumors *in vivo*.

A further complication to an understanding of immunologic mechanisms of tumor destruction has been the discovery in recent years that cellular hypersensitivity itself is not a homogeneous entity. We have shown that several forms of delayed-onset, lymphocyte-mediated hypersensitivity in animals and man are characterized by substantial infiltrations of basophilic leukocytes; these have been designated "cutaneous basophil hypersensitivity" (CBH)<sup>1</sup> to distinguish them from classic tuberculin hypersensitivity in which basophils are rare (17-23). At present, CBH-type reactions

\* Portions of this work have been presented in abstract form (1972. *Fed. Proc.* **31**:784). This work was supported by U.S. Public Health Service Grants AI-09529, AI-10,071, by U.S. Public Health Service research contract NIH 71-2172, and by General Research Support Fund Award 27812 to A.M.D.

† National Institutes of Health Career Development Awardee 5-K4-AI-46352.

§ Investigator, Howard Hughes Medical Institute.

<sup>1</sup> *Abbreviations used in this paper:* CBH, cutaneous basophil hypersensitivity; DSM, dense surface material; OPF, osmium-potassium ferrocyanide.

have been induced to a variety of protein antigens, and basophils characterize the lesions of contact allergy, hypersensitivity to vaccinia virus, and skin allograft rejection in guinea pigs.

The object of the present investigation was to provide a detailed analysis of the morphologic events associated with immunologically mediated tumor destruction as it occurs in vivo. Such a study, it was expected, would favor certain of the current in vitro models at the expense of others and might in addition suggest additional mechanisms such as those involving basophils. Diethylnitrosamine-induced hepatomas in inbred guinea pigs provide a particularly suitable system (4-7, 10, 24-26). Several antigenically distinct hepatoma lines are available, and systemic tumor resistance is readily induced by immunization of animals with tumor cells alone or in combination with mycobacteria. Further, tumor immunity is closely correlated with the induction of delayed-onset hypersensitivity and with the ability of host lymphocytes to produce at least one mediator (10).

#### *Materials and Methods*

*Tumor Immunizations and Skin Tests.*—Ascites variants of two hepatomas (lines 1 and 10) originally induced with *N*-nitrosodiethylamine in Sewall-Wright inbred strain 2 guinea pigs were employed in this study. Males were used in all experiments, but tumors were sometimes maintained in female animals; no Y chromosome-associated transplantation antigen has been found in guinea pigs (27). Details of tumor induction, formation of ascites variants, and transplantation techniques have been previously reported (4, 24). Tumor cells were recovered from the peritoneal cavity after intraperitoneal injection of 50 ml of medium 199 and were purified as described earlier (4).

Strain 2 male guinea pigs obtained from the Harvard University colony were immunized to line 1 tumor by a series of weekly intradermal injections of  $3 \times 10^6$  ascites cells. Animals received at least three tumor injections but the immune response was little affected by continued weekly immunization for up to 10 wk. Line 10 immune animals, kindly supplied by Dr. Berton Zbar, had been immunized with a single intradermal injection of  $1.5 \times 10^6$  tumor cells mixed with  $6 \times 10^6$  living BCG of the Phipps strain (TMC-1027; Trudeau Institute, Saranac Lake, N. Y.) several weeks before skin test. The tumor-specific transplantation antigens of lines 1 and 10 tumors do not cross-react with each other (25), a finding confirmed in this study.

Skin reactions were elicited by intradermal injection of  $3 \times 10^6$  tumor cells in 0.1 ml of medium 199 into the plucked flank skin of unsensitized and specifically or nonspecifically sensitized guinea pigs and were read at 4 and 24 h. The diameter of erythema (millimeters) and extent of induration (0 to ++++) were recorded.

*Fixation and Processing of Tissues.*—Animals were sacrificed by a blow to the head or with ether anesthesia, and skin reactions were immediately excised, cut into thin strips, and fixed in 5% phosphate-buffered glutaraldehyde, pH 7.3, for light microscopy. Tissues were postfixed in osmium tetroxide and 1- $\mu$ m epon-embedded sections were prepared and Giemsa stained (18). Peritoneal exudates from sensitized and control animals injected with  $30 \times 10^6$  line 1 tumor cells intraperitoneally (i.p.) were harvested at 1 or 3 days and were centrifuged and fixed in BEEM capsules (Better Equipment for Electron Microscopy, Bronx, N. Y.) and similarly processed.

Electron microscope studies were performed on 1- and 3-day peritoneal exudates induced with  $30 \times 10^6$  line 1 tumor cells in sensitized and control animals. In some instances exudate

cells were pelleted before fixation, whereas in other instances freshly collected cell suspensions were diluted 1:10 in fixative and centrifuged after primary fixation. In either instance cells were fixed at room temperature for 2 h in a fluid composed of 1% paraformaldehyde, 1.25% glutaraldehyde, and 0.025% Ca Cl<sub>2</sub> in 0.1 M sodium cacodylate buffer, pH 7.4 (28) and thereafter were washed overnight in cold 0.1 M cacodylate buffer, pH 7.4. For routine work, specimens were postfixed for 2 h in cold 2% collidine-buffered osmium tetroxide, dehydrated in a graded series of alcohols, and were embedded in a propylene oxide-epon sequence. Some cultures were stained en bloc with uranyl acetate before dehydration according to the method of Farquhar and Palade (29), slightly modified (28).

Electron microscope visualization of extracellular surface material was accomplished using a new osmium-potassium ferrocyanide (OPF) technique (30,31). Specimens were postfixed for 2 h at 4°C in 2% aqueous osmium tetroxide and 1.5% potassium ferrocyanide in 0.1 M pH 6.0 sodium phosphate buffer and were thereafter processed as above.

*Performance of Cell Counts.*—Quantitative studies of the various cell types infiltrating cutaneous reactions were performed as previously described (18, 23). Briefly, differential counts were made of all tumor and infiltrating cells in two or more randomly selected swaths, each 100  $\mu$ m wide, taken vertically through the entire thickness of the skin including dermis and subjacent fat and muscle layers. This method allowed calculation of absolute values for each cell type expressed as cells per millimeter of cutaneous surface as well as the relative frequency of each cell.

Peripheral white cell counts were performed on blood obtained from the venous plexus of the ear. In addition circulating basophils and eosinophils were enumerated using absolute counting methods (18, 32).

## RESULTS

*Gross Appearance of Skin Reactions Elicited by Line 1 or Line 10 Tumor Cells in Sensitized and Control Guinea Pigs.*—In confirmation of previous work (4, 26) line 1 or line 10 tumor cells elicited delayed-onset, erythematous indurated skin reactions maximal at 24 h when injected intradermally into specifically sensitized strain 2 guinea pigs (Table I). Little or no reaction was observed grossly when the same cells were injected into unsensitized animals or into animals sensitized against the other tumor cell line. These results establish that

TABLE I  
24 h Skin Reactions Elicited by  $3 \times 10^6$  Line 1 or Line 10 Tumor Cells in Specifically Sensitized, Nonspecifically Sensitized, or Nonsensitized Strain 2 Guinea Pigs

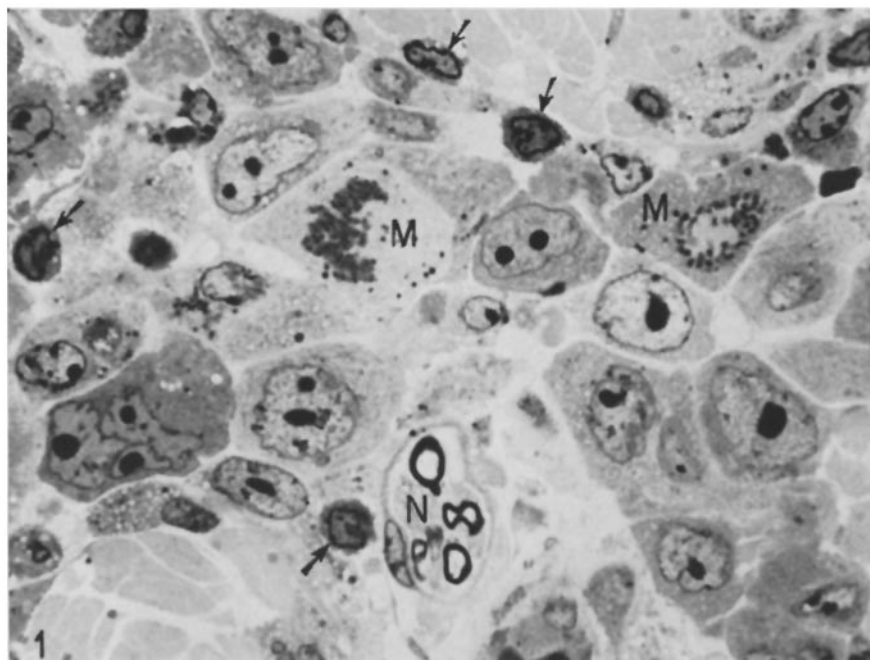
Skin test	Sensitization*	No. of animals	24 h reaction‡
Line 1	Line 1	11	12 ++
	Line 10	7	4 $\pm$
	None	12	6 $\pm$
Line 10	Line 10	7	16 +++
	Line 1	6	7 $\pm$
	None	6	9 $\pm$

\* Details of sensitization are recorded in Materials and Methods.

‡ Reactions were scored as diameter of erythema (millimeters) and degree of induration (0 to +++).

the reactions to be described were directed against specific antigens peculiar to line 1 or to line 10 tumor cells.

*Microscopic Appearance of 24 h Skin Test Sites after Injection of Line 1 or Line 10 Tumor Cells in Control and Specifically Sensitized Guinea Pigs.*—Line 1 or line 10 tumor cells injected intradermally into unsensitized or nonspecifically sensitized animals formed nests in the dermis, particularly in the deep dermis at its junction with the fat and muscular layers of the subcutis, and tended to spare the most superficial or papillary dermal layer (4). Tumor cells at 16- and 24-h sites were viable by morphologic criteria, exhibited frequent mitoses, and had elicited a moderate cellular infiltrate composed of lymphocytes, macrophages, neutrophils, and rare basophils (Fig. 1, Table II). Absolute cell counts revealed an inflammatory cell to tumor cell ratio of 0.5 to 0.8. The former were clearly of host origin because they were observed arriving in blood vessels and because the tumor cell suspension used for skin test contained fewer than 2% inflammatory cells.



Figs. 1-6 represent photomicrographs of 1- $\mu$ m, epon-embedded, Giemsa-stained sections of skin lesions obtained 24 h after intradermal injection of  $3 \times 10^6$  line 1 or line 10 ascites tumor cells in specifically sensitized or control guinea pigs.

FIG. 1. Appearance of line 10 tumor cells in the reticular (deep) dermis of an unsensitized guinea pig. Tumor cells are large, vary in size and shape, and may have more than a single nucleus (lower left). Mitoses (*M*) are abundant. A modest inflammatory infiltrate composed of mononuclear cells of various types (arrows) is evident. *N*, myelinated nerve.  $\times 1,000$ .

TABLE II  
*Absolute and Relative Counts of Tumor Cells and the Inflammatory Cell Infiltrate in the 24 h Cutaneous Lesions Elicited in Sensitized and Control Strain 2 Guinea Pigs with  $3 \times 10^6$  Line 1 or 10 Tumor Cells*

Skin test	Sensitization*	No. of animals	Absolute cell counts $\pm$ SE expressed as cells/linear mm surface†							Tumor cells‡	Total cells counted per animal
			Lymphocytes	Monocytes-macrophages	Polymorphs	Basophils	Eosinophils	Total inflammatory cells			
Line 1	Line 1	13	340 $\pm$ 29 (21 $\pm$ 1%)	767 $\pm$ 52 (49 $\pm$ 3%)	292 $\pm$ 58 (18 $\pm$ 3%)	195 $\pm$ 27 (12 $\pm$ 1%)	5 $\pm$ 3 ( $<$ 1%)	1,599 $\pm$ 106	442 $\pm$ 77	408 $\pm$ 27	
	Line 10	4	90 $\pm$ 25 (16 $\pm$ 4%)	224 $\pm$ 18 (40 $\pm$ 3%)	250 $\pm$ 48 (41 $\pm$ 5%)	21 $\pm$ 10 (3 $\pm$ 1%)	0	584 $\pm$ 82	1,180 $\pm$ 222	353 $\pm$ 47	
	None	9	169 $\pm$ 35 (19 $\pm$ 3%)	417 $\pm$ 81 (46 $\pm$ 4%)	255 $\pm$ 50 (34 $\pm$ 7%)	13 $\pm$ 4 (2 $\pm$ 0.5%)	1 $\pm$ 1 ( $<$ 1%)	856 $\pm$ 118	1,054 $\pm$ 103	389 $\pm$ 24	
Line 10	Line 10	4	481 $\pm$ 93 (26 $\pm$ 2%)	830 $\pm$ 129 (46 $\pm$ 2%)	86 $\pm$ 30 (5 $\pm$ 2%)	388 $\pm$ 33 (23 $\pm$ 2%)	15 $\pm$ 4 (2 $\pm$ 0.1%)	1,789 $\pm$ 217	431 $\pm$ 104	444 $\pm$ 54	
	Line 1	3	263 $\pm$ 42 (38 $\pm$ 2%)	313 $\pm$ 21 (47 $\pm$ 6%)	90 $\pm$ 42 (12 $\pm$ 5%)	20 $\pm$ 8 (3 $\pm$ 1%)	3 $\pm$ 1 (0.4 $\pm$ 0.1%)	690 $\pm$ 78	1,057 $\pm$ 290	349 $\pm$ 73	
	None	4	135 $\pm$ 25 (29 $\pm$ 4%)	269 $\pm$ 59 (56 $\pm$ 10%)	104 $\pm$ 50 (17 $\pm$ 4%)	8 $\pm$ 2 (2 $\pm$ 1%)	0	503 $\pm$ 125	861 $\pm$ 139	275 $\pm$ 48	

\* See Materials and Methods.

† Relative cell counts, expressed as percent of the total inflammatory infiltrate  $\pm$  SE, are included in parentheses.‡ Total recognizable tumor cells, including those judged nonviable by morphologic criteria, expressed as tumor cells/linear millimeter surface  $\pm$  SE.

Similar injections of either tumor line in specifically sensitized guinea pigs elicited typical delayed-onset skin reactions associated with tumor cell necrosis and a more extensive inflammatory infiltrate including substantial numbers of basophilic leukocytes (Figs. 2-6, Table II). Occasional nests of viable tumor persisted (Fig. 2), but for the most part tumor cells, located in the same distribution in the dermis as in controls, were damaged or dead by morphologic criteria (Figs. 4-6). Total tumor cells of both lines were reduced to one-third to one-half of the number counted in similar injection sites in control animals (Table II). Basophils were present in large numbers in the papillary (superficial) dermis where tumor cells were rare (Fig. 3) as well as in association with tumor cells in the deeper dermis (see below).

In an attempt to determine the mechanism of tumor cell destruction, anatomic relationships were sought between tumor cells and the various components of the inflammatory infiltrate. In control reactions (Fig. 1), where tumor cells were more frequent than inflammatory cells, such associations were not common although neutrophils and macrophages were engaged in the process of phagocytosing occasional dead tumor cells and other debris. By contrast, in specifically sensitized animals inflammatory cells at 24 h outnumbered recognizable tumor cells by approximately three to one, and anatomic relationships between tumor and inflammatory cells were considerably more frequent (Figs. 4-6). A large fraction of tumor cells in sensitized animals were damaged or dead by morphologic criteria and such cells were commonly surrounded by apparently viable neutrophils and macrophages that contained phagocytosed material within their cytoplasm. In some instances, individual small or medium-sized lymphocytes were found in relation to clumps of healthy-appearing or damaged tumor cells but such associations were uncommon.

A striking feature of reactions in sensitized animals was the frequency of intimate associations between basophils and both viable and necrotic tumor cells. Some of the granules of basophils disposed about tumor cells lacked their usual affinity for Giemsa stain and appeared pale (Figs. 4-6), suggesting that a portion of the granules' substance responsible for normal staining had been lost (see electron microscope findings below). Most such basophils had intact cell membranes and normal-appearing nuclei but others were disintegrating and could be recognized only by their characteristic granules. Degranulation of basophils was also observed and basophil granules were occasionally found free in the tissues (Fig. 21) and within the cytoplasm of macrophages.

Detailed cell counts permitted quantitative comparisons of the absolute and relative frequencies of the various types of infiltrating cells participating in experimental and control reaction sites (Table II). The total inflammatory cell infiltrate was increased two to threefold in positive reactions. Absolute numbers of lymphocytes and of monocytes-macrophages showed a similar two to threefold increase but maintained approximately the same relative frequency as was observed in control animals. The absolute neutrophil count was little changed in reactions in sensitized animals and as a result the relative frequency

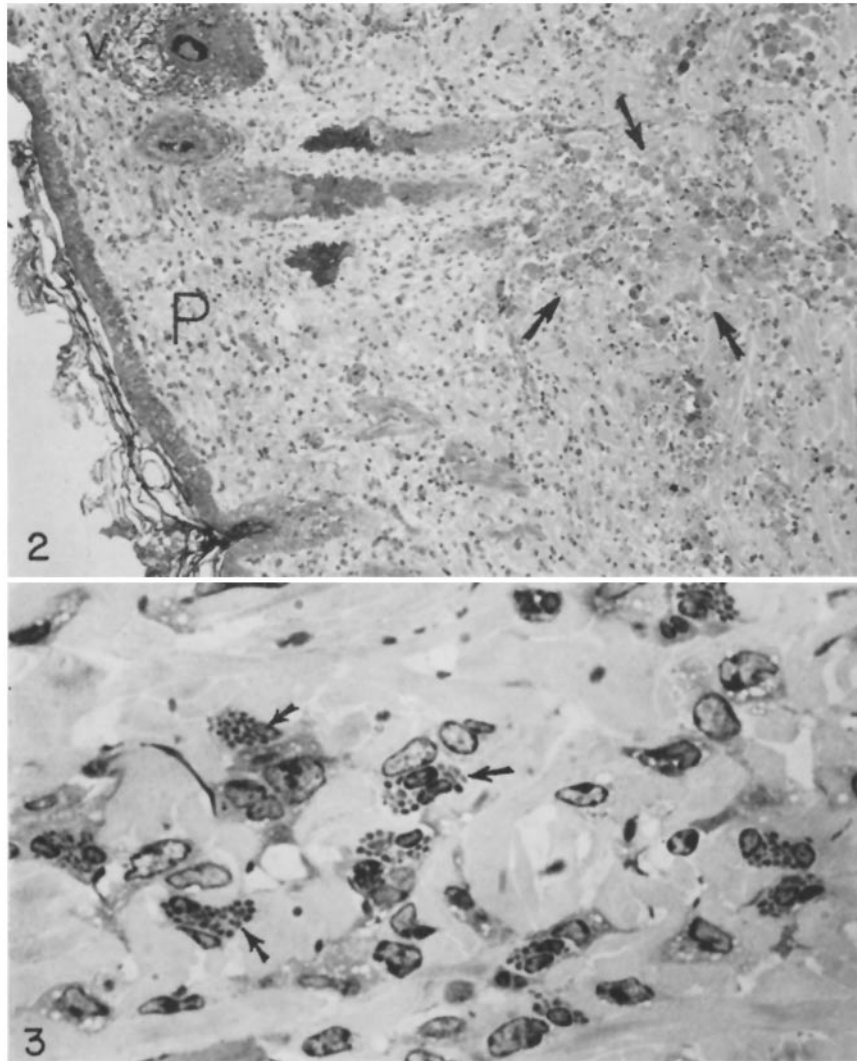
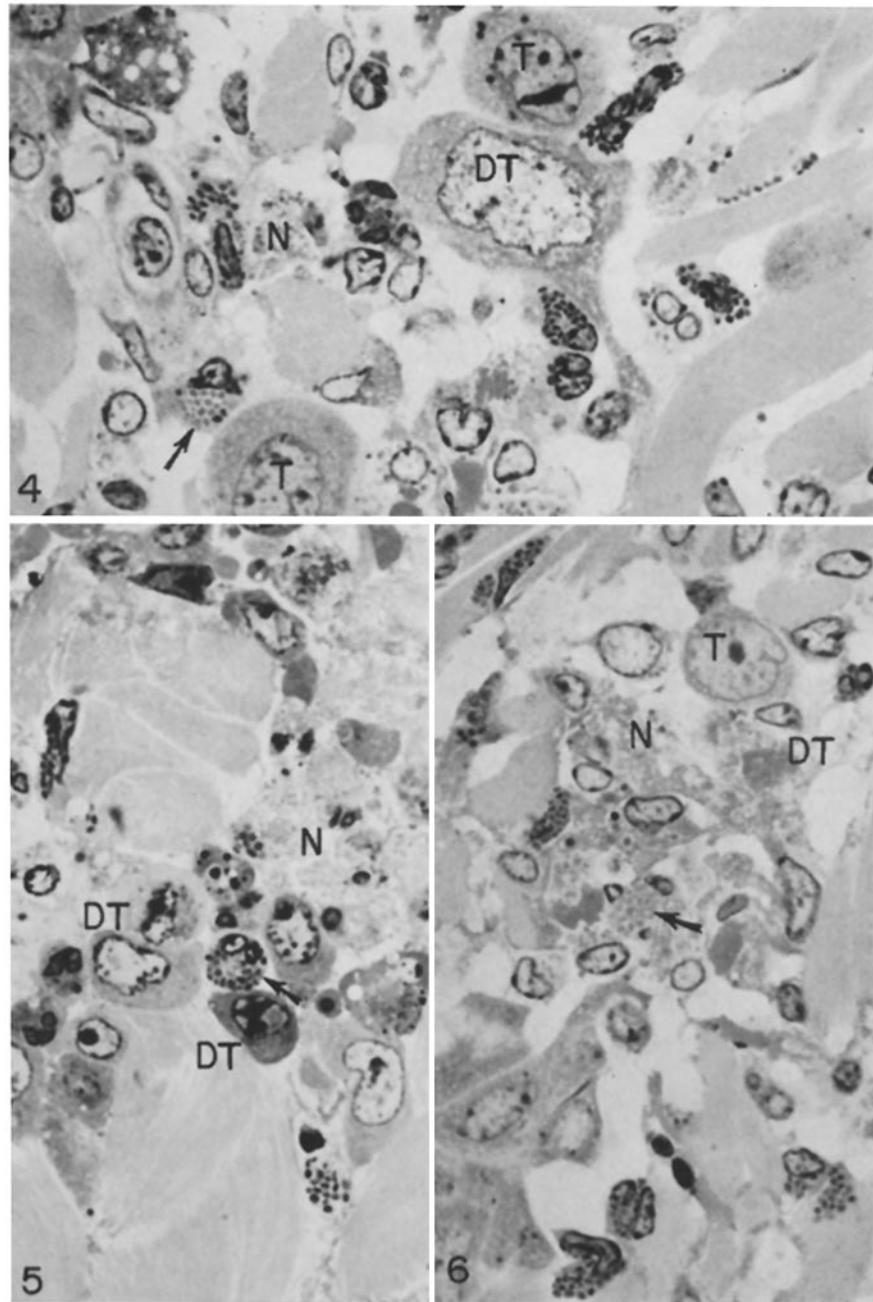


FIG. 2. Low magnification photomicrograph illustrating delayed-type reaction in the skin of a specifically sensitized animal challenged with line 10 tumor. Tumor cells are primarily located in the deep dermis (arrows). An extensive inflammatory infiltrate derived from the blood is associated with the tumor cells but also involves the papillary or most superficial dermis (*P*) where tumor cells are rare, even in control animals; basophils are particularly frequent in this region (see Fig. 3) as well as in the deeper dermis associated with tumor cells (see Figs. 4-6). Note vacuolation of epidermis and a hair follicle (*V*), the latter associated with a cellular infiltrate. Such changes were not observed in test sites in control animals.  $\times 100$ .

FIG. 3. Papillary dermis of a 24 h skin test site in a guinea pig sensitized to and challenged with line 1 tumor cells. At least 10 basophils (several indicated by arrows) along with various types of mononuclear cells are present; no tumor is recognized. There is some variation in the staining density of basophil granules but this is more striking among basophils immediately adjacent to tumor cells (Figs. 4-6).  $\times 1,000$ .



FIGS. 4-6. Immunologic rejection of line 10 (Figs. 4 and 6) and line 1 (Fig. 5) tumor cells in the skin of specifically sensitized guinea pigs. The figures illustrate progressive degrees of tumor damage and necrosis in association with a cellular infiltrate which includes numerous basophils. Note associations between basophils and damaged tumor cells (*DT*); such cells may exhibit pale staining with loss of nuclear and cytoplasmic detail (Figs. 4-6) or nuclear pyknosis (Fig. 5, lower *DT*) (compare with apparently viable tumor cells, *T*). Eventually there is cellular dissolution and necrosis of tumor (*N*) as illustrated in all three figures. Several basophils (arrows) exhibit striking loss of staining density of some or all of their cytoplasmic granules. Mononuclear cells and occasional neutrophils are also present. All  $\times 1,000$ .



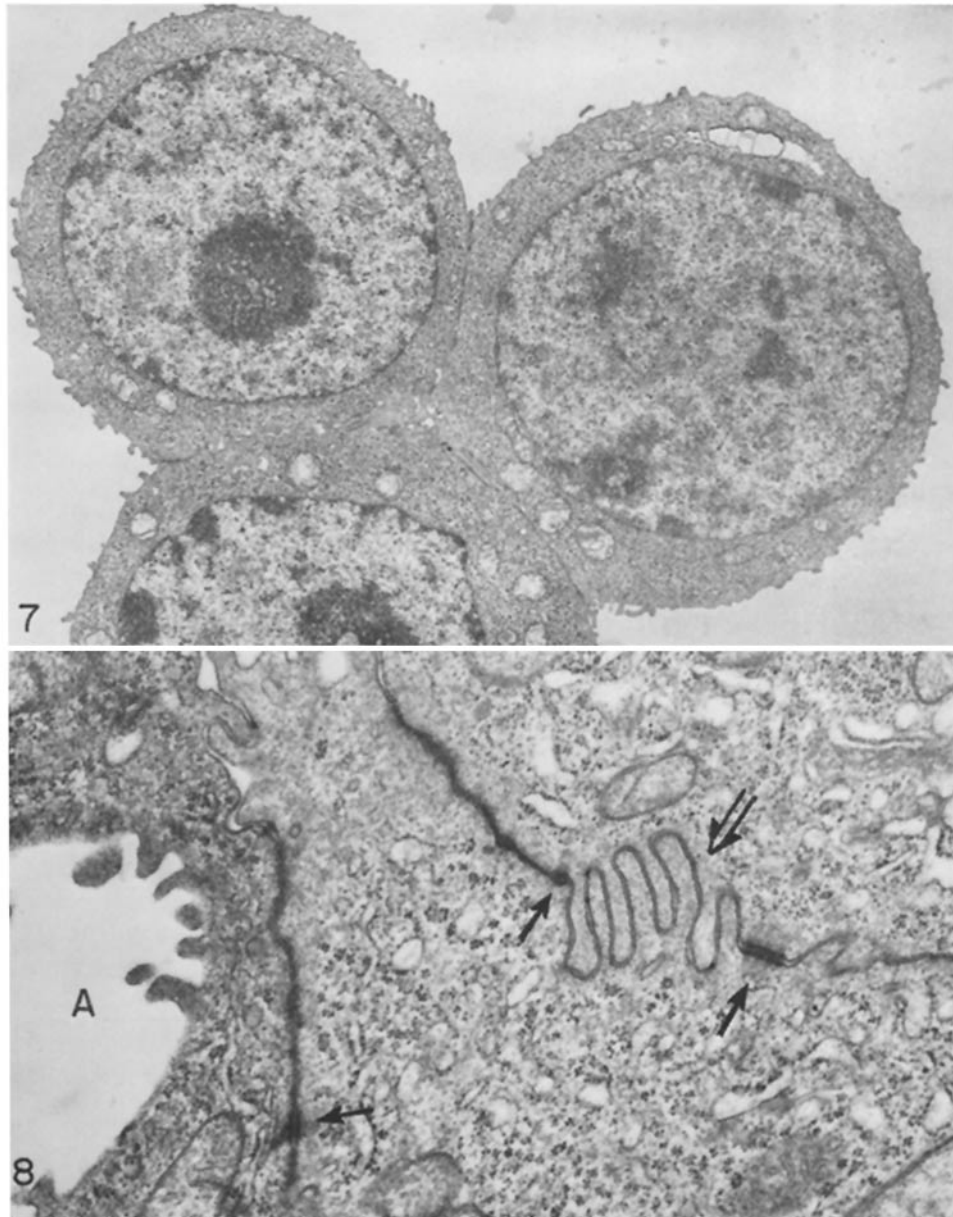
of neutrophils was significantly reduced. By contrast, the absolute number of basophils in positive skin reactions was increased 10–50 times over control sites with a corresponding relative increase in basophils of 4- to 12-fold (Table II). Eosinophils were infrequent in both experimental and control tests. The differences in cell numbers and frequencies observed between experimental and control test sites must be regarded as minimal values since measurements were performed near the centers of both experimental and control sites and experimental lesions were three to nine times larger in area than control reactions.

*Peritoneal Exudates Induced with Line 1 Ascites Tumor Cells in Sensitized and Control Guinea Pigs.*—To facilitate electron microscope observations and to determine whether the pattern of tumor rejection described above was unique to the skin, morphologic studies were also performed on exudates collected at 1–3 days after injection of  $30 \times 10^6$  line 1 tumor cells into the peritoneal cavities of sensitized and control strain 2 guinea pigs.

In control animals tumor cells elicited a modest inflammatory infiltrate composed of monocytes-macrophages, neutrophils, and lymphocytes at 24 h; thereafter, tumor grew extensively to account for greater than 98% of peritoneal exudate cells 3 days after injection. By contrast, sensitized animals rejected these larger tumor injections, a process associated with an extensive inflammatory infiltration of the peritoneal cavity. As in the skin the majority of invading cells were lymphocytes and monocytes-macrophages. However, basophils were regularly present by 24 h and accounted for 2–12% of cells (mean 5.8%) in the four animals whose exudates were examined on day 3. Eosinophils were extremely rare in either sensitized or control exudates but accounted for 10% of cells in one exceptional sensitized animal.

*Electron Microscope Appearance of Line 1 Ascites Tumor Cells.*—Tumor cells from 1- or 3-day exudates in normal strain 2 guinea pigs were rounded cells, larger than macrophages, with few, relatively short surface villi (Fig. 7). The nuclei were large, often lobulated, with an open central chromatin pattern and condensed chromatin aggregates at the nuclear membrane. Multiple large nucleoli were present. Cytoplasmic organelles included numerous free polysomes, a few strands of rough endoplasmic reticulum, and a large active Golgi area. Mitochondria were numerous and often had a pale matrix and irregular cristae. Microtubules and microfilaments were frequently present in the cytoplasm. Tumor cells were sometimes arranged in small cell clumps firmly held together by means of well-developed desmosomes (Fig. 8). Interdigitating short villi also served as points of intercellular attachment. Small acinic or canalicular spaces were present within the cytoplasm of cells or between adjacent cells that were attached by desmosomes; such spaces were regularly invaginated by villous processes projecting from the surfaces of surrounding cells.

With the OPF method tumor cell surfaces were coated with abundant extramembranous deposits of dense surface material (DSM) closely resembling the deposits we have previously described on peritoneal macrophages (Fig. 9 and 10) (31). These were arranged as a linear cell coat, accentuated at intervals by



Figs. 7-21. Electron micrographs illustrating the appearance of line 1 tumor and tumor-induced inflammatory cell response in the peritoneal cavities of control and specifically sensitized guinea pigs. Exudates were harvested 1 or 3 days after challenge with  $30 \times 10^6$  line 1 cells i.p. All electron micrographs are lightly stained with lead citrate.

Figs. 7 and 8. Line 1 hepatoma cells in a 3 day exudate obtained from an unsensitized animal. Malignant cells have large nucleoli, numerous cytoplasmic ribosomes, and many mitochondria that are slightly swollen and that have a pale matrix. Tumor cells formed small, tightly joined clumps (Fig. 7), held together by specialized surface attachments (Fig. 8). These include interdigitating villi (double-tailed arrow) and desmosomes (arrows). One cell exhibits an intracytoplasmic acinus (A), a characteristic feature of these cells probably derived from bile duct epithelium. Both uranyl en bloc. Fig. 7,  $\times 5,000$ ; Fig. 8,  $\times 21,000$ .

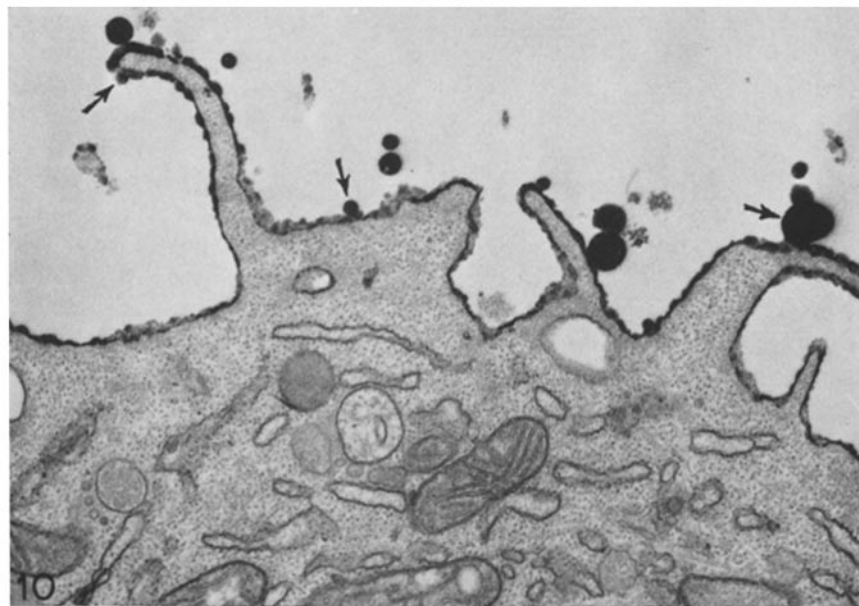
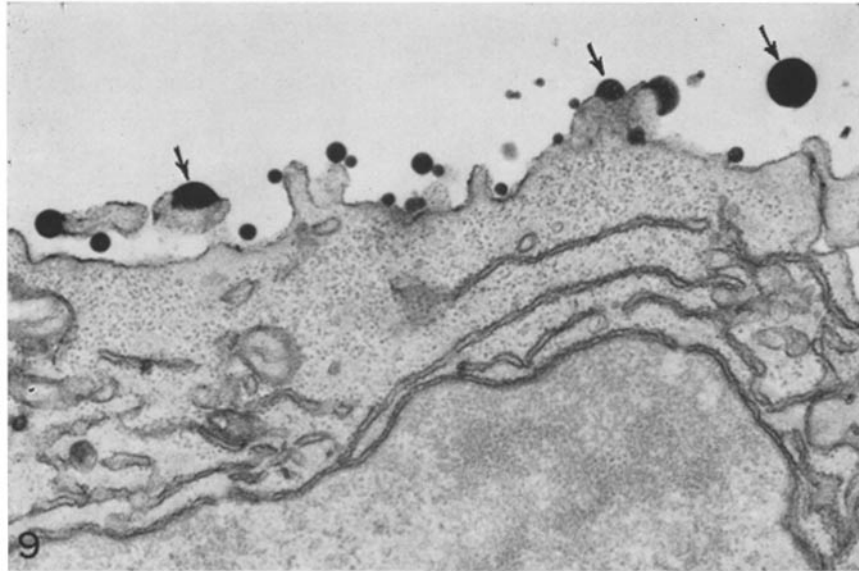


FIG. 9. Surface of tumor cell similar to those illustrated in Figs. 7 and 8 but fixed in suspension and processed with the OPF method. Dense surface material (DSM) is present primarily as large globules associated with villi (arrows). Similar material is free adjacent to the cell (arrows).  $\times 20,000$ .

FIG. 10. Peritoneal macrophage fixed and processed as in Fig. 9. Both linear and globular dense surface material (DSM) coat the surface external to the trilaminar unit membrane (31). Larger globules of dense material are in continuity with the membrane as well as lying free, adjacent to the cell (arrows).  $\times 20,000$ .

the formation of globular masses that appeared to be budding from the cell; in addition, similar dense globules were observed free of cellular attachments (Fig. 9). DSM was particularly abundant on free cell surfaces, whereas desmosome attachments lacked DSM and the membranes lining acinic spaces possessed only small amounts. Some acinic spaces, however, contained very dense, myelin-figurelike membranous material similar in appearance to DSM. In addition, occasional cytoplasmic vesicles, rough endoplasmic reticulum, and perinuclear cisternae contained material of the same density as DSM.

*Electron Microscope Studies of Line 1 Tumor Rejection in the Peritoneal Cavities of Sensitized Guinea Pigs.*—Exudates harvested at 1 and 3 days from specifically sensitized guinea pigs were largely composed of variably-sized aggregates or clumps of inflammatory and dead or dying tumor cells rather than of dispersed individual cells. The few residual viable tumor cells resembled those observed in control exudates and were generally not associated with inflammatory cell aggregates. Cell aggregates were composed of macrophages, lymphocytes, basophils, rare eosinophils, and tumor cells that showed varying degrees of nuclear and cytoplasmic dissolution. Macrophages accounted for approximately 70% of total cells, a higher proportion than was observed in tumor rejection sites in the skin. Macrophages were largely responsible for the formation of cellular aggregates, creating a cellular meshwork by means of mutual interdigitations of villous processes (Fig. 11). Other inflammatory cells, including basophils and lymphocytes, were also included in such aggregates and formed surface contacts with macrophages that involved apposition of relatively flattened membrane segments and invaginations of macrophages by short pointed pseudopods (Figs. 12 and 13). A striking feature of these aggregates, revealed by the use of OPF postfixation, was the lack of DSM on the surfaces of the cells composing them (Figs. 11–13). We have demonstrated a similar loss of cell coat material from macrophages and other cells whose migration from capillary tubes was inhibited by the interaction of sensitized lymphocytes and a soluble protein antigen (31). Cell aggregates of the type described here, but involving inflammatory cells exclusively, were observed in these inhibited cultures.

*Macrophages.*—The peritoneal macrophages in sensitized guinea pigs differed in the following respects from the few such cells observed in control animals and from the macrophages of oil-induced exudates. Macrophages in exudates rejecting tumor cells appeared “activated” in that they contained increased numbers of dense bodies, mitochondria, rough endoplasmic reticulum, vacuoles, and smooth and coated pinocytotic vesicles (Figs. 11, 12, and 14). Many possessed phagolysosomes as they avidly ingested morphologically dead and damaged tumor cells (Fig. 14), cellular debris, occasional erythrocytes, and portions of basophils and isolated basophil granules. Glycogen deposits were reduced in quantity.

*Basophils.*—Guinea pig basophils are granulocytes with multilobed nuclei and prominent cytoplasmic granules. Their cytoplasm includes numerous membrane-bound vesicles and vacuoles, many of which are in close association

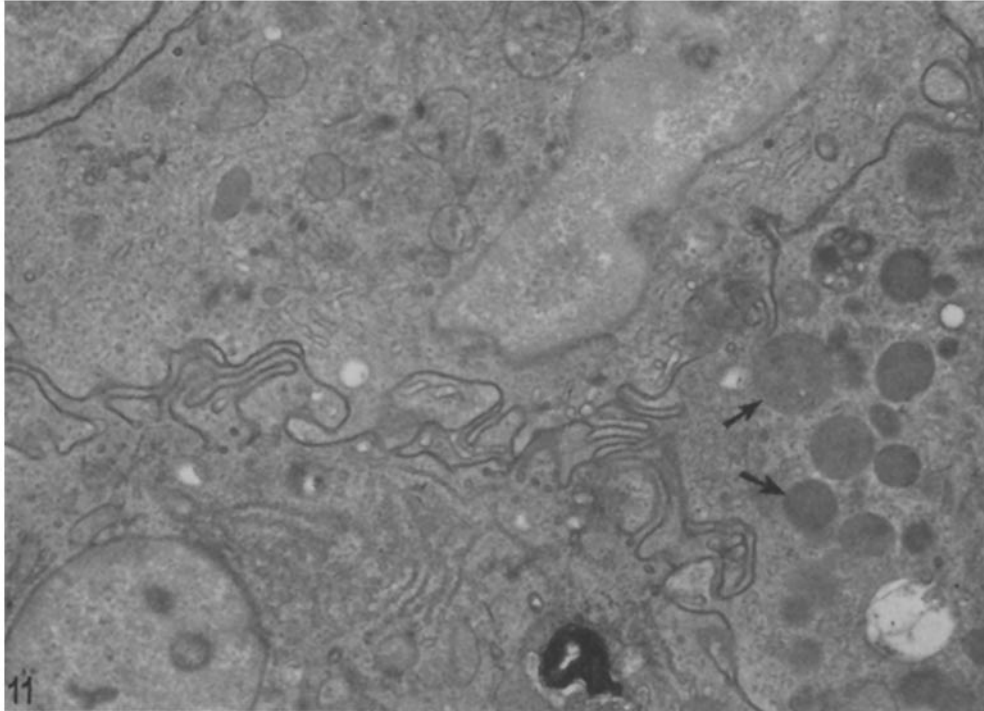


FIG. 11. Aggregated macrophages obtained from a 3 day exudate induced with line 1 tumor cells in a specifically sensitized guinea pig. Three macrophages are held together by means of a complex meshwork of interdigitating surface villi that lack detectable DSM (compare with Fig. 10). These cells are morphologically activated in that they have prominent nucleoli, many cell processes, and numerous cytoplasmic organelles including vesicles, mitochondria, dense bodies, and Golgi lamellae. One cell has particularly numerous lysosomes (arrows). OPF.  $\times 10,000$ .

or in actual continuity with either the cytoplasmic granules and their limiting membranes or with the plasma membrane itself (Figs. 15 and 16) (33). The characteristic cytoplasmic granules are membrane bound and have a unique crystalline ultrastructure whose appearance varies depending on the plane of section (Figs. 15 and 16) (33, 34).

Basophilic leukocytes were regularly found in peritoneal exudates in which tumor cells were undergoing immunologic rejection and formed a consistent component of peritoneal cell aggregates where they were associated with macrophages (Figs. 12 and 13) and less frequently with tumor cells, small lymphocytes, and neutrophils (Fig. 21). The cytoplasmic granules of these basophils exhibited certain changes that had only rarely been observed when these cells were examined in the blood or bone marrow (33).

One such change was a variable but frequently striking loss of granule

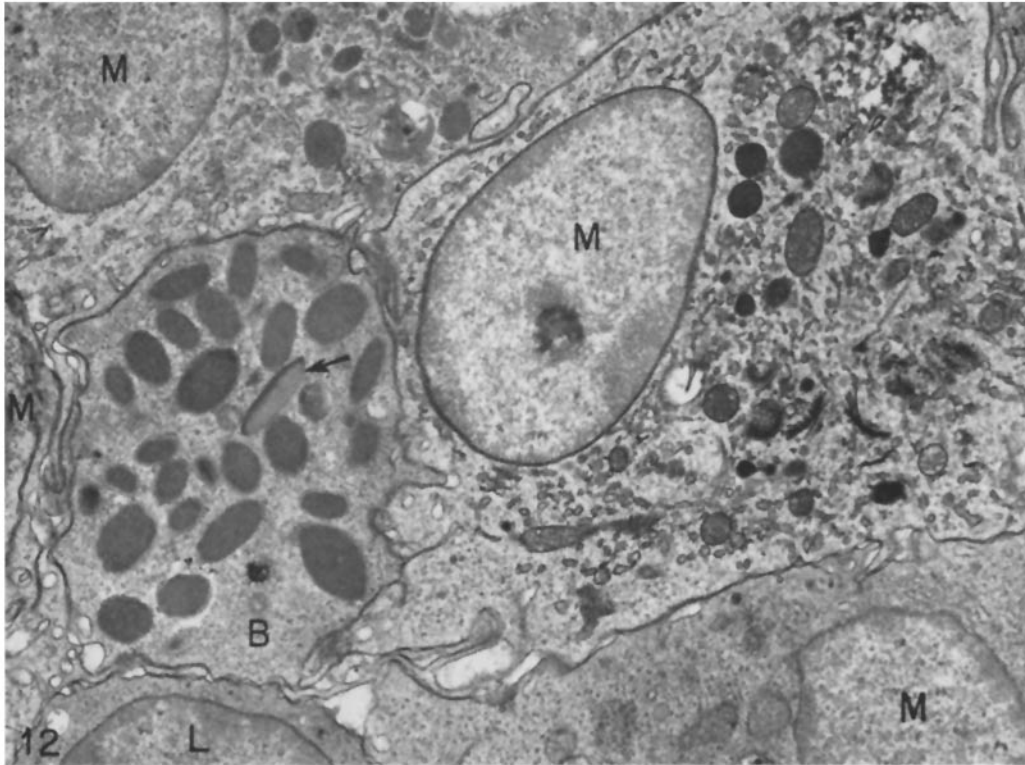


FIG. 12. Cell aggregate from a 3 day exudate in a sensitized guinea pig. Four activated macrophages (*M*) and one lymphocyte (*L*) surround a basophil (*B*) that has short surface processes invaginating adjacent cells. Numerous lysosomes and other organelles are present in the macrophages. One basophil granule (arrow) exhibits a striking loss of electron density and is illustrated at higher magnification in Fig. 18. All cells lack DSM. OPF.  $\times 7,000$ .

electron density that in extreme form proceeded to electron lucency (Figs. 12, 13, 17–20). This change is probably analogous to the loss of Giemsa staining observed in the light microscope by basophils adjacent to tumor cells (Figs. 4–6). At least some vesicles whose membranes had fused with granules contained material similar to that of granule substance (Fig. 17). In addition, occasional granules contained membranous whorles resembling myelin figures at their periphery (Fig. 20). Other granules were enveloped by membranes of increased density. Basophil degranulation was also observed with extrusion of cytoplasmic granules from morphologically viable cells (Fig. 21). Such extruded granules lacked limiting membranes and were often surrounded by an irregular rim of amorphous, moderately dense material that may represent partially dissolved granule substance. Extruded basophil granules were ingested by

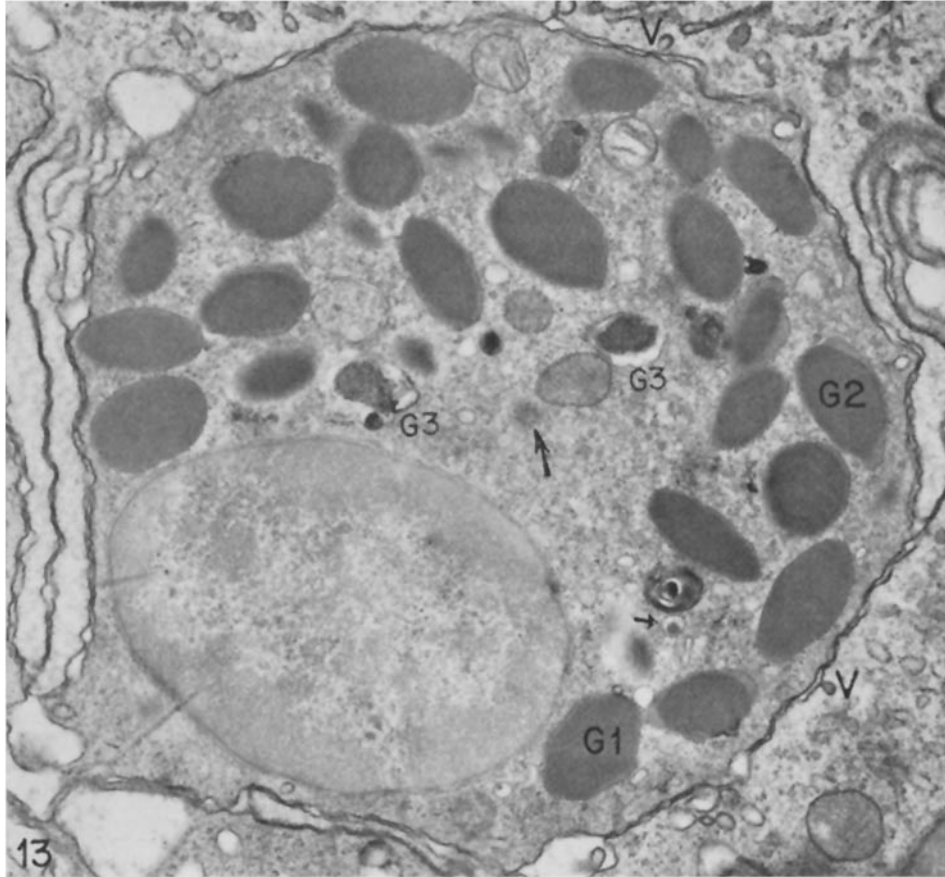


FIG. 13. Higher magnification of a basophil in a cellular aggregate of the type illustrated in Figs. 11 and 12. Only one nuclear lobe is present in this section and multiple cytoplasmic granules of characteristic ultrastructure (33, 34) are apparent. Note the prominent centriole (large arrow) and relatively inconspicuous Golgi apparatus. Numerous membrane-bound cytoplasmic vesicles are present. Some of these are closely associated with granules (*G1*) and some contain material similar in appearance and density to granule substance (small arrow). Other granules (*G2*) show slightly dense material filling irregular protrusions beneath the granule membrane. Two granules (*G3*) show empty vacuolar areas in the same locations. Elongate villi of four activated macrophages surround this basophil and their peripheral cytoplasm contains numerous coated vesicles (*V*). OPF.  $\times 10,000$ .

macrophages (rarely by neutrophils [Fig. 21]) and retained their ultrastructure even when enclosed within phagolysosomes. Dead and damaged basophils were less frequent in these peritoneal exudates than in the corresponding skin reactions.

*Other Cells.*—Small lymphocytes comprised a regular but minor component

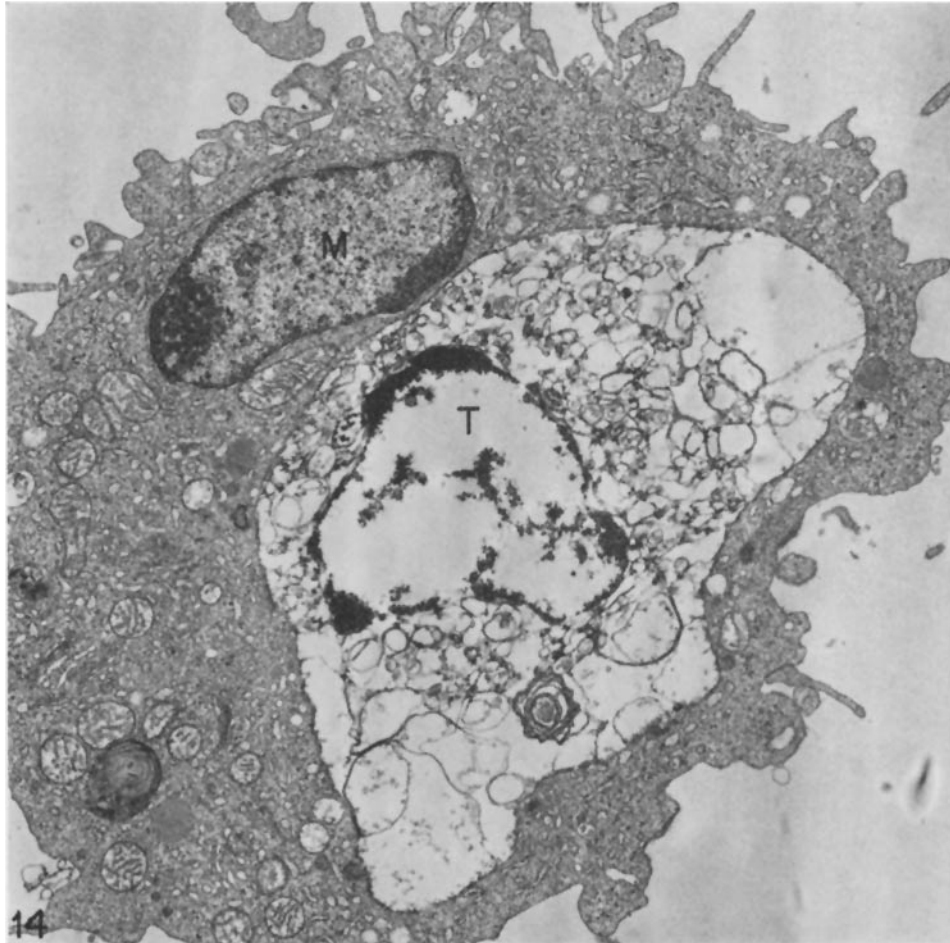
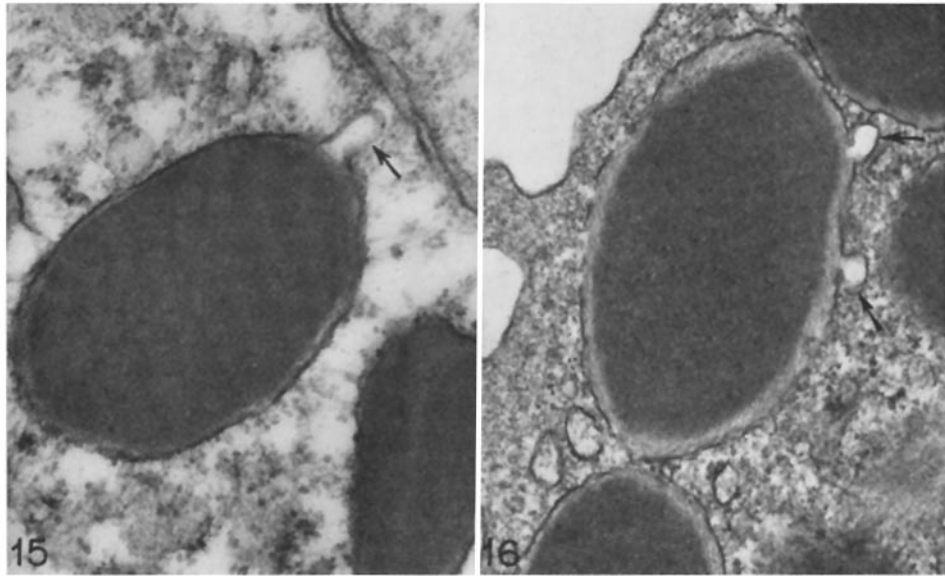


FIG. 14. Activated macrophage (*M*) obtained from a 3 day exudate in a specifically sensitized animal. The macrophage has within its cytoplasm a degenerating tumor cell (*T*). It is not possible to determine whether the tumor cell was dead before ingestion. Uranyl en bloc.  $\times 10,000$ .

of cell aggregates. They formed no striking associations with tumor cells, macrophages, or basophils nor was there evidence of lymphocyte enlargement or blast transformation. Typical eosinophils and neutrophils were present in very small numbers.

*Alterations in Blood Basophil Levels after Intraperitoneal Tumor Injection.*—Earlier studies indicated that guinea pigs primed for CBH reactivity with a single immunizing injection of protein antigen did not develop peripheral basophilia nor was basophilia induced by skin test (18). Animals sensitized against

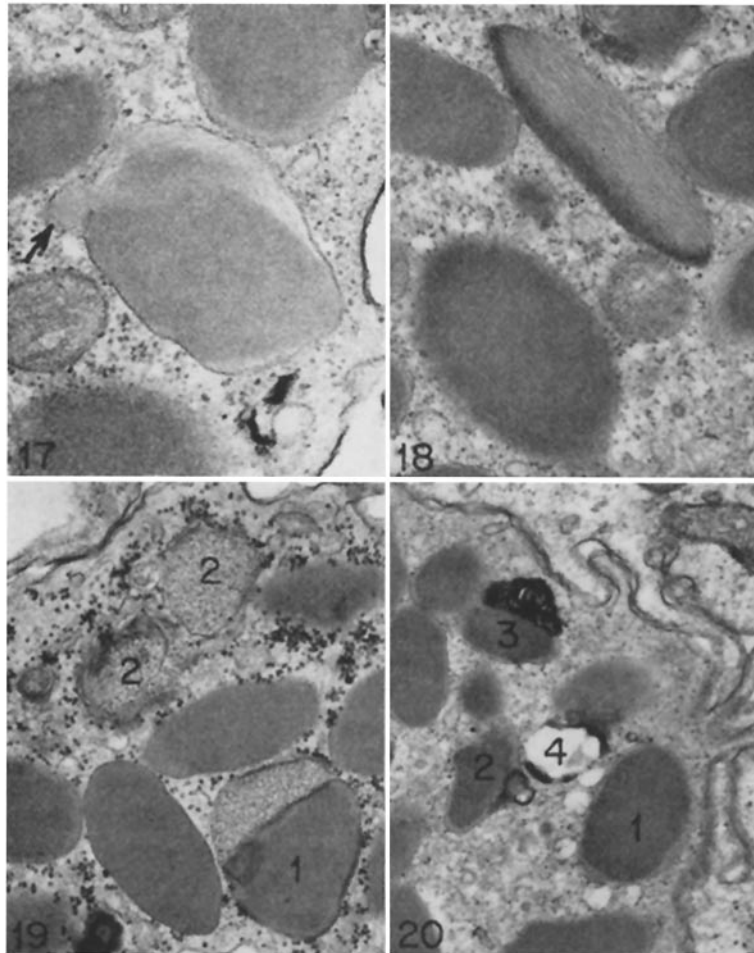




FIGS. 15 and 16. High magnification electron photomicrographs illustrating the characteristic parallel array structure of guinea pig basophil granules (33, 34). Several membrane-bound vesicles (arrows) with electron-lucent lumens communicate with the granules and one (Fig. 15) extends nearly to the cell's surface membrane. Note the decreased density in the submembranous zone of the granule in Fig. 16 (compare with Figs. 12, 13, and 17-20). Fig. 15, OPF; Fig. 16, uranyl en bloc. Both  $\times 30,000$ .

line 1 tumors by repeated intradermal injections of  $3 \times 10^6$  viable cells at weekly intervals also did not exhibit basophilia. However, when previously sensitized animals were challenged intraperitoneally with  $30 \times 10^6$  line 1 cells, ten times the usual skin test dose, a striking and highly significant peripheral basophilia developed within 1 day (mean 3.9-fold increase; range 2.4-8-fold) and thereafter declined, returning to base-line values over the course of a week (Fig. 22). The great majority of peritoneal tumor cells were killed within 3 days of such challenge. The total white blood cell count was also increased by a smaller (50%) but statistically significant amount 1 day after challenge but returned to normal at 3 days. Levels of circulating eosinophils showed no consistent change at any interval.

Similar injections of tumor cells in unsensitized animals caused no immediate alterations in circulating white blood cells; however, numbers of circulating basophils, but not of other granulocytes, rose gradually in some animals and by 7-9 days were elevated nearly threefold over starting values (range, 0-8-fold) (Fig. 22). Thus, basophilia developed in control animals after a latent period that may correspond to the interval required for the initiation of a



FIGS. 17-20. High magnification electron photomicrographs of guinea pig basophil granules (3-day exudates in specifically sensitized animals) illustrating loss in density and structure of granule matrix and accumulation of membranous whorles (Fig. 20). Note that granule matrix is replaced by less dense material which appears fibrillar in longitudinal section (Figs. 17 and 18) and appears granular when cut in cross section (Fig. 19, granules labeled 1 and 2). Similar fibrillar material extends into the granule associated vesicle of Fig. 17 (arrow). Loss of granule density begins at the granule periphery (Figs. 16, 17, and 20), but may extend to involve much (Fig. 18 and Fig. 19, granule 1) or all (Fig. 19, granules labeled 2) of the granule. In Fig. 20, one granule (1) is closely associated with at least five electron-lucent vesicles; another (2) exhibits fusion of an attached vesicle with a very dense membrane; a third (3) has closely associated with it multiple whorles of dense membranes; and a fourth (4) consists of a largely empty (electron-lucent) space surrounded by a dense membrane. Granule 4 is thought to represent a basophil granule that has lost its contents. All OPF. Fig. 17,  $\times 24,000$ ; Fig. 18,  $\times 24,000$ ; Fig. 19,  $\times 18,000$ ; Fig. 20,  $\times 18,000$ .

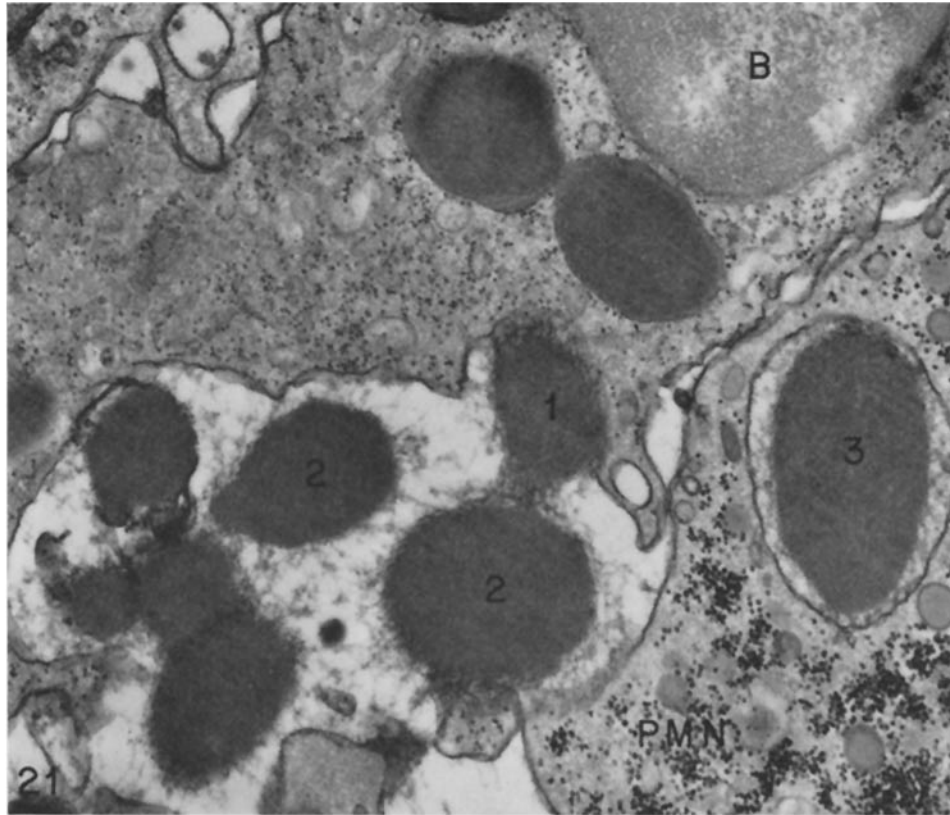


FIG. 21. Extrusion of characteristic cytoplasmic granules into the extracellular space from a morphologically viable basophil (*B*). One granule (*1*) is in the process of traversing the basophil cytoplasmic membrane. Several others (*2*), already in the extracellular space, have lost their surrounding membranes and are surrounded by lightly dense fibrillar and particulate material, thought to represent beginning dissolution of granule matrix. An adjacent polymorphonuclear leukocyte (*PMN*) has ingested a basophil granule (*3*) that is contained within a membrane-limited phagolysosome. This phagocytosed basophil granule has retained its characteristic ultrastructure. Typical cytoplasmic granules, pale appearing with OPF, and abundant dense glycogen particles are also present in the neutrophil. OPF.  $\times 22,000$ .

primary immune response. Such animals, however, were not able to reject the rapidly growing tumor in their peritoneal cavities and regularly died of their malignancy within 2–3 wk.

#### DISCUSSION

The data presented here confirm earlier studies associating syngeneic tumor rejection in guinea pigs with cell-mediated hypersensitivity and afford a

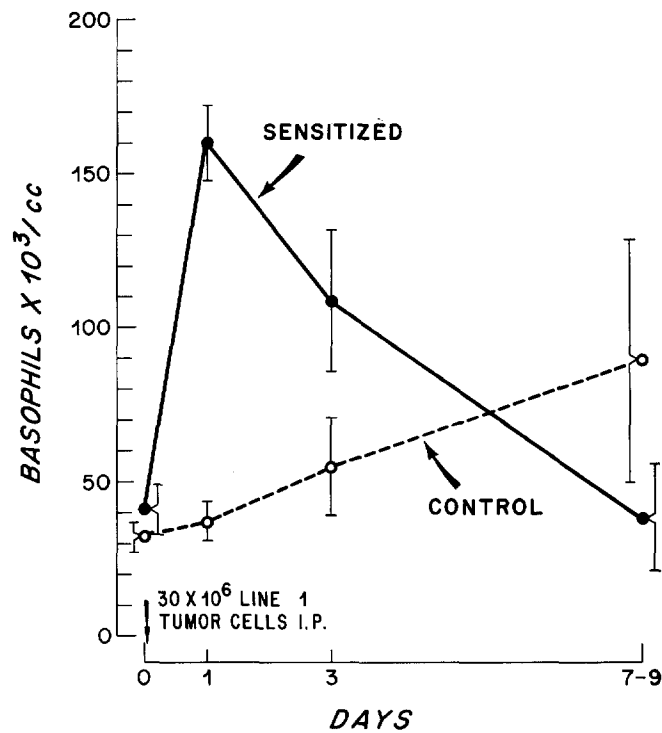


FIG. 22. Circulating absolute basophil levels in the peripheral blood of specifically sensitized (●—●) and unsensitized (○---○) guinea pigs at successive intervals after intraperitoneal injection of  $30 \times 10^6$  line 1 tumor cells.

morphologic description of such rejection as it occurs *in vivo*. The findings suggest that cell-mediated tumor rejection may involve basophilic leukocytes and peritoneal cell aggregate formation and permit examination of previously proposed *in vitro* models of tumor rejection in the light of events actually occurring in the intact animal.

Tumor injections in unsensitized or in nonspecifically tumor-sensitized animals attracted modest accumulations of lymphocytes, macrophages, and neutrophils but only rare basophils; and basophils were, in fact, the only infiltrating cell to demonstrate a relative increase in frequency in sensitized as compared with control animals. Striking associations between basophils and tumor cells were observed in the skin but were less common in the macrophage-rich cell aggregates characteristic of tumor rejection in the peritoneal cavity. However, basophils also accumulated in these aggregates, and intraperitoneal tumor injection induced a prompt basophilia in specifically sensitized animals.

Taken together, these data comprise an impressive body of evidence linking basophils with tumor immunity.<sup>2</sup>

In addition to their striking associations with tumor cells in the skin of sensitized animals, large accumulations of basophils were also present in the papillary dermis where tumor cells were relatively infrequent. This distribution of basophils is characteristic of all of the lesions of cutaneous basophil hypersensitivity thus far studied in the guinea pig (18–21) and suggests that factors other than antigen distribution in the dermis determine basophil localization. One possible explanation is that the papillary dermal vasculature is specialized in some way to facilitate the diapedesis of basophils.

The functions of basophils in cell-mediated hypersensitivity or in normal physiology are poorly understood. Basophils pinocytose and accumulate in their cytoplasmic granules certain proteins such as horseradish peroxidase, but they do not ingest significant amounts of several other soluble proteins or of inert particulate matter (33). No evidence for a phagocytic function was found in the present study, and dying tumor cells and cell debris, avidly phagocytosed by macrophages, were never observed within basophils. Basophil function is more likely related to the release of the contents of their prominent cytoplasmic granules that are thought to store pharmacologic mediators such as histamine (18). This hypothesis is supported by morphologic evidence demonstrating occasional basophil degranulation and by the regular loss in both light and electron microscope staining density of basophil granules in the course of tumor destruction. The latter change, initially affecting individual granules, sometimes proceeded to involve all granules within a cell and was particularly striking in basophils adjacent to tumor cells undergoing immunologic rejection. Basophils so altered appeared viable by morphologic criteria. We postulate that the observed loss of basophil granule density reflects release of pharmacologic agents contained within these granules and that release proceeds by means of exocytosis (33, 36). According to this view microvesicles containing granule mediators pass from the cytoplasmic granules to the cell surface where they fuse with the cell membrane and discharge their contents. Consistent with our hypothesis, a fraction of microvesicles within basophils contained material similar in appearance and electron density to that comprising the substance of basophil granules (Fig. 17). Microvesicles have been shown to transport tracers in the opposite direction, from the cell surface to basophil granules (33).

Electron microscope studies of line 1 tumor rejection in the peritoneal cavities of specifically sensitized animals revealed several additional findings that may be relevant to an understanding of host immune defense mechanisms. First,

---

<sup>2</sup> Basophils have also been shown to accumulate in skin window sites in response to slices of killed autologous breast cancer in some patients who have been treated for this malignancy (35).

macrophages, lymphocytes, and other peritoneal cells formed cell clumps or aggregates held together by complex interdigitations of elongate villous macrophage processes. This meshwork closely resembled the aggregates occurring *in vitro* among peritoneal exudate cells whose migration from capillary tubes was inhibited as a consequence of interaction between sensitized lymphocytes and specific antigen (31), except that tumor cells and basophils were also included. Cell aggregate formation may be related to tumor killing in that nearly all tumor cells in aggregates were morphologically dead or damaged whereas the few remaining viable peritoneal tumor cells were not trapped within aggregates. Second, the peritoneal macrophages associated with tumor rejection exhibited the morphologic criteria of "activation," in contrast to peritoneal macrophages obtained from nonimmune animals or from oil-induced peritoneal exudates. Third, both the peritoneal cell aggregates and their counterparts in the *in vitro* migration inhibition assay system had reduced extramembranous cell surface material of the type normally covering peritoneal exudate and line 1 ascites tumor cells. It is unlikely that the reduction in cell surface material under these conditions can be attributed to a failure of penetration of the OPF reagent since similar extramembranous material was visualized in acinar spaces of clustered tumor cells from control exudates and on the glass-adherent surfaces of cultured macrophages (31). A cause-effect relationship between cell aggregation and lack of cell surface material has not yet been established. Possibly this extramembranous material repels adjacent cells that are similarly coated, thus preventing aggregation of dispersed cells.

It seems unlikely from our data that anatomic contacts between individual sensitized lymphocytes and tumor cells are necessary for tumor destruction in the intact animal (11-13). Associations between individual lymphocytes and tumor cells were relatively infrequent and clumps of living, damaged, and dead tumor cells were commonly observed in the skin without relation to lymphocytes. If anatomic associations with lymphocytes are important in tumor rejection, they must be of sufficiently brief duration so as to be rare at any single moment of time. These findings, therefore, support the view that lymphocytes mediate tumor destruction in a less direct fashion, possibly by the secretion of mediators that are either themselves tumoricidal or which attract and activate nonspecific inflammatory cells.

#### SUMMARY

The morphologic events associated with the immunologic rejection by strain 2 guinea pigs of ascites variants of two lines of diethylnitrosamine-induced tumors have been studied by light and electron microscopy.

Tumor injection sites in the skin of control animals exhibited clusters of viable, actively mitotic tumor cells along with a modest inflammatory infiltrate composed of lymphocytes, macrophages, neutrophils, and rare basophils.

In contrast, similar injections of either tumor line in specifically sensitized guinea pigs elicited typical delayed-type skin reactions associated with tumor cell necrosis and a more extensive inflammatory infiltrate including a selective increase in the number of basophilic leukocytes (12%, line 1, or 23%, line 10, of total inflammatory cells). That basophils may have a role in tumor resistance *in vivo* is suggested by the close anatomic associations observed between basophils and tumor cells, and by the fact that basophils were the only inflammatory cell to demonstrate a relative increase in frequency in the lesions of sensitized as compared with control animals. Moreover, intraperitoneal injection of line 1 tumor in specifically sensitized animals elicited a striking basophilia within 24 h. Unlike macrophages, basophils did not phagocytose tumor cells but did evidence occasional extrusion of granules and frequently exhibited loss of granule staining density, a change that may be related to release of mediator substances.

Electron microscope studies of line 1 tumor rejection in the peritoneal cavities of specifically sensitized guinea pigs demonstrated aggregations of "activated" macrophages, lymphocytes, basophils, and damaged or dead tumor cells. These aggregates, held together by complex interdigitations of macrophage villi, closely resembled those occurring *in vitro* among peritoneal exudate cells whose migration from capillary tubes was inhibited by migration inhibition factor (MIF). Moreover, cells in these aggregates, as well as macrophages inhibited by MIF *in vitro*, lacked a normal coating of cell surface material.

The authors gratefully acknowledge the kind assistance of Dr. Berton Zbar who provided animals immunized against line 10 tumor for this study. We also thank Ellen Morgan for photographic assistance with the electron micrographs and Blanche Simpson for technical assistance.

#### REFERENCES

1. Old, L. J., and E. A. Boyse. 1965. Antigens of tumors and leukemias induced by virus. *Fed. Proc.* **24**:1009.
2. Klein, G. 1966. Tumor antigens. *Annu. Rev. Microbiol.* **20**:223.
3. Burnet, F. M. 1970. The concept of immunological surveillance. *Prog. Exp. Tumor Res.* **13**:1.
4. Churchill, W. H., Jr., H. J. Rapp, B. S. Kronman, and T. Borsos. 1968. Detection of antigens of a new diethylnitrosamine-induced transplantable hepatoma by delayed hypersensitivity. *J. Natl. Cancer Inst.* **41**:13.
5. Wepsic, H. T., B. Zbar, H. J. Rapp, and T. Borsos. 1970. Systemic transfer of tumor immunity. Delayed hypersensitivity and suppression of tumor growth. *J. Natl. Cancer Inst.* **44**:955.
6. Kronman, B. S., H. T. Wepsic, W. H. Churchill, Jr., B. Zbar, T. Borsos, and H. J. Rapp. 1969. Tumor specific antigen detected by inhibition of migration. *Science (Wash. D.C.)*. **165**:296.

7. Zbar, B., H. T. Wepsic, T. Borsos, and H. J. Rapp. 1970. Tumor-graft rejection in syngeneic guinea pigs. Evidence for a two-step mechanism. *J. Natl. Cancer Inst.* **44**:473.
8. Hellström, K. E., and I. Hellström. 1969. Cellular immunity against tumor antigens. *Adv. Cancer Res.* **12**:167.
9. Hellström, I., K. E. Hellström, G. E. Pierce, and J. P. S. Yang. 1968. Cellular and humoral immunity to different types of human neoplasms. *Nature (Lond.)*. **220**:1352.
10. Churchill, W. H., B. Zbar, J. A. Belli, and J. R. David. 1972. Detection of cellular immunity to tumor antigens of a guinea pig hepatoma by inhibition of macrophage migration. *J. Natl. Cancer Inst.* **48**:541.
11. Rosenau, W., and H. D. Moon. 1961. Lysis of homologous cells by sensitized lymphocytes in tissue culture. *J. Natl. Cancer Inst.* **27**:471.
12. Wilson, D. B., and R. E. Billingham. 1967. Lymphocytes and transplantation immunity. *Adv. Immunol.* **7**:189.
13. Lawrence, H. S., and M. Landy, editors. 1969. *Mediators of Cellular Immunity*. Academic Press, Inc., New York.
14. Ruddle, N. H., and B. H. Waksman. 1968. Cytotoxicity mediated by soluble antigen and lymphocytes in delayed hypersensitivity. III. Analysis of mechanism. *J. Exp. Med.* **128**:1267.
15. Williams, T. W., and G. A. Granger. 1969. Lymphocyte in vitro cytotoxicity: correlation of derepression with release of lymphotoxin from human lymphocytes. *J. Immunol.* **103**:170.
16. Ward, P. A., C. D. Offen, and J. R. Montgomery. 1971. Chemoattractants of leukocytes with special reference to lymphocytes. *Fed. Proc.* **30**:1721.
17. Richerson, H. B., H. F. Dvorak, and S. Leskowitz. 1970. Cutaneous basophil hypersensitivity. I. A new look at the Jones-Mote reaction, general characteristics. *J. Exp. Med.* **132**:546.
18. Dvorak, H. F., A. M. Dvorak, B. A. Simpson, H. B. Richerson, S. Leskowitz, and M. J. Karnovsky. 1970. Cutaneous basophil hypersensitivity. II. A light and electron microscopic study. *J. Exp. Med.* **132**:558.
19. Dvorak, H. F. 1971. Role of basophilic leukocytes in allograft rejection. *J. Immunol.* **106**:279.
20. Dvorak, H. F., B. A. Simpson, R. C. Bast, and S. Leskowitz. 1971. Cutaneous basophil hypersensitivity. III. Participation of the basophil in hypersensitivity to antigen-antibody complexes, delayed hypersensitivity, and contact allergy. Passive transfer. *J. Immunol.* **107**:138.
21. Dvorak, H. F., and M. Hirsch. 1971. Role of basophilic leukocytes in immunity to vaccinia virus infection. *J. Immunol.* **107**:1576.
22. Bast, R. C., B. A. Simpson, and H. F. Dvorak. 1971. Heterogeneity of the cellular immune response. II. The role of adjuvant. Lymphocyte stimulation in cutaneous basophil hypersensitivity. *J. Exp. Med.* **133**:202.
23. Dvorak, H. F., and M. C. Mihm, Jr. 1972. Basophilic leukocytes in allergic contact dermatitis. *J. Exp. Med.* **135**:235.
24. Rapp, H. J., W. H. Churchill, Jr., B. S. Kronman, R. T. Rolley, W. G. Hammond, and T. Borsos. 1968. Antigenicity of a new diethylnitrosamine-induced trans-



- plantable guinea pig hepatoma. Pathology and formation of ascites variant. *J. Natl. Cancer Inst.* **41**:1.
25. Kronman, B. S., H. T. Wepsic, W. H. Churchill, Jr., B. Zbar, T. Borsos, and H. J. Rapp. 1970. Immunotherapy of cancer. An experimental model in syngeneic guinea pigs. *Science (Wash. D.C.)*. **168**:257.
  26. Zbar, B., I. D. Bernstein, and H. J. Rapp. 1971. Suppression of tumor growth at the site of infection with living *Bacillus Calmette-Guerin*. *J. Natl. Cancer Inst.* **46**:831.
  27. Bauer, J. A., Jr. 1960. Genetics of skin transplantation and estimate of the number of histocompatibility genes in inbred guinea pigs. *Ann. N. Y. Acad. Sci.* **87**:78.
  28. Karnovsky, M. J. 1967. The ultrastructural basis of capillary permeability studied with peroxidase as a tracer. *J. Cell Biol.* **35**:213.
  29. Farquhar, M. G., and G. E. Palade. 1965. Cell junction in amphibian skin. *J. Cell Biol.* **26**:263.
  30. Karnovsky, M. J. 1971. Use of ferrocyanide-reduced osmium tetroxide in electron microscopy. *In* Abstracts of the 11th Annual Meeting of the American Society of Cell Biology, New Orleans. 146.
  31. Dvorak, A. M., M. E. Hammond, H. F. Dvorak, and M. J. Karnovsky. 1972. Loss of cell surface material from peritoneal exudate cells associated with lymphocyte-mediated inhibition of macrophage migration from capillary tubes. *Lab. Invest.* **27**:561.
  32. Lowell, F. C. 1967. Clinical aspects of eosinophilia in atopic disease. *J. Am. Med. Assoc.* **202**:875.
  33. Dvorak, A. M., H. F. Dvorak, and M. J. Karnovsky. 1972. Uptake of horseradish peroxidase by guinea pig basophilic leukocytes. *Lab. Invest.* **26**:27.
  34. Terry, R. W., D. F. Bainton, and M. G. Farquhar. 1969. Formation and structure of specific granules in basophilic leukocytes of the guinea pig. *Lab. Invest.* **21**:65.
  35. Black, M. M., and H. P. Leis, Jr. 1971. Cellular responses to autologous breast cancer tissue. *Cancer*. **28**:263.
  36. Dvorak, H. F., and A. M. Dvorak. 1972. Basophils, mast cells, and cellular immunity in animals and man. *Hum. Pathol.* **3**:454.