

Red urine and a red herring – diagnosing rare diseases in the light of the COVID-19 pandemic

Roter Harn und eine falsche Fährte – Diagnose seltener Erkrankungen im Lichte der COVID-19-Pandemie



Authors

Philipp Jud¹, Gerald Hack², Alexander Christian Reisinger², Angela Horvath^{3,4}, Philipp Eller², Vanessa Stadlbauer^{3,4}

Affiliations

- 1 Department of Angiology, Medical University of Graz (31475), Graz, Austria
- 2 Intensive Care Unit, Medical University of Graz (31475), Graz, Austria
- 3 Department of Gastroenterology and Hepatology, Medical University of Graz (31475), Graz, Austria
- 4 CBMed Center of Biomarker Research, Graz, Austria

Schlüsselwörter

COVID-19, Porphyrie, seltene Erkrankungen

Key words

COVID-19, porphyria, rare diseases

received 12.06.2021

accepted 13.09.2021

published online 12.11.2021

Bibliography

Z Gastroenterol 2022; 60: 1326–1331

DOI 10.1055/a-1659-4481

ISSN 0044-2771

© 2021. The Author(s).

This is an open access article published by Thieme under the terms of the Creative Commons Attribution-NonDerivative-NonCommercial-License, permitting copying and reproduction so long as the original work is given appropriate credit. Contents may not be used for commercial purposes, or adapted, remixed, transformed or built upon. (<https://creativecommons.org/licenses/by-nc-nd/4.0/>).

Georg Thieme Verlag KG, Rüdigerstraße 14,
70469 Stuttgart, Germany

Correspondence

Vanessa Stadlbauer
Medical University of Graz
Department of Gastroenterology and Hepatology,
Auenbruggerplatz 15, 8010 Graz, Austria
vanessa.stadlbauer@medunigraz.at

ABSTRACT

Background The COVID-19 pandemic has occupied the time and resources of health care professionals for more than 1 year. The risk of missed diagnoses has been discussed in the medical literature, mainly for common diseases such as cancer and cardiovascular events. However, rare diseases also need appropriate attention in times of a pandemic.

Case Report We report a 34-year-old woman with fever, pinprick sensation in her chest and thoracic spine, and dizziness after receiving the first dose of ChAdOx1 nCoV-19 vaccination. The patient's condition worsened with abdominal pain, red urine, and hyponatremia, needing intensive care admission. Syndrome of inappropriate antidiuretic hormone secretion (SIADH) was diagnosed. Vaccine-induced thrombocytopenia and thrombosis were ruled out. Acute hepatic porphyria was finally diagnosed, and the patient recovered completely after treatment with hemin.

Conclusion Currently, the focus of physicians is on COVID-19 and associated medical problems, such as vaccine side effects. However, it is important to be vigilant for other uncommon medical emergencies in medically exceptional situations that may shift our perception.

ZUSAMMENFASSUNG

Hintergrund Die COVID-19-Pandemie beansprucht seit mehr als einem Jahr Zeit und Ressourcen von Angehörigen der Gesundheitsberufe. Kollateralschäden infolge verspäteter Diagnosen wurden in der medizinischen Literatur hauptsächlich für Volkskrankheiten wie Krebs und kardiovaskuläre Ereignisse diskutiert. Aber auch seltene Krankheiten bedürfen in Zeiten einer Pandemie der entsprechenden Aufmerksamkeit.

Fallbericht Wir berichten über eine 34-jährige Frau mit Fieber, Parästhesien in Brust und Brustwirbelsäule und Schwindel nach der ersten Dosis der ChAdOx1-nCoV-19-Impfung. Der Zustand der Patientin verschlechterte sich mit Bauchschmerzen, rotem Urin und Hyponatriämie und sie musste intensivmedizinisch behandelt werden. Es wurde ein Syndrom der inadäquaten Sekretion des antidiuretischen Hormons (SIADH) diagnostiziert. Eine Vakzin-induzierte Thrombozytopenie und Thrombose wurde ausgeschlossen. Schließlich wurde eine akute hepatische Porphyrie diagnostiziert und die Patientin erholte sich nach Behandlung mit Hämin vollständig.

Fazit Aktuell liegt der Fokus der Mediziner*innen auf COVID-19 und den damit verbundenen medizinischen Problemen, wie zum Beispiel Impfnebenwirkungen. Es ist jedoch wichtig, in medizinisch außergewöhnlichen Situationen auf andere seltene medizinische Notfälle zu achten, die unsere Wahrnehmung verändern können.

Introduction

The COVID-19 pandemic has kept the medical world on edge for more than a year. While the pandemic undoubtedly has direct implications for infected patients and families, as well as broad social and economic consequences, there is also a need to examine the pandemic's effect on patients with non-COVID-19-related diseases. Warnings have been issued that collateral damages from the pandemic may occur due to delayed diagnoses. Evidence is accumulating that common life-threatening diseases, such as cardiovascular diseases and cancer, may experience a delay in diagnosis and treatment during the pandemic [1, 2]. People suffering from rare diseases, defined as diseases affecting fewer than 5 per 10000 people, are already a vulnerable patient group during "normal" times. Although individually rare, collectively, 6–8% of the European population suffer from rare diseases [3]. These patients often undergo several diagnostic tests, have multiple visits to different specialists, and receive a conclusive diagnosis only after a long period [4].

Data from Hong Kong suggest that the COVID-19 pandemic impacts early diagnosis and appropriate management of rare diseases and resource utilization; it also affects the physical and mental well-being of people suffering from rare diseases [5].

In early 2021, an additional variable came into the equation: COVID-19 vaccines and their serious adverse events, including possible fatal thromboembolic side effects [6]. Of the currently approved vaccines against COVID-19, the administration of the ChAdOx1 nCoV-19 vaccine has been associated with vaccine-induced immune thrombotic thrombocytopenia (VITT) and concomitant thromboembolic events, also in unusual anatomical locations including cerebral venous sinus, splanchnic veins, or portal veins [7, 8, 9].

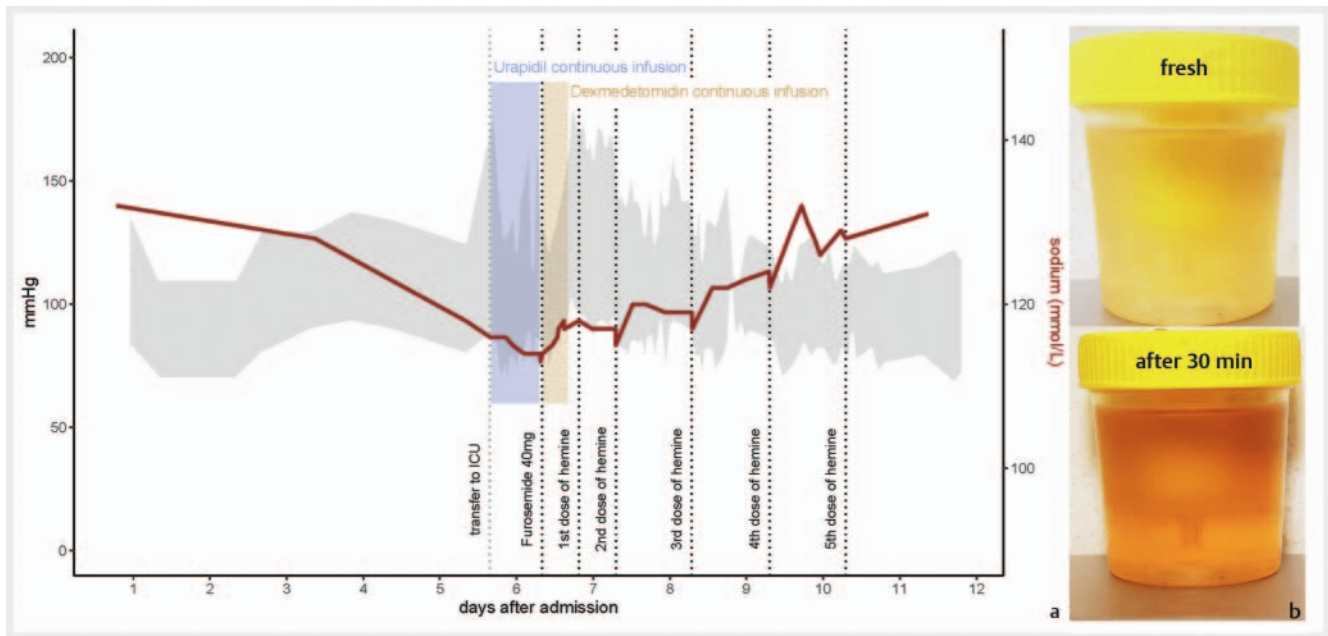
Case report

A 34-year-old physiotherapist presented to the emergency department 4 days after receiving the first dose of ChAdOx1 nCoV-19 vaccination with a fever that resolved after 3 doses of 500 mg of paracetamol within 12 hours, pinprick sensations in her chest and thoracic spine, and dizziness. The patient's medical history included Hashimoto thyroiditis under thyroid hormone therapy and an appendectomy 11 years ago; histology showed ulcero-phlegmonous appendicitis. Vital signs (blood pressure 115/70 mmHg, heart rate 80 beats per minute, temperature 35.6 °C, peripheral oxygen saturation 100% at ambient air) were uneventful; clinical examination, electrocardiography, and chest x-ray showed no pathological findings. Laboratory analysis revealed a slightly elevated serum creatinine of 1.01 mg/dL (normal range 0.5–0.9), mild thrombocytopenia of 142 G/L (normal range 150–370), and a slightly decreased serum sodium of 134 mmol/L (normal range 135–145). D-dimer and cardiac enzymes were unremarkable. The patient received 1 g metamizole intravenously and was discharged to home with resolved symptoms after an observation period of 5 hours. Sixteen hours later, she presented again with additional lower abdominal pain, vomiting, and loose stools. Laboratory findings and a clinical examination were again unremark-

able. Focused abdominal sonography and a plain abdominal film showed no abnormalities. After an overnight observation period and supportive treatment with metamizole, butylscopolamine bromide, and crystalloid fluid intravenously, she was discharged home but presented again to our emergency department on the same day. She reported that her urine had turned red, and her dizziness had worsened. Laboratory evaluation revealed progressive thrombocytopenia (128 G/L) and hyponatremia (128 mmol/l), while fibrinogen and D-dimer were unremarkable. Urine dipstick was highly positive for bilirubin, hemoglobin, and ketoacids with only slight microhematuria. The patient additionally reported that she had followed a "low-carb" diet for a few days in an attempt to lose weight (body mass index 25.6 kg/m²). A pregnancy test was negative, and a gynecological examination was inconspicuous. An abdominal CT was performed to exclude potential VITT and thrombosis of the splanchnic veins, revealing no thrombosis or other pathologies. She was admitted for further observation and supportive therapy. On the next day, the patient reported pollakisuria and dysuria in addition to lower abdominal pain; a urine dipstick was positive for nitrite. Urinary tract infection was suspected, and antibiotic therapy with single-shot fosfomycin (3 g) was administered. The patient claimed progressive weakness, needing help with walking, and reported progressive lower abdominal pain. As metamizole did not adequately improve the pain, piritramide was prescribed. The patient could not eat full meals due to pain and therefore received oral nutritional supplements in the hospital. The patient's description of pain was remarkable: a sensation of a burning ball that exploded in her pelvis.

Progressive hyponatremia and hypertension were noticed over the weekend, and the patient was subsequently admitted to ICU. Syndrome of inappropriate antidiuretic hormone secretion (SIADH) was diagnosed based on euvolemic state with reduced serum osmolality (243 mosm/kg [normal range 280–300]), a high urinary osmolality (479 mosm/kg [normal range 50–120]) and urinary sodium (177 mmol/L), and adequate thyroid function. Therefore, the patient received fluid restriction and furosemide as symptomatic treatment of SIADH. Hypertension required treatment with continuous infusion of urapidil for several hours (► **Table 1**).

The reddening of urine already noticed in the emergency department had triggered a porphyria diagnosis; however, the results were delayed due to the weekend and arrived when the patient was already in the ICU receiving treatment for SIADH. Porphyrins (13734.0 g/24 h [normal range 0.0–150.0]), 5-aminolevulinic acid (104.25 mg/24 h [normal range 0.25–6.40]) and porphobilinogen (58.80 mg/24 h [normal range 0.10–1.70]) were highly elevated in the urine. Therefore, the diagnosis of acute hepatic porphyria was made. Treatment with hemin 3 mg/kg body weight for 5 consecutive days was initiated, and all potentially prophyrogenic drugs were stopped and replaced by safe alternatives. We chose to give hemin for 1 additional day because of the severity of symptoms at the start of treatment. Initiation of hemin was followed by the rapid improvement of the patient's blood pressure and hyponatremia (► **Fig. 1A**). Also, her abdominal pain improved rapidly over the next few days, leading to a rapid reduction in the need for pain medication. She was discharged from ICU with nearly normalized serum sodium and without ab-



► **Fig. 1A** Blood pressure and serum sodium during the hospitalization in relation to medication. After transfer to ICU Urapidil, continuous infusion was necessary for blood pressure control. Dexmedetomidin was administered overnight for sedation. Before the diagnosis of porphyria was made on day 7 of the hospital stay, the patient also received potentially unsafe drugs for porphyria. **B** Urine of the patient at asymptomatic state (fresh and after 30 minutes of daylight exposure). Darkening of urine in acute hepatic porphyrias is due to the accumulation of porphyrins and/or porphobilin in the urine.

► **Table 1** Laboratory findings during hospitalization.

Parameter	Unit	Normal range	Hospital admission	ICU admission	ICU discharge	Follow up
White blood count	G/L	4.4–11.3	3.99	9.59	6.16	5.38
Hemoglobin	G/L	12.0–15.3	12.6	13.1	12.3	11.3
Platelets	G/L	150–370	128	223	219	216
Creatinine	mg/dL	0.5–0.9	1.01	0.93	0.74	0.84
Serum osmolality	mosm/kg	280–300	–	243	–	–
Serum sodium	mmol/L	135–145	128	116	131	138
Porphyrins	g/24 h	0–150	13,734.0	–	402.7	–
5-aminolevulinic acid	mg/24 h	0.25–6.40	104.25	–	2.21	–
Porphobilinogen	mg/24 h	0.10–1.70	58.80	–	5.12	–

dominal pain, but she reported residual dysesthesia in her legs which gradually improved over the following weeks. At ICU discharge, urinary porphyrins (402.7 g/24 h), 5-aminolevulinic acid (2.21 mg/24 h), and porphobilinogen (5.12 mg/24 h) were markedly improved. Despite these low levels of porphyrins in urine, urine changed to a red-orange color after 30 minutes of exposure to daylight (► **Fig. 1B**).

Further analysis of porphyrins in feces and genetic analysis confirmed the diagnosis of acute intermittent porphyria. The most likely trigger of the disease was the “low-carb” ketogenic diet the

patient initiated a few days before symptom onset. The patient received counseling on avoiding porphyrinogenic drugs based on the NAPOS list (<http://www.drugs-porphyrin.org>) and carbohydrate restriction to prevent further acute attacks. No further attacks occurred in the observation period of the subsequent 5 months.

Discussion

During clinical decision-making, the focus may be diverted to COVID-19 disease and associated medical problems, such as vac-

cine-related side effects, while “classic” rare diseases may be overlooked. We report the case of a 34-year patient with her first attack of acute hepatic porphyria most likely triggered by the initiation of a “low-carb” ketogenic diet in the attempt to lose weight. Additionally, the patient received vaccination against COVID-19 a few days before symptom onset. In our case, the patient was fully explored regarding VITT, including several blood tests and a CT scan of the abdomen.

Side effects of ChAdOx1 nCoV-19 vaccination include fatigue, myalgia, or fever, while serious side effects like allergic reactions and VITT may also occur [10]. Increasing venous thromboembolism and VITT rates have been described in 18–65-year-old recipients of ChAdOx1 nCoV-19 vaccination. The underlying pathway contributing to VITT may be comparable to autoimmune heparin-induced thrombocytopenia contributed by platelet factor 4-polyanion complexes [7, 8, 9]. In our case, vaccine-induced thrombosis of the splanchnic veins, which was suspected due to initial progressive thrombocytopenia and symptom progression, was quickly ruled out by negative d-dimers, absent evidence of splanchnic thrombosis on CT scan, and finally by spontaneous recovery of thrombocytopenia. However, the patient’s symptoms could not be explained after the initial diagnostic checkup and even worsened, leading to further exploration.

Acute pain is the cardinal symptom of acute hepatic porphyria, but management and pain assessment have been poorly studied in these patients. Pain during an attack is usually severe enough to require opioid analgesics. Mild pain can be treated with acetaminophen [11], while metamizole is a potentially porphyrogenic drug [12]. In our case, the patient described the pain in a unique way and required treatment with opioid analgesics. The description that her urine had a reddish color was the trigger to initiate the diagnosis of acute hepatic porphyria; however, the likelihood of this diagnosis was first considered low. In our patient, a urine dipstick positive for nitrite together with pollakisuria, dysuria, and lower abdominal pain, led to the much more likely suspicion of a urinary tract infection in a young woman [13]. However, autonomous bladder dysfunction with dysuria may also be symptoms of acute hepatic porphyria [14]. Tachycardia and hypertension in acute hepatic porphyria may be signs of the affection of the autonomous nervous system or may be secondary to acute pain; in our patient, blood pressure increases corresponded with pain attacks, but hypertension also required continuous intravenous therapy over several hours in addition to opioid analgesics. As in our patient, nausea and vomiting also often accompany abdominal pain in acute hepatic porphyria and may be caused by visceral neuropathy [14].

The most dangerous symptom in our patient was progressive hyponatremia. In patients with hyponatremia, hydration status, serum, and urine osmolality, as well as urine sodium, should be investigated to allow for differential diagnoses. Mild to severe hyponatremia occurs in 25–60 % of cases during an acute porphyria attack, and hyponatremia is also a marker of the severity of the attack [15]. SIADH is the pathophysiological basis for hyponatremia in acute hepatic porphyria. The etiology of SIADH during attacks of acute hepatic porphyria is multifactorial: abdominal pain

is a stimulus for the synthesis of ADH. The excess of ADH acts on the V1a receptors of the vasculature, increasing peripheral resistance and raising central blood pressure, and on the renal V2 receptors, preventing the kidney from adequately eliminating any water overload. Acute attacks are also frequently accompanied by paralytic ileus that causes intestinal sequestration of water and electrolytes, which, in turn, stimulates the secretion of angiotensin II. The third ventricle is equipped with receptors for angiotensin II, which directly stimulate ADH secretion [15].

Treatment of SIADH in acute hepatic porphyria is based on 2 pillars: general treatment of SIADH and specific therapy of acute hepatic porphyria. General treatment of SIADH includes fluid restriction and loop diuretics [16, 17]. Tolvaptan is also considered to be useful in SIADH caused by acute hepatic porphyria [15]. Specific treatment of an acute hepatic porphyria attack is facilitated with intravenous hemin (3 mg/kg body weight per day, dissolved in albumin, for 4 consecutive days) [18] that is taken up into hepatocytes and represses synthesis of the first enzyme in the heme biosynthetic pathway, delta-aminolevulinic acid synthase. This decreases the accumulation of heme precursors and their byproducts, as documented by rapid and dramatic reductions in plasma and urinary porphobilinogen and delta-aminolevulinic acid. Although large randomized controlled trials are lacking, evidence is strong that hemin is effective and safe as an immediate therapeutic agent in acute hepatic porphyria [19]. When hemin is unavailable, carbohydrate loading through intravenous glucose administration can be used as a temporary measure until hemin is available. Glucose and other carbohydrates reduce the excretion of porphyrin precursors by downregulating hepatic delta-aminolevulinic acid synthase, an effect mediated by decreases in the peroxisome proliferator-activated receptor-gamma coactivator 1-alpha. However, the effect of glucose is weak compared to the effect of hemin [20]. In addition, intravenous glucose can cause and aggravate hyponatremia and therefore would not have been feasible in our patient [15]. Very recently, the RNA interference (RNAi) therapy Givosiran, which reduces the annualized attack rate by 74 %, became available for patients with recurrent attacks [21, 22].

Early diagnosis of acute hepatic porphyria is important for the outcome of the disease. Attacks are less severe and have a lower risk for ICU admission in patients already diagnosed with porphyria as treatment is usually initiated earlier, and triggers are consistently avoided [23]. However, the delay between symptom onset and diagnosis may be delayed for several years—a mean delay of 15 years was reported in a cohort from the USA. [24] Under exceptional circumstances, such as during the current COVID-19 pandemic but also during other situations such as a heatwave, a political conflict, or even during a football game, [25] the perception of medical professionals may (but of course should not) be shifted, leading to misdiagnosis. Novel approaches, such as machine learning and knowledge engineering, can be helpful to mitigate illusory correlations and metacognition errors in medicine, especially in the emergency medicine setting [26], and detect rare diseases in electronic patient records [27].

Conclusion

We managed to diagnose acute hepatic porphyria in a young woman at her first attack. It is important to be vigilant and not to forget other common but also uncommon disorders, such as acute hepatic porphyria, as a rare trigger of SIADH [28] and potentially life-threatening disease during the current challenges of the pandemic. The European Porphyria Network (EPNET, www.porphyrria.net) issued a statement that “as with all other vaccines, the COVID-19 vaccines carry no additional risk in acute porphyria, and we recommend that people with acute intermittent porphyria, porphyria variegata or hereditary coproporphyrin accept vaccination when this is offered” [29]. Although the COVID-19 vaccination, especially in combination with a ketogenic diet, cannot be completely excluded as a trigger for the acute porphyria attack, we believe that it was a “red herring” in our case.

Ethical Approval and Consent to participate

Not applicable (Case report)

Consent for publication

The patient gave written consent to this publication.

Availability of supporting data

The dataset used and/or analyzed during the current study is available from the corresponding author on reasonable request.

Authors' contributions

PJ, GH, ACR, PE, and VS were involved in patient management. All authors provided critical intellectual content to the manuscript. AH and VS created the visualization. All authors approved the final manuscript.

Conflict of Interest

The authors declare that they have no conflict of interest.

References

- [1] Kiss P, Carcel C, Hockham C et al. The impact of the COVID-19 pandemic on the care and management of patients with acute cardiovascular disease: a systematic review. *Eur Heart J Qual Care Clin Outcomes* 2021; 7: 18–27. doi:10.1093/ehjqcco/qcaa084
- [2] Sud A, Jones ME, Broggio J et al. Collateral damage: the impact on outcomes from cancer surgery of the COVID-19 pandemic. *Ann Oncol* 2020; 31: 1065–1074. doi:10.1016/j.annonc.2020.05.009
- [3] Taruscio D, Vittozzi L, Stefanov R. National plans and strategies on rare diseases in Europe. *Adv Exp Med Biol* 2010; 686: 475–491. doi:10.1007/978-90-481-9485-8_26
- [4] Evans WR, Rafi I. Rare diseases in general practice: recognising the zebras among the horses. *Br J Gen Pract* 2016; 66: 550–551. doi:10.3399/bjgp16X687625
- [5] Chung CC, Wong WH, Fung JL et al. Impact of COVID-19 pandemic on patients with rare disease in Hong Kong. *Eur J Med Genet* 2020; 63: 104062. doi:10.1016/j.ejmg.2020.104062
- [6] Castelli GP, Pognani C, Sozzi C et al. Cerebral venous sinus thrombosis associated with thrombocytopenia post-vaccination for COVID-19. *Crit Care* 2021; 25: 137. doi:10.1186/s13054-021-03572-y
- [7] Pottegard A, Lund LC, Karlstad O et al. Arterial events, venous thromboembolism, thrombocytopenia, and bleeding after vaccination with Oxford-AstraZeneca ChAdOx1-S in Denmark and Norway: population based cohort study. *BMJ* 2021; 373: n1114. doi:10.1136/bmj.n1114
- [8] Greinacher A, Thiele T, Warkentin TE et al. Thrombotic thrombocytopenia after ChAdOx1 nCoV-19 vaccination. *N Engl J Med* 2021. doi:10.1056/NEJMoa2104840
- [9] Schultz NH, Sorvoll IH, Michelsen AE et al. Thrombosis and thrombocytopenia after ChAdOx1 nCoV-19 vaccination. *N Engl J Med* 2021. doi:10.1056/NEJMoa2104882
- [10] Ramasamy MN, Minassian AM, Ewer KJ et al. Safety and immunogenicity of ChAdOx1 nCoV-19 vaccine administered in a prime-boost regimen in young and old adults (COV002): a single-blind, randomised, controlled, phase 2/3 trial. *Lancet* 2021; 396: 1979–1993. doi:10.1016/S0140-6736(20)32466-1
- [11] Cardenas JL, Guerrero C. Acute intermittent porphyria: general aspects with focus on pain. *Curr Med Res Opin* 2018; 34: 1309–1315. doi:10.1080/03007995.2018.1435521
- [12] Silva CD, Mateus JE, Teles C et al. Acute intermittent porphyria: analgesia can be dangerous. *BMJ Case Rep* 2019; 12: doi:10.1136/bcr-2019-231133
- [13] Flores-Mireles AL, Walker JN, Caparon M et al. Urinary tract infections: epidemiology, mechanisms of infection and treatment options. *Nat Rev Microbiol* 2015; 13: 269–284. doi:10.1038/nrmicro3432
- [14] Anderson KE. Acute hepatic porphyrias: current diagnosis & management. *Mol Genet Metab* 2019; 128: 219–227. doi:10.1016/j.ymgme.2019.07.002
- [15] Solares I, Tejedor M, Jerico D et al. Management of hyponatremia associated with acute porphyria-proposal for the use of tolvaptan. *Ann Transl Med* 2020; 8: 1098. doi:10.21037/atm-20-1529
- [16] Verbalis JG, Goldsmith SR, Greenberg A et al. Diagnosis, evaluation, and treatment of hyponatremia: expert panel recommendations. *Am J Med* 2013; 126: S1–42. doi:10.1016/j.amjmed.2013.07.006
- [17] Cuesta M, Thompson CJ. The syndrome of inappropriate antidiuresis (SIAD). *Best Pract Res Clin Endocrinol Metab* 2016; 30: 175–187. doi:10.1016/j.beem.2016.02.009
- [18] Stolzel U, Doss MO, Schuppan D. Clinical guide and update on porphyrias. *Gastroenterology* 2019; 157: 365–381 e364. doi:10.1053/j.gastro.2019.04.050
- [19] Mustajoki P, Nordmann Y. Early administration of heme arginate for acute porphyric attacks. *Arch Intern Med* 1993; 153: 2004–2008
- [20] Anderson KE, Bloomer JR, Bonkovsky HL et al. Recommendations for the diagnosis and treatment of the acute porphyrias. *Ann Intern Med* 2005; 142: 439–450. doi:10.7326/0003-4819-142-6-200503150-00010
- [21] Balwani M, Sardh E, Ventura P et al. Phase 3 trial of RNAi therapeutic Givosiran for acute intermittent porphyria. *N Engl J Med* 2020; 382: 2289–2301. doi:10.1056/NEJMoa1913147
- [22] Gouya L, Ventura P, Balwani M et al. EXPLORE: A prospective, multinational, natural history study of patients with acute hepatic porphyria with recurrent attacks. *Hepatology* 2020; 71: 1546–1558. doi:10.1002/hep.30936
- [23] Edell Y, Mamet R, Cohen S et al. The clinical importance of early acute hepatic porphyria diagnosis: a national cohort. *Intern Emerg Med* 2021; 16: 133–139. doi:10.1007/s11739-020-02359-3
- [24] Bonkovsky HL, Maddukuri VC, Yazici C et al. Acute porphyrias in the USA: features of 108 subjects from porphyrias consortium. *Am J Med* 2014; 127: 1233–1241. doi:10.1016/j.amjmed.2014.06.036

- [25] Wilbert-Lampen U, Leistner D, Greven S et al. Cardiovascular events during World Cup soccer. *N Engl J Med* 2008; 358: 475–483. doi:10.1056/NEJMoa0707427
- [26] Kirubarajan A, Taher A, Khan S et al. Artificial intelligence in emergency medicine: a scoping review. *J Am Coll Emerg Physicians Open* 2020; 1: 1691–1702. doi:10.1002/emp2.12277
- [27] Cohen AM, Chamberlin S, Deloughery T et al. Detecting rare diseases in electronic health records using machine learning and knowledge engineering: case study of acute hepatic porphyria. *PLoS One* 2020; 15: e0235574. doi:10.1371/journal.pone.0235574
- [28] Ventura P, Cappellini MD, Biolcati G et al. A challenging diagnosis for potential fatal diseases: recommendations for diagnosing acute porphyrias. *Eur J Intern Med* 2014; 25: 497–505. doi:10.1016/j.ejim.2014.03.011
- [29] COVID-19 and Porphyria: COVID-19 vaccine safety. <https://porphyria.eu>