

Early myocardial oedema can predict subsequent cardiomyopathy in high-dose anthracycline therapy

Fabian Muehlberg^{1*}, Markus Kornfeld¹, Leonora Zange¹, Saeed Ghani², Annette Reichardt¹, Peter Reichardt¹ and Jeanette Schulz-Menger¹

¹Working Group on Cardiovascular Magnetic Resonance, Experimental and Clinical Research Center – a joint cooperation between the Charité Medical Faculty and the Max-Delbrück Center for Molecular Medicine; and HELIOS Hospital Berlin Buch, Department of Cardiology and Nephrology, DZHK (German Center for Cardiovascular Research) partner site, Berlin, Germany; and ²Department for Interdisciplinary Oncology and Sarcoma Center, HELIOS Hospital Berlin-Buch, Berlin, Germany

Abstract

Aims This study aims to assess subclinical changes in functional and morphologic myocardial MR parameters very early into a repetitive high-dose anthracycline treatment (planned cumulative dose >650 mg/m²), which may predict subsequent development of anthracycline-induced cardiomyopathy (aCMP).

Methods Thirty sarcoma patients with previous exposition of 300–360 mg/m² doxorubicin-equivalent chemotherapy who were planned for a second treatment of anthracycline-based chemotherapy (360 mg/m² doxorubicin-equivalent) were recruited. Enrolled individuals received three CMR studies (before treatment, 48 h after first anthracycline treatment and upon completion of treatment). Native T1 mapping (MOLLI 5s(3s)3s), T2 mapping, and extracellular volume (ECV) maps were acquired in addition to a conventional CMR with SSFP-cine imaging at 1.5 T. Patients were given 0.2 mmol/kg gadoteridol for ECV quantification and LGE imaging. Blood samples for cardiac biomarkers were obtained before each scan. Development of relevant aCMP was defined as drop of left ventricular ejection fraction (LVEF) by $>10\%$ compared with baseline.

Results Twenty-three complete datasets were available for analysis. Median treatment time was 20.7 ± 3.0 weeks. Eight patients developed aCMP with LVEF reduction $>10\%$ until end of chemotherapy. Baseline LVEF was not different between patients with and without subsequent aCMP. Patients with aCMP had decreased LV mass upon completion of therapy (99.4 ± 26.5 g vs. 90.3 ± 24.8 g; $P = 0.02$), whereas patients without aCMP did not show a change in LV mass (91.5 ± 20.0 g vs. 89.0 ± 23.6 g; $P > 0.05$). On strain analysis, GLS (-15.3 ± 1.3 vs. -13.4 ± 1.6 ; $P = 0.02$) and GCS (-16.7 ± 2.1 vs. -14.9 ± 2.6 ; $P = 0.04$) were decreased in aCMP patients upon completion of therapy, whereas non-aCMP individuals showed no change in GLS (-15.4 ± 3.3 vs. -15.4 ± 3.4 ; $P = 0.97$). When assessed 48 h after first dose of anthracyclines, patients with subsequent aCMP had significantly elevated myocardial T2 times compared with before therapy (53.0 ± 2.8 ms vs. 49.3 ± 5.2 ms, $P = 0.02$) than patients who did not develop aCMP (50.7 ± 5.1 ms vs. 51.1 ± 3.9 ms, $P > 0.05$). Native T1 times decreased at 48 h after first dose irrespective of development of subsequent aCMP (1020.2 ± 28.4 ms vs. 973.5 ± 40.3 ms). Upon completion of therapy, patients with aCMP had increased native T1 compared with baseline (1050.8 ± 17.9 ms vs. 1022.4 ± 22.0 ms; $P = 0.01$), whereas non-aCMP patients did not (1034.5 ± 46.6 ms vs. 1018.4 ± 29.7 ms; $P = 0.15$). No patient developed new myocardial scars or compact myocardial fibrosis under chemotherapy. Cardiac biomarkers were elevated independent of development of aCMP.

Conclusions With high cumulative anthracycline doses, early increase of T2 times 48 h after first treatment with anthracyclines can predict the development of subsequent aCMP after completion of chemotherapy. Early drop of native T1 times occurs irrespective of development of aCMP in high-dose anthracycline therapy.

Keywords anthracyclines; cardiomyopathy; mapping; cardio-oncology; MRI; cardiotoxicity

Received: 27 April 2022; Revised: 6 October 2022; Accepted: 7 November 2022

*Correspondence to: Muehlberg, Fabian, Working Group on Cardiovascular Magnetic Resonance, Experimental and Clinical Research Center – a joint cooperation between the Charité Medical Faculty and the Max-Delbrück Center for Molecular Medicine; and HELIOS Hospital Berlin Buch, Department of Cardiology and Nephrology, DZHK (German Center for Cardiovascular Research) partner site, Berlin, Germany. Email: fabian.muehlberg@helios-kliniken.de

Introduction

In many cancer therapies, anthracyclines remain the mainstay of treatment, especially in breast cancer, lymphoma, and most soft tissue sarcoma.^{1,2}

As a result of significantly improved outcomes in patients with these malignancies over the last decades, the importance of long-term side effects of chemotherapy has drastically increased.³

Anthracyclines frequently have cardiotoxic side effects, which are known to be dose dependent. Heart failure due to anthracyclines occurs in up to 30% of patients and has severe prognostic implications as it can lead to mortality rates worse than that associated with many malignancies.^{4,5}

There is no single universally accepted definition or categorization of cardiotoxicity by anthracyclines. Several types of anthracycline-induced cardiomyopathy (aCMP) that are categorized according to timing of onset of cardiac dysfunction into acute (days after start of chemotherapy), early-onset (months after start of chemotherapy) and late-onset aCMP (years after completion of chemotherapy).⁶ In this study, we focused on development of early-onset aCMP.

With increasing knowledge of aCMP, chemotherapy courses typically contain a low to moderate cumulative dose of anthracyclines today. However, many malignancies—such as soft tissue sarcoma—have finite options for subsequent therapy lines. The repetition of an efficient therapy line comprises an important therapeutic principle in the treatment of recurrent or metastatic disease. In these patients, the careful balance between beneficial anti-cancer and harming cardiotoxic effects is often hard to maintain. Clinical guidelines and consensus statements of major cardiology and oncology societies on prevention and treatment of anthracycline-induced cardiomyopathy concentrate on serial screening for LVEF reduction before, during and after chemotherapy.^{7–9} This strategy identifies patients only after development of clinically overt heart failure and therefore in a late stage of the cardiotoxic cascade. There is currently no tool for prediction of cardiotoxicity before or early into the treatment in these high-risk patients. Hence, many patients with potential benefit from repetitive, high-dose anthracycline therapy are withheld from treatment due to safety concerns.

Cardiovascular magnetic resonance (CMR) is a non-invasive imaging technique that allows thorough myocardial tissue differentiation. Myocardial T1 and T2 mapping are promising techniques in this regard as they enable quantitative assessment of diffuse myocardial tissue alteration through a pixel-wise analysis approach.^{10,11}

In a previous study, we investigated the role of CMR in patients with low to moderate cumulative dose of anthracyclines (<360 mg/m² doxorubicin-equivalent).¹² We found that in previously untreated patients, the first dose of anthracyclines leads to a substantial decrease of native

myocardial T1 times at 48 h after first application in those patients who developed subsequent aCMP upon completion of the entire course of chemotherapy. Patients without development of aCMP did not show this early T1 drop.

However, given the complex and dose-dependent mechanism of aCMP, the observed phenomenon may not be applicable in the setting of high-cumulative doses in patients with repetitive anthracycline treatments.

Accordingly, the purpose of the present study was to assess the predictive value of parametric mapping techniques for detection of acute effects of anthracyclines on cardiac tissue in sarcoma patients who have had a previous course of anthracycline-based chemotherapy and who were planned for another course of anthracyclines.

We hypothesized that—given the previous exposure to moderate anthracycline doses—the cardiotoxic mechanism may lead to a different myocardial phenotype compared with previously untreated patients.

Methods

Study population

A total of 30 patients were prospectively recruited between January 2016 and November 2019. All patients had histologically confirmed soft tissue sarcoma, had a previous course of anthracycline-based chemotherapy with a cumulative doxorubicin-equivalent dose of 360–400 mg/m², and were planned for a second course of anthracycline-based chemotherapy, leading to a total cumulative dose of 720–800 mg/m². As per standard in-house protocol, patients received a cardioprotective treatment with 500 mg/m² dexrazoxane before each anthracycline application.

Exclusion criteria were chronic renal failure (glomerular filtration rate <30 mL/m²), cardiac metastases, known incompatibility for gadolinium contrast media and contraindication for magnetic resonance imaging. All enrolled individuals were approved by the local ethical review board and gave written informed consent before participation.

CMR protocol

All study participants underwent three CMR scans of approximately 40 min each on a 1.5-T Siemens AvantoFit® scanner (Siemens Healthineers, Erlangen, Germany) with a 32-channel phased array coil. The first CMR scan was performed within 48 h before start of anthracycline treatment (baseline CMR), the second scan 48 h after the first anthracycline treatment was administered, and the third scan 4 weeks after the last anthracycline. Participants received 0.2 mmol/kg of gadoteridol contrast agent (ProHance®, Bracco Diagnostics, Princeton, NJ) during each scan. All

imaging sequences were performed according to previously published techniques.¹² Left ventricular (LV) and right ventricular (RV) volumetric and functional parameters were assessed in long and short-axis steady-state free precession cine sequences. Cine imaging parameters included field of view (FOV) 340 mm, voxel size $1.8 \times 1.8 \times 7 \text{ mm}^3$, 3 mm gap, echo time (TE) 1.2 ms, repetition time (TR) 33.4 ms, flip angle 74° , bandwidth 930 Hz.

T1 mapping was performed using a modified Look-Locker inversion recovery (MOLLI) sequence in a mid-ventricular short-axis slice before and 15 min after contrast administration. Sequence parameters: native T1: 5s(3s)3s with FOV 360 mm, voxel size $1.6 \times 1.6 \times 7 \text{ mm}^3$, TE 1 ms, TR 339.4 ms, flip angle 35° , bandwidth 1063 Hz; post-contrast: 4s(1s)3s(1s)2s with FOV 360 mm, voxel size $1.6 \times 1.6 \times 7 \text{ mm}^3$, TE 1 ms, TR 419.4 ms, flip angle 35° , bandwidth 1063 Hz.

Motion-corrected T2 mapping was performed using an established T2 prepared steady-state free precession technique (three single-shot images with T2 preparation times of 0/24/55 ms and voxel size of $1.6 \times 1.6 \times 6.0 \text{ mm}$).¹³

Late gadolinium enhancement was used for focal fibrosis imaging and performed in the same slice positions as cine imaging using a gradient echo-based segmented phase-sensitive inversion recovery sequence in single-slice, single-breathhold fashion. LGE scan parameters: FOV 380 mm, voxel size $1.8 \times 1.8 \times 7 \text{ mm}$, no interslice gap, TE 1 ms, TR 700 ms, flip angle 65° , bandwidth 1184 Hz.

Image analysis

Experienced readers with at least 3 years of experience in CMR analysis in a centre with 3.000 scans per year were blinded to clinical patient information. All image analysis was performed using cvi42® post-processing software version 4.2 (Circle Cardiovascular Imaging Inc., Calgary, Canada). LV and RV size and function as well as LV mass were assessed in short-axis cine images; atrial volumes were assessed monoplanar (right atrium) or biplanar (left atrium) in long-axis cine four-chamber and two-chamber views.

Epicardial and endocardial contours in a mid-ventricular short-axis slice were traced for T1 and T2 mapping analysis, and a 5% safety margin was applied endocardial and epicardial to minimize partial volume effects. Both T2 and T1 maps were quantified as average global values in the analysed slice as previously reported.¹² Visual surveys were evaluated for artefacts before quantification and segments with relevant artefacts were excluded from analysis (e.g. caused by susceptibility, unintended motion effects or incorrect motion correction).

Relative and absolute extracellular volume (ECV) fraction were calculated by means of native and post-contrast T1 values as previously established.¹¹ Relative ECV was reported

as per cent of myocardial volume of the corresponding short axis plane, absolute ECV in gram extrapolated towards LV mass.

Visual evaluation of LGE images was performed by two independent readers and included presence, location and transmural of identified lesions. Differentiation of real LGE lesions from artefacts was realized during image acquisition by verification in two perpendicular slices or altered readout direction.

Strain analysis was performed as feature tracking analysis was performed retrospectively as published before.¹⁴ Global longitudinal strain (GLS) and global circumferential strain (GCS) were assessed in three LAX views (4CV, 3CV, and 2CV) and SAX slices accordingly. Trabeculae, papillary muscles, pericardium, and epicardial fat were consequently excluded from contouring.

Interobserver and intraobserver variability analysis was performed on subsets of 10 subjects.

According to current guidelines, patients with LVEF drop of $>10\%$ points were defined as patients with aCMP. All other patients were defined non-aCMP patients for further analysis.

Laboratory blood analysis

Before each CMR scan, venous blood samples were. High-sensitivity cardiac troponin T concentrations were measured using the Elecsys® hsTNT STAT assay (Roche Diagnostics, Mannheim, Germany). The analytical limit of detection was 5 ng/L, and the 99th percentile upper reference limit was 14 ng/L.

Plasma N-terminal pro brain natriuretic peptide (NT-proBNP) concentrations were measured using the Elecsys® proBNP II assay (Roche Diagnostics). The analytical limit of detection of NT-proBNP was 5 pg/mL.

Statistical analysis

All measured values are shown as mean \pm standard deviation (SD). Statistical analysis was performed using SPSS Statistics 22.0.0 (IBM, Armonk, NY, USA). Using Wilcoxon signed-rank test, significant values were accepted by $P < 0.05$.

Univariate analysis for prediction of LVEF drop was done using two-sided t-test embedded into ANOVA analysis.

Univariate logistic regression analysis was performed to examine associations between CMR parameters and development of aCMP, and odds ratio (OR) and 95% confidence intervals (CI) were calculated.

Correlation analyses were performed using the Spearman rank correlation coefficients. To test for group differences of categorical variables, χ^2 -test was applied.

For intraobserver and interobserver reproducibility, images were analysed twice by blinded readers. The results were evaluated by intraclass-correlation coefficients.

Results

Patient characteristics

We initially recruited 30 patients. Seven individuals had to be excluded due to early study abort because of cardiac metastasis ($n = 1$), death after the first application of chemotherapy due to rapidly progressive disease ($n = 1$), individual wish ($n = 2$) or termination of anthracycline chemotherapy during the study due to progressive disease under treatment ($n = 3$). Accordingly, we had 23 complete datasets for analysis. Mean age of study cohort was 53.5 ± 12.0 years; 11 patients (48%) were female.

All individuals had previously been treated with 350 ± 32 mg/m² doxorubicin-equivalent chemotherapy. The time gap between this previous and the new course of anthracyclines was 28 ± 14 months. Further baseline

characteristics of study cohort are summarized in *Table 1*. Patients received a mean cumulative dose of doxorubicin-equivalent chemotherapy of 362 ± 30 mg/m² within a mean treatment time of 20.7 ± 3.0 weeks.

LV and RV function

Eight patients had developed LVEF reduction $>10\%$ upon completion of therapy as compared with baseline and were defined as aCMP patients for further analysis (*Figure 1*). In this aCMP group, mean LVEF decreased from $59.4 \pm 8.4\%$ at baseline to $46.5 \pm 8.4\%$ after chemotherapy ($P < 0.01$), whereas non-aCMP patients had no difference in LVEF until completion of therapy (baseline: $62.6 \pm 5.8\%$, after chemotherapy: $60.5 \pm 5.5\%$, $P = 0.58$). *Figure 1* displays individual LVEF changes between baseline and completion of chemotherapy, and detailed results of anatomical and functional parameters of all CMR studies are illustrated in *Table 2A*. In aCMP patients LV mass decreased significantly from baseline (99.4 ± 26.5 g) until completion of therapy (90.3 ± 24.8 g; $P = 0.02$), whereas while LV mass did not change in non-aCMP patients over the course of chemotherapy (baseline: 91.5 ± 20.0 g; after therapy: 89.0 ± 23.6 g).

Within 48 after the first treatment with anthracyclines, non-aCMP patients showed an increase in LVEF ($59.5 \pm 6.3\%$ vs. $62.2 \pm 6.0\%$, $P = 0.03$), LVEDV (143.2 ± 33.5 mL vs. 158.5 ± 36.5 mL, $P < 0.01$), RVEDV (173.7 ± 39.9 mL vs. 187.4 ± 38.6 mL, $P = 0.01$), and RVEF ($50.7 \pm 4.8\%$ vs. $54.3 \pm 5.3\%$, $P < 0.01$) as compared with baseline, whereas patients with subsequent aCMP did not (see *Table 2A*). LV mass did not change in either group after the first dose of anthracyclines.

Strain analysis results are displayed in *Table 2A* and revealed a significant decrease of GLS (-15.3 ± 1.3 vs.

Table 1 Patient characteristics

Patient characteristics	
Age	53.5 ± 12.0 yrs
Gender	12 M/11 F
BMI	25.1 ± 3.4 kg/m ²
Hypertension	14/23 (61%)
Diabetes	2/23 (9%)
CAD	1/23 (4%)
(Ex-) Smoker	7/23 (30%)

BMI, body mass index; CAD, coronary artery disease; F, female; M, male; yrs, years.

Figure 1 LVEF development before and after chemotherapy. Red data points indicate aCMP patients with LVEF drop of $>10\%$ during chemotherapy. Averages for aCMP and non-aCMP patients are displayed above.

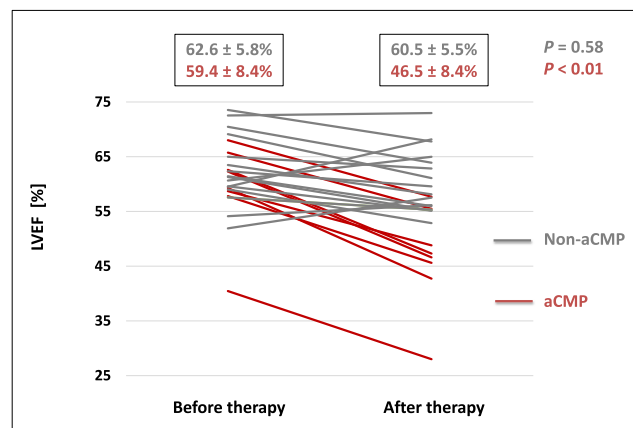


Table 2 Volumetric and functional assessment and univariate logistic regression analysis for aCMP development

A. Volumetric and functional assessment							
Non-aCMP				P value		P value	
	LVEDV	mL	143.2 ± 33.5	158.5 ± 36.5	< 0.01	154.2 ± 33.5	0.07
	LVEF	%	59.5 ± 6.3	62.2 ± 6.0	0.03	60.5 ± 5.4	0.57
	RVEDV	mL	174.7 ± 40.0	187.4 ± 38.6	0.01	181.5 ± 45.5	0.22
	RVEF	%	50.7 ± 4.8	54.3 ± 5.2	< 0.01	51.9 ± 5.3	0.29
	LVM	g	91.5 ± 20.0	91.9 ± 17.8	0.77	89.8 ± 23.6	0.37
	GLS	%	-15.4 ± 3.3	-16.3 ± 2.7	0.18	-15.4 ± 3.4	0.97
	GCS	%	-16.0 ± 2.6	-16.7 ± 2.5	0.13	-17.1 ± 2.3	0.02
		Before therapy	48 h after 1st dose		After therapy		
aCMP				P value		P value	
	LVEDV	mL	157.5 ± 31.2	178.5 ± 36.4	0.03	157.3 ± 29.3	0.98
	LVEF	%	59.4 ± 8.4	57.3 ± 9.7	0.35	46.5 ± 8.4	< 0.01
	RVEDV	mL	166.2 ± 35.3	184.4 ± 58.9	0.07	156.6 ± 22.0	0.60
	RVEF	%	51.3 ± 8.7	54.9 ± 8.2	0.13	52.0 ± 6.1	0.64
	LVM	g	99.4 ± 26.5	96.1 ± 23.8	0.25	90.3 ± 26.5	0.02
	GLS	%	-15.3 ± 1.3	-16.7 ± 2.4	0.12	-13.4 ± 1.6	0.02
	GCS	%	-16.7 ± 2.1	-17.7 ± 1.5	0.27	-14.9 ± 2.6	0.04

B. Univariate logistic regression analysis for aCMP development. Odds ratio (OR) and 95% confidence interval (CI) for developing aCMP

	Univariate OR (95% CI)	P value
Baseline LVEF	1.02 (0.98–1.06)	0.36
Baseline LVEDV	1.07 (0.82–1.44)	0.22
Baseline RVEF	1.01 (0.96–1.03)	0.63
Baseline RVEDV	1.03 (0.66–3.04)	0.26
Baseline LVM	0.84 (0.69–2.11)	0.10
Baseline GLS	0.91 (0.61–1.10)	0.19
Baseline GCS	0.90 (0.74–1.09)	0.57
Baseline T1	1.03 (0.88–1.19)	0.47
Baseline T2	0.90 (0.68–1.07)	0.20
ΔT1 @ 48 h	1.02 (0.53–1.28)	0.91
ΔT2 @ 48 h	1.13 (1.04–1.32)	0.02
ΔLVEF @ 48 h	0.88 (0.59–1.11)	0.09
ΔLVEDV @ 48 h	1.22 (0.92–1.42)	0.14
ΔRVEF @ 48 h	1.07 (0.89–1.27)	0.16
ΔRVEDV @ 48 h	0.95 (0.84–1.10)	0.38

Grey data include patients without development of aCMP; red data include aCMP patients. P values indicate statistical significance towards baseline data (before therapy).

-13.4 ± 1.6; P = 0.02) and GCS (-16.7 ± 2.1 vs. -14.9 ± 2.6; P = 0.04) in aCMP patients upon completion of therapy as compared with baseline, whereas non-aCMP individuals showed no change in GLS (-15.4 ± 3.3 vs. -15.4 ± 3.4; P = 0.97). However, a slight increase of GCS (-16.0 ± 2.6 vs. -17.1 ± 2.3; P = 0.02) was detected in non-aCMP patients after chemotherapy. At 48 h after first dose of anthracyclines neither group showed changes of GLS and GCS as compared with baseline (see [Table 2A](#) for details).

Univariate logistic regression analysis showed no significant correlation of any functional baseline CMR parameter with development of subsequent aCMP ([Table 2B](#)).

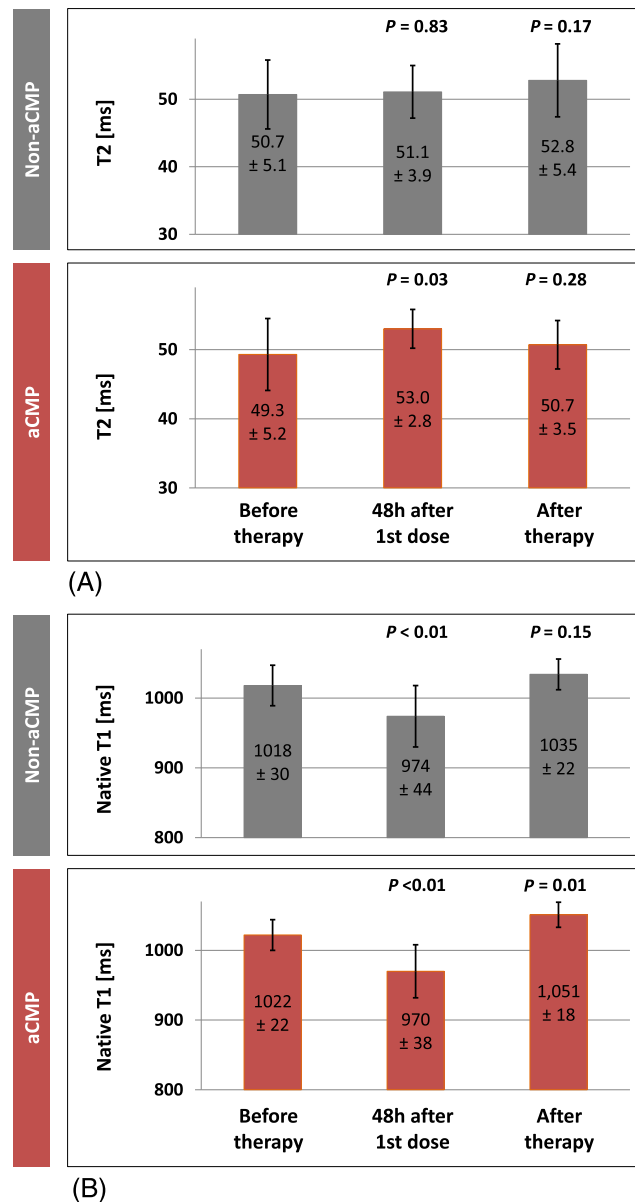
Myocardial tissue differentiation

We observed a significant increase of myocardial T2 time in patients who developed aCMP from 49.3 ± 5.2 ms at baseline to 53.0 ± 2.8 ms at 48 h after the first dose of anthracyclines (P = 0.02). Patients without development of aCMP until

completion of chemotherapy did not show a change in T2 at 48 h (50.7 ± 5.1 ms at baseline; 51.1 ± 3.9 ms at 48 h; P = 0.83). Upon completion of therapy, T2 times were not significantly different from baseline values in either group. For details, see [Figures 2A](#) and [3](#).

Evaluation of native T1 maps showed a significant decrease of T1 times 48 h after the first dose of anthracyclines in both groups, aCMP (1022.4 ± 22.0 ms vs. 970.3 ± 38.1 ms; P < 0.01) and non-aCMP patients (1018.4 ± 29.7 ms vs. 974.2 ± 43.6 ms; P < 0.01). Inter-group comparison showed no difference in the degree of T1 decrease between groups. After completion of chemotherapy, however, native T1 times were significantly increased as compared with baseline in aCMP patients (1050.8 ± 17.9 ms vs. 1022.4 ± 22.0 ms; P = 0.01), but not significantly different in patients without development of aCMP (baseline: 1018.4 ± 29.7 ms; after chemotherapy: 1034.5 ± 46.6 ms; P = 0.15). For details, see [Figures 2B](#) and [3](#). Univariate logistic regression analysis confirmed the

Figure 2 (A) T2 mapping. (B) Native T1 mapping. Grey columns represent patients without development of aCMP, and red columns aCMP patients. *P* values indicate statistical significance towards baseline (before therapy). CTX, chemotherapy.



association of T2 increase at 48 h with development of aCMP upon completion of therapy [OR: 1.13 (CI: 1.04–1.32); $P = 0.02$]; see [Table 2B](#).

Reliability was excellent for both interobserver and intraobserver evaluations (Spearman rank correlation for native T1 times $r_s = 0.92$ with $P = 0.01$ and for T2 times $r_s = 0.89$ with $P = 0.01$, intraclass-correlation coefficient 0.96 for native T1 and 0.97 for T2).

ECV analysis showed that absolute ECV values did not change significantly between baseline, 48 h after first dose of anthracyclines and after chemotherapy in aCMP and

non-aCMP patients ([Table 3](#)). Due to the loss in LV mass over the course of chemotherapy, an increase of relative ECV after completion of chemotherapy was detectable in aCMP patients against baseline from $25.3 \pm 1.7\%$ to $28.4 \pm 1.7\%$ ($P = 0.03$). However, this change was not verifiable in absolute ECV values (22.0 ± 3.3 g at baseline vs. 24.0 ± 3.2 g after therapy, $P = 0.22$).

LGE analysis revealed that two individuals had myocardial fibrosis at baseline CMR. Both subjects were in the non-aCMP group and had minor subendocardial scars as well as known coronary artery disease. None of the

Figure 3 Representative aCMP imaging data. Native T1 and T2 maps of patient with aCMP before chemotherapy and 48 h after first dose application. Displayed times are average slice global values.

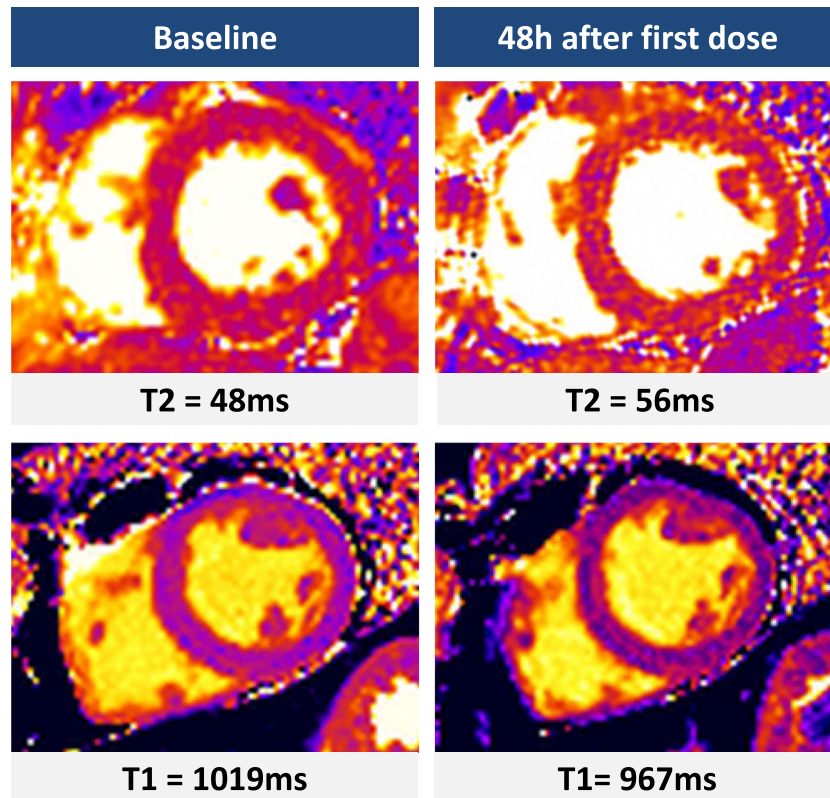


Table 3 ECV assessment

		Before therapy	48 h after 1st dose	P value		After therapy	P value
Non-aCMP							
Relative ECV	%	24.0 ± 2.4	25.1 ± 2.7	0.24		26.4 ± 2.6	0.09
Absolute ECV	g	22.0 ± 5.4	23.0 ± 5.8	0.20		23.7 ± 3.9	0.15
		Before therapy	48 h after 1st dose	P value		After therapy	P value
aCMP							
Relative ECV	%	25.3 ± 1.7	25.5 ± 2.3	0.66		28.4 ± 1.7	0.03
Absolute ECV	g	25.1 ± 3.3	24.5 ± 3.6	0.33		25.5 ± 3.2	0.22

Grey data include patients without development of aCMP; red data include aCMP patients. *P* values indicate statistical significance toward baseline data (before therapy).

detected LGE lesions changed on follow-up CMR scans. A very small intramural lateral basal LGE lesion was detected in one non-aCMP patient after completion of chemotherapy, which was not detected at baseline or at 48 h after first dose.

Laboratory results

High-sensitive troponin T and NT-proBNP blood analysis were obtained before each scan and complete datasets were

available for 20 individuals (7 aCMP; 13 non-aCMP). Results are displayed in *Table 4*. There was no significant difference in troponin T levels at baseline between aCMP (10.0 ± 4.2 ng/L) and non-aCMP patients (7.1 ± 2.6 ng/L; *P* = 0.29) and no significant elevation at 48 h after first anthracycline treatment (aCMP: 14.6 ± 6.5 ng/L, *P* = 0.10; non-aCMP: 7.6 ± 3.7 ng/L, *P* = 0.66). Upon completion of anthracycline therapy, however, an increase of troponin T levels against baseline occurred in both patient groups (aCMP: 20.7 ± 9.3 ng/L, *P* = 0.04; non-aCMP: 14.9 ± 9.9 ng/L, *P* = 0.02). NT-proBNP was neither different between aCMP

Table 4 Laboratory blood analysis

		Before therapy	48 h after 1st dose	After therapy		
Non-aCMP				<i>P</i> value	<i>P</i> value	
High-sensitive troponin T	ng/L	7.1 ± 2.6	7.6 ± 3.7	0.66	14.9 ± 9.9	0.02
NTproBNP	pg/mL	158.4 ± 79.1	211.7 ± 144.2	0.33	203.0 ± 208.4	0.77
aCMP				p value	p value	
High-sensitive troponin T	ng/L	10.0 ± 4.2	14.6 ± 6.5	0.10	20.7 ± 9.3	0.03
NTproBNP	pg/mL	230.4 ± 79.1	211.7 ± 144.2	0.77	225.1 ± 82.3	0.91

Grey data include patients without development of aCMP; red data include aCMP patients. *P* values indicate statistical significance toward baseline data (before therapy).

and non-aCMP patients at any time point nor did we see a statistically significant increase at 48 h or upon completion of chemotherapy (Table 4).

Discussion

In this study, we focused on the effect of cumulative high-dose anthracycline doses on cardiac morphology and function. We identified several myocardial tissue changes predicting an early-onset cardiomyopathy due to high-dose anthracyclines. Firstly, 30% of recruited patients showed a decrease in LVEF of more than 10% over the course of an anthracycline-based chemotherapy, which was defined as development of aCMP. Secondly, patients who developed aCMP had decreased LV mass upon completion of therapy, whereas patients without aCMP did not show a change in LV mass. Thirdly, an increase of myocardial T2 time within 48 h after the first dose of the repetitive anthracycline regime was associated with subsequent development of aCMP. Fourthly, an acute decrease in native T1 time within 48 h was detected in all patients independent of development of subsequent aCMP; however, only in patients with aCMP native myocardial T1 times were elevated upon completion of the chemotherapy regime. Finally, absolute ECV values did not qualify to discriminate between patients with and without development of aCMP in this study.

In the following, the results will be discussed in the context of current scientific knowledge and also in comparison with the results of our previous study on patients with low to moderate doses of anthracyclines.¹²

The prevalence of aCMP is heavily depending on the definition, diagnostic modality, and timing of aCMP and, hence, has a wide range between 3% and 48%.^{5,15,16} CMR is widely accepted as the reference method for measurement of left ventricular volumes and LVEF due to best reproducibility among non-invasive imaging techniques.^{17,18}

CMR has been shown to be superior to echocardiography in detection of LVEF decline under anthracycline therapy, that is, revealing an LVEF drop to <50% in a quarter of all patients

within 6 months of therapy using CMR, which is in line with our results.^{18,19} Interestingly, the prevalence of aCMP in this study (30% of all study individuals) is comparable with our previous study with therapy-naïve patients.¹² It is known from larger studies that the probability of aCMP increases with higher cumulative doses of anthracyclines. This incongruence could derive from the relatively small cohort in our study and was not interpreted as a general phenomenon.

The association between sarcopenia and declining LVEF, which we observed in this study, is in line with previous limited data on anthracyclines as well as trastuzumab therapy and was also observed in patients with low to moderate anthracycline doses.^{12,20,21}

Myocardial atrophy and general cachexia are known to be independent predictors for mortality in cancer patients.²² The decrease of LV mass in patients with aCMP may also serve as a phenotypic criterion for aCMP, albeit the differentiation between cause and consequence remains unclear.

In vivo studies showed that the degree of cardiac atrophy is dose-dependent and may be mediated through upregulation of muscle enzymes.²³ We have not found a more severe cardiac atrophy as compared with patients with low to moderate anthracycline therapy. However, in our study cohort, there was a significant amount of time between both courses anthracyclines (on average 28 months), which may have reduced the cumulative sarcopenic effect. Furthermore, the patients in this study received very similar cumulative doses of anthracyclines independent of development of aCMP, making dosing differences a minor contributor to observed group effects.

Strain analysis showed comparable changes as LVEF for both groups. GLS and GCS declined upon completion of chemotherapy in patients with LVEF drop; however, no drop of GLS and GCS was seen at 48 h after first treatment. Interestingly, we detected a slight increase of GCS in non-aCMP patients after completion of therapy. Although this increase was statistically significant in this cohort, the extent of this GCS increase was 1.1% and therefore, in our opinion, hardly clinically relevant.

The role of strain analysis in detection of cardiotoxicity gained significant importance in recent years, as several

studies have shown that GLS and GCS can serve as earlier markers for cardiotoxicity as LVEF and may hence be a more reliable screening parameter.^{24,25} Most of these studies, however, used echocardiography for strain analysis and investigated individuals over longer periods of time after completion of chemotherapy.

Myocardial T1 and T2 mapping gained increasing importance for assessing chemotherapy-related myocardial injury.^{9,12,23,26} Common goal is to assess mapping techniques as potential biomarkers of chemotherapy-related cardiotoxicity that may have the ability to detect myocardial tissue damage earlier than conventional functional metrics. In the present study, we found that in the setting of cumulative high-dose anthracycline therapy, a very early increase of T2 time was detectable in patients developing aCMP upon completion of chemotherapy, but not in patients with preserved LVEF. In the setting of lower cumulative anthracycline doses (<360 mg/m²), no change of T2 time was detectable at the same time point.¹²

In order to correctly interpret results, we believe that two factors are of utmost importance for detection of structural and functional myocardial changes: (i) timing of the MRI scan and (ii) dose of the cardiotoxic agent. Myocardial injury is a very dynamic process and may lead to very different results depending on the cumulative dose and on the time between administration of the toxic agent and scanning.

An increase of T2 times as a reflection of myocardial oedema after anthracycline therapy was also observed in previous studies. In vivo studies with mice and rats showed that severe myocardial oedema assessed by T2 time is detectable after several weeks of treatment and that the degree of oedema (30% increase of baseline T2 times) is extensively larger than in our study.^{26,27} However, the cumulative dose and the treatment schedules with weekly intraperitoneal injections of anthracyclines are significantly more intense than current clinical practice and may lead to different degrees of myocardial injury.

In another study, Galán-Arriola *et al.* injected doxorubicin into coronary arteries of 20 pigs.²⁸ With serial MRI scans, they also found a substantial increase of T1 and T2 times with declining LVEF, which could be halted by stopping anthracycline therapy, indicating the rather acute nature of the observed cardiotoxicity. Although all previously mentioned animal studies were able to observe substantial myocardial oedema even weeks after anthracycline therapy, in the present study, we were able to detect increased T2 times only very early into the treatment (48 h after the first dose) but not after completion of therapy. We hypothesize that the comparatively more severe effects in animal studies reflect their significantly higher anthracycline dose and the way of administration (i.e. intracoronarily), leading to a more extensive and prolonged degree of myocardial injury. Supporting this hypothesis, Farhad *et al.* found increased myocardial T2 times in mice treated with moderate doses

of anthracyclines at 5 weeks after beginning of anthracycline treatment, which resolved upon a 20-week follow-up.²⁹

Assessing native T1 times, we found an early decrease 48 h after the first dose in all individuals independent of subsequent aCMP development, whereas only patients with subsequent aCMP showed an increased native T1 time upon completion of therapy. These results are in contrast to a previous study: In therapy-naïve patients with lower cumulative anthracycline dose, an early decrease of myocardial T1 time only occurred in patients with subsequent aCMP, but not in patient with preserved LVEF.¹² We hypothesize that this early drop in native T1 time reflects an acute cardiotoxic effect, which is dose dependent and varies individually. Hence, it has an effect on T1 time in all patients previously treated with anthracyclines (whose myocardium has already experienced toxic injury), but only in a subset of vulnerable individuals that were not previously treated.

The pathophysiologic mechanism behind this decrease in native T1 remains unclear. Until today, there is a lack of histologic data at this very early timing of myocardial tissue assessment after anthracycline administration.

One hypothesis includes the involvement of radical oxygen species (ROS), which are known to play a key role in anthracycline-mediated cardiotoxicity and which affect mitochondrial function and increase lipid peroxidation.³⁰ Furthermore, it is known that intracardiomyocyte vacuolization occurs due to anthracycline cardiotoxicity.²⁸ It is possible that this may lead to increased lipid deposition (like in Fabry's disease) and thereby decreases native T1.³¹

The observation that T1 times normalize again upon completion of therapy in patients without aCMP further strengthens the possibility that rather acute than chronic toxic effects are mediating the early native T1 decrease.

Some patients, however, develop aCMP, and long-term increases of native T1 can be observed as a reflection of chronic myocardial injury with diffuse fibrosis and remodelling. Several CMR studies with cancer survivors have investigated changes in myocardial T1 and T2 times and found that anthracyclines can cause an increase of native T1 times and ECV due to development of diffuse myocardial fibrosis years after completion of treatment.^{32–34}

This indicates that there is a long-term myocardial remodelling effect due to anthracyclines, which increases risk for cardiovascular disease.

We found no evidence for early increase of ECV in this study irrespective of development of aCMP and neither acutely after the first dose of anthracyclines nor upon completion of therapy. Although relative ECV values have increased, this was rather due to sarcopenia-mediated decrease of myocardial mass. Absolute ECV values did not change in either group. This observation is in line with our study on previously anthracycline-naïve patients.^{12,21}

Other groups have reported that there is increase in ECV in childhood cancer survivors, however, only assessed by relative ECV.³²

In our opinion, there certainly is a degree of mild diffuse fibrosis attributing to increased relative ECV in the long term. The present study, however, did not evaluate long-term effects years after completion of treatment.

Anthracycline-associated cardiomyopathy typically does not lead to new focal LGE lesions. In this study, a very small intramural lateral basal LGE lesion was detected after completion of chemotherapy, which was not detected at baseline or at 48 h after first dose. In our opinion, it is not necessarily new and could have been missed in the first two scan given the very small size of the lesion, that is, due to different breathing pattern.

Blood sample analysis before each CMR scan showed minimal but significant elevations of high-sensitive troponin T in all patients, irrespective of development of aCMP. In previously untreated patients, results were analogous.¹² Troponin T as a highly sensitive biomarker for cellular myocardial injury maybe elevated in most patients under anthracycline therapy as minor myocardial damage may occur in the majority of patients but does not necessarily lead to clinically overt heart failure. In the literature, there is mixed evidence for validity of troponin T as an early biomarker for aCMP; however, in larger cohorts of breast cancer patients, an association of troponin T elevations and LVEF decline was detectable.³⁵ In light of the smaller sample size in our study and different primary endpoints, we believe that larger studies with serial CMR scans and biomarker evaluations may help to assess the role of troponin T as a tool for early aCMP risk assessment. Similarly, NT-proBNP as a well-established biomarker for heart failure was not suitable to distinguish between aCMP and non-aCMP patients in this study and neither in previously untreated patients.¹² Although differences between groups were statistically not significantly different, we detected trend toward higher baseline NT-proBNP levels in aCMP patients. Again, this could be attributable to the comparatively lower sample size in this study and should be addressed in larger cohorts.

In conclusion, we showed that anthracycline-mediated cardiomyopathy can display several phenotypes depending on cumulative dose, way of agent administration, and—most importantly—timing of assessment. Acute toxic effects may lead to early native T1 and T2 changes as observed in this and previous studies, whereas chronic myocardial remodel-

ling due to anthracyclines may lead to diffuse interstitial fibrosis in cancer survivors. Nevertheless, myocardial T1 and T2 mapping may represent a tool for early identification of patients at highest risk for development of aCMP.

Larger, interventional studies are needed to investigate if preventive measures—such as primary aCMP prevention with heart failure medication—inhibit these observed early changes of T1 and T2 times after anthracycline treatment.

Limitations

This was a single-centre study and we observed patients only until completion of therapy. However, long-term effects of anthracyclines are known to develop even years after completion of treatment. Studies with longer follow-up may help to discriminate between patients with early-onset and late-onset aCMP.

Mapping sequences were acquired without full LV coverage, potentially missing regional abnormalities.

Acknowledgements

We want to thank our study nurses and MR technicians for their continuous support with data acquisition and recruitment. Special thanks to the entire team of the Department of Interdisciplinary Oncology and Sarcoma Center for their help with patient recruitment.

Open Access funding enabled and organized by Projekt DEAL.

Conflict of interest

Peter Reichardt received personal fees from Roche Holding AG and Bayer AG. Jeanette Schulz-Menger received grants from Helios Kliniken GmbH, Siemens Healthineers, and Bayer AG. The other authors have nothing to declare.

Funding

This study received no external funding.

References

1. Giordano SH, Lin Y-L, Kuo YF, Hortobagyi GN, Goodwin JS. Decline in the use of anthracyclines for breast cancer. *J Clin Oncol*. 2012; **30**: 2232–2239.
2. Nabhan C, Byrtek M, Rai A, Dawson K, Zhou X, Link BK, Friedberg JW, Zelenetz AD, Maurer MJ, Cerhan JR, Flowers CR. Disease characteristics, treatment patterns, prognosis, outcomes and lymphoma-related mortality in elderly follicular lymphoma in the United States. *Br J Haematol*. 2015; **170**: 85–95.
3. Coleman MP, Forman D, Bryant H, Butler J, Rachtel B, Maringe C, Nur U,

- Tracey E, Coory M, Hatcher J, McGahan C, Turner D, Marrett L, Gjerstorff ML, Johannesen TB, Adolfsson J, Lambe M, Lawrence G, Meechan D, Morris EJ, Middleton R, Steward J, Richards MA, ICBP Module 1 Working Group. Cancer survival in Australia, Canada, Denmark, Norway, Sweden, and the UK, 1995-2007 (the International Cancer Benchmarking Partnership): An analysis of population-based cancer registry data. *Lancet (London, England)*. 2011; **377**: 127-138.
4. Alvarez JA, Russell RR. Cardio-oncology: The nuclear option. *Curr Cardiol Rep*. 2017; **19**: 31.
 5. Swain SM, Whaley FS, Ewer MS. Congestive heart failure in patients treated with doxorubicin: A retrospective analysis of three trials. *Cancer*. 2003; **97**: 2869-2879.
 6. Levis BE, Binkley PF, Shapiro CL. Cardiotoxic effects of anthracycline-based therapy: What is the evidence and what are the potential harms? *Lancet Oncol*. 2017; **18**: e445-e456.
 7. Tarantini L, Gulizia MM, Di Lenarda A, Maurea N, Giuseppe Abrignani M, Bisceglia I, Bovelli D, De Gennaro L, Del Sindaco D, Macera F, Parrini I. ANMCO/AIOM/AICO consensus document on clinical and management pathways of cardio-oncology: Executive summary. *Eur Heart J Suppl*. 2017; **19**: D370-D379.
 8. Plana JC, Galderisi M, Barac A, Ewer MS, Ky B, Scherrer-Crosbie M, Ganame J, Sebag IA, Agler DA, Badano LP, Banchs J, Cardinale D, Carver J, Cerqueira M, DeCara JM, Edvardsen T, Flamm SD, Force T, Griffin BP, Jerusalem G, Liu JE, Magalhaes A, Marwick T, Sanchez IY, Sicari R, Villarraga HR, Lancellotti P. Expert consensus for multimodality imaging evaluation of adult patients during and after cancer therapy: A report from the American Society of Echocardiography and the European Association of Cardiovascular Imaging. *Eur Heart J Cardiovasc Imaging*. 2014; **15**: 1063-1093.
 9. Čelutkienė J, Pudil R, López-Fernández T, Grapsa J, Nihoyannopoulos P, Bergler-Klein J, Cohen-Solal A, Farmakis D, Tocchetti CG, von Haehling S, Barberis V, Flachskampf FA, Čeponienė I, Haegler-Laube E, Suter T, Lapinskas T, Prasad S, de Boer RA, Wechalekar K, Anker MS, Iakobishvili Z, Bucciarelli-Ducci C, Schulz-Menger J, Cosyns B, Gaemperli O, Belenkov Y, Hulot JS, Galderisi M, Lancellotti P, Bax J, Marwick TH, Chioncel O, Jaarsma T, Mullens W, Piepoli M, Thum T, Heymans S, Mueller C, Moura B, Ruschitzka F, Zamorano JL, Rosano G, Coats AJS, Asteggiano R, Seferovic P, Edvardsen T, Lyon AR. Role of cardiovascular imaging in cancer patients receiving cardiotoxic therapies: A position statement on behalf of the Heart Failure Association (HFA), the European Association of Cardiovascular Imaging (EACVI) and the Cardio-Oncology Council of the European Society of Cardiology (ESC). *Eur J Heart Fail*. 2020; **22**: 1504-1524.
 10. Kim PK, Hong YJ, Im DJ, Suh YJ, Park CH, Kim JY, Chang S, Lee HJ, Hur J, Kim YJ, Choi BW. Myocardial T1 and T2 mapping: Techniques and clinical applications. *Korean J Radiol*. 2017; **18**: 113-131.
 11. Piechnik SK, Jerosch-Herold M. Myocardial T1 mapping and extracellular volume quantification: An overview of technical and biological confounders. *Int J Cardiovasc Imaging*. 2018; **34**: 3-14.
 12. Muehlberg F, Funk S, Zange L, von Knobelsdorff-Brenkenhoff F, Blaszczyk E, Schulz A, Ghani S, Reichardt A, Reichardt P, Schulz-Menger J. Native myocardial T1 time can predict development of subsequent anthracycline-induced cardiomyopathy. *ESC Hear Fail*. 2018; **5**: 620-629.
 13. Schmachl L, Traber J, Grieben U, Utz W, Dieringer MA, Kellman P, Blaszczyk E, von Knobelsdorff-Brenkenhoff F, Spuler S, Schulz-Menger J. Cardiac involvement in myotonic dystrophy type 2 patients with preserved ejection fraction: Detection by cardiovascular magnetic resonance. *Circ Cardiovasc Imaging*. 2016; **9**: e004615.
 14. Lim C, Blaszczyk E, Riazy L, Wiesemann S, Schüller J, von Knobelsdorff-Brenkenhoff F, Schulz-Menger J. Quantification of myocardial strain assessed by cardiovascular magnetic resonance feature tracking in healthy subjects—Influence of segmentation and analysis software. *Eur Radiol*. 2021; **31**: 3962-3972.
 15. Curigliano G, Cardinale D, Dent S, Criscitello C, Aseyev O, Lenihan D, Cipolla CM. Cardiotoxicity of anticancer treatments: Epidemiology, detection, and management. *CA Cancer J Clin*. 2016; **66**: 309-325.
 16. Krischer JP, Epstein S, Cuthbertson DD, Goorin AM, Epstein ML, Lipshultz SE. Clinical cardiotoxicity following anthracycline treatment for childhood cancer: The Pediatric Oncology Group experience. *J Clin Oncol*. 1997; **15**: 1544-1552.
 17. Grothues F, Smith GC, Moon JCC, Bellenger NG, Collins P, Klein HU, Pennell DJ. Comparison of interstudy reproducibility of cardiovascular magnetic resonance with two-dimensional echocardiography in normal subjects and in patients with heart failure or left ventricular hypertrophy. *Am J Cardiol*. 2002; **90**: 29-34.
 18. Ylänen K, Eerola A, Vettenranta K, Poutanen T. Three-dimensional echocardiography and cardiac magnetic resonance imaging in the screening of long-term survivors of childhood cancer after cardiotoxic therapy. *Am J Cardiol*. 2014; **113**: 1886-1892.
 19. Drafts BC, Twomley KM, D'Agostino R, Lawrence J, Avis N, Ellis LR, Thohan V, Jordan J, Melin SA, Torti FM, Little WC. Low to moderate dose anthracycline-based chemotherapy is associated with early noninvasive imaging evidence of subclinical cardiovascular disease. *JACC Cardiovasc Imaging*. 2013; **6**: 877-885.
 20. Neilan TG, Coelho-Filho OR, Pena-Herrera D, Shah RV, Jerosch-Herold M, Francis SA, Moslehi J, Kwong RY. Left ventricular mass in patients with a cardiomyopathy after treatment with anthracyclines. *Am J Cardiol*. 2012; **110**: 1679-1686.
 21. Ferreira de Souza T, Quinaglia A C Silva T, Osorio Costa F, Shah R, Neilan TG, Velloso L, Nadruz W, Brenelli F, Sposito AC, Matos-Souza JR, Cendes F, Coelho OR, Jerosch-Herold M, Coelho-Filho OR. Anthracycline therapy is associated with cardiomyocyte atrophy and preclinical manifestations of heart disease. *JACC Cardiovasc Imaging*. 2018; **11**: 1045-1055.
 22. Williams GR, Muss HB, Shachar SS. Cachexia in patients with cancer. *Lancet Oncol*. 2016; **17**: e220.
 23. Willis MS, Parry TL, Brown DI, Mota RI, Huang W, Beak JY, Sola M, Zhou C, Hicks ST, Caughey MC, D'Agostino RB Jr, Jordan J, Hundley WG, Jensen BC. Doxorubicin exposure causes subacute cardiac atrophy dependent on the striated muscle-specific ubiquitin ligase MuRF1. *Circ Heart Fail*. 2019; **12**: e005234.
 24. Charbonnel C, Convers-Domart R, Rigaudeau S, Taksin AL, Baron N, Lambert J, Ghez S, Georges JL, Farhat H, Lambert J, Rousselot P, Livarek B. Assessment of global longitudinal strain at lowdose anthracycline-based chemotherapy, for the prediction of subsequent cardiotoxicity. *Eur Heart J Cardiovasc Imaging*. 2017; **18**: 392-401.
 25. Laufer-Perl M, Derakhshesh M, Milwidsky A, Mor L, Ravid D, Amrami N, Sherez J, Keren G, Topilsky Y, Arbel Y. Usefulness of global longitudinal strain for early identification of subclinical left ventricular dysfunction in patients with active cancer. *Am J Cardiol*. 2018; **122**: 1784-1789.
 26. Noel CV, Rainusso N, Robertson M, Romero J, Masand P, Coarfa C, Pautler R. Early detection of myocardial changes with and without dextrazoxane using serial magnetic resonance imaging in a pre-clinical mouse model. *Cardio-oncology (London, England)*. 2021; **7**: 23.
 27. Park HS, Hong YJ, Han K, Kim PK, An E, Lee JY, Park CH, Lee HJ, Hur J, Kim YJ, Choi BW. Ultrahigh-field cardiovascular magnetic resonance T1 and T2 mapping for the assessment of anthracycline-induced cardiotoxicity in rat models: Validation against histopathologic changes. *J Cardiovasc Magn Reson*. 2021; **23**: 76.

28. Galán-Arriola C, Lobo M, Vílchez-Tschischke JP, López GJ, de Molina-Iracheta A, Pérez-Martínez C, Agüero J, Fernández-Jiménez R, Martín-García A, Oliver E, Villena-Gutierrez R, Pizarro G, Sánchez PL, Fuster V, Sánchez-González J, Ibanez B. Serial magnetic resonance imaging to identify early stages of anthracycline-induced cardiotoxicity. *J Am Coll Cardiol.* 2019; **73**: 779–791.
29. Farhad H, Staziaki PV, Addison D, Coelho-Filho OR, Shah RV, Mitchell RN, Szilveszter B, Abbasi SA, Kwong RY, Scherrer-Crosbie M, Hoffmann U, Jerosch-Herold M, Neilan TG. Characterization of the changes in cardiac structure and function in mice treated with anthracyclines using serial cardiac magnetic resonance Imaging. *Circ Cardiovasc Imaging.* 2016; **9**.
30. Asensio-López MC, Soler F, Pascual-Figal D, Fernández-Belda F, Lax A. Doxorubicin-induced oxidative stress: The protective effect of nicorandil on HL-1 cardiomyocytes. *PLoS One.* 2017; **12**: e0172803.
31. Liu JM, Liu A, Leal J, McMillan F, Francis J, Greiser A, Rider OJ, Myerson S, Neubauer S, Ferreira VM, Piechnik SK. Measurement of myocardial native T1 in cardiovascular diseases and norm in 1291 subjects. *J Cardiovasc Magn Reson.* 2017; **19**: 74.
32. Mawad W, Mertens L, Pagano JJ, Riesenkauff E, Reichert MJE, Mital S, Kantor PF, Greenberg M, Liu P, Nathan PC, Grosse-Wortmann L. Effect of anthracycline therapy on myocardial function and markers of fibrotic remodeling in childhood cancer survivors. *Eur Heart J Cardiovasc Imaging.* 2021; **22**: 435–442.
33. Tham EB, Haykowsky MJ, Chow K, Spavor M, Kaneko S, Khoo NS, Pagano JJ, Mackie AS, Thompson RB. Diffuse myocardial fibrosis by T1-mapping in children with subclinical anthracycline cardiotoxicity: Relationship to exercise capacity, cumulative dose and remodeling. *J Cardiovasc Magn Reson.* 2013; **15**: 48.
34. Neilan TG, Coelho-Filho OR, Shah RV, Feng JH, Pena-Herrera D, Mandry D, Pierre-Mongeon F, Heydari B, Francis SA, Moslehi J, Kwong RY, Jerosch-Herold M. Myocardial extracellular volume by cardiac magnetic resonance imaging in patients treated with anthracycline-based chemotherapy. *Am J Cardiol.* 2013; **111**: 717–722.
35. Simões R, Silva LM, Cruz ALVM, Fraga VG, de Paula SA, Gomes KB. Troponin as a cardiotoxicity marker in breast cancer patients receiving anthracycline-based chemotherapy: A narrative review. *Biomed Pharmacother.* 2018; **107**: 989–996.