

## Serological and Molecular Characteristics of the First Korean Case of *Echinococcus multilocularis*

Jin-Sook Jeong<sup>1</sup>, Sang-Young Han<sup>2</sup>, Young-Hoon Kim<sup>3</sup>, Yasuhito Sako<sup>4</sup>, Tetsuya Yanagida<sup>4</sup>, Akira Ito<sup>4,\*</sup>  
and Jong-Yil Chai<sup>5,\*</sup>

Departments of <sup>1</sup>Pathology, <sup>2</sup>Internal Medicine, <sup>3</sup>General Surgery, Dong-A University College of Medicine, Busan 602-714, Korea; <sup>4</sup>Department of Parasitology, Asahikawa Medical University, Asahikawa, Hokkaido 078-8510, Japan; <sup>5</sup>Department of Parasitology and Tropical Medicine, Seoul National University College of Medicine, Seoul 110-799, Korea

**Abstract:** In December 2011, we reported an autochthonous case of *Echinococcus multilocularis* infection in a 42-year-old woman in Korea. The diagnosis was based on histopathological findings of the surgically resected liver cyst. In the present study, we evaluated the serological and molecular characteristics of this Korean *E. multilocularis* case. The patient's serum strongly reacted with affinity-purified native Em18 and recombinant Em18 antigens (specific for *E. multilocularis*) but negative for recombinant antigen B8/1 (reactive for *Echinococcus granulosus*). In immunoaffinity chromatography, the serum also strongly reacted with *E. multilocularis* and only weakly positive for *E. granulosus*. We determined the whole nucleotide sequence of *cox1* (1,608 bp) using the paraffin-embedded cystic tissue which was compared with *E. multilocularis* isolates from China, Japan, Kazakhstan, Austria, France, and Slovakia. The Korean case showed 99.8-99.9% similarity with isolates from Asia (the highest similarity with an isolate from Sichuan, China), whereas the similarity with European isolates ranged from 99.5 to 99.6%.

**Key words:** *Echinococcus multilocularis*, alveolar echinococcosis, immunodiagnosis, *cox1*, South Korea

*Echinococcus multilocularis*, the most pathogenic species of the genus *Echinococcus*, causes a zoonotic infection resulting in a potentially fatal chronic liver disease called human hepatic alveolar echinococcosis (AE) [1,2]. AE has an extensive geographical distribution, mainly across the northern hemisphere, including endemic regions in central Europe, most of northern and central Eurasia, expanding eastward to Japan and parts of North America [1,2]. However, autochthonous AE had never been reported in South Korea before our recent report in 2011 [3].

The case involved a 42-year-old woman who suffered from recurrent hepatic AE. She had undergone 2 times liver operations [3]. At the second operation, the resected liver mass was largely necrotic and showed many multilocular cysts with eosinophilic laminated layers [3], compatible with the histopathology of *E. multilocularis* infection [4]. Based on the histopathological findings together with clinical features, we con-

cluded that the Korean case was AE of the PNM stage 4 according to the WHO classification [5]. She has been residing only in an urban area of South Korea, Gimhae-si (city) and had never traveled abroad [3].

In the present study, we evaluated the serological and molecular characteristics of this Korean case and obtained information on the possible geographical origin of the parasite for the case by serological testing of the patient's serum and a molecular approach using the paraffin-embedded histological sample. The mitochondrial cytochrome c oxidase subunit 1 (*cox1*) gene sequence was obtained and compared with other *E. multilocularis* isolates available in GenBank, particularly those reported from Asian (China, Japan, and Kazakhstan) and European countries (Austria, France, and Slovakia).

The patient's serum was isolated from blood and stored at -70°C until use. Serological studies were performed against several different antigens which can differentiate AE and cystic echinococcosis (CE) which is caused by *Echinococcus granulosus*. The antigens used for immunoblot included affinity-purified native Em18 antigen (a) and recombinant Em18 antigen (b) both of which are highly specific for AE, and hydatid cystic fluid antigen (c) and recombinant antigen B8/1 (d) that are more specific for CE than AE, but which may show weak re-

•Received 23 August 2013, revised 3 September 2013, accepted 5 September 2013.

\*Corresponding authors (cjl@snu.ac.kr; akiraito@asahikawa-med.ac.jp)

© 2013, Korean Society for Parasitology and Tropical Medicine

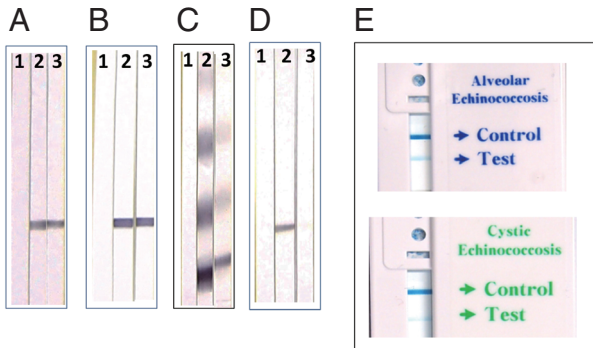
This is an Open Access article distributed under the terms of the Creative Commons Attribution Non-Commercial License (<http://creativecommons.org/licenses/by-nc/3.0>) which permits unrestricted non-commercial use, distribution, and reproduction in any medium, provided the original work is properly cited.

sponses due to cross-reactivity in some AE patients [6-8]. The patient's serum showed strong reactions with (a) and (b), and a weak reaction with (c), but a negative reaction for (d) (Fig. 1A-D) which could confirm *E. multilocularis* infection for the Korean case. In addition, serological tests were also performed using the most recently developed commercially available immunochromatography kit for AE and CE [9] (ICST, Saitama,

Japan). A strong positive reaction was evident with AE but only a weak positive reaction was seen with CE (Fig. 1E), which also suggested AE for the Korean case.

The complete sequence of the *cox1* gene was determined using the paraffin-embedded histological specimen of the patient according to the method described previously [10]. We determined the whole nucleotide sequence of *cox1* gene (1,608 bp; GenBank accession no. AB780998), which was compared with isolates of *E. multilocularis* from China (AB461417, AB477011, AB477012, and AB477010), Japan (AB461416 and AB385610), Kazakhstan (AB461415), Austria (AB461412), France (AB461413), and Slovakia (AB461414). The Korean case showed 99.8-99.9% similarity with 7 isolates from Asia, with the highest similarity with the China 1 isolate (AB461417) from Sichuan. However, the similarity with European isolates ranged from 99.5 to 99.6% (Fig. 1F).

The analysis of the *cox1* gene sequence allowed us to suggest cautiously that the possible origin of the parasite should be Asia, including the Sichuan area of China, as described in a previous report [10]. However, the patient had never been abroad including Sichuan, China [3]. Furthermore, whether an indigenous life cycle of *E. multilocularis* is present in South Korea is unknown. The patient had no special history of contacting dogs imported from abroad or visiting zoos [3]. Therefore, the route of infection in the Korean patient is still obscure, and research is needed. Nonetheless, clinical attention should be paid to AE, as there may be other AE cases in South Korea.



F			2	2	3	3	3	6	6	6	7	8	9	0	3
Isolates	(Acc. No.)		6	3	8	4	6	6	2	7	8	2	2	2	4
			9	7	9	6	4	8	5	5	8	1	2	6	8
Korea	(AB780998)	A	T	T	T	G	C	T	T	C	C	G	C	A	A
China1	(AB461417)	.	.	.	.	.	.	C	.	.	.	.	.	.	.
China2	(AB477011)	G	.	.	.	.	.	C	.	.	.	.	.	.	.
China3	(AB477012)	.	.	.	.	.	.	C	.	.	T	.	.	.	.
China4	(AB477010)	.	.	.	.	.	.	C	.	.	.	.	.	G	.
Japan1	(AB385610)	.	.	.	.	.	.	C	.	.	.	.	.	.	G
Japan2	(AB461416)	.	.	.	.	.	.	C	.	.	.	.	.	.	G
Kazakhstan	(AB461415)	.	.	.	.	.	.	C	.	.	.	.	.	G	G
Austria	(AB461412)	.	C	C	C	T	.	C	G	T	.	A	.	.	.
France	(AB461413)	.	C	C	.	.	T	C	G	T	.	A	.	.	.
Slovakia	(AB461414)	.	C	C	.	.	.	C	G	T	.	A	.	.	.

**Fig. 1.** Results of serological tests with *E. multilocularis* and *E. granulosus* (A-E) and molecular comparison (F) of the present case with other geographical isolates. Lane 1, negative control; Lane 2, positive control; and Lane 3, patient serum. (A) Strong reactivity of the test serum to affinity-purified native Em18 antigen specific for *E. multilocularis* was evident. (B) Strong reactivity of the test serum to recombinant Em18 antigen specific for *E. multilocularis* was evident. (C) Weak reactivity of the test serum to cystic fluid antigen of *E. granulosus* was shown. (D) There was no reactivity of the test serum to recombinant antigen B8/1 specific for *E. granulosus*. (E) Results of immunochromatographic test against *E. multilocularis* (alveolar echinococcosis; band apparent) and *E. granulosus* (cystic echinococcosis; band faint). (F) DNA sequence (1,068 bp) comparisons of the *cox1* gene of the Korean case of *E. multilocularis* (Genbank no. AB780998) with other isolates reported from Asian and European countries. The China 1 isolate (AB461417) showed the highest (99.9%) similarity with the present case with only 1 nucleotide substitution (1,607/1,608) at sequence no. 625.

**Conflict of interest**

We have no conflict of interest related to this study.

**REFERENCES**

1. Craig P. *Echinococcus multilocularis*. *Curr Opin Infect Dis* 2003; 16: 437-444.
2. Kern P. Clinical features and treatment of alveolar echinococcosis. *Curr Opin Infect Dis* 2010; 23: 505-512.
3. Kim SJ, Kim JH, Han SY, Kim YH, Cho JH, Chai JY, Jeong JS. Recurrent hepatic alveolar echinococcosis; report of the first case in Korea with unproven infection route. *Korean J Parasitol* 2011; 49: 413-418.
4. Brunetti E, Kern P, Vuitton DA, Writing Panel for the WHO-IWGE. Expert consensus for the diagnosis and treatment of cystic and alveolar echinococcosis in humans. *Acta Trop* 2010; 114: 1-16.
5. Kern P, Wen H, Sato N, Vuitton DA, Gruener B, Shao Y, Delabrousse E, Kratzer W, Bresson-Hadni S. WHO classification of

- alveolar echinococcosis: principles and application. *Parasitol Int* 2006; 55: s283-s287.
6. Ito A, Nakao M, Sako Y. Echinococcosis: serological detection of patients and molecular identification of parasites. *Future Microbiol* 2007; 2: 439-449.
  7. Ishikawa Y, Sako Y, Itoh S, Ohtake T, Kohgo Y, Matsuno T, Ohsaki Y, Miyokawa N, Nakao M, Nakaya K, Ito A. Serological monitoring of progression of alveolar echinococcosis with multiorgan involvement by use of recombinant Em18. *J Clin Microbiol* 2009; 47: 3191-3196.
  8. Mamuti W, Sako Y, Xiao N, Nakaya K, Nakao M, Yamasaki H, Lightowlers MW, Craig PS, Ito A. *Echinococcus multilocularis*: developmental stage-specific expression of antigen B 8-kDa subunits. *Exp Parasitol* 2006; 113: 75-82.
  9. Sako Y, Tappe D, Fukuda K, Kobayashi Y, Itoh S, Frosch M, Grüner B, Kern P, Ito A. Immunochromatographic test with recombinant Em18 antigen for the follow-up study of alveolar echinococcosis. *Clin Vaccine Immunol* 2011; 18: 1302-1305.
  10. Ito A, Agvaandaram G, Bat-Ochir OE, Chuluunbaatar B, Gonchingsenghe N, Yanagida T, Sako Y, Myadagsuren N, Dorjsuren T, Nakaya K, Nakao M, Ishikawa Y, Davaajav A, Dulmaa N. Histopathological, serological, and molecular confirmation of indigenous alveolar echinococcosis cases in Mongolia. *Am J Trop Med Hyg* 2010; 82: 266-269.

