

Protective Effect of Sorrel Extract on Adult Rats Treated by Carbon Tetrachloride

Abdullah Gliil Alkushi

Department of Anatomy, Faculty of Medicine, Umm Al-Qura University, Makkah, Kingdom of Saudi Arabia

ABSTRACT

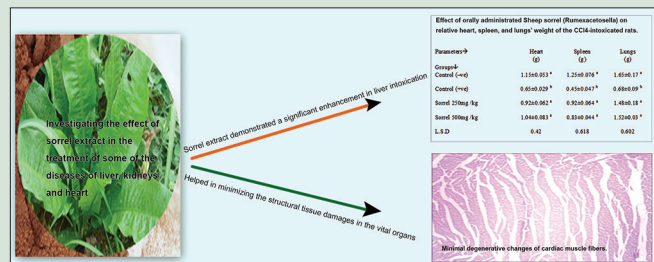
Context: Heart, kidneys, and liver are the vital organs present in vertebrates and some other animals. They have a wide range of functions, such as maintaining homeostasis, detoxification, protein synthesis, and production of biochemical, that are necessary for digestion and maintaining circulation. These organs are necessary for the survival, and currently, there are no means to compensate for the absence of their functionalities in a long term. The damage of liver can affect other vital organs, including kidneys and heart. **Aims:** This study aimed at investigating the effect of sorrel extract in the treatment of some of the diseases of liver, kidneys, and heart using experimental animals. **Settings and Design:** This study is a randomized, controlled clinical trial. **Materials and Methods:** Forty mature male albino rats, weighing 150–160 g, were used and divided into four equal groups. One group was kept as negative control (C –ve) group whereas the other three groups were injected subcutaneously (s/c) with carbon tetrachloride in 50% V/V paraffin oil (2 ml/kg b.wt.). Tissue specimens were obtained from all the groups and fixed in 10% formalin for histopathological examination. **Statistical Analysis Used:** The obtained data were statistically analyzed using computerized Superior Performing Statistical Software (SPSS) at SAS Institute, Cary, NC, USA. Effects of different treatments were analyzed by one-way analysis of variance test using Duncan's multiple range test, and $P < 0.05$ was also used to indicate the significance level between different groups (Snedecor and Cochran, 1967). **Results:** The resulting data showed that the sorrel extract demonstrated a significant enhancement in liver intoxication and all other tested parameters. In addition, it also helped in minimizing the structural tissue damages in the vital organs. **Conclusions:** According to these results, sorrel can impair the liver function and maintain the functions of the vital organs.

Key words: Carbon tetrachloride, heart, histopathological changes, kidneys, liver, sorrel

SUMMARY

- All rats, poisoned with carbon tetrachloride (CCl_4) and administrated with all tested herbs, showed a significant increase in BWG as compared to the control (+ve) group

- Sorrel extract demonstrates a significant enhancement in liver intoxication and all other tested parameters and can reduce the lipid peroxidation in CCl_4 -induced liver damage
- All rats, poisoned with CCl_4 and orally fed with all tested herbs, showed a significant decrease in the mentioned parameters when compared to control (+ve) group.



Abbreviations Used: ALT: Alanine transaminase, AST: Aspartate transaminase, ALP: Alkaline phosphatase, ALB: Albumin; BWG%: Body weight gain percentage, CCl_4 : Carbon tetrachloride, CAT: Catalase, GGT: Gamma-glutamyl transferase, GSH-Px: Glutathione peroxidase, GLOB: Globulin, iNOS: Inducible nitric oxide synthase, MDA: Malondialdehyde, RP: Rumex patientia, SOD: Superoxide dismutase, TP: Total protein, TC: Total cholesterol, TG: Triglycerides.

Correspondence:

Dr. Abdullah Gliil Alkushi,
Department of Anatomy, Faculty of Medicine,
Umm Al-Qura University, Makkah, Saudi Arabia.
E-mail: dr.alkushi@gmail.com
DOI: 10.4103/0974-8490.204653

Access this article online

Website: www.phcogres.com

Quick Response Code:



INTRODUCTION

Heart, kidneys, and liver are the vital organs in human. At times, liver damage can affect these vital organs that are necessary for survival. It plays a major role in metabolism and facilitates some of the functions in the body, including glycogen storage, decomposition of red blood cells, plasma protein synthesis, hormone production, and detoxification. It lies below the diaphragm in the abdominopelvic region of the body. It secretes bile, an alkaline compound, which aids in digestion via the emulsification of lipids. Highly specialized tissues of the liver regulate a wide variety of high-volume biochemical reactions, i.e., the synthesis and breakdown of small and complex molecules. These reactions are necessary for the normal vital functions of a living body.^[1]

Carbon tetrachloride (CCl_4) is a xenobiotic, which mainly affects liver and kidney.^[2] The CCl_4 , when gets activated in liver, generates a free radical-mediated lipid peroxidation causing functional and

morphological changes in the cell membrane due to the accumulation of oxidants resulting in liver damage.^[3]

Sheep sorrel (*Rumex*), also known as *Acetosella vulgaris*, is a species of sorrel – a perennial plant, which exhibits antiproliferative, antioxidant, antiviral, antimutagenic, and antigenotoxic effects.^[4-7]

This is an open access article distributed under the terms of the Creative Commons Attribution-NonCommercial-ShareAlike 3.0 License, which allows others to remix, tweak, and build upon the work non-commercially, as long as the author is credited and the new creations are licensed under the identical terms.

For reprints contact: reprints@medknow.com

Cite this article as: Alkushi AG. Protective effect of sorrel extract on adult rats treated by carbon tetrachloride. Phcog Res 2017;9:200-7.

Ahmed *et al.*^[8] conducted a study, by comparing aminoguanidine and silymarin, to examine their possible hepatoprotective effects and beneficial effects on the CCl₄-induced liver fibrosis. It was concluded that aminoguanidine showed protective effects against CCl₄-induced hepatotoxicity through its inducible nitric oxide synthase (iNOS) inhibition and antioxidant effects. In addition, silymarin exhibited more potential hepatoprotective effects than aminoguanidine.

Venkataramanan *et al.*^[9] further demonstrated about silymarin and silybin of the perennial plant, which are commonly used to protect the liver from damages caused by hepatitis viruses, alcohol, and other substances. Compounds found in silybin and silymarin act as antioxidants and stimulate the tissue repair of the liver.

Sedaghat *et al.*^[10] mentioned in their study that *Rumex patientia* (RP) could exert beneficial health effects to ameliorate the metabolic diseases. Subchronic treatment of diabetic rats with RP could result in lessening the abnormal changes in blood glucose level and improving the lipid profile, including high-density lipoprotein-cholesterol (HDL-C) and low-density lipoprotein-cholesterol (LDL-C) in part, due to its attenuation of lipid peroxidation in the hepatic tissue.

Predes *et al.*^[11] also examined that the hydroethanolic extracts could exhibit the strongest free radical scavenging activity while the Soxhlet extraction demonstrated the highest phenolic content. Moreover, the dichloromethane extracts showed a selective antiproliferative activity against the human cancer cell lines.

In another study conducted by Lin *et al.*,^[12] *Arctium lappa* Linne was found to protect the liver cells from CCl₄- or acetaminophen-induced liver damages through its antioxidative effects on hepatocytes. This resulted in the elimination of the deleterious effects of toxic metabolites from CCl₄ or acetaminophen.

Further, a study by Chen *et al.*^[13] found that fraxetin could exhibit potential protective effects against CCl₄-induced oxidative stress and hepatic fibrosis.

Therefore, the aim of this study was to investigate the effects of possible therapies and treatments with plant seeds, *Burdock* root, and sorrel root on the impaired liver function, in case of the albino rats injected with CCl₄.

MATERIALS AND METHODS

Materials

Plants

The plant used in this experiment was sheep sorrel (*Rumex*), which is a species of sorrel. It is also known as *A. vulgaris* Fourr.

This selection was made to study its effects on the treatment of some of the induced liver diseases in the albino rats using the sheep sorrel extracts, which were purchased as dried material from the local market.

Basal diet

The basal diet was prepared according to the method suggested by Reeves *et al.*^[14] Under this method, the diet constituted of 20% protein (casein), 10% sucrose, 4.7% corn oil, 2% choline chloride, 1% vitamin mixture, 3.5% salt mixture, and 5% fiber (cellulose). The remaining percentage was of corn starch, as recorded in Table 1.

Carbon tetrachloride

As per the study conducted by Passmore and Eastwood,^[15] 10% liquid solution of CCl₄ was dispensed in white plastic bottles, each containing one liter. At the same time, it was also mixed with paraffin oil that was obtained from pharmacy for dilution purposes during the induction.

Rats

Forty mature male albino rats of Sprague-Dawley strain, weighing 150–160 g (b.wt.) and of 14–16 weeks old, were obtained from the animal

house of the Department of Anatomy, Faculty of Medicine, Umm-AlQura University. The animals were allocated in plastic cages with metallic stainless covers and kept under the strict hygienic measures. Before the beginning of the experiment, the basal diet was fed to the rats for 7 days for adaptation. Rats were fed in special nonscattering feeding cups to avoid the loss of food and contamination. Water was provided *ad libitum* via a narrow-mouthed bottle, which was tightly fixed with a metallic tube at its mouth using a piece of rubber tube. The animals were subjected to a 12 h light and dark schedule for 7 days before the experiment.

Methods

Preparation of plant extracts

- The sorrel was ground using porcelain grinder so that it could pass through the sieve mesh pores of 1 mm diameter
- About 25 g sorrel sample and 500 ml distilled water were kept in a conical flask provided with glass condensers, and then boiled for 1 h at 70°C
- The mixture was cooled and filtered, and the filtrate was poured into different Petri dishes, which were dried in a fan oven at 70°C until it got dried as a film. It was then crushed, and the dried powder was dissolved in distilled water and placed in dark bottles to prevent oxidation so that it could be saved until the experiment.^[16]

Grouping and feeding of rats

The experiment was performed in the Department of Anatomy, Faculty of Medicine, Umm-AlQura University. All the rats were fed for 1 week on the designed basal diet before the experiment and were then divided into two main groups. The first group ($n = 10$ rats) was fed the basal diet only as a negative control (C –ve) for 28 days, and the rats of the second main group ($n = 30$ rats) were injected subcutaneously (s/c) with CCl₄ to induce liver damage.^[17]

The rats were then divided into four groups ($n = 10$ rats) as follows:

- Group 1 was fed on the basal diet only, as a negative control (C –ve group)
- Group 2 was kept without any treatment as a positive control (C +ve group) and fed on basal diet for 28 days
- Group 3 was fed on basal diet plus oral feeding of sorrel extract at a single dose of 250 mg/kg (b.wt.)
- Group 4 was fed on basal diet plus oral feeding of sorrel extract at a single dose of 500 mg/kg (b.wt.).

Table 1: Effect of orally administrated sheep sorrel (*Rumex acetosella*) on body weight gain, relative liver, and kidneys' weight in carbon tetrachloride-intoxicated rats

Groups	Parameters		
	BWG/28 days (g)	Liver (g)	Kidneys (g)
Control			
–ve	64.00±2.64 ^a	5.75±2.95 ^a	1.75±0.92 ^a
+ve	8.00±0.70 ^d	4.25±1.83 ^a	0.97±0.07 ^a
Sorrel (mg/kg)			
250	35.00±2.29 ^c	4.98±2.69 ^a	1.70±0.27 ^a
500	20.50±1.82 ^b	5.20±1.00 ^a	1.75±0.13 ^a
SD	3.29	1.49	1.37

Values denote arithmetic means±SD of the means. Means with different letters (a, b, c, and d) in the same column differ significantly at $P \leq 0.05$ while one-way ANOVA test showed that the values with similar letters are nonsignificant. ANOVA: Analysis of variance; SD: Standard deviation; BWG: Body weight gain

Induction of liver intoxication in rats

According to the method suggested by Jayasekhar *et al.*,^[17] 36 male albino rats were treated with subcutaneous injection of CCl₄ mixed with paraffin oil in 50% V/V (2 ml/kg b.wt.) twice a week for 2 weeks to induce chronic liver damage.

After CCl₄ had been injected, the blood samples were obtained from the rats by retro-orbital method to ensure the occurrence of liver injury and to estimate the liver function.

Blood sampling

At the end of the experiment period (28th day), the rats were sacrificed under ether anesthesia. Blood samples were then obtained by retro-orbital method in a clean and dry centrifuge tube. The samples were allowed to clot by placing them at room temperature for 20 min and then centrifuged at 1500 revolutions per minute (rpm) for 15 min. Serum samples were collected by a dry clean syringe, poured in Wasserman tubes, and then kept frozen in a refrigerator at 10°C until biochemical analysis. Thereafter, the liver, spleen, heart, lungs, and kidneys were removed from the animal's body and washed in saline solution, which were subsequently dried and weighted. Relative weights of the mentioned organs were calculated using the following formula:

$$\text{Relative organ weight} = \frac{\text{Organ weight}}{\text{body weight}} \times 100$$

For fixation before the histopathological investigation, the organs were kept in formalin solution (10% V/V) as per the method described by Drury and Wallington.^[18]

Biological evaluation

At the end of the experiment period (8 weeks), the rats were sacrificed under diethyl ether anesthesia. Blood samples were obtained in a clean, dry centrifuge tube using the retro-orbital method. They were allowed to clot at 25°C for 20 min and then centrifuged at 3000 rpm for 15 min. Serum samples, collected using a dry, clean syringe, were poured in Wasserman tubes and kept frozen in a refrigerator at -10°C till biochemical analysis. Liver, spleen, heart, lungs, and kidneys were removed and washed in saline solution, which were later dried and weighted. Relative weights of the organs were calculated according to the method described by Drury and Wallington.^[18]

During the initial period of the experiment, all the rats were weighed once a week, and the consumed diets (daily food intake) were recorded every day. At the end of the experiment, the biological evaluation of the experimental diets was also carried out by determining the body weight gain percentage (BWG%) and feed efficiency ratio, as described by Chapman *et al.*^[19] The daily food intake was also calculated.

Biochemical analysis

At the end of the experimental period, the blood samples were collected for serum separation, which was further used to determine the following parameters: (a) serum liver enzymes (alanine transaminase [ALT], aspartate transaminase [AST], and alkaline phosphatase [ALP]); (b) total protein (TP), albumin (ALB), and globulin (GLOB); (c) total cholesterol (TC); (d) triglycerides (TGs); (e) lipoprotein fractions (HDL-C, LDL-C, and very-LDL-C [VLDL-C]); (f) creatinine; (g) urea; and (h) uric acid.^[20-27]

Tissue specimens

Specimens from liver, kidney, and heart of all the experimental rats were collected at the end of the experiment.

Histopathological examination

The tissue specimens, collected from liver, kidney, and heart of rats of different groups, were immediately fixed in 10% formalin solution. After proper fixation, the specimens were dehydrated in ethyl alcohol, cleared in xylol, and finally embedded followed by paraffin casting. Thin paraffin sections were prepared, which were later stained with hematoxylin and eosin stain.^[28] The histological examination was done in the histology laboratory in the Department of Anatomy, Faculty of Medicine, the Umm Al-Qura University, Saudi Arabia.

Statistical analysis

The obtained data were statistically analyzed using computerized Superior Performing Statistical Software (SPSS) at SAS Institute, Cary, NC, USA. Effects of different treatments were analyzed by one-way analysis of variance test using the Duncan's multiple range test, and $P < 0.05$ was also used to indicate the significance level between different groups.^[29]

RESULTS AND DISCUSSION

Effect on body weight gain, liver's and kidneys' weight

Data listed in Table 1 show the effect of orally administrated water herbal extract of sorrel root on BWG, relative liver and kidneys' weight in CCl₄-intoxicated rats.

CCl₄-intoxicated rats of control (+ve) group showed 8 ± 0.70 g/28 days BWG compared to 64 ± 2.64/28 days BWG shown by the control (-ve) group. These results highlighted the significant decrease between the control positive and negative groups.

All rats, poisoned by CCl₄ and administrated with all tested herbs, showed a significant increase in BWG as compared to the control (+ve) group.

Concerning the liver and kidneys' weight gain, there were nonsignificant changes between control (-ve) and control (+ve) groups when compared to all other tested groups. These findings agreed to the ideology of Girish *et al.*,^[30] who supported the use of these active phytochemicals of silymarin against the toxic liver injury. The silymarin drug may be helpful in preventing the lipid peroxidation and augment the antioxidant defense system or regeneration of hepatocytes. These active phytochemicals may be developed as drugs for the treatment of liver diseases.

Effect on heart, spleen, and lungs' weight

Data listed in Table 2 show the effect of orally administrated water extracts of sheep sorrel root, given in two doses, on the relative heart, spleen, and lungs' weight of the CCl₄-poisoned rats.

Table 2: Effect of orally administrated sheep sorrel (*Rumex acetosella*) on relative heart, spleen, and lungs' weight of the carbon tetrachloride-intoxicated rats

Groups	Parameters		
	Heart (g)	Spleen (g)	Lungs (g)
Control			
-ve	1.15±0.053 ^a	1.25±0.076 ^a	1.65±0.17 ^a
+ve	0.65±0.029 ^b	0.45±0.047 ^b	0.68±0.09 ^b
Sorrel (mg/kg)			
250	0.92±0.062 ^a	0.92±0.064 ^a	1.48±0.18 ^a
500	1.04±0.083 ^a	0.83±0.044 ^a	1.52±0.03 ^a
LSD	0.42	0.618	0.602

Values denote arithmetic means±SD of the means. Means with different letters (a and b) in the same column differ significantly at $P \leq 0.05$ while one-way ANOVA test showed that the values with similar letters are nonsignificant. ANOVA: Analysis of variance; SD: Standard deviation; BWG: Body weight gain; LSD: Least standard deviation

It is clear that the heart weight of the CCl₄-injected rats of the control (+ve) group was 0.65 ± 0.029 g whereas the rats of the control (-ve) group weighed 1.15 ± 0.053 g, when compared in terms of the relative weight value. There was a significant level of increase in the control (-ve) and (+ve) group of rats. On the other hand, a nonsignificant difference was recorded when the CCl₄-poisoned rats and the orally administered water herb extracts' rats were compared to control (+ve) group.

In case of the spleen weight, there was a significant decrease in the weights of the CCl₄-injected rats of the control (+ve) group compared to the control (-ve) group, which were 0.45 ± 0.047 g and 1.25 ± 0.076 g, respectively. When compared to the control (+ve) group, rats injected with CCl₄ and orally administered with all tested herbs showed nonsignificant changes.

Concerning to the lungs' weight, there was a significant decrease in control (+ve) group in comparison to the control (-ve) group, which were 0.68 ± 0.09 g and 1.65 ± 0.17 g, respectively. All the rats, injected with CCl₄ and orally administered with all tested herbs, showed a significant increase in levels compared to the control (+ve) group and non-significant changes when compared to the control (-ve) group. These results were in agreement with the findings of Cetinkaya *et al.*,^[31] who examined the extract from the roots of RP, L. (*Polygonaceae*) (D-1) for its effects on rat's liver, erythrocyte antioxidant enzyme systems, and lipid peroxidation. As per their study, the measurements of the glutathione peroxidase (GSH-Px), superoxide dismutase (SOD), and catalase (CAT) activities along with the malondialdehyde (MDA) levels of liver and erythrocytes in the D-1-administered animals showed an increase in the GSH-Px and SOD activities, when compared to the control group. No significant decrease was observed in CAT activity, and no changes were observed in MDA levels.

Tsai *et al.*^[32] showed that silymarin, a standardized extract of the *Silybum marianum*, having a long tradition of herbal remedy, was introduced a few years ago as a hepatoprotective agent. However, the therapeutic effects of silymarin remain undefined. CCl₄ is used extensively as a xenobiotic to induce oxidative stress and as hepatic toxin for experimental induction of liver fibrosis in the laboratory, which indicated that silymarin may have the potential to increase the resolution of the CCl₄-induced liver fibrosis in rats.

Biochemical analysis

Data from Tables 3-8 show the effect of oral administration of sheep sorrel (*Rumex acetosella*) in two doses (250 or 500 mg/kg b.wt.) on liver enzymes (AST, ALT, and ALP), TP, ALB, GLOB, serum lipid profile (TC, TGs, and total lipids [TLs]), serum levels of lipoprotein fractions (HDL-C, LDL-C, and VLDL-C), glucose, and kidney functions (creatinine, urea, and uric acid) in rats intoxicated with CCl₄.

Effect on aspartate transaminase and alanine transaminase

Effects of orally administered sheep sorrel (*R. acetosella*) on AST and ALT weight of rats intoxicated with CCl₄ are recorded in Table 3.

Table 3 clearly states that the serum levels of AST enzyme of the CCl₄-intoxicated rats were 16 ± 1.98 IU/l in control (-ve) group compared to the 36 ± 2.01 IU/l in control (+ve) group. These results showed that there was a significant decrease in control (+ve) group compared to the control (-ve) group.

In case of ALT, the rats intoxicated with CCl₄ measured 4 ± 1.73 IU/l in control (-ve) group compared to the 15 ± 3.0 IU/l in control (+ve) group, which shows that there was a significant increase in control (+ve) group compared to the control (-ve) group. The best treatments were resulted in *Burdock* root (500 mg/kg) and sorrel root (500 mg/kg),

Table 3: Effect of oral administrated sheep sorrel (*Rumex acetosella*) on aspartate transaminase and alanine transaminase in rats intoxicated with carbon tetrachloride

Groups	Parameters	
	AST (IU/L)	ALT (IU/L)
Control		
-ve	16.00±1.98 ^d	4.00±1.73 ^d
+ve	36.00±2.01 ^a	15.00±3.00 ^a
Sorrel (mg/kg)		
250	32.00±2.64 ^b	7.20±2.02 ^c
500	31.75±2.54 ^b	4.00±2.29 ^d
LSD	1.304	1.31

Values denote arithmetic means±SD of the means. Means with different letters (a, b, c, and d) in the same column are significantly different at P≤0.05 while the one-way ANOVA test showed that the values with similar letters were nonsignificant. AST: Aspartate transaminase; ALT: Alanine transaminase; LSD: Least standard deviation; SD: Standard deviation; ANOVA: Analysis of variance

Table 4: Effect of orally administrated sheep sorrel (*Rumex acetosella*) on ALP and GGT weights in rats intoxicated with carbon tetrachloride

Groups	Parameters	
	ALP (IU/L)	GGT (IU/L)
Control		
-ve	71±1.59 ^d	5.2±2.03 ^b
+ve	184±2.61 ^a	10±2.75 ^a
Sorrel (mg/kg)		
250	121.5±3.50 ^a	5.9±2.59 ^b
500	91.3±3.04 ^c	3.6±2.12 ^c
SD	2.186	0.987

Values denote arithmetic means±SD of the means. Means with different letters (a, b, c, and d) in the same column are significantly different at P≤0.05 while one-way ANOVA test showed that the values with similar letters are nonsignificant. ALP: Alkaline phosphatase; GGT: Gamma-glutamyl transferase; SD: Standard deviation; ANOVA: Analysis of variance

Table 5: Effect of orally administrated sheep sorrel (*Rumex acetosella*) on total protein, albumin, and globulin protein levels in rats intoxicated with carbon tetrachloride

Groups	Parameters		
	TP (g/dl)	ALB (g/dl)	GLOB (g/dl)
Control			
-ve	7.35±0.53 ^a	3.8±0.58 ^a	3.5±0.29 ^d
+ve	10.00±0.65 ^a	2.8±0.08 ^b	7.3±0.38 ^a
Sorrel (mg/kg)			
250	7.95±0.41 ^a	2.9±0.27 ^b	5.05±0.12 ^b
500	8.5±0.50 ^a	3.3±0.75 ^b	4.7±0.38 ^c
SD	2.97	0.926	0.998

Values denote arithmetic means ± SD of the means. Means with different letters (a, b, c, d) in the same column are significantly different at P≤0.05 while one-way ANOVA test showed that the values with similar letters are nonsignificant. TP: Total protein; ALB: Albumin; GLOB: Globulin; ANOVA: Analysis of variance; SD: Standard deviation

which were 4 ± 2.64 and 4 ± 2.29 IU/l, respectively. These results were supported by Wagoner *et al.*,^[33] who demonstrated that silymarin, an extract from *S. marianum*, and its purified flavonolignans have shown inhibition to hepatitis C virus infection, both *in vitro* and *in vivo*. The mechanisms of silymarin's antiviral action appear to block the virus's entry and transmission, possibly by targeting the host cell. Jain *et al.*^[34] also investigated the effects of silymarin and *naringenin* in counteracting the arsenic-induced hepatic oxidative stress postexposure. The results

Table 6: Effect of orally administrated with sheep sorrel (*Rumex acetosella*) on total lipid, total cholesterol, and triglycerides in rats intoxicated with carbon tetrachloride

Groups	Parameters		
	TL (g/dl)	TC (g/dl)	TG (g/dl)
Control			
-ve	244±3.61 ^c	101.1±2.05 ^c	73±2.65 ^d
+ve	584±3.46 ^a	146±2.64 ^a	213±2.57 ^a
Sorrel (mg/kg)			
250	499.2±2.55 ^b	124.8±2.44 ^b	130.2±2.55 ^a
500	544±2.51 ^a	136±2.64 ^a	143±2.65 ^a
SD	1.77	4.25	1.04

Values denote arithmetic means±SD of the means. Means with different letters (a, b, c, and d) in the same column are significantly different at $P \leq 0.05$ while one-way ANOVA test showed that the values with similar letters are nonsignificant. ANOVA: Analysis of variance; SD: Standard deviation; TL: Total lipid; TC: Total cholesterol; TG: Triglycerides

Table 7: Effect of orally administrated sheep sorrel (*Rumex acetosella*) on high-density lipoprotein, low-density lipoprotein, and very low-density lipoprotein in rats intoxicated with carbon tetrachloride

Groups	Parameters		
	HDL (mg/dl)	LDL (mg/dl)	VLDL (mg/dl)
Control			
-ve	68.45±1.51 ^c	18.20±2.03 ^c	14.60±1.51 ^c
+ve	61.50±2.10 ^d	41.80±2.89 ^a	42.60±2.26 ^a
Sorrel (mg/kg)			
250	80.80±1.63 ^a	17.90±3.44 ^c	26.04±1.98 ^a
500	65.20±3.47 ^c	17.80±2.49 ^c	23.00±1.73 ^b
SD	1.36	2.98	2.59

Values denote arithmetic means±SD of the means. Means with different letters (a, b, c, and d) in the same column are significantly different at $P \leq 0.05$ while one-way ANOVA test shows that the values with similar letters are nonsignificant. HDL: High-density lipoprotein; LDL: Low-density lipoprotein; VLDL: Very low-density lipoprotein; SD: Standard deviation; ANOVA: Analysis of variance

Table 8: Effect of oral administration with sheep sorrel (*Rumex acetosella*) on creatinine, urea, and uric acid in rats intoxicated with carbon tetrachloride

Groups	Parameters		
	Creatinine (mg/dl)	Urea (mg/dl)	Uric acid (mg/dl)
Control			
-ve	0.60±0.01 ^b	56.40±1.83 ^b	2.10±0.02 ^a
+ve	1.50±0.3 ^a	69.00±2.65 ^a	5.40±0.08 ^a
Sorrel (mg/kg)			
250	0.46±0.04 ^b	47.60±3.19 ^c	2.30±0.04 ^a
500	0.40±0.02 ^b	56.50±1.80 ^b	3.10±0.01 ^a
SD	0.71	4.42	3.15

Values denote arithmetic means±SD of the means. Means with different letters (a, b, c) in the same column are significantly different at $P \leq 0.05$ while one-way ANOVA test showed that the values with similar letters are nonsignificant. SD: Standard deviation; ANOVA: Analysis of variance

highlighted the flavonoid's antioxidant potential, which might be beneficial in the clinical recovery of cases exposed to arsenic. These flavonoids can be incorporated into the diet or cosupplemented during the chelation treatment that may provide a protective effect against the arsenite-induced cytotoxicity.

Effect on alkaline phosphatase and gamma-glutamyl transferase

Data presented in Table 4 show the effect of orally administrated sheep sorrel (*R. acetosella*) on ALP and gamma-glutamyl transferase (GGT) weights of rats intoxicated with CCl₄.

It is clear that there was a significant increase in ALP and GGT values for the control (+ve) group compared to the control (-ve) group, which were 184.00 ± 2.61 and 71.00 ± 1.59 IU/l for ALP and 10.00 ± 2.75 and 5.20 ± 2.03 IU/l for GGT, respectively. Rats, injected with CCl₄ and orally administrated with all the tested herb extracts, showed a significant decrease in ALP and GGT when compared to the control (+ve) group.

These data were confirmed by Ahmed *et al.*,^[8] who examined the possible hepatoprotective effect of aminoguanidine in comparison to silymarin, and investigated the possible beneficial effects of the combined action of aminoguanidine and silymarin drugs on CCl₄-induced liver fibrosis. It was concluded that aminoguanidine possesses protective effect against CCl₄-induced hepatotoxicity through its iNOS inhibition and antioxidant effects. In addition, the combination of AG with silymarin has more potent hepatoprotective effect than aminoguanidine.

Effect on total protein, albumin, and globulin

Data illustrated in Table 5 show the effect of orally administrated sheep sorrel (*R. acetosella*) on TP, ALB, and GLOB protein levels in rats intoxicated with CCl₄.

From Table 5, it is clear that in the rats poisoned with CCl₄, the serum levels of TP in control (-ve) group was 7.35 ± 0.53 g/dl compared to 10.00 ± 0.65 g/dl in control (+ve) group, which points at the nonsignificant difference between control (+ve) and (-ve) groups.

All rats, poisoned with CCl₄ and orally fed with all the tested herbs, exhibited nonsignificant changes when compared to control (+ve) group for the ALB protein level. Without treatment, the protein level in control (+ve) group of CCl₄-intoxicated rats was 2.80 ± 0.08 g/dl compared to 3.80 ± 0.58 g/dl in control (-ve) group. These results showed the significant decrease in control (+ve) group compared to control (-ve) group. All the tested groups showed nonsignificant changes when compared to control (+ve) group.

In case of the GLOB protein level, there was a significant increase in control (+ve) group (7.30 ± 0.30 g/dl) compared to control (-ve) group (3.50 ± 0.29 g/dl). All rats, injected with CCl₄ and orally administrated with all tested herbs, showed a significant decrease when compared to control (+ve) group.

These results proved to be in agreement with Cetinkaya *et al.*,^[31] who reported on the effect of the aqueous extract from the roots of RP, *L. (Polygonaceae)* (D-1). They investigated the effects of the D-1 extract on rat liver and erythrocyte antioxidant enzyme systems and lipid peroxidation. GSH-Px, SOD, CAT, and MDA levels of liver and erythrocytes in D-1-administered animals showed that there was an increase in the GSH-Px and SOD activities when compared to that of controls. No significant decrease was observed in CAT activity, and no changes in MDA levels were observed.

Effect on total lipids, total cholesterol, and triglycerides

Data presented in Table 6 show the effect orally administrated sheep sorrel (*R. acetosella*) on TLs, TC, and TGs in rats intoxicated with CCl₄. Table 6 shows that control (+ve) group measurements for TL, TC, and TG were 584 ± 3.46, 146 ± 2.64, and 213 ± 2.57 g/dl, respectively, while the control (-ve) group measurements were 244 ± 3.61, 101.1 ± 2.05, and 73 ± 2.65 g/dl, respectively. These data denote a significant increase in the control (+ve) group when compared to control (-ve) group for the previously mentioned parameters. All rats, poisoned with CCl₄ and orally fed with all tested herbs, showed a significant decrease in the mentioned parameters when compared to control (+ve) group. These findings were in agreement with the results of Muriel and Mourelle,^[35] who studied the effect of silymarin on liver lipid peroxidation and membrane lipid alterations induced by an acute dose of CCl₄. Their

study results indicate that silymarin can protect against the alterations induced by CCl₄ on the liver plasma membrane by modifying its phospholipid content through its antioxidant properties. In this concern, Lin *et al.*^[36] conducted a study on *A. lappa* L., root and suggested that it has anti-inflammatory and free radical scavenging activity, which could have inhibitory effects on carrageenan-induced paw edema and CCl₄-induced hepatotoxicity. Based on similar results, Zick *et al.*^[37] also concluded that breast cancer, being a major cause of morbidity, mortality, and medical expenditures among women in Canada, can be treated through herbal methods. Essiac (Resperin Canada Limited, Waterloo, Ontario, Canada) is a blend of at least four herbs *Burdock* root (*A. lappa*), Indian rhubarb (*Rheum palmatum*), sheep sorrel (*R. acetosella*), and the inner bark of *slippery elm* (*Ulmus fulva* or *Ulmus rubra*). This blended herb has become one of the more popular herbal remedies for breast cancer treatment, secondary prevention, improving the quality of life, and controlling negative effects of conventional breast cancer treatment.

Effect on high-density lipoprotein, low-density lipoprotein, and very-low-density lipoprotein

Table 7 shows the effect of orally administrated sheep sorrel (*R. acetosella*) on HDL, LDL, and VLDL in rats intoxicated with CCl₄.

Data illustrated in Table 7 show the effect of orally administrated sorrel root on HDL, LDL, and VLDL in the rats intoxicated with CCl₄. These data showed that in rats, injected with CCl₄ and not treated, the HDL level in control (+ve) group was 61.5 ± 2.10 mg/dl compared to 68.45 ± 1.5 mg/dl in control (-ve) group. These results showed that there was a significant decrease in control (+ve) group compared to control (-ve) group. All rats, injected with CCl₄ and orally administrated with all tested herbs, showed a significant increase in HDL when compared to control (+ve) group and showed an insignificant increase in sorrel 500 mg/kg when compared to control (-ve) group, which was 65.2 ± 3.47 mg/dl. Regarding the LDL and VLDL levels, there was a significant increase in control (+ve) group when compared to control (-ve) group. All rats, injected with CCl₄ and orally fed on all tested herbs, showed a significant decrease in LDL and VLDL when compared to control (+ve) group. These findings agreed with Flora *et al.*,^[38] who demonstrated that silymarin, derived from the plant *S. marianum*, has been used for centuries as a natural remedy for liver and biliary tract diseases. As interest for an alternative therapy has emerged in the United States, gastroenterologists have encountered increasing numbers of patients taking silymarin with little understanding about its purported properties. Silymarin and its active constituent silybin have been reported to act as antioxidants scavenging

free radicals and inhibiting lipid peroxidation. Studies also suggested that they protect against genomic injury, increase hepatocyte protein synthesis, decrease the activity of tumor promoters, stabilize most cells, chelate iron, and slow down the calcium metabolism. Cetinkaya *et al.*^[31] also investigated on the aqueous extract from the roots of RP L. (*Polygonaceae*) for its effects on liver and erythrocyte antioxidant enzyme systems and lipid peroxidation in rats. GSH-Px, SOD, CAT activities, and MDA measurement levels of liver and erythrocytes in D-1-administrated animals showed that there was an increase in GSH-Px and SOD activities when compared to that of controls. No significant decrease was observed in CAT activity, and no changes in MDA levels were observed.

Effect on creatinine, urea, and uric acid

Table 8 shows the effect of orally administrated with sheep sorrel (*R. acetosella*) on creatinine, urea, and uric acid in rats intoxicated with CCl₄.

Data illustrated in Table 8 show a significant increase in control (+ve) group with 69 ± 2.65 mg/dl compared to 56.40 ± 1.83 mg/dl in control (-ve) group. All rats, injected with CCl₄ and orally administrated with all tested herbs, showed a significant decrease in serum urea when compared to control (+ve) group. Rats, administrated with CCl₄ and sorrel 250 mg/kg, showed the most significant decrease compared to either control (+ve) or (-ve) groups. Concerning creatinine, there was a significant increase in control (+ve) group compared to control (-ve) group. All groups showed a significant decrease when compared to control (+ve) group except for seed 500 mg/kg. In case of uric acid, there were nonsignificant differences between control (+ve) and (-ve) groups. In addition, there were nonsignificant changes between all the groups when compared to control (+ve) group. These data were supported by the findings in the study of Brown,^[39] who mentioned that, as per some folk herbalists, dried *Burdock* could be considered to be a diuretic, diaphoretic, and a blood-purifying agent. The seeds of *A. lappa* have been used in traditional Chinese medicine, under the name niupangzi (also coined as niúbàng). Karimi *et al.*^[40] also studied the protective effect of methanolic extract of the seeds and silymarin against cisplatin-induced renal toxicity. They found it to be effective in protecting against the toxicity and might serve as a novel combination agent with cisplatin to limit renal injuries.

Histopathological results

Microscopically view of a rat from Group 1 revealed the normal histological structure of hepatic lobule, normal renal tissue, and normal cardiac muscle (×40) [Figure 1a-c].

Meanwhile, the liver of a rat from Group 2 showed focal hepatic necrosis associated with leukocyte infiltration, congestion of hepatportal blood

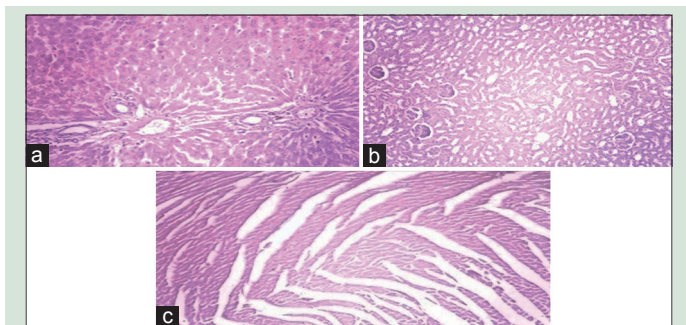


Figure 1: (a) The picture shows normal hepatocytes, central vein, and portal tracts (×40) (at column width); (b) the picture shows within normal renal tissue (×40) (at column width); (c) the picture shows normal cardiac muscle fiber (×40) (at column width)

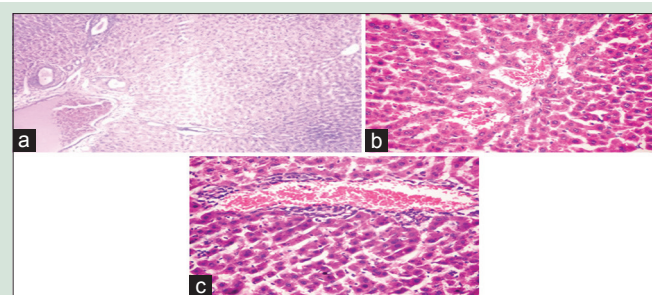


Figure 2: (a) Degenerative changes of hepatocytes; (b) the picture shows congestive changes of hepatocytes; (c) the picture shows infiltration and hemorrhages of hepatocytes (×40) (at full page width)

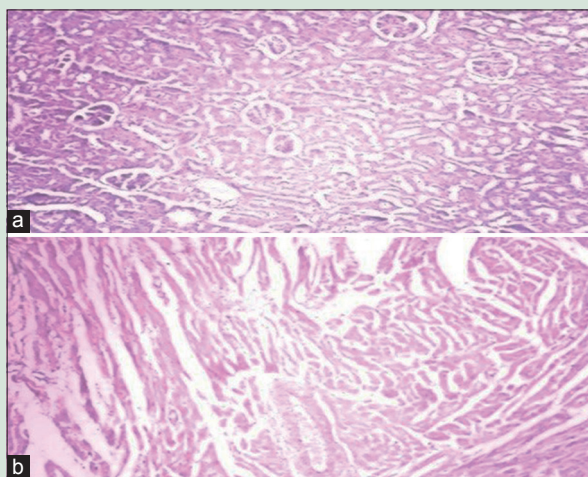


Figure 3: (a) The picture shows degenerative changes of the tubular epithelium and glomeruli (×40) (at column width); (b) the picture shows mild hydropic degeneration of cardiac muscle fiber (×40) (at column width)

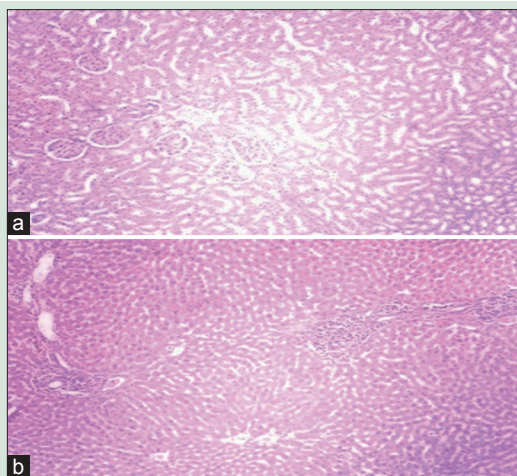


Figure 5: (a) The picture shows minimal degenerative changes of the tubular epithelium and glomeruli (×40) (at column width); (b) the picture shows minimal degenerative changes with infiltration of portal tracts with mono-nuclear cells (×40) (at column width)

vessels, and portal infiltration with leukocytes, necrosis of hepatocytes, dilatation of hepatic sinusoids, and binucleated hepatocytes. However, the other sections revealed Kupffer cells activation and portal infiltration with leukocytes as well as focal hepatic necrosis. Kidney showed degenerative changes of the tubular epithelium and glomeruli. Heart shows mild hydropic degeneration of cardiac muscle fiber [Figures 2 and 3a, b].

In Group 3, liver of a rat revealed mild degenerative changes in dilatation of central vein and hepatic sinusoids as well as focal hepatic necrosis associated with leukocyte infiltration, and tubule epithelium and glomeruli [Figure 4a-c].

Apparently, normal hepatic lobule, noticed in the liver of a rat from Group 4, revealed minimal histopathological changes [Figures 5a, b and 6]. These findings agreed with Girish *et al.*,^[30] who supported the use of the active phytochemicals of silymarin against toxic liver injury, which might prevent the lipid peroxidation and augment the antioxidant defense system or regeneration of hepatocytes. It also agreed with the findings of Emelike and Dapper,^[41] which concluded that the

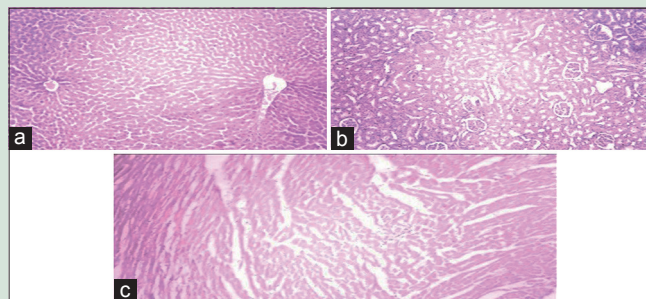


Figure 4: (a) The picture shows mild degenerative changes of the hepatocytes (×40) (at column width); (b) the picture shows mild degenerative changes of tubule epithelium and glomeruli (×100) (at column width); (c) the picture shows minimal degenerative changes of cardiac muscle fibers (×40) (at column width)

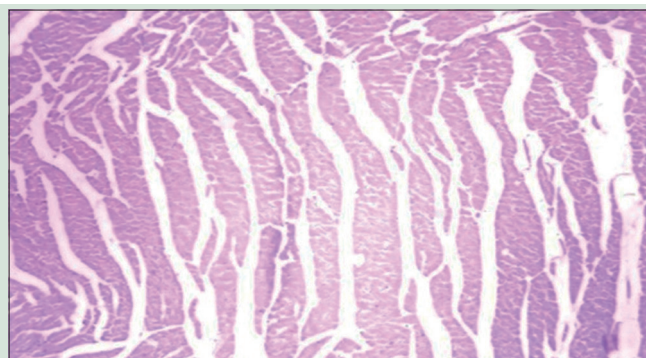


Figure 6: The picture shows minimal degenerative changes of cardiac muscle fibers (×40) (at column width)

sorrel extract could reduce the lipid peroxidation in CCl₄-induced liver damage in experimental animals.

In Group 4, the kidney and cardiac muscles showed minimal degenerative changes that agreed with studies supporting the protective and antioxidative effects of sorrel extract.^[4-7,40,42-48]

CONCLUSION

The sorrel extract demonstrated a significant enhancement in liver intoxication and all other tested parameters in this study. It helped in minimizing the structural tissue damages in the vital organs. Based on these results, sorrel can impair the liver function and maintain the functions of the vital organs.

Financial support and sponsorship

Nil.

Conflicts of interest

There are no conflicts of interest.

REFERENCES

1. Maton A, Hopkins J, McLaughlin CW, Johnson S, Warner MQ, LaHart D, *et al.* Human Biology and Health. Englewood Cliffs, New Jersey, USA: Prentice Hall; 1993.
2. Hashemi JM. *Hibiscus sabdariffa* calyx extract alleviate hepatotoxicity induced by carbon tetrachloride on male albino rats. *Nat Sci* 2014;12:111-20.
3. Singh N, Kamath V, Narasimhamurthy K, Rajini PS. Protective effect of potato peel extract against carbon tetrachloride-induced liver injury in rats. *Environ Toxicol Pharmacol* 2008;26:241-6.
4. Kucekova Z, Mlcek J, Humpolicek P, Rop O, Valasek P, Saha P. Phenolic

- compounds from *Allium schoenoprasum*, *Tragopogon pratensis* and *Rumex acetosa* and their antiproliferative effects. *Molecules* 2011;16:9207-17.
5. He SY, Gao YJ, Shentu JL, Chen KB. Combined effects of copper and simulated acid rain on copper accumulation, growth, and antioxidant enzyme activities of *Rumex acetosa*. *Ying Yong Sheng Tai Xue Bao* 2011;22:481-7.
 6. Gescher K, Hensel A, Hafezi W, Derksen A, Kühn J. Oligomeric proanthocyanidins from *Rumex acetosa* L. inhibit the attachment of herpes simplex virus type-1. *Antiviral Res* 2011;89:9-18.
 7. Lee NJ, Choi JH, Koo BS, Ryu SY, Han YH, Lee SI, *et al.* Antimutagenicity and cytotoxicity of the constituents from the aerial parts of *Rumex acetosa*. *Biol Pharm Bull* 2005;28:2158-61.
 8. Ahmed AF, Mahmoud MF, Ouf MA, El-Fathaah EA. Aminoguanidine potentiates the hepatoprotective effect of silymarin in CCL4 treated rats. *Ann Hepatol* 2011;10:207-15.
 9. Venkataraman R, Ramachandran V, Komoroski BJ, Zhang S, Schiff PL, Strom SC. Milk thistle, a herbal supplement, decreases the activity of CYP3A4 and uridine diphosphoglucuronosyl transferase in human hepatocyte cultures. *Drug Metab Dispos* 2000;28:1270-3.
 10. Sedaghat R, Roghani M, Ahmadi M, Ahmadi F. Antihyperglycemic and antihyperlipidemic effect of *Rumex patientia* seed preparation in streptozotocin-diabetic rats. *Pathophysiology* 2011;18:111-5.
 11. Predes FS, Ruiz AL, Carvalho JE, Foglio MA, Dolder H. Antioxidative and *in vitro* antiproliferative activity of *Arctium lappa* root extracts. *BMC Complement Altern Med* 2011;11:25.
 12. Lin SC, Chung TC, Lin CC, Ueng TH, Lin YH, Lin SY, *et al.* Hepatoprotective effects of *Arctium lappa* on carbon tetrachloride- and acetaminophen-induced liver damage. *Am J Chin Med* 2000;28:163-73.
 13. Chen X, Ying X, Zhang W, Chen Y, Shi C, Hou Y, *et al.* The hepatoprotective effect of fraxetin on carbon tetrachloride induced hepatic fibrosis by antioxidative activities in rats. *Int Immunopharmacol* 2013;17:543-7.
 14. Reeves PG, Nielsen FH, Fahey GC Jr. AIN-93 purified diets for laboratory rodents: Final report of the American Institute of Nutrition ad hoc writing committee on the reformulation of the AIN-76A rodent diet. *J Nutr* 1993;123:1939-51.
 15. Passmore R, Eastwood MA. *Human Nutrition and Dietetics*. 8th ed. Edinburgh, Scotland, UK: Churchill Livingstone; 1986.
 16. Nagm DR. Effect of Some Common Herbs on Weight Reduction in Obese rats. M.Sc. Thesis, Faculty of Home Economics, Menoufiya University, Al Minufiyah, Egypt; 2002. p. 17-8.
 17. Jayasekhar P, Mohanan PV, Rathinam K. Hepatoprotective activity of ethyl acetate extract of *Acacia catechu*. *Indian J Pharmacol* 1997;29:426-8.
 18. Drury RA, Wallington EA. *Carlton's Histological Technique*. 5th ed. Oxford, UK: Oxford University; 1967.
 19. Chapman DG, Castillo R, Campbell JA. Evaluation of protein in foods. I. A method for the determination of protein efficiency ratios. *Can J Biochem Physiol* 1959;37:679-86.
 20. Reitman S, Franke L. Colorimetric method for aspartate and alanine aminotransferase. *Am J Clin Pathol* 1957;28:26.
 21. Roy SE. Colorimetric determination of serum alkaline phosphatase. *Clin Chem* 1970;16:431-2.
 22. Dumas BT, Perry BW, Sasse EA, Straumfjord JV Jr. Standardization in bilirubin assays: Evaluation of selected methods and stability of bilirubin solutions. *Clin Chem* 1973;19:984-93.
 23. Jacobs NJ, Vandemark PJ. The purification and properties of the alpha-glycerophosphate-oxidizing enzyme of *Streptococcus faecalis* 10C1. *Arch Biochem Biophys* 1960;88:250-5.
 24. Gordon T, Castelli WP, Hjortland MC, Kannel WB, Dawber TR. High density lipoprotein as a protective factor against coronary heart disease. The Framingham Study. *Am J Med* 1977;62:707-14.
 25. Henry RJ, Cannon DC, Winkelman JW. *Clinical Chemistry Principal and Techniques*. 2nd ed. New York: Harper and Row Publisher; 1974.
 26. Patton CJ, Crouch SR. Spectrophotometric and kinetics investigation of the Berthelot reaction for the determination of ammonia. *Anal Chem* 1977;49:464-9.
 27. Schultz A. Uric acid. In: Kaplan LA, Pesce AJ, editors. *Clinical Chemistry: Theory, Analysis, and Correlation*. St. Louis, Toronto, Princeton: The C. V. Mosby Co.; 1984. p. 1261-6.
 28. Bancroft JD, Stevens A, Turner DR. *Theory and Practice of Histological Techniques*. 3rd ed. Edinburgh, London, Melbourne, New York: Churchill Livingstone; 1990. p. 726.
 29. Snedecor GW, Cochran WG. *Statistical Methods*. 6th ed. Ames, USA: Iowa State University Press; 1967.
 30. Girish C, Koner BC, Jayanthi S, Ramachandra Rao K, Rajesh B, Pradhan SC. Hepatoprotective activity of picroliv, curcumin and ellagic acid compared to silymarin on paracetamol induced liver toxicity in mice. *Fundam Clin Pharmacol* 2009;23:735-45.
 31. Cetinkaya O, Silig Y, Cetinkaya S, Demirezer LO. The effects of *Rumex patientia* extract on rat liver and erythrocyte antioxidant enzyme system. *Pharmazie* 2002;57:487-8.
 32. Tsai JH, Liu JY, Wu TT, Ho PC, Huang CY, Shyu JC, *et al.* Effects of silymarin on the resolution of liver fibrosis induced by carbon tetrachloride in rats. *J Viral Hepat* 2008;15:508-14.
 33. Wagoner J, Morishima C, Graf TN, Oberlies NH, Teissier E, Pêcheur EI, *et al.* Differential *in vitro* effects of intravenous versus oral formulations of silibinin on the HCV life cycle and inflammation. *PLoS One* 2011;6:e16464.
 34. Jain A, Yadav A, Bozhkov AI, Padalko VI, Flora SJ. Therapeutic efficacy of silymarin and naringenin in reducing arsenic-induced hepatic damage in young rats. *Ecotoxicol Environ Saf* 2011;74:607-14.
 35. Muriel P, Mourelle M. Prevention by silymarin of membrane alterations in acute CCl₄ liver damage. *J Appl Toxicol* 1990;10:275-9.
 36. Lin CC, Lu JM, Yang JJ, Chuang SC, Ujiiie T. Anti-inflammatory and radical scavenge effects of *Arctium lappa*. *Am J Chin Med* 1996;24:127-37.
 37. Zick SM, Sen A, Feng Y, Green J, Olatunde S, Boon H. Trial of Essiac to ascertain its effect in women with breast cancer (TEA-BC). *J Altern Complement Med* 2006;12:971-80.
 38. Flora K, Hahn M, Rosen H, Benner K. Milk thistle (*Silybum marianum*) for the therapy of liver disease. *Am J Gastroenterol* 1998;93:139-43.
 39. Brown D. *New Encyclopedia of Herbs and Their Uses: The Herb Society of America*. London, United Kingdom: DK Publishing; 2001.
 40. Karimi G, Ramezani M, Tahoonian Z. Cisplatin nephrotoxicity and protection by milk thistle extract in rats. *Evid Based Complement Alternat Med* 2005;2:383-6.
 41. Emelike CU, Dapper DV. Biochemical effects of oral administration of aqueous extract of *Hibiscus sabdariffa* on wistar albino rats. *IOSR J Dent Med Sci* 2013;9:35-9.
 42. Bako IG, Mabrouk MA, Abubakar A. Antioxidant effect of ethanolic seed extract of *Hibiscus sabdariffa* linn (*Malvaceae*) alleviate the toxicity induced by chronic administration of sodium nitrate on some haematological parameters in wistars rats. *Adv J Food Sci Technol* 2009;1:39-42.
 43. Kolawole OT, Akiibinu MO, Akanji MA. Assessment of the effect of aqueous extract of calyx of *Hibiscus sabdariffa* on some biochemical indices of renal function in rats. *Int J Pharm Sci* 2014;4:587-90.
 44. Olubunmi AW, Anthony JA. Phytochemical constituents and antioxidant activities of the whole leaf extract of *Aloe ferox* Mill. *Pharmacognosy Res* 2011;7:325-33.
 45. Bairwa NK, Sethiya NK, Mishra SH. Protective effect of stem bark of *Ceiba pentandra* linn. against paracetamol-induced hepatotoxicity in rats. *Pharmacognosy Res* 2010;2:26-30.
 46. Rahmani AH. *Cassia fistula* Linn: Potential candidate in the health management. *Pharmacognosy Res* 2015;7:217-24.
 47. Liang L, Wu X, Zhu M, Zhao W, Li F, Zou Y, *et al.* Chemical composition, nutritional value, and antioxidant activities of eight mulberry cultivars from China. *Pharmacogn Mag* 2012;8:215-24.
 48. Zhao J, Liu T, Xu F, You S, Xu F, Li C, *et al.* Anti-arthritis effects of total flavonoids from *Juniperus sabina* on complete Freund's adjuvant induced arthritis in rats. *Pharmacogn Mag* 2016;12:178-83.