

Clinical outcomes and time to recurrence of phototherapeutic keratectomy in Japan

Osamu Hieda, MD, PhD^{a,*}, Satoshi Kawasaki, MD, PhD^b, Kiyoshi Yamamura, MD^c,
Mina Nakatsukasa, MD, PhD^a, Shigeru Kinoshita, MD, PhD^d, Chie Sotozono, MD, PhD^a

Abstract

To assess the indications, outcomes and time to recurrence of phototherapeutic keratectomy (PTK) for anterior corneal pathology.

This study involved 714 eyes of 477 consecutive patients (mean age: 66.0 ± 15.2 years; range: 6–101 years) who underwent PTK as the initial surgical intervention for an anterior corneal pathology. In case of each patient, the cornea treated by PTK, followed up by slit-lamp examination and corrected distance visual acuity (CDVA) testing. Main outcome measures included Slit-lamp findings (1), CDVA (2), patients' complaints (3).

The mean follow-up period was 44.0 ± 38.8 months (range: 1–156 months).

We treated 376 granular corneal dystrophy (GCD) eyes, 238 band keratopathy (BK) eyes, 23 epithelium attachment disorder eyes, 16 gelatinous drop-like corneal dystrophy (GDLD) eyes, 13 lattice corneal dystrophy (LCD) eyes, and 48 eyes with other corneal diseases. The CDVA significantly improved from LogMAR 0.65 ± 0.61 pre PTK to LogMAR 0.26 ± 0.39 post PTK. A 2 or more lines increase of CDVA was observed in GCD eyes (67.8%), BK eyes (49.2%), epithelium attachment disorder eyes (57.1%), GDLD eyes (87.5%), LCD eyes (76.9%), and other corneal disease eyes (60.4%). The recurrence of BK was rare. GCD recurred slowly. Epithelium attachment disorder eyes remitted simultaneously, and recurred comparatively faster.

PTK was proved to be a successful therapy for all 6 corneal disease categories. Disease recurrence after PTK differed among the diseases, and surgeons should recognize the different rates of disease recurrence after PTK surgery.

Abbreviations: BK = band keratopathy, CDVA = corrected distance visual acuity, GCD = granular corneal dystrophy, GDLD = gelatinous drop-like corneal dystrophy, LCD = lattice corneal dystrophy, MMC = mitomycin-C, PTK = phototherapeutic keratectomy.

Keywords: corneal dystrophy, excimer laser, phototherapeutic keratectomy (PTK), recurrence rate

1. Introduction

Phototherapeutic keratectomy (PTK) is a surgical procedure utilizing a 193-nm argon fluoride excimer laser to treat anterior corneal pathology.^[1–5] Using the PTK technique, superficial

corneal opacification can be ablated, leaving the clear underlying stroma undisturbed. The PTK can be recommended in cases of corneal dystrophies,^[2,6–9] band keratopathy (BK),^[10] recurrent corneal erosion,^[11–13] and certain types of degenerative corneal diseases.^[14–16] PTK is thought to be a minimally invasive therapy for an anterior corneal pathology. The surgery is performed under topical anesthesia and allows to achieve faster visual recovery that can be obtained via all other procedures, such as manual keratectomy or lamellar keratoplasty. There is also a good feedback from the patients suffered from a superficial corneal pathology.^[17]

The efficacy of the PTK procedure varies widely, depending on the type of corneal disorder. For example, in case of TGBI related corneal dystrophies, the corrected distance visual acuity (CDVA) improvement rate of 2 or more lines is reportedly about 70%^[2] and for BK it is 33%.^[1] Early post PTK recurrence has been reported in some pathologies, such as Epithelial Basement Membrane Dystrophy,^[18] Reis-Bücklers corneal dystrophy,^[18] and homozygous granular corneal dystrophy (GCD) Type II.^[19] The number of attempts is limited as PTK makes stroma thinner. If the speed of recurrence is slow, we do not hesitate to recommend PTK for the patient. If the speed of recurrence is high, we discuss with the patient whether to perform PTK or not. Therefore, the decision on PTK performance can be made according to the speed of recurrence.

The purpose of the present study was to investigate the clinical outcomes and recurrence of PTK for anterior corneal pathology. This study included the largest sample size and longest follow-up periods than previous reports (Table 1), and we compared post PTK recurrence rate for various clinical pathologies.

Editor: Khaled Ahmed Abdelrahman.

All disclosures now or in the previous two years that related to any commercial companies or devices are employee (none), consultant or advisory positions (none); speaker bureaus (none), lecture fees (none); grant support (none), equity payments (none); patents (none); advisor to investment companies (none); and expert witness testimony (none).

The authors have no funding and conflicts of interests to disclose.

This retrospective review of patient data was approved by the Human Studies Committee of Kyoto Prefectural University of Medicine.

^a Department of Ophthalmology, Kyoto Prefectural University of Medicine, Kyoto,

^b Department of Ophthalmology, Osaka University, Osaka, ^c Baptist Eye Institute, Kyoto, ^d Department of Frontier Medical Science and Technology for Ophthalmology, Kyoto, Japan.

* Correspondence: Osamu Hieda, Department of Ophthalmology, Kyoto Prefectural University of Medicine, 465 Kajii-cho, Hirokoji-agaru, Kawaramachi-dori, Kamigyo-ku, Kyoto 602-0841, Japan (e-mail: ohieda@koto.kpu-m.ac.jp).

Copyright © 2019 the Author(s). Published by Wolters Kluwer Health, Inc. This is an open access article distributed under the terms of the Creative Commons Attribution-Non Commercial License 4.0 (CCBY-NC), where it is permissible to download, share, remix, transform, and buildup the work provided it is properly cited. The work cannot be used commercially without permission from the journal.

Medicine (2019) 98:27(e16216)

Received: 20 August 2018 / Received in final form: 30 May 2019 / Accepted: 31 May 2019

<http://dx.doi.org/10.1097/MD.0000000000016216>

Table 1
Review of patient outcomes post phototherapeutic keratectomy (PTK).

Author (year, country)	Cohort Size (eyes)	Follow-up period (range in months)	CDVA improvement (%)	Symptomatic Recurrence (Average months to recurrence \pm SD)	Comments
Sher (1991, USA) ^[1]	33	3–12	48	NA	First report: >30
Stark (1992, USA) ^[2]	27	3–24	78 (success rate)	NA	Lattice dystrophy: 11 eyes included
O'Bart (1993, UK) ^[10]	122	4–60	88 (smooth type only)	5 eyes	Band keratopathy: 122 eyes only
Maloney (1996, USA) ^[5]	232	1–24	45	5 eyes	First report: >200
Thomann (1996, Switzerland) ^[14]	17	3–32	NA	NA	BK: 17 eyes
Ookita (1999, Japan) ^[7]	37	25–49	78.4	(24.9 \pm 9.7)	Granular dystrophy: 37 eyes
Jain (1999, UK) ^[12]	77	6–55	NA	4 eyes	Recurrent erosion: 77 eyes
Ellies (2003, France) ^[21]	42	3.6–79.8	85.7	7 eyes	TGFBI-related dystrophy after PK
Oura (2007, Japan) ^[25]	5	36	80	0 eyes	GDLD: 5 eyes
Nassaralla (2012, Brazil) ^[13]	26	120–168	0	6 eyes	Recurrent erosion: 26 eyes
Chen (2013, China) ^[8]	44	80–120	NA	ABMD (13.5) Lattice dystrophy (19.7)	Longest follow-up without recurrent erosion

The above list shows the previous reports on PTK with the great number of cases and with the long follow-up periods. The type of disease was limited to the disease being studied (i.e., granular corneal dystrophy, band keratopathy, epithelium attachment disorder, GDLD, lattice corneal dystrophy).

ABMD = anterior basement membrane dystrophy, GDLD = gelatinous drop-like corneal dystrophy, NA = not available, SD = standard deviation, TGFBI = transforming growth factor beta-induced.

2. Methods

2.1. Study population

This study is a retrospective, single-center clinical case series. A total of 844 PTKs were performed at the Baptist Eye Clinic, Kyoto, Japan between August 1998 and March 2010. Among them, 714 PTKs (226 eyes of 154 males and 488 eyes of 323 females) who had an initial surgical intervention for the anterior corneal pathology were enrolled in this study. Exclusion criteria included cases of repeated PTK, PTKs performed after keratectomy or keratoplasty, and PTKs with a follow-up period of less than 1 month. The mean age of the enrolled subjects was 66.0 ± 15.2 years (range, 6–101 years), and the mean follow-up period was 44.0 ± 38.8 months (range, 1–156 months).

The indications for PTK were determined by a decrease in CDVA and painful epithelium attachment disorder. Written informed consent was obtained from all patients in accordance with the tenets set forth in the *Declaration of Helsinki*, and approval for this retrospective study was obtained from the Institutional Review Board of Kyoto Prefectural University of Medicine, Kyoto, Japan.

2.2. Preoperative diagnosis

Preoperative diagnoses (Table 2) included GCD (376 eyes), BK (238 eyes), epithelium attachment disorder that included recurrent corneal erosion, bullous keratopathy with no possibility of visual improvement, persistent epithelial defect, filamentary keratitis and shield ulcer (23 eyes), gelatinous drop-like corneal dystrophy (GDLD) (16 eyes), lattice corneal dystrophy (LCD) (13 eyes), and other corneal diseases (48 eyes). Patients were divided into 6 groups: granular dystrophy, BK, epithelium attachment disorder, GDLD, lattice dystrophy, and others. “Others” group consists of all diseases presented with 10 or less than 10 eyes. Disease diagnoses were primarily performed by clinical observation using slit-lamp microscopy.

In Japan, 80% to 90% of the GCD patients are ‘type II’, previously called Avellino dystrophy.^[20] During the study period, 28 GCD eyes were diagnosed by genetic screening, and most of them (26 of the 28, 93%) were ‘type II’. Thus, we regarded the clinical results of this article as ‘type II’ results. Among the GCD

patients, no autosomal dominant homozygous patients were included. All cases of LCD were considered to be ‘type 1’ in the slit lamp findings.

2.3. Interventional procedure

PTK was performed using one of three commercially available 193 nm excimer laser devices, each produced by a different company. 443 eyes of the 714 operated eyes were treated by the EC-5000 (Nidek Co. Ltd., Gamagori, Japan) excimer laser device mostly in the 6 mm optical zone with a 1 mm transition zone, 142 eyes were treated by the VISX (Johnson & Johnson Vision Care, Inc., Jacksonville, FL) excimer laser device mostly in the 6 mm optical zone, and 129 eyes were treated by the Technolas 217z (Bausch & Lomb, Rochester, NY) excimer laser device mostly in the 5.2 mm optical zone with a 3.6 mm transition zone.

In most of the PTK operations, the epithelium was removed directly by the excimer laser, and the ablation continued into the corneal stroma until removing the bulk of the pathological cornea. In a few cases, the epithelial layer was removed

Table 2
Phototherapeutic keratectomy: preoperative diagnoses.

	No. of eyes	No. of patients
Granular corneal dystrophy	376	229
Band keratopathy	238	167
Epithelium attachment disorder	23	21
Gelatinous drop-like corneal dystrophy	16	10
Lattice corneal dystrophy	13	8
Unknown corneal opacity	10	10
Thiel-Behnke corneal dystrophy	8	5
Amyloid deposit at the apex of keratoconus	9	9
Amyloid deposit without keratoconus	8	8
Macula corneal dystrophy	4	2
Schnyder corneal dystrophy	2	2
Multiple myeloma deposit	2	1
Opacity after epidemic keratoconjunctivitis	2	2
Pterygium-related opacity	1	1
Acanthamoeba-related opacity	1	1
Reis-Bücklers corneal dystrophy	1	1
Total	714	477

Table 3**Phototherapeutic keratectomy: corrected distance visual acuity and related characteristics.**

	Mean age (yr)	Gender (F/M)	Ablation Depth (um)	Mean Follow-up (months)	Cat-op (cases)	The time before achieving Post-CDVA (months)	Pre	Post	2 lines or more Improved (%)	2 lines or more Worse (%)
Granular dystrophy	66.2±11.8 (21–89)	253/123	106.7±12.6 (50–157)	47.2±40.3 (1–156)	115	13.9±17.4 (1 to 114)	0.52±0.38	0.17±0.21	67.8	0.26
Band keratopathy	72.9±12.1 (6–101)	180/58	100.3±15.6 (50–150)	40.8±37.0 (1–144)	72	13.0±16.9 (1 to 90)	0.78±0.76	0.42±0.51	49.2	3.78
Epithelium attachment disorder	57.1±16.8 (26–81)	15/8	90.3±25.3 (58–150)	34.4±37.7 (1–126)	3	6.8±9.9 (1 to 30)	1.16±1.06	0.46±0.76	57.1	0
Gelatinous drop-like dystrophy	32.1±11.8 (15–51)	7/9	106.8±26.0 (58–150)	57.1±30.3 (1–126)	0	20.6±18.7 (1 to 60)	1.09±0.80	0.20±0.18	87.5	0
Lattice dystrophy	51.2±15.6 (33–76)	6/7	106.1±9.8 (100–130)	44.8±25.6 (12–102)	2	14.8±18.36 (1 to 54)	0.83±0.50	0.16±0.21	76.9	0
Other corneal diseases	49.3±20.2 (9–88)	27/21	106.8±24.7 (50–151)	34.2±38.2 (1–156)	5	8.0±12.8 (1 to 54)	0.69±0.67	0.23±0.39	60.4	4.17
Total	66.0±15.2 (6–101)	448/226	104.1±15.7 (50–157)	44.0±38.8 (1–156)	197	13.1±16.9 (1 to 114)	0.65±0.61	0.26±0.39	61.2	1.68

The postoperative CDVA=the best CDVA recorded after PTK. Cat-op=the eyes in which cataract surgery was performed post PTK.

Ablation Depth=the mean calculated total ablation depth (epithelium and stroma). ()=range.

mechanically. In those cases, the total ablation depth was defined by the sum of the average epithelial layer thickness (50 μm) and the computationally-predicted excimer laser ablation depth. In 24 eyes with amyloid deposit at the apex of keratoconus, granular dystrophy, and other corneal diseases, small size (2–3 mm) ablation was performed to treat focal protrusions and opacifications. Thus, the ablation depth in those eyes could not be calculated due to the numerous ablations that were performed. When we use masking fluids and perform smoothing ablation, if it is not possible to resect it, it is excluded from the depth of ablation. The averages of the ablation depth according to the disease are shown in Table 3.

For 3 days before the PTK procedure, all patients were prescribed 0.5% cefmenoxime hydrochloride eye drops (Bestron; Senju Pharmaceutical Co. Ltd., Osaka, Japan) 4-times daily and 100 mg cefcapene pivoxil hydrochloride hydrate (Flomox; Shionogi & Co., Ltd., Osaka, Japan) orally for 3-times daily. After the PTK, all patients were initially administered 0.1% fluorometholone eye drops (Flumetholon; Santen Pharmaceutical Co., Ltd., Osaka, Japan) and 0.3% ofloxacin hydrate eye drops (Tarivid; Santen), or 0.5% levofloxacin hydrate eye drops (Cravit Ophthalmic Solution; Santen), or 0.3% gatifloxacin hydrate eye drops (Gatiflo Ophthalmic Solution; Senju) 4-times daily, with a tapering-off of the dosage over the following 12 weeks. Each patient wore a continuous-use soft contact lens on the operated cornea until the epithelial defect was closed. Epithelium attachment disorder necessitates that a soft contact lens be worn for several months after PTK. In all of the GDLT cases, a soft contact lens was worn, as much as possible, for a long-term post PTK period.

2.4. Definition of recurrence

In accordance with the previous study, the definition of the corneal pathology recurrence was different in relation to the type of corneal disease.^[18] As for the corneal diseases other than epithelium attachment disorder, the recurrence was defined by the significant level of increased opacification at the superficial layer of the central cornea that was associated with the decrease in the CDVA of 2 or more lines. When cataract surgery was performed following PTK, recurrence occurred at the point when CDVA decreased by 2 or more lines from the maximum visual acuity after cataract operation. When cataract progression occurred during the post PTK period, cataract surgery was performed, and if CDVA decrease remained 2 or more lines than

the highest CDVA after PTK, it was defined as recurrence. As for the epithelium attachment disorder, the recurrence was defined by the episode of the pain.

2.5. Data analysis

For the data analysis, the preoperative CDVA was recorded at the patient's last visit before the PTK. We examined CDVA of the patients in 1 month, 3 months and 6 months period after PTK surgery, and then continued it semi-annually. The postoperative CDVA was the best CDVA recorded after PTK. When cataract surgery was performed immediately after PTK, the highest CDVA after cataract surgery was regarded as postoperative CDVA. The two bullous keratopathy eyes with no light perception were excluded from VA analysis.

Refractive change was observed before and after PTK. The analysis of the refraction change was carried out only in cases with preoperative and postoperative corrected VA of logMAR 0.3 or more. Moreover, the exclusion criteria of the refraction change analysis were cases in which cataract surgery was performed within 3-months after PTK.

The time course analysis for the probability of recurrence after PTK was evaluated using the Kaplan–Meier survival analysis. The PTK survival rate was compared by the 6 clinical-diagnosis criteria with log-rank test. The minimum sample size in the stratified analysis of the single disease was set at 13. The difference between the 6 clinical diseases statistically analyzed with the meaningful probability *P* value assumed it to be lower than 0.0033 (0.05/15) in considerations with the multiple comparisons. Statistical analysis testing was performed with SPSS version 21 software for Windows (SPSS Inc., Chicago, IL).

3. Results

Superficial corneal pathologies were successfully cured in cases of all patients. In most cases, epithelial defects were sealed within 3 to 5 days, and VA improved slowly. The mean calculated total ablation depth (epithelium and stroma) was $104.0\pm 15.7\ \mu\text{m}$ (range, 50–157 μm). After PTK, 197 eyes (27.5%) underwent cataract surgery. The mean time before achieving CDVA was 13.1 ± 16.9 months (range, 1–114 months). The characteristics of the patients and depth of ablation, follow-up period, number of cataracts, and change in visual acuity before and after PTK for the 6 diseases are outlined in Table 2.

3.1. CDVA

After PTK, the mean CDVA improved significantly in cases of all 6 diseases (Table 3). A logMAR 0.2 or less decrease of CDVA was observed in 1 of 376 (0.26%) granular dystrophy eyes, in 9 of 238 (3.78%) BK eyes, and in 2 of 48 (4.17%) other corneal disease eyes. The reason of the visual impairment in 12 eyes was thought to be the progression of an eye disease other than the patient's original disease (7 irregular astigmatisms, 2 bullous keratopathy, 1 diabetic retinopathy, 1 cataract, and 1 methicillin-resistant *Staphylococcus aureus* keratitis immediately after PTK.

3.2. Time to recurrence

During the follow-up period, a significant level of recurrence of the original corneal pathology occurred in 53 eyes with granular dystrophy, 4 eyes with BK, 13 eyes with epithelium attachment disorder, 1 eye with GDLD, 4 eyes with lattice dystrophy, and 11 eyes with other corneal diseases. The results of the survival analysis for the recurrence of the 6 corneal pathologies after PTK are shown in Figure 1. The survival curves were different among the criteria of the 6 diseases at a statistically significant level ($P < .0001$, Log rank test). The P value of the log rank test for each pair of disease groups is shown in Table 4.

The median survival time for observing a significant recurrence for granular dystrophy was 120 months (restricted mean survival time: 114.6 months, 95% confidence interval (CI) 106.6–122.6).

Table 4

The P value of the log rank test for each pair of disease groups.

	Granular	Band	EAD	GDLD	Lattice
Granular					
Band	<.001*				
EAD	<.001*	<.001*			
GDLD	.67	.041	<.001*		
Lattice	.02	<.001*	.01	.13	
Others	.001*	<.001*	.002*	.06	.80

EAD = epithelium attachment disorder, GDLD = gelatinous drop-like dystrophy. significant P value was $P < .0033$.

Granular dystrophy recurred significantly faster than BK, and later than epithelium attachment disorder ($P < .0001$). Slit-lamp examination showed signs of increased central opacification of the superficial cornea within 3 to 4 years post PTK for GCD, yet VA had not decreased more than logMAR0.2 in most cases at that point (Fig. 2).

There were only 4 BK eyes with significant recurrence during the follow-up period. The restricted mean survival time for observing a significant recurrence for BK was 139.7 months (95% CI 134.9–144.2). Slit-lamp examination rarely showed signs of increased central opacification after PTK for BK (Fig. 3). BK recurred significantly later than granular dystrophy, epithelium attachment disorder, lattice dystrophy, and the other corneal diseases ($P < .0001$).

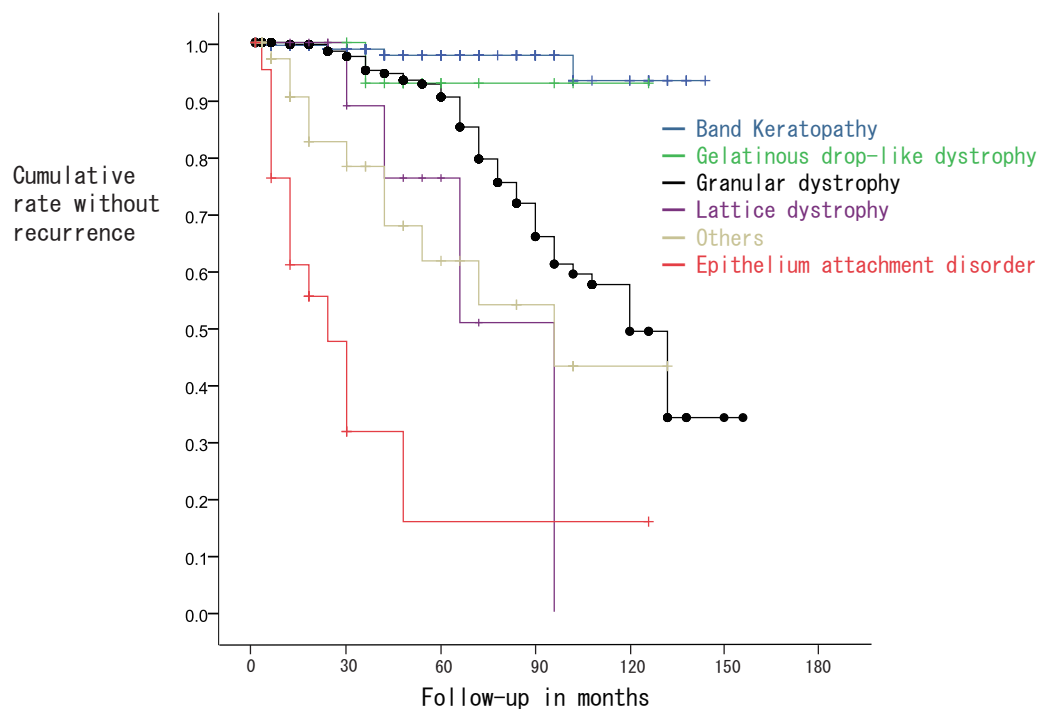


Figure 1. Line charts demonstrating the cumulative survival rate for the recurrence of granular dystrophy, band keratopathy, epithelium attachment disorder, gelatinous drop-like dystrophy (GDLD), lattice dystrophy, and other corneal diseases following phototherapeutic keratectomy (PTK), as analyzed by Kaplan–Meier survival analysis. The significant recurrence of the disease was defined by visual decrease with a 2-line or more loss of the corrected distance visual acuity (CDVA) caused by the increased corneal opacity resulting from the disease or one or more episodes of recurrent corneal erosion.

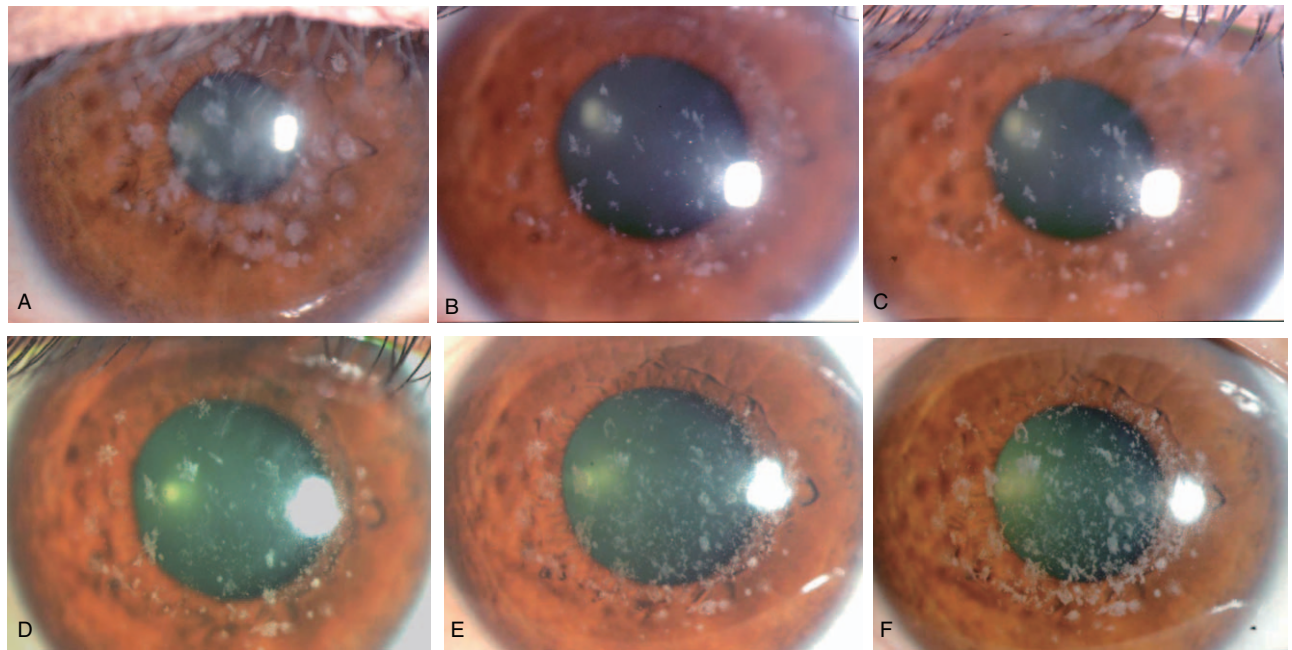


Figure 2. Slit-lamp microscopy images of the right eye of 46-year-old female with granular dystrophy. A, Before PTK. B, 6-months post PTK. C, Two and a half years post PTK. D, 5-years post PTK. E, Seven and a half years post PTK. F, Ten and a half years post PTK. Granular dystrophy recurred slowly post PTK, but the CDVA after 10 years was decimal 0.8. No significant recurrence was observed after 10 years. PTK = phototherapeutic keratectomy.

The median survival time for observing a significant recurrence for epithelium attachment disorder was 24 months (restricted mean survival time: 39.4 months, 95% CI 14.4–62.2). Epithelium attachment disorder recurred significantly faster than the 4 diseases without lattice dystrophy ($P < .0033$).

There was only 1 GDLD eye with significant recurrence during follow-up period. The restricted mean survival time for observing

a significant recurrence for GDLD was 119.6 months (95% CI 107.4–131.7). In the GDLD patients who wore an extended-period soft contact lens after PTK, slit-lamp examination rarely revealed signs of increased central opacification (Fig. 4). The median survival time for observing a significant recurrence for lattice dystrophy and other corneal diseases was 96 months (restricted mean survival time: 74.2 months, 95% CI 52.4–96.0)

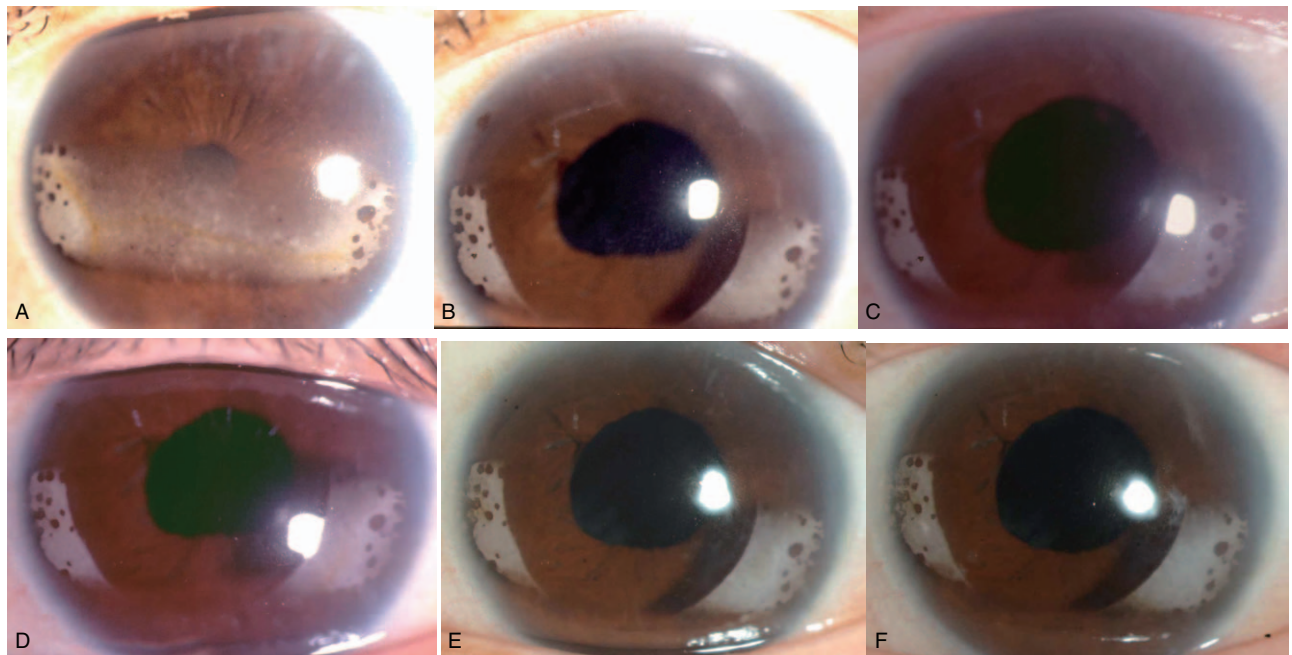


Figure 3. Slit-lamp microscopy images of the right eye of 55-year-old female with band keratopathy. A, Before PTK. B, 6-months post PTK. C, 2-years post PTK. D, 6-years post PTK. E, 9-years post PTK. F, 12-years post PTK. No recurrence of band keratopathy was observed post PTK.

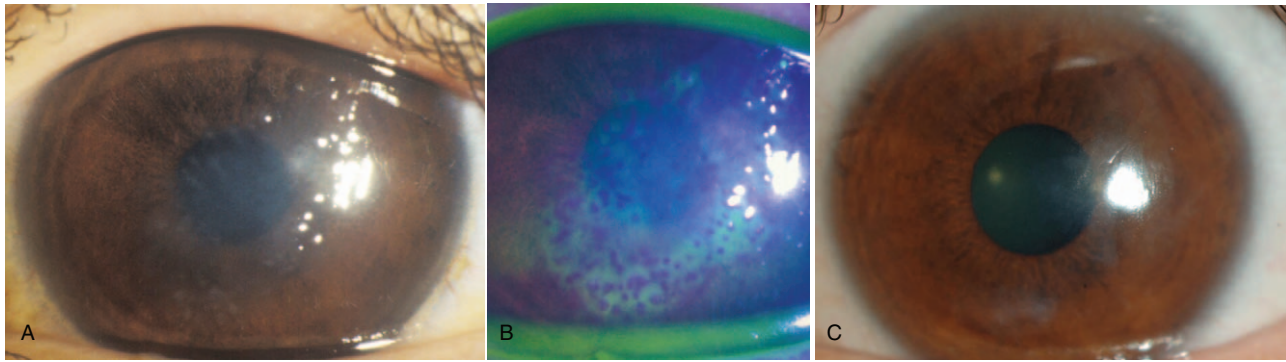


Figure 4. Slit-lamp microscopy images of the left eye of 21-year-old male with GDLD. A, Before PTK. B, Fluorescein staining before PTK. C, Two and a half years post PTK with a soft contact lens. No recurrence of GDLD was observed post PTK with a soft contact lens. GDLD = gelatinous drop-like corneal dystrophy, PTK = phototherapeutic keratectomy.

and 72 months (restricted mean survival time: 81.6 months 95% CI 62.3–100.9)

3.3. Complications

Bacterial corneal ulcers were observed for a few days after PTK in 2 of the 714 eyes (0.28%). The primary disease of those 2 eyes was BK. The infections were cured by the local and systemic antibiotics therapy. Seven (1.0%) of the 714 eyes underwent corneal keratoplasty after PTK until the final follow-up examination. The reasons for undergoing penetrating keratoplasty were the progression of underlying diseases other than the original disease [1 eye with bullous keratopathy and BK, 1 eye with herpetic keratitis and corneal opacity and 1 eye with cataract and Schnyder corneal dystrophy], or recurrence of the original disease (1 eye with Schnyder dystrophy and 1 eye with keratoconus-related amyloid deposits), and insufficient PTK treatment of the original disease (1 eye with corneal opacity). We performed lamellar keratoplasty for 1 insufficient PTK eye with GDLD

The mean refractive change within 3-months after PTK was 1.53 ± 1.68 diopters (D) (range, -3 to 8.25 D; $n=193$). Seven of 193 eyes had refractive correction simultaneously with PTK. In myopia cases with strong hyperopic change, myopic correction was performed. The strong myopic change cases were removal of amyloid deposit at the apex of keratoconus.

4. Discussion

The findings of this single-center study demonstrated that the mean CDVA improved significantly in cases of all 6 diseases after PTK, and a recurrence requiring an additional PTK differed among the diseases. The recurrence rate of BK and GDLD was low, and only a few PTK-related severe complications were found.

Improvement in visual acuity surpassed the reported one, and average months to recurrence were longer. As for the procedure used in a previous study, we defined the significant recurrence by slit-lamp findings and at least a 2 lines loss of CDVA. In this study, the mean age of the patients undergoing PTK surgery exceeded 60 years, and the frequency of cases in which a cataract progressed postoperatively was high. When cataract surgery was performed within a few months after PTK, visual acuity after cataract operation was regarded as the highest CDVA. If cataract progressed in several years after PTK, cataract surgery was

performed, and if it remained two or more lines lower than the highest CDVA after PTK, it was defined as recurrence. Possibly as an effect of the cataract surgery, the significant recurrence of corneal dystrophy was slower than in a previous report.^[18,21]

The granular dystrophy patients in this study were mostly treated by PTK at our clinic. The recurrence slowly occurred, and after about 10 years (120 months) vision decreases significantly. We are not using mitomycin-C (MMC) in the PTK routine. The frequency of corneal opacity that causes visual function deterioration after PTK is low, due to continuing low-concentration steroid instillation for at least 3 months. We use MMC only in cases with high risk of postoperative haze and early recurrence. For example, homozygous granular dystrophy. Since this time, we observed only a case of initial corneal operation, there was no case using MMC.

Since most of the patients with BK were elderly who had a coexisting ocular disease, the damage to the retina and optic nerve in their eyes was more frequent.^[22] A 2 or more lines increase of CDVA rate (49.2%) after PTK for BK was satisfactory, although frequency of recurrence BK was low.

Epithelium attachment disorder eyes often have an underlying corneal disease, for example, bullous keratopathy, atopic keratoconjunctivitis, or severe dry eye. Since PTK did not heal the underlying disease, the epithelial problem was temporary relieve.

GDLD has been reported as an uncommon, autosomal recessive disease,^[23,24] characterized by bilateral corneal amyloidosis. The epithelial barrier function may be compromised in the corneas, thereby allowing the formation of amyloid depositions through permeation of the ingredients of tears. Soft contact lens offered a protection against post PTK recurrence, and according to the previous report^[25] recurrence was found to be rare.

Patients with lattice dystrophy respond in a manner similar to those with granular dystrophy. Other corneal diseases involved corneal dystrophy and secondary anterior corneal change. Thus, the recurrence of those other corneal diseases might be mid-way between granular dystrophy, and epithelium attachment disorder.

It should be noted that this study presents retrospective findings from 1 facility. So, it may be difficult to say whether or not these results are common in terms of disease type and age distribution. In Japan, granular dystrophy and BK have become the 2 major indications for PTK.^[22] In this study, these 2 diseases involved a higher number of cases and a longer follow-up period

than it has been reported in previous studies.^[18,22] Thus our findings could be more profounding.

This time, we covered all cases of at least 1 month of follow-up. PTK haze develops in 1 to 3 months after surgery; recurrence of corneal disorder is early and becomes apparent every half year. It is difficult to distinguish haze and recurrence at the time of 1 month postop examination. We will consider long term cases as a subject for future research. Since most corneal dystrophies can be diagnosed genetically,^[26,27] few patients in this study underwent genetic screening. In the previous study, we reported cases of genetically diagnosed Thiel–Behnke dystrophy.^[28] In the future, we hope to perform a case-control study using genetic screening between early recurrence cases and late recurrence cases of the same category of corneal dystrophy in order to better understand the precise clinical course of corneal dystrophy post PTK surgery.

Therefore, to sum up, the findings of present study show that PTK is a successful therapy for granular dystrophy, BK, epithelium attachment disorder, GDL, lattice dystrophy, and other corneal diseases. Moreover, the recurrence of BK and GDL was rare. Granular dystrophy did slowly recur, with the elapsed time to the significant recurrence being approximately 10 years on median. Thus, it is important for surgeons to recognize different recurrence rates among the various disease categories after PTK surgery.

Acknowledgments

The authors wish to thank Mr. John Bush for editing the manuscript.

Author contributions

Conceptualization: Osamu Hieda, Satoshi Kawasaki, Shigeru Kinoshita.

Data curation: Osamu Hieda, Kiyoshi Yamamura, Mina Nakatsukasa.

Investigation: Kiyoshi Yamamura, Mina Nakatsukasa.

Project administration: Shigeru Kinoshita.

Supervision: Shigeru Kinoshita, Chie Sotozono.

Validation: Chie Sotozono.

Writing – original draft: Osamu Hieda.

Writing – review & editing: Osamu Hieda, Satoshi Kawasaki.

References

- Sher NA, Bowers RA, Zabel RW, et al. Clinical use of the 193-nm excimer laser in the treatment of corneal scars. *Arch Ophthalmol* 1991;109:491–8.
- Stark WJ, Chamon W, Kamp MT, et al. Clinical follow-up of 193-nm ArF excimer laser photokeratectomy. *Ophthalmology* 1992;99:805–12.
- Campos M, Nielsen S, Szerenyi K, et al. Clinical follow-up of phototherapeutic keratectomy for treatment of corneal opacities. *Am J Ophthalmol* 1993;115:433–40.
- Hersh PS, Burnstein Y, Carr J, et al. Excimer laser phototherapeutic keratectomy. Surgical strategies and clinical outcomes. *Ophthalmology* 1996;103:1210–22.
- Maloney RK, Thompson V, Ghiselli G, et al. A prospective multicenter trial of excimer laser phototherapeutic keratectomy for corneal vision loss. The Summit Phototherapeutic Keratectomy Study Group. *Am J Ophthalmol* 1996;122:149–60.
- Rapuano CJ. Excimer laser phototherapeutic keratectomy in eyes with anterior corneal dystrophies: preoperative and postoperative ultrasound biomicroscopic examination and short-term clinical outcomes with and without an antihyperopia treatment. *Trans Am Ophthalmol Soc* 2003;101:371–99.
- Ookita TTS, Yokoi N, Noshida K, et al. Recurrence of granular corneal dystrophy after phototherapeutic keratectomy. *Folia Ophthalmologica Jpn* 1999;50:645–50.
- Chen M, Xie L. Features of recurrence after excimer laser phototherapeutic keratectomy for anterior corneal pathologies in north china. *Ophthalmology* 2013;120:1179–85.
- Koksal M, Kargi S, Gurelik G, et al. Phototherapeutic keratectomy in Schnyder crystalline corneal dystrophy. *Cornea* 2004;23:311–3.
- O'Brart DP, Gartry DS, Lohmann CP, et al. Treatment of band keratopathy by excimer laser phototherapeutic keratectomy: surgical techniques and long term follow up. *Br J Ophthalmol* 1993;77:702–8.
- Cavanaugh TB, Lind DM, Cutarelli PE, et al. Phototherapeutic keratectomy for recurrent erosion syndrome in anterior basement membrane dystrophy. *Ophthalmology* 1999;106:971–6.
- Jain S, Austin DJ. Phototherapeutic keratectomy for treatment of recurrent corneal erosion. *J Cataract Refract Surg* 1999;25:1610–4.
- Nassaralla BR, Nassaralla Junior JJ. Ten-year results of phototherapeutic keratectomy on recurrent corneal erosions. *Arq Bras Oftalmol* 2012;75:33–7.
- Thomann U, Meier-Gibbons F, Schipper I. Phototherapeutic keratectomy for bullous keratopathy. *Br J Ophthalmol* 1995;79:335–8.
- Fagerholm P. Phototherapeutic keratectomy: 12 years of experience. *Acta Ophthalmol Scand* 2003;81:19–32.
- Das S, Langenbacher A, Pogorelov P, et al. Long-term outcome of excimer laser phototherapeutic keratectomy for treatment of Salzmann's nodular degeneration. *J Cataract Refract Surg* 2005;31:1386–91.
- Fujita A, Hieda O, Nakajima N, et al. The VF-14 index of functional visual impairment in patients with corneal disease treated by phototherapeutic keratectomy. *Nihon Ganka Gakkai Zasshi* 2005;109:736–40.
- Dinh R, Rapuano CJ, Cohen EJ, et al. Recurrence of corneal dystrophy after excimer laser phototherapeutic keratectomy. *Ophthalmology* 1999;106:1490–7.
- Inoue T, Watanabe H, Yamamoto S, et al. Recurrence of corneal dystrophy resulting from an R124H Big-h3 mutation after phototherapeutic keratectomy. *Cornea* 2002;21:570–3.
- Konishi M, Mashima Y, Yamada M, et al. The classic form of granular corneal dystrophy associated with R555W mutation in the BIGH3 gene is rare in Japanese patients. *Am J Ophthalmol* 1998;126:450–2.
- Ellies P, Bejjani RA, Bourges JL, et al. Phototherapeutic keratectomy for BIGH3-linked corneal dystrophy recurring after penetrating keratoplasty. *Ophthalmology* 2003;110:1119–25.
- Amano S, Oshika T, Tazawa Y, et al. Long-term follow-up of excimer laser phototherapeutic keratectomy. *Jpn J Ophthalmol* 1999;43:513–6.
- Tsujikawa M, Kurahashi H, Tanaka T, et al. Identification of the gene responsible for gelatinous drop-like corneal dystrophy. *Nat Genet* 1999;21:420–3.
- Weiss JS, Moller HU, Lisch W, et al. The IC3D classification of the corneal dystrophies. *Cornea* 2008;27(Suppl 2):S1–83.
- Oura YNK, Hori Y, Mseda N, et al. Phototherapeutic keratectomy and use of extended-wear therapeutic soft contact lenses for the treatment of gelatinous drop-like corneal dystrophy. *Folia Ophthalmologica Jpn* 2007;58:384–8.
- Munier FL, Korvatska E, Djemai A, et al. Kerato-epithelin mutations in four 5q31-linked corneal dystrophies. *Nat Genet* 1997;15:247–51.
- Ellies P, Renard G, Valleix S, et al. Clinical outcome of eight BIGH3-linked corneal dystrophies. *Ophthalmology* 2002;109:793–7.
- Hieda O, Kawasaki S, Wakimasu K, et al. Clinical outcomes of phototherapeutic keratectomy in eyes with thiel-behnke corneal dystrophy. *Am J Ophthalmol* 2013;155:66–72. e1.