

Delayed activation of leg somatotopic fibers of an injured corticospinal tract in a patient with cerebral infarction

Min Jye Cho, Sung Ho Jang*

Stroke is a leading cause of major adult disabilities, and motor weakness is one of the most serious disability-related sequelae of stroke. Most of the motor recovery in stroke patients is reported to occur within 6 months after stroke onset, and this period is deemed critical for motor recovery in stroke (Grefkes and Fink, 2020; Olafson et al., 2021). Therefore, active rehabilitation within 6 months after stroke onset is strongly recommended for hemiparetic stroke patients (Grefkes and Fink, 2020; Olafson et al., 2021). Research on delayed motor recovery after the critical period is important in stroke rehabilitation because it could provide a basis for rehabilitation strategies for chronic patients who failed to show good recovery during the critical period, even though they had a potential for good motor recovery. However, little is known about delayed motor recovery occurring more than 6 months after stroke onset (Jang et al., 2019).

In the current study, we report on a stroke patient who showed delayed leg motor recovery and activation of the leg somatotopic fibers of an injured corticospinal tract (CST) during 4 months occurring 8 months after stroke onset. Recovery and activation were demonstrated via follow-up diffusion tensor tractography (DTT) and transcranial magnetic stimulation (TMS), respectively.

A 60-year-old right-handed man presented with complete paralysis of the right upper and lower extremities (Medical Research Council [MRC] score: 0/5) at the onset of an infarct in the left middle cerebral artery region. He underwent thrombectomy for occlusion of the sphenoidal segment (M1) of the left middle cerebral artery after the onset of the infarction in the left middle cerebral artery territory at the department of neurosurgery of a university hospital. He started rehabilitation to improve the weakness on the right upper and lower extremities 2 weeks after onset at a local rehabilitation center. At 8 months after onset, he was admitted to the rehabilitation center of the above university hospital to undergo additional rehabilitation. Brain magnetic resonance images at 8 and 12 months after onset showed leukomalactic lesions in the left corona radiata, the internal capsule, and the basal ganglia (**Figure 1A**).

He showed the severe weakness of the right extremities (MRC scores: shoulder abductor; 2, finger extensors; 0, hip flexor; 3⁺, knee extensor; 4⁻ and ankle dorsiflexor; 0) (Menon et al., 2019). He underwent comprehensive rehabilitative therapy, including neurotropic drug administration (dopaminergic drugs: pramipexole, ropinirole, and amantadine), movement therapy, and neuromuscular electrical stimulation of the right finger extensors and ankle dorsiflexors (20 minutes, 5 times a day) (Hesse and Werner, 2003; Engelter et al., 2019; Tashiro et al., 2019). Movement therapy was conducted with a focus on the improvement of the function of the right extremities and trunk and was conducted five times per week in our physical and occupational therapy department during a 2-month hospitalization period and underwent further movement therapy three times per week at an outpatient clinic for 2 months after discharge. The weakness of his right ankle dorsiflexors showed good recovery from 8 months to 12 months after onset, but there was no significant motor recovery of other muscles (MRC score: ankle dorsiflexor; 0 → 2⁺). The patient provided informed consent to participate in this study. The study protocol was approved by the Institutional Review Board of Yeungnam University Hospital, Republic of Korea (YUMC 2019-06-032) on June 21, 2019.

DTT data were acquired at 8 and 12 months after stroke onset using a 6-channel head coil on a 1.5 T Philips Gyroscan Intera (Philips, Best, The Netherlands). Seventy contiguous slices (acquisition matrix = 96 × 96, reconstructed to matrix = 192 × 192 matrix, field of view (FOV) = 240 mm × 240 mm, repetition time (TR) = 10,398 ms, echo time (TE) = 72 ms, SENSE factor = 2, EPI factor = 59 and $b = 1000 \text{ s/mm}^2$, number of excitations = 1, and thickness = 0.5 mm) were acquired. A fiber assessment by continuous tracking algorithm was used for fiber tracking. Each of the DTT replications was intra-registered to the baseline (b0) images to correct for residual eddy-current image distortions and head motion effects by using diffusion registration software (Philips Medical Systems, Best, the Netherlands) with a threshold fractional anisotropy value of 0.2 and an angle of 50°. For reconstruction of the CST, the first region of interest was placed on the upper pons in an axial image,

and the second region of interest was placed at the mid pons in an axial image (Boudier-Revéret et al., 2020).

The left CST was observed to descend through the posterior portion of the infarcted area in the corona radiata on the 8-month DTT. However, the left CST was on the 12-month DTT thicker than on the 8-month DTT, and there was an increase in the number of transcallosal fibers on 12-month DTT (fiber number: 3836) compared with that on the 8-month DTT (fiber number: 369) (**Figure 1B**).

TMS was performed 8 and 12 months after onset using a Magstim Novametric 200 magnetic stimulator with a 9-cm mean diameter circular coil (Novametric Medical Systems Inc, Wallingford, CT, USA). Cortical stimulation was performed with the coil held tangentially over the vertex. The left hemisphere was stimulated by a counterclockwise current, while the right hemisphere was stimulated by a clockwise current. Motor evoked potentials (MEPs) were obtained from both tibialis anterior (TA) muscles in a relaxed state with maximum stimulator output. Each hemisphere was stimulated four times at a minimum of 10-second intervals. To avoid possible bias when averaging several MEPs, which can be quite variable, we selected the MEP with the shortest latency and the largest amplitude. We measured the parameters of latency and amplitude (from negative to positive peak) from the accepted MEP (Bell et al., 2018).

No MEP was obtained from the right TA muscle 8 months after onset. A lower amplitude MEP (latency: 34.2 ms, amplitude: 100 μV , ET: 100%) was obtained from the right TA muscle than from the left TA (latency: 34.1 ms, amplitude: 900 μV , excitatory threshold: 100%) 12 months after onset (**Figure 1C**).

In this study, by using follow-up DTT and TMS, we evaluated the motor function of the recovered ankle muscle of a patient with a middle cerebral artery infarct. Based on the following observations, we believe that the recovery of the right ankle muscle was related to the activation of the leg somatotopic fibers of the injured left CST. When he started rehabilitation at our rehabilitation center at 8 months after onset, he had complete weakness of his right ankle dorsiflexors and this weakness was recovered to resistance to gravity during the 4 months of rehabilitation at our rehabilitation center. At 8 months after onset, DTT assessment showed the integrity of the left CST along with the posterior portion of the infarcted area is preserved; in addition, the fiber number value, which represents the total fiber number of the CST, increased from 369 (8 months) to 3836 (12 months) (Jang et al., 2013). Considering the somatotopic

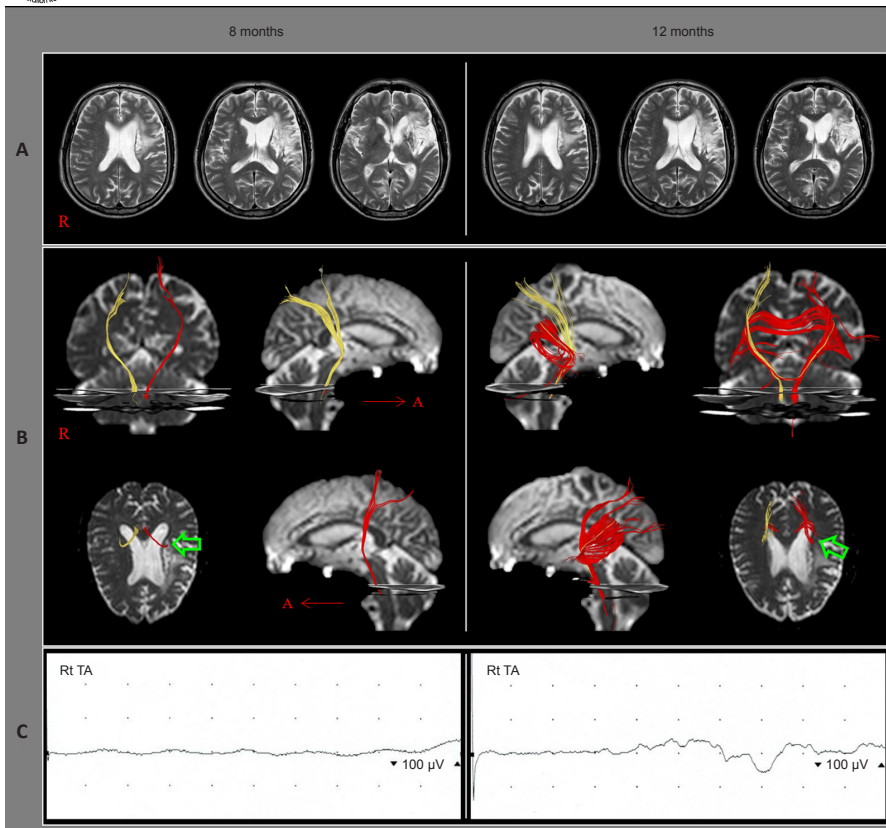


Figure 1 | MRI and DTT images and motor evoked potentials of a 60-year-old male patient with cerebral infarction. (A) T2-weighted MRI images show an encephalomalacia in the left middle cerebral artery region. (B) DTT results. The left corticospinal tract (red) is observed to descend through the posterior portion of the infarcted area in the corona radiata (green arrows) at 8 months after onset. The left corticospinal tract is observed to be thickened and the transcallosal fibers increased at 12 months after onset (fiber number: 3836) compared with that at 8 months after onset (fiber number: 369). The right corticospinal tract is indicated by a yellow color. (C) Transcranial magnetic stimulation (TMS)-induced motor evoked potentials obtained from the right tibialis anterior (TA) muscle. No motor evoked potential is obtained from the right TA muscle at 8 months after onset. A low amplitude motor evoked potential (latency: 34.2 ms, amplitude: 100 μ V) is obtained from the right TA muscle at 12 months after onset. DTT: Diffusion tensor tractography; MRI: magnetic resonance imaging.

arrangement of the CST in the corona radiata, we suggest that the leg somatotopic fibers of the left CST were preserved at 8 months after onset and became activated by the four months of rehabilitation at our rehabilitation center (Kwon et al., 2014). It appears that the results of our TMS studies of the TA muscle concurred with the DTT results. The patient had undergone similar rehabilitation at a local rehabilitation center; however, at our rehabilitation center, neurotropic drugs were used and the patient underwent more frequent neuromuscular electrical stimulation (previous local rehabilitation center, 1–2 times a day; our rehabilitation center, 5 times a day) was different therapeutic modalities.

In conclusion, our results suggest that the delayed motor recovery of the affected leg of the patient with cerebral infarction could be ascribed to the activation of the leg somatotopic fibers of the injured CST. This result indicates the importance of determining the MEP of related muscles and of evaluating the state of the CST via DTT and TMS study. However, further studies with large sample size are warranted to verify the findings.

Min Jye Cho, Sung Ho Jang*

Department of Physical Medicine and Rehabilitation, College of Medicine, Yeungnam University, Namku, Daegu, Republic of Korea
*Correspondence to: Sung Ho Jang, MD, strokerekab@hanmail.net.

<https://orcid.org/0000-0001-6383-5505> (Sung Ho Jang)

Date of submission: December 10, 2020

Date of decision: May 10, 2021

Date of acceptance: August 20, 2021

Date of web publication: April 1, 2022

<https://doi.org/10.4103/1673-5374.339013>

Funding: This work was supported by the Medical Research Center Program (2015R1A5A2009124, to SHJ) through the National Research Foundation of Korea (NRF) funded by the Ministry of Science, ICT, and Future Planning.

How to cite this article: Cho MJ, Jang SH (2022) Delayed activation of leg somatotopic fibers of an injured corticospinal tract in a patient with cerebral infarction. *Neural Regen Res* 17(11): 2551-2552.

Author contributions: Study concept, design, and critical revision of the manuscript for intellectual content: MJC. Study concept and design, manuscript development, writing, funding, and critical revision of the manuscript for intellectual content: SHJ. Both authors approved the final

version of this paper.

Conflicts of interest: The authors declare no conflict of interest.

Open access statement: This is an open access journal, and articles are distributed under the terms of the Creative Commons AttributionNonCommercial-ShareAlike 4.0 License, which allows others to remix, tweak, and build upon the work non-commercially, as long as appropriate credit is given and the new creations are licensed under the identical terms.

References

- Bell SJ, Lauer A, Lench DH, Hanlon CA (2018) Visual attention affects the amplitude of the transcranial magnetic stimulation-associated motor-evoked potential: a preliminary study with clinical utility. *J Psychiatr Pract* 24:220-229.
- Boudier-Revéret M, Hsiao MY, Shyu SG, Chang MC (2020) Injury of corticospinal tract and corticoreticular pathway caused by high-voltage electrical shock: a case report. *BMC Neurol* 20:130.
- Engelter S, Hemkens LG, Speich B, Traenka C (2019) Dopaminergic agents versus control for enhancing stroke recovery and rehabilitation. *Cochrane Database Syst Rev* 2019:CD013416.
- Grefkes C, Fink GR (2020) Recovery from stroke: current concepts and future perspectives. *Neural Res Pract* 2:17.
- Hesse S, Werner C (2003) Poststroke motor dysfunction and spasticity: novel pharmacological and physical treatment strategies. *CNS Drugs* 17:1093-1107.
- Jang SH, Chang CH, Lee J, Kim CS, Seo JP, Yeo SS (2013) Functional role of the corticoreticular pathway in chronic stroke patients. *Stroke* 44:1099-1104.
- Jang SH, Chang CH, Jung YJ, Seo YS (2019) Recovery of an injured corticospinal tract via an unusual pathway in a stroke patient: case report. *Medicine (Baltimore)* 98:e14307.
- Kwon HG, Yang JH, Park JB, Kim MH, Choi SH, Yang DS (2014) Anatomical location and somatotopic organization of the corticospinal tract in the corona radiata of the normal human brain: a diffusion tensor tractography study. *Neuroreport* 25:710-714.
- Menon P, Yiannikas C, Kiernan MC, Vucic S (2019) Regional motor cortex dysfunction in amyotrophic lateral sclerosis. *Ann Clin Transl Neurol* 6:1372-1382.
- Olafson ER, Jamison KW, Sweeney EM, Liu H, Wang D, Bruss JE, Boes AD, Kuceyeski A (2021) Functional connectome reorganization relates to post-stroke motor recovery and structural and functional disconnection. *Neuroimage* 245:118642.
- Tashiro S, Mizuno K, Kawakami M, Takahashi O, Nakamura T, Suda M, Haruyama K, Otaka Y, Tsuji T, Liu M (2019) Neuromuscular electrical stimulation-enhanced rehabilitation is associated with not only motor but also somatosensory cortical plasticity in chronic stroke patients: an interventional study. *Ther Adv Chronic Dis* 10:2040622319889259.

C-Editor: Zhao M; L-Editors: Li CH, Song LP; T-Editor: Jia Y