

Vascular Type of Ehlers-Danlos Syndrome: A Case Report of an Aortic Dissection During Pregnancy

Authors' Contribution:
Study Design A
Data Collection B
Statistical Analysis C
Data Interpretation D
Manuscript Preparation E
Literature Search F
Funds Collection G

ABCDEF **Georgios Papadopoulos**
DF **Oliver Maier**
CDF **Florian Bönner**
ABCDEF **Verena Veulemans**

Clinic for Cardiology, Pneumology and Angiology, University Hospital of Düsseldorf, Düsseldorf, Germany

Corresponding Author: Georgios Papadopoulos, e-mail: georgios.papadopoulos@med.uni-duesseldorf.de, geo11987@yahoo.gr
Conflict of interest: None declared

Patient: Female, 30
Final Diagnosis: Aortic dissection
Symptoms: Tearing back pain
Medication: —
Clinical Procedure: Conservative treatment
Specialty: Cardiac Surgery

Objective: Rare disease

Background: Vascular type of Ehlers-Danlos syndrome (vEDS) is a rare connective tissue disorder associated with a high prevalence rate of aortic dissection (AD). The coexistence of a pregnancy raises these rates and the diagnostic complexity of the situation. In this article, we present a different initial diagnostic approach to an acute aortic syndrome.





Case Report: A young pregnant woman (29th week gestation) with vEDS was admitted to our clinic due to sudden tearing back pain radiating to the left arm. Four years ago, the same patient underwent a surgical aortic valve reconstruction and replace of the ascending and proximal arch of the aorta because of an acute Stanford A AD. The clinical, laboratory as well as transthoracic echocardiographic findings did not reveal any objective signs of an acute aortic syndrome. Due to the relative contraindications against computed tomography imaging due to pregnancy, we conducted a transesophageal echocardiography which revealed acute progress of pre-existing AD. A follow-up computed tomography could verify our findings, showing a Stanford B dissection, which was treated conservatively. After 2 weeks, due to a distal progression of dissection, our patient underwent a cesarean section. In absence of new clinical findings, the young patient was discharged the following week.

Conclusions: Patients with vEDS are at high risk of an AD and other life-threatening complications, especially during pregnancy. According to the guidelines of European Society of Cardiology (ESC), vEDS-patients should be thoroughly screened. In the case of pregnancy, physicians should consider frequent follow-up examinations and be prepared for diagnosis and treatment of the potential complications.

MeSH Keywords: Aortic Rupture • Ehlers-Danlos Syndrome • Pregnancy

Abbreviations: vEDS – vascular form of Ehlers-Danlos syndrome; AD – aortic dissection; ESC – European Society of Cardiology; CT – computed tomography; CMR – cardiovascular magnetic resonance

Full-text PDF: <https://www.amjcaserep.com/abstract/index/idArt/911688>

 1397  2  2  8



Background

Ehlers-Danlos Syndrome is a rare connective tissue disorder with 6 different known types. The vascular form (vEDS), formerly known as type IV, affects about 1: 200 000 individuals. For vEDS, 50% are caused by *de novo* mutation in a collagen protein (COL3A1) and the other 50% of patients inherit the defective gene in an autosomal dominant way [1]. Pregnancy for women with vEDS has an estimated 5.3% mortality risk due to peripartum arterial rupture or uterine rupture. In addition, one-fourth of individuals with vEDS, confirmed by laboratory testing, experienced a major complication by age 20 years and more than 80% by age 40 years. The median age of death is 48 years in a reviewed population [1]

Pregnancy is a perilous period for vEDS patients and severe adverse events should be expected by attending clinicians. The diagnosis of these complications needs to be quick and not delay the therapeutic process. This article presents a rare case of a pregnant woman with vEDS and recurrence of an aortic dissection (AD), illuminating an alternative diagnostic course of aortic syndrome and providing clinicians with more knowledge regarding similar incidents.

Case Report

Patient information

A 30-year-old pregnant woman was admitted to the emergency department of our clinic on a Sunday morning, due to an abrupt onset of tearing back pain radiating to the left arm.

The patient was in the 29th week of gestation (G 1 P0), had a jelly-like placenta, and was being treated with surfactant induction therapy. A vascular form of Ehlers-Danlos syndrome (vEDS) had been identified in her adolescence. Four years ago, an intimal tear located at 2 cm proximal to the aortic arch led to AD, type Stanford A. A modified Yacoub aortic valve reconstruction with replacement of the ascending and proximal arch of the aorta with Dacron-graft was performed.

Existing arterial hypertension since 2012 was under treatment with beta-blocker; hypothyroidism and contrast agent-allergy were also disclosed in her medical history.

The reported pain had a sudden onset during sleep and first emerged during pregnancy. It had a tearing quality and was independent from any movement but slightly more intense with deep inspiration. After administration of piritramid, the patient was free of pain. Due to the described vEDS, the patient was under frequent observation, with the last examination taking place in our gynecology department 2 weeks before admission.

Apart from the jelly-like placenta, there were no pregnancy complications. Nine months ago, in the annual follow-up, an echocardiography and a cardiovascular magnetic resonance (CMR) imaging showed no signs of a new aortic pathology.

Physical examination

A physical examination revealed a respiratory and hemodynamic stable young patient with normal vital signs and symmetric brachial blood pressure. The thoracic auscultation showed symmetric vesicular sounds as well as rhythmic and clear heart sounds without signs for heart or valve failure. There was no abdominal tenderness or rigidity and no pathological neurological signs during the examination.

Diagnostic assessment

The electrocardiogram showed a sinus rhythm with normal frequency and without disturbance of the depolarization. The transthoracic echocardiography showed a normal global heart function with a first degree of aortic and mitral regurgitation and absence of pericardial effusion. The blood tests revealed no pathological findings with normal levels of troponin T and unspecific raised level of D-dimers for pregnancy. The patient was examined by an interdisciplinary team including cardiologists, vascular surgeons, gynecologists, and radiologists. According to her risk profile and patient history, there was an implication of a recurrent AD. However, the diagnostic process had not revealed any objective findings.

Considering the risk of computed tomography (CT) and associated exposure of the fetus at radiation and contrast agent, or alternatively a contrast enhanced CMR examination, the probability of AD and the optimal diagnostic strategy were discussed.

Looking for alternative and readily available diagnostic methods with consideration of our efforts to investigate our clinical suspicion, we concluded that a transesophageal echocardiography would be a helpful tool. Therefore, we admitted the young patient to our intensive care unit and conducted the transesophageal echocardiography, which showed a movable dissection membrane in the descending aorta with double barrel sign and periaortic edema (Figure 1). After our first imaging findings with clear suggestion of a new AD in descending aorta, the indication for a contrast enhanced CT was provided. CT angiography (Figure 2) verified our prior findings and revealed a Stanford B AD as a progress of the previous aortic disease with entry point proximal to the stent graft, reaching to the abdominal aorta (7th thoracic vertebra). The patient was monitored under bed confinement and for blood pressure control.

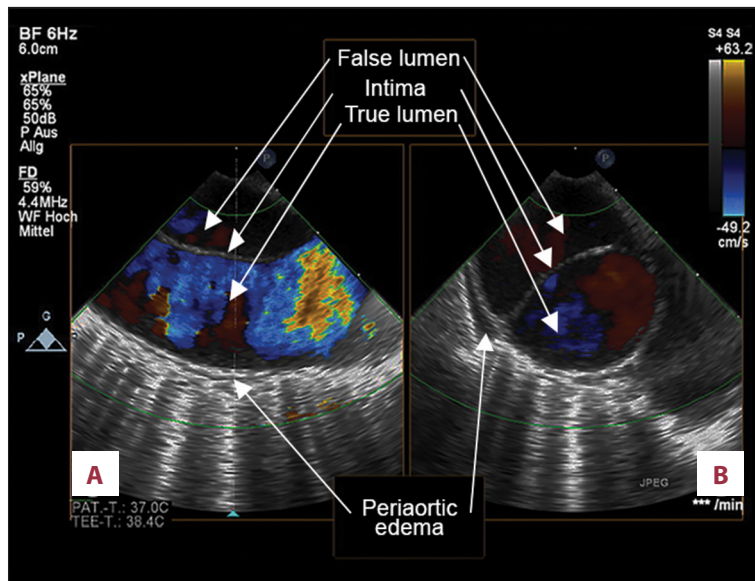


Figure 1. Transesophageal echocardiography: signs of aortic dissection in the proximal segment of the descending aorta in sagittal (A) and transversal view (B).

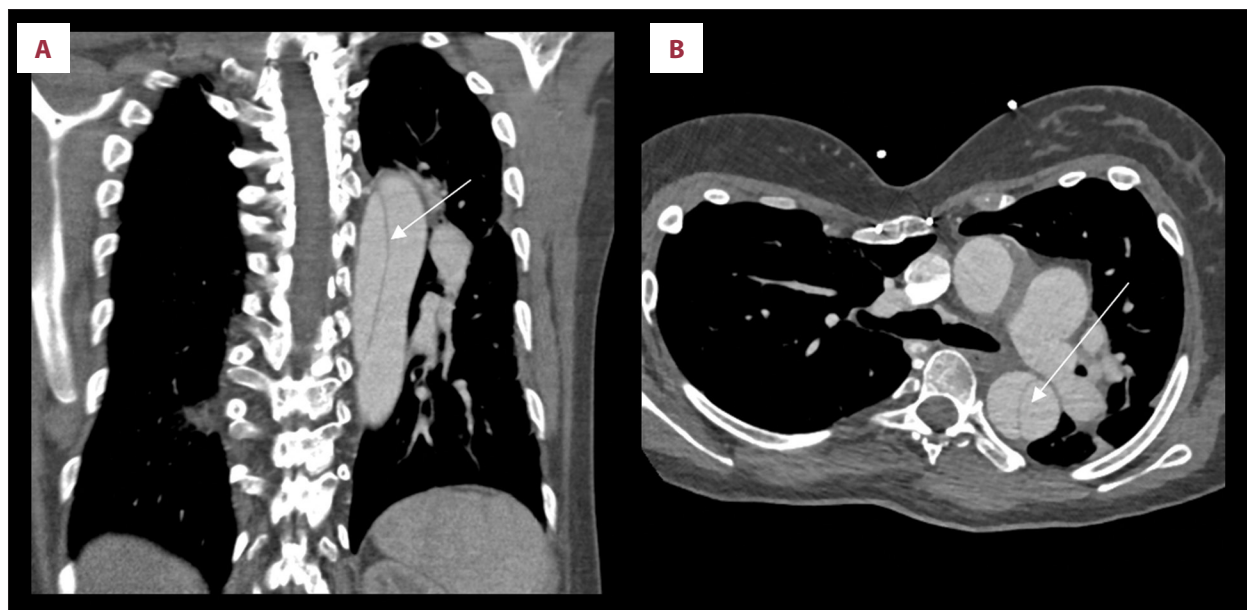


Figure 2. Computed tomography angiography: signs of the dissection membrane (arrow) of the descending aorta in frontal (A) and transversal view (B). True and false lumens are equally contrasted.

Treatment

The treatment the AD was not invasive but pharmaceutical. Piritramid was administrated to alleviate the acute pain of dissection. Before conduction of CT angiography, the patient was premedicated with methylprednisolone as a prophylaxis against her contrast agent allergy. The regulation of her blood pressure was achieved initially with alpha-methyldopa and beta blockers, and later with ACE-inhibitors.

Follow-up and outcomes

Two weeks later, due to recurrent back pain, a magnetic resonance imaging was conducted and revealed a distal progression of the dissection until the aortic bifurcation, without clinical deterioration of the patient. The gynecologists signaled the indication for a primary cesarean section and the patient gave birth to her first healthy child through an uncomplicated delivery. Four days later, a control CT angiography showed a new distal progression of the dissection, this time reaching the iliac arteries, though in absence of visceral ischemia signs. Using stable clinical progress over the next 2 weeks, an operative

Table 1. Timeline.

Timeline	
Day 1	<ul style="list-style-type: none"> • Patient's admission with acute onset of tearing back pain • Physical examination, electrocardiogram, and transthoracic echocardiography with no objective findings pertaining to AD • Signs of AD in transesophageal echocardiography • Proof of AD Stanford B in computed angiography • Decision for a conservative therapy (monitoring and blood pressure regulation)
Day 8	<ul style="list-style-type: none"> • Recurrent back pain • Distal progress of the AD reaching the aortic bifurcation in magnetic resonance imaging • Decision for a primary section from gynecologists • Uncomplicated cesarean delivery
Day 12	<ul style="list-style-type: none"> • Control computed tomography angiography with further distal progress of AD involving the iliac arteries • Decision against a surgery due to absence of signs of visceral ischemia
Day 27	<ul style="list-style-type: none"> • Discharge of the patient after a 2-week period of clinical stability and regulation of the blood pressure

AD – aortic dissection.

treatment was avoided, and the patient was discharged. The case timeline is shown in Table 1.

Discussion

In general, vEDS is associated with a high rate of complications. Zilocchi et al. describe a prevalence of 78% in arterial abnormalities in their radiologic findings [2] including ectasias (14.5%), aneurysms (50.6%), dissections (22.9%), and occlusions (12%). The localization of these findings has a visceral (31.3%), iliac (26.5%), cervicocerebral (19.3%), aortic (10.8%), and femoropopliteal (9.6%) distribution.

According to Pepin et al. [1] two-thirds of the arterial ruptures are sited in thoracic and abdominal region. Gastrointestinal perforations happen in 15% of these patients and spontaneous or recurrent pneumothoraces may be the first manifestation of vEDS.

Pregnancy can be fatal in 1 out of 20 women, with arterial dissection or rupture being described with a prevalence of 9.2% [3]. One study reported the uterine rupture was present at 2.6% of the cases and other life-threatening surgical complications appeared also in 2.6% of cases [3].

A large-scale survey [4], which included women with all forms of EDS who reported at least 1 pregnancy, showed spontaneous abortion in 57.2% of cases and a preterm birth in 25.2% of the cases.

Table 2. Clinical data useful to assess the a priori probability of acute aortic syndrome according to ECS guidelines².

High-risk conditions	High-risk pain features	High-risk examination features
Marfan syndrome (or other connective tissue diseases)	Chest, back, or abdominal pain described as any of the following: <ul style="list-style-type: none"> – abrupt onset – severe intensity – ripping or tearing 	Evidence of perfusion deficit: <ul style="list-style-type: none"> – pulse deficit – systolic blood pressure difference – focal neurological deficit (in conjunction with pain)
Family history of aortic disease		Aortic diastolic murmur (new and with pain)
Known aortic valve disease		Hypotension or shock
Known thoracic aortic aneurysm		
Previous aortic manipulation (including cardiac surgery)		

Presence of at least one risk factor of each category gives one point at the risk score classification (1–3): 0–1 – low probability; 2–3 – high probability.

For these reasons, raising awareness about the fatal risks of pregnancy in patients with vEDS should be considered. According to ECS guidelines [5], vEDS is a contraindication for pregnancy because of the risk of uterine rupture. In cases of pregnancy, patients with pathologic aortic findings should be monitored by echocardiography at 4- to 12-week intervals during pregnancy and 6-months post-partum [6].

AD is a well described medical emergency with high mortality, requiring urgent diagnosis and therapy [6]. According to the algorithm of the ESC-guidelines on the diagnosis and treatment of aortic diseases [7], stable patients with coexisting high-risk conditions and pain features (Table 2) who have an inconclusive transthoracic echocardiography, should undergo a CT examination as the first option or alternatively a transesophageal echocardiography.

The deterministic effects of the fetal exposure to radiation are considered negligible below 50 mGy, especially during the third gestational trimester. The maximal dose absorbed by the fetus during a thoracic CT is lower than 1 mGy. Regarding the risk of malignancy after radiation exposure *in utero* the literature

is still inconclusive [8]. However, the current ESC guidelines mention that in pregnancy and in absence of an emergency case, a minimal radiation exposure should be considered in the selection of imaging modality (class I, level C). A non-contrast enhanced CMR holds a class I recommendation in pregnancy for diagnostic assessment of aortic disease. However, paramagnetic contrast agents should be avoided [5].

Conclusions

In summary, pregnancy for vEDS patients is associated with many fatal complications, with AD being one of the most frequent and hazardous complications. ESC guidelines suggest that women with vEDS avoid pregnancy; ESC guidelines provide the medical community with a diagnostic schema for a prompt and secure diagnosis of an aortic syndrome.

Conflict of interests

None.

References:

1. Pepin MG, Murray ML, Byers PH: Vascular Ehlers-Danlos syndrome. 1999 Sep 2 In: Adam MP, Ardinger HH, Pagon RA et al. (eds.), GeneReviews [Internet]. Seattle (WA): University of Washington, Seattle; 1993–2017. <https://www.ncbi.nlm.nih.gov/books/NBK1494/>
2. Zilocchi M, Macedo TA, Oderich GS et al: Vascular Ehlers-Danlos syndrome: Imaging findings. *Am J Roentgenol*, 2007; 189(3): 712–19
3. Murray ML, Pepin M, Peterson S, Byers PH: Pregnancy-related deaths and complications in women with vascular Ehlers-Danlos syndrome. *Genet Med*, 2014; 16(12): 874–80
4. Hurst BS, Lange SS, Kullstam SM et al: Obstetric and gynecologic challenges in women with Ehlers-Danlos syndrome. *Obstet Gynecol*, 2014; 123(3): 506–13
5. Regitz-Zagrosek V, Blomstrom LC, Borghi C et al: ESC Guidelines on the management of cardiovascular diseases during pregnancy: The Task Force on the Management of Cardiovascular Diseases during Pregnancy of the European Society of Cardiology (ESC). *Eur Heart J*, 2011; 32(24): 3147–97
6. Mukherjee D, Eagle KA: Aortic dissection – an update. *Curr Probl Cardiol*, 2005; 30(6): 287–325
7. Erbel R, Aboyans V, Boileau C et al: 2014 ESC guidelines on the diagnosis and treatment of aortic diseases: Document covering acute and chronic aortic diseases of the thoracic and abdominal aorta of the adult. The Task Force for the Diagnosis and Treatment of Aortic Diseases of the European Society of Cardiology (ESC). *Eur Heart J*, 2014; 135(41): 2873–926
8. Needleman S, Powell M: Radiation hazards in pregnancy and methods of prevention. *Best Pract Res Clin Obstet Gynaecol*, 2016; 33: 108–16