

Suncon medical adhesive is a suitable alternative to fibrin glue in the 23G minimally invasive vitrectomy

SHA LIU, SUYAN LI, ZHENGPEI ZHANG, SUJUAN JI and HAIYANG LIU

Department of Ophthalmology, The Municipal Affiliated Hospital of Xuzhou Medical College,
Eye Institute of Xuzhou, Xuzhou, Jiangsu 221002, P.R. China

Received February 8, 2016; Accepted February 24, 2017

DOI: 10.3892/etm.2017.4520

Abstract. Fibrin glue is frequently used to close the incision of the sclera and conjunctiva. However, its use is limited due to its blood-borne origins. The study evaluated the suitability of Suncon medical adhesive as a replacement for fibrin glue in 23G minimally invasive vitrectomy as an animal study. One eye of Japanese white rabbits (total, 18 rabbits) received an intravitreal injection of 0.05 ml of Suncon medical adhesive, while the other eye was injected with 0.05 ml of saline and served as the control eye. Slit lamp, indirect ophthalmoscope and electroretinogram (ERG) examinations were carried out before and 28 days after the interventions. At the end of the observation period (28 days), ophthalmectomy was performed for the light microscopy examination. ERG measurements included the b-wave amplitude of rod cell response (Rod-R), maximum mixing response (Max-R) and cone cell response (Cone-R), P₂-wave amplitude of oscillatory potentials (Ops) and mean amplitude of 30 Hz scintillation response. The slit lamp examination showed no abnormal inflammatory reactions in the control or treatment eyes. The difference in ERG measurements was not statistically significant between the control or treatment eyes. Furthermore, the cells in each layer of retinas exposed to Suncon medical adhesive or saline were morphologically normal under light microscopy. In conclusion, Suncon medical adhesive injected at doses of 0.05 ml is well-tolerated by the retina. Therefore, the Suncon medical adhesive is a suitable alternative to fibrin glue.

Introduction

Scleral tunnel incision is used in the 23G minimally invasive vitrectomy and has the advantage of scar closure. However, surgery may be complicated by low intraocular pressure (IOP),

which is caused by intraoperative leakage in scleral incision. Sutureless surgery avoids irritation of ocular tissues and is, therefore, the most popular method to prevent IOP. To close the incision of the sclera and conjunctiva, fibrin glue was used, first in a 20G vitrectomy (1), and subsequently in 23G and 25G vitrectomies (2). No incision leakage, adverse effects, or low IOP were observed during the postoperative follow-up. However, the clinical use of fibrin glue is limited in China due to its blood-borne origins (2).

In the present study, we tested Suncon medical adhesive as a replacement for fibrin glue. Medical adhesive is a new approach for closing surgical incisions. It reduces operation times, requires no postoperative suture removal, and attenuates postoperative foreign body sensation. The Suncon medical adhesive is one of the homologues of α -cyanoacrylate and can be used with some modifications as a rapid medical adhesive. It prevents scar tissue formation, promotes tissue healing, has hemostatic and bactericidal effects, and relieves pain. Adhesion time is 6-14 sec, and protective film forms during 5-7 days elapsing from adhesion to spontaneous detachment. The Suncon medical adhesive has other advantages as well: i) Sufficient time to perform the operation before coagulation, ii) sufficient adhesive force for closing the incision after coagulation, iii) mild post-operative inflammatory reactions, iv) free circulation of fluids which prevents tissue necrosis, v) stable physical and chemical properties, and vi) disappearance of adhered incision site.

The Suncon medical adhesive is effective in eyelid laceration (3) and in patients with corneal perforation of <3 mm (4), and has been usable for transparent corneal notch (5). However, the usefulness of Suncon medical adhesive for 23G minimally invasive vitrectomy (e.g., potentially leaking scleral incision or retinal toxicity) has yet to receive proper attention.

To test its suitability for 23G minimally invasive vitrectomy and exclude potential toxicity to retina, we utilized the Suncon medical adhesive in an animal model of this intervention. The results showed that Suncon medical adhesive is well-tolerated by retina when used at volumes of 0.05 ml and can thus be a suitable alternative to fibrin glue.

Correspondence to: Dr Suyan Li, Department of Ophthalmology, The Municipal Affiliated Hospital of Xuzhou Medical College, Eye Institute of Xuzhou, 19 Zhongshan North Road, Xuzhou, Jiangsu 221002, P.R. China
E-mail: lishuyang1106@163.com

Key words: Suncon medical adhesive, retina, function, animal model

Materials and methods

Laboratory animals and reagents. We used 18 healthy male and female Japanese white rabbits that did not have

Table I. ERG results.

Variables	Rod-R (μ V)	Max-R (μ V)	Cone-R (μ V)	Ops (μ V)	30 Hz (μ V)
Control eyes	114.478 \pm 12.157	227.528 \pm 20.268	158.632 \pm 12.402	11.540 \pm 1.187	87.088 \pm 7.053
Treatment eyes	120.756 \pm 9.679	244.896 \pm 16.645	160.933 \pm 9.919	12.808 \pm 2.590	82.712 \pm 6.750

Data are presented as mean \pm standard deviation. ERG, electroretinogram; Rod-R, rod cell response; Max-R, maximum mixing response; Cone-R, cone cell response; Ops, oscillatory potentials.

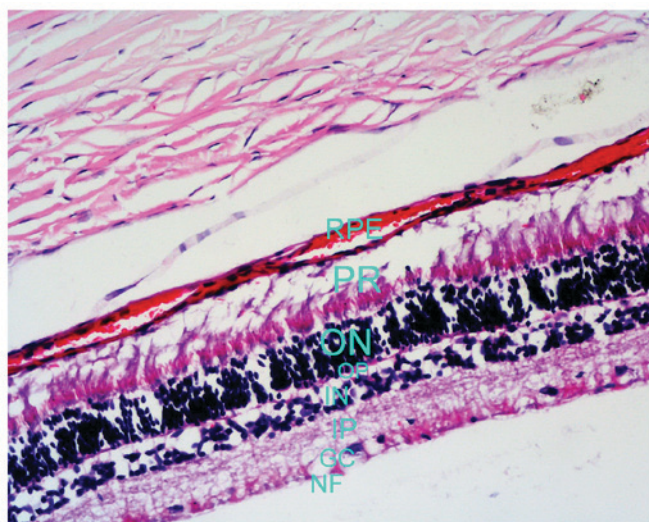


Figure 1. Control eye (hematoxylin and eosin staining; magnification, x100). RPE, retinal pigment epithelium; PR, photoreceptor cell layer, ON, outer plexiform layer; OP, outer plexiform layer; IN, inner nuclear layer; IP, inner plexiform layer; GC, ganglion cell layer; NF, nerve fiber layer.

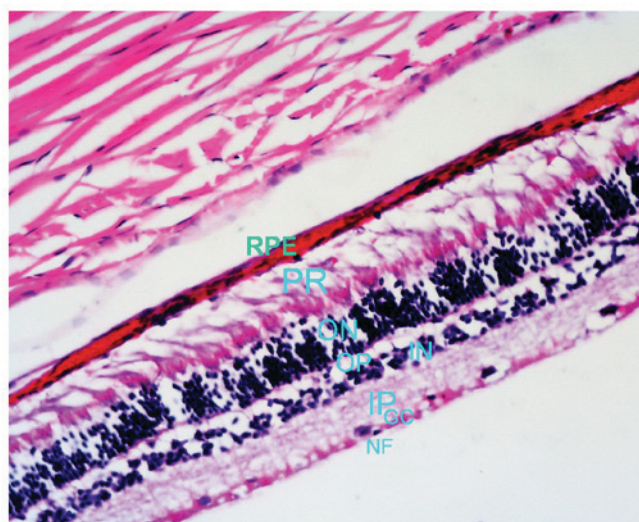


Figure 2. Treatment eye (hematoxylin and eosin staining; magnification, x100). RPE, retinal pigment epithelium; PR, photoreceptor cell layer; ON, outer plexiform layer; OP, outer plexiform layer; IN, inner nuclear layer; IP, inner plexiform layer; GC, ganglion cell layer; NF, nerve fiber layer.

oculopathy. The animals were purchased from the Laboratory Animal Center of Xuzhou Medical College (Xuzhou, China). Conventional housing and diet were provided for one week before the experiment to maintain the body weight at 2.5-3.0 kg. This study was approved by the Animal Ethics Committee of Animal Center of Xuzhou Medical College.

Suncon medical adhesive was purchased from the Beijing Suncon Science and Technology Development Co., Ltd. (Beijing, China). The Retiscan Electrophysiology Examination System was from Roland Inc. (Waiblingen, Germany), while contact lens and needle electrodes were obtained from the Beijing Gaoshi Yuanwang Science and Technology Co., Ltd. (Beijing, China).

Interventions. The rabbits were anaesthetized by intravenous (auricular vein) injection of 3% pentobarbital sodium at a dose of 1 ml/kg. In each rabbit, one eye was chosen as a treatment eye, and this eye received an intravitreal injection of 0.05 ml of the Suncon medical adhesive. Another eye served as the control eye. The Suncon medical adhesive was aspirated with a 1-ml sterile syringe and injected intravitreally in the treatment eye at 3 mm behind the upper limbus of the sclera. The depth of insertion was 0.7 cm in the vertical direction of the eye center. Suncon medical adhesive was slowly injected into the vitreous body, after which the needle was removed and pressure was applied with a cotton

bud. Chloramphenicol eye drops were then administered into this eye. The control eye received intravitreal injection of 0.05 ml of normal saline.

Outcome measures. The conjunctiva, sclera, cornea, anterior chamber and lens were observed with a slit lamp before the intravitreal injection of Suncon medical adhesive, and on days 1, 7, 14, 21 and 28 after the injection. In addition, the vitreous body and retina were examined with an indirect ophthalmoscope (Barui Medical Equipment Co., Beijing, China). The electroretinogram (ERG) examination was performed 28 days after the intravitreal injections. The ERG pattern was selected with Reti port32 (Barui Medical Equipment Co.), and the position of each wave was selected, and b-wave amplitude of rod cell response (Rod-R), maximum mixing response (Max-R) and cone cell response (Cone-R), P₂-wave amplitude of oscillatory potentials (Ops), and mean amplitude of 30 Hz scintillation response were recorded. The stimulator was GanzfeldQ450, and the flash source was white light-emitting diode.

After examinations, the animals were euthanized. The eyeballs were removed and immersed in the eyeball fixation solution (150 ml of 80% ethanol, 60 ml of formalin, 15 ml of glacial acetic acid, and 1 g of crystallized picric acid), dehydrated, embedded in paraffin, sliced, stained with hematoxylin and eosin, and subjected to light microscopy.

Statistical analysis. Statistical analysis was performed with SPSS 16.0 statistical software (SPSS, Inc., Shanghai, China). Quantitative data are shown as mean \pm standard deviation, and the t-test was used for intergroup comparisons. $P < 0.05$ was considered to indicate a statistically significant difference.

Results

Inflammatory reaction. No inflammatory reaction (e.g., keratic precipitates or anterior chamber flare) were observed on a slit lamp examination in either treatment or control eyes.

ERG. Table I shows the mean amplitude of ERG patterns in treatment and control eyes. The differences in the b-wave of Rod-R, Max-R and Cone-R, P₂-wave amplitude of Ops, and mean amplitude of 30 Hz scintillation response were not statistically significant between eyes subjected to the Suncon medical adhesive or saline.

Light microscopy examination. Layers of retina were normal, albeit the retinal inner and outer limiting membranes were observed with difficulties. In the control eyes, the cells of the nerve fiber, ganglion cell, inner plexiform, inner nuclear, outer plexiform, outer nuclear, photoreceptor cell layers, and retinal pigment epithelium were morphologically intact and well organized (Fig. 1). Similarly, the cells in the corresponding layers of treatment eyes were morphologically intact and well organized, and exhibited no bleeding, exudation or retinal detachment (Fig. 2).

Discussion

In the present study, we tested the suitability of Suncon medical adhesive for 23G minimally invasive vitrectomy, with a specific focus to potential toxicity to retina. In addition to ophthalmologic evaluation, we recorded b-wave, which reflects the electrical activity in bipolar cells and Müller cells, and represents the functional status of retina (6). We

demonstrate that intravitreal injection of 0.05 ml of Suncon medical adhesive causes no damage to the retinal function. Light-microscopy examination found that the cells in each layer of the retina in the treatment group were morphologically normal. Furthermore, no obvious inflammatory reaction and no adverse effects on function and morphology of retinal cells were observed.

In conclusion, Suncon medical adhesive injected at doses of 0.05 ml is well-tolerated by the retina. Therefore, the Suncon medical adhesive is a suitable alternative to fibrin glue. This may be especially relevant for patients with thinner suture in the scleral incision, to prevent incision leakage and incomplete closure.

Acknowledgements

This study was supported by the Major Research Project of Jiangsu Provincial Health Department (grant no. H201054).

References

1. Batman C, Ozdamar Y, Mutevelli S, Sonmez K, Zilelioglu G and Karakaya J: A comparative study of tissue glue and vicryl suture for conjunctival and scleral closure in conventional 20-gauge vitrectomy. *Eye (Lond)* 23: 1382-1387, 2009.
2. Batman C, Ozdamar Y, Aslan O, Sonmez K, Mutevelli S and Zilelioglu G: Tissue glue in sutureless vitreoretinal surgery for the treatment of wound leakage. *Ophthalmic Surg Lasers Imaging* 39: 100-106, 2008.
3. Huang M and Ye Y: Medical adhesive in the treatment of eyelid injury. *J Ocular Trauma Occup Eye Dis* 25: 850, 2003 (In Chinese).
4. Setlik DE, Seldomridge DL, Adelman RA, Semchyshyn TM and Afshari NA: The effectiveness of isobutyl cyanoacrylate tissue adhesive for the treatment of corneal perforations. *Am J Ophthalmol* 140: 920-921, 2005.
5. Meskin SW, Ritterband DC, Shapiro DE, Kusmierczyk J, Schneider SS, Seedor JA and Koplins RS: Liquid bandage (2-octyl cyanoacrylate) as a temporary wound barrier in clear corneal cataract surgery. *Ophthalmology* 112: 2015-2021, 2005.
6. Wu L and Wu D: *Clinical visual electrophysiology*. Science Press, Beijing, pp17-20, 1999.