



Case Report

An Indonesian male with congenital hypogonadotropic hypogonadism: A case report and literature review



Leadri Surya Arrosy, Hermina Novida*

Department of Internal Medicine, Faculty of Medicine, Universitas Airlangga – Dr. Soetomo General Academic Hospital, Surabaya, Indonesia

ARTICLE INFO

Keywords:

Congenital hypogonadotropic hypogonadism
Follicle-stimulating hormone
Luteinizing hormone
Testosterone

ABSTRACT

Introduction: Congenital hypogonadotropic hypogonadism (CHH) is a rare disorder caused by insufficient gonadotropin-releasing hormone (GnRH) production.

Case presentation: An Indonesian adolescent, 22 years old, Javanese ethnic, complained of a small penis, low sexual desire, fatigue, and anosmia since childhood. Medical history stated that the patient had low testosterone levels 7 years ago and received testosterone once. Testosterone, luteinizing hormone (LH), and follicle-stimulating hormone (FSH) were decreased. The testicular ultrasound result was bilateral microtestis, suspicious of bilateral hypoplasia of the epididymis. Brain MRI also supports the diagnosis of hypogonadotropic hypogonadism, and the patient received Sustanon of 250 mg/2 weeks. The patient showed a good prognosis after 1 month of therapy.

Discussion: The success of CHH therapy must be explored to improve its management.

Conclusion: CHH in an Indonesian male shows a good prognosis with testosterone injection.

1. Introduction

Congenital hypogonadotropic hypogonadism (CHH) is a rare disorder caused by insufficient production of gonadotropin-releasing hormone (GnRH), which is the primary hormone that regulates the reproductive axis [1,2]. It is estimated that as many as 1 in 4000 births experience CHH [3,4]. Patients usually require lifelong treatment, but 10–20% of patients show spontaneous recovery of reproductive function [1,5]. This study reported an Indonesian male with congenital hypogonadotropic hypogonadism. We report based on SCARE guidelines 2020 [6].

2. Case presentation

An Indonesian adolescent, 22 years old, Javanese ethnic, complained of a small penis, low sexual desire, fatigue, and anosmia since childhood to hospital via outpatient polyclinic. Medical history stated that the patient had low testosterone levels 7 years ago and received testosterone once. One year ago, the patient was involved in a motorcycle accident and had an epidural hemorrhage. Afterwards, craniotomy debridement, dura mater exploration, decortication, cranialization, and

reconstruction were performed. Laboratory examination showed testosterone of 6.5 mg/dL, luteinizing hormone (LH) of 1.6 mUI/mL, and follicle-stimulating hormone (FSH) of 1.55 mUI/mL. Testicular ultrasound results showed a right scrotum size of $0.93 \times 0.90 \times 1.73$ cm, left scrotum size of $1.04 \times 0.78 \times 1.51$ cm, and intratestis Doppler vascularization decreased (Fig. 1). Brain MRI showed fluid intensity with a firm boundary in the intrasellar that pushed and thinned out the pituitary to the inferior following a partially empty sella, no intrasellar mass, encephalomalacia cyst in the right frontal lobe, bilateral maxillary sinusitis (Fig. 2).

The researchers diagnosed hypogonadotropic hypogonadism, and the patient received Sustanon of 250 mg/2 weeks. The patient experienced improvement after 1 month of therapy, in which pubic growth occurred in the genitalia. Laboratory examination showed FSH of 0.44 mUI/mL and testosterone of 464.82 mg/dL. In the 2nd month, the patient had no complaints and the hormonal analysis of stable (growth hormone of 0.671 ng/mL, prolactin of 211.8 uIU/mL, and cortisol of 67.44 ng/mL). Sustanon injection (250 mg) is continuous every 2 weeks for patient therapy.

* Corresponding author. Department of Internal Medicine, Faculty of Medicine, Universitas Airlangga – Dr. Soetomo General Academic Hospital, Jl. Mayjend Prof. Dr. Moestopo No. 6-8, Airlangga, Gubeng, Surabaya, East Java, 60286, Indonesia.

E-mail address: hermina.novida0122@gmail.com (H. Novida).

<https://doi.org/10.1016/j.amsu.2022.104720>

Received 3 July 2022; Received in revised form 11 September 2022; Accepted 11 September 2022

Available online 15 September 2022

2049-0801/© 2022 The Authors. Published by Elsevier Ltd on behalf of IJS Publishing Group Ltd. This is an open access article under the CC BY-NC-ND license (<http://creativecommons.org/licenses/by-nc-nd/4.0/>).

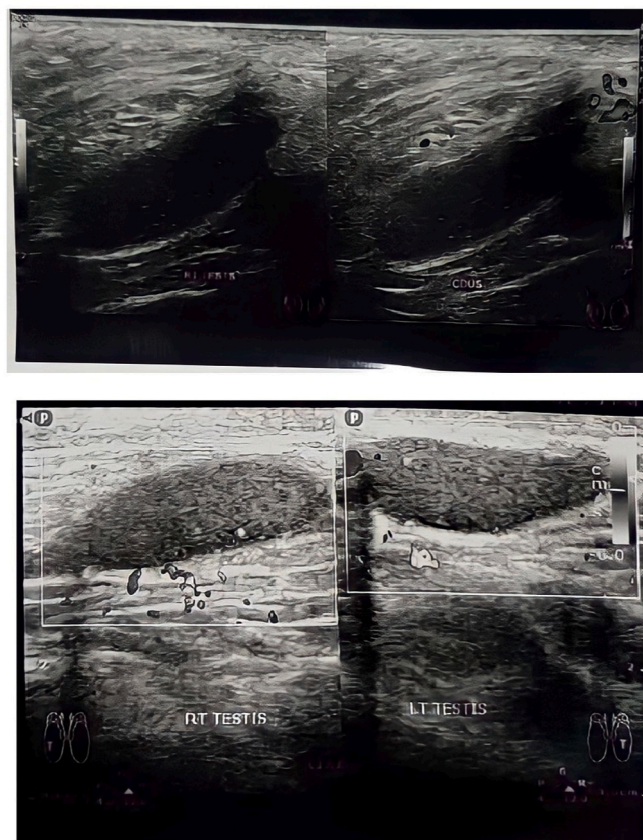


Fig. 1. Testicular ultrasound showing bilateral microtestis.

3. Discussion

Physical examination should confirm hair growth, body proportions, penile length, location of the urethral meatus, testicular volume (using a Prader orchidometer), breast enlargement, and other dysmorphic features. Adult males usually have a testicular volume more significant than 15 mL [7,8]. A eunuchoidal proportion is expected as well as decreased muscle mass. In addition, signs of associated developmental abnormalities such as cryptorchidism with or without micropenis and midline defects. Phenotypes such as cleft palate or sensorineural deafness suggest a syndromic form of CHH, most commonly associated with Kallmann syndrome [1,9].

Isolated hypogonadotropic hypogonadism is characterized by low serum testosterone levels in male individuals (usually <2 nmol/L) and low or normal serum levels of gonadotropins (LH and FSH) with normal pituitary function. In early adolescence (13–16 years), the diagnosis of CHH is difficult because isolated hypogonadotropic hypogonadism is common in CHH and CDGP (Constitutional Delay of Growth and Puberty). In CHH, the GnRH stimulation test has poor diagnostic value. In the absence of a gonadotropin response, this test can help to confirm severe GnRH deficiency. Several other tests have been proposed to differentiate CHH and CDGP, but to date, there is no gold standard diagnostic test to differentiate CHH from CDGP fully. Inhibin B is a Sertoli cell number marker and correlates with testicular volume. Men with CHH and severe GnRH deficiency usually have deficit serum inhibin B levels (<30 pg/mL) [1,3].

Measuring LH and FSH concentrations can help differentiate between primary and secondary hypogonadism. In secondary hypogonadism, normal or low-normal LH does not correspond to low testosterone levels. If secondary hypogonadism is detected, prolactin levels should be determined to rule out hyperprolactinemia, serum iron, and TIBC measured to exclude hemochromatosis, and imaging of the

pituitary with MRI to exclude space-occupying lesions [7]. Bone densitometry may be used in men with minimal trauma, fracture, loss of height, or known low bone mass. When common causes of secondary hypogonadism are excluded, the diagnosis of isolated hypogonadotropic hypogonadism remains. The disorder is idiopathic or associated with a genetic syndrome. The presence of specific features, such as small testes plus anosmia and cleft palate (Kallmann syndrome), short stature (e.g., deletion of adjacent genes from the X chromosome), and the primary adrenal deficiency (NROB1 mutations) may facilitate recognition of specific syndromes [10].

The history of anosmia is reliable, but claims to have a ‘good’ sense of smell are not always consistent with formal olfactory testing [1]. Coronal T2-sequence brain MRI via the olfactory bulb depicting the absence or hypoplasia of the olfactory bulb is pathognomonic for Kallmann syndrome [11]. Genetic testing is helpful for diagnosis, prognosis and genetic counselling in CHH. In summary, X-linked inheritance was observed in pedigrees when male-to-male transmission of the disease phenotype did not occur, but the disease was observed in male members of the maternal line. This feature is typical for the KAL1 (ANOS1) mutation underlying Kallmann syndrome [1,3]. Algorithm for diagnosis of isolated GnRH deficiency in males (Fig. 3) [12].

Hormone replacement with testosterone is the definitive treatment for hypogonadism [13]. After the intramuscular injection of 200 mg of testosterone, the serum testosterone concentration increases to the supraphysiological range within 24–48 hours and gradually decreases to the low-normal range over 2 weeks. This pharmacokinetic variability can cause fluctuations in the patient’s mood, libido, and energy levels. In contrast, administration of 100 mg weekly produces physiological concentrations but requires four injections every month [10,14]. Testosterone therapy does not induce testicular growth or spermatogenesis in men with HH, as it depends on high intra-testicular concentrations of testosterone produced by LH-stimulated Leydig cells, in conjunction with FSH acting on Sertoli cells. Therefore, fertility induction therapy with pulsatile GnRH or exogenous gonadotropins is necessary [15].

4. Conclusion

An Indonesian adolescent, 22 years old, Javanese ethnic, complained of a small penis, low sexual desire, fatigue, and anosmia since childhood. Medical history stated that the patient had low testosterone levels 7 years ago and received testosterone once. Testosterone, LH, and FSH were decreased. The testicular ultrasound result was bilateral microtestis, suspicious of bilateral hypoplasia of the epididymis. Brain MRI also supports the diagnosis of hypogonadotropic hypogonadism, and the patient received Sustanon of 250 mg/2 weeks. The patient showed a good prognosis after 1 month of therapy. CHH in an Indonesian male shows a good prognosis with testosterone injection. CHH diagnosis is often an obstacle to genetic test confirmation in low-resource settings.

Ethical approval

Not applicable.

Sources of funding

None.

Author contribution

All authors contributed toward data analysis, drafting and revising the paper, gave final approval of the version to be published and agree to be accountable for all aspects of the work.

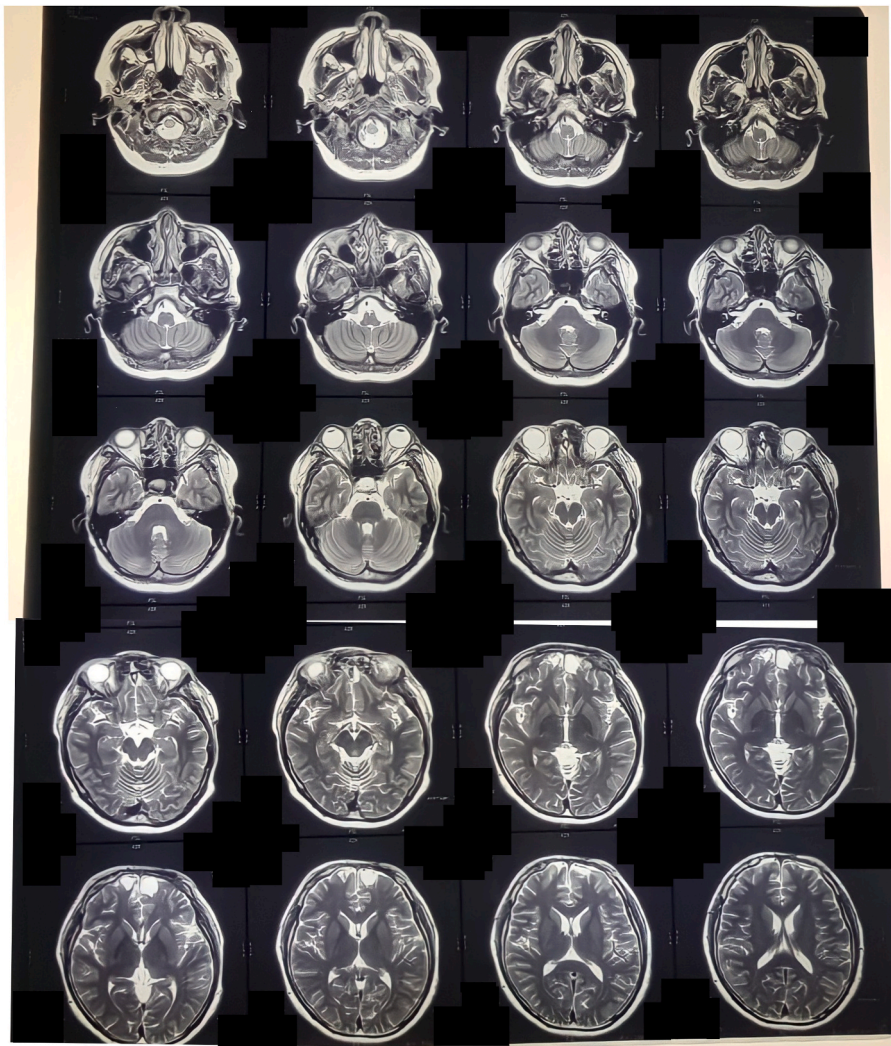


Fig. 2. Brain magnetic resonance imaging (MRI).

Registration of research studies

1. Name of the registry: -.
2. Unique Identifying number or registration ID: -.
3. Hyperlink to your specific registration (must be publicly accessible and will be checked): -.

Guarantor

Hermina Novida is the person in charge of the publication of our manuscript.

Consent

Written informed consent was obtained from the patient for publication of this case report and accompanying images. A copy of the written consent is available for review by the Editor-in-Chief of this journal on request.

Provenance and peer-review

Not commissioned, externally peer-reviewed.

Conflict of interest

Leadri Surya Arrosy and Hermina Novida declare that they have no conflict of interest.

Funding

None.

Ethical approval

This case report does not require any ethical approval.

Consent

Written informed consent was obtained from the patient for publication of this case report and accompanying images. A copy of the written consent is available for review by the Editor-in-Chief of this journal on request.

Declaration of competing interest

Leadri Surya Arrosy and Hermina Novida declare that they no conflict of interest.

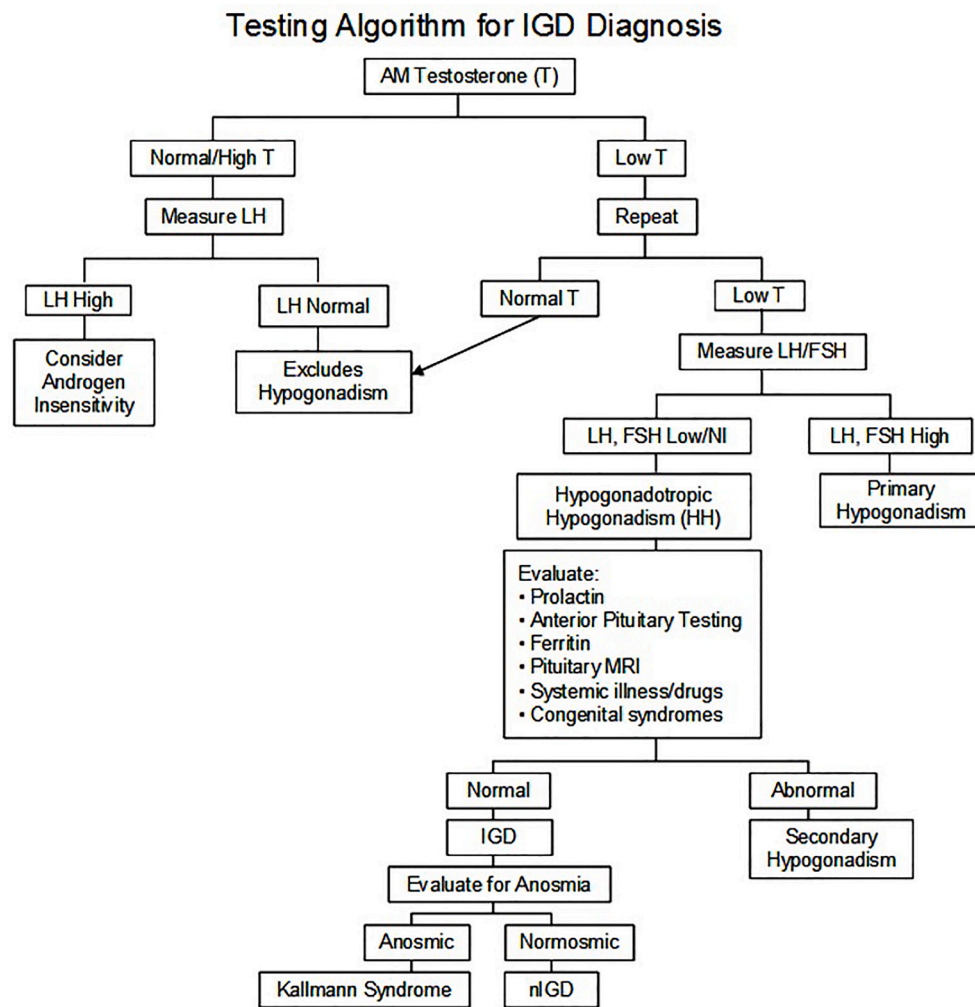


Fig. 3. Testing algorithm to establish the diagnosis of isolated GnRH deficiency in males.

Note: IGD = isolated gonadotropin deficiency, FSH = follicle-stimulating hormone, and LH = luteinizing hormone

Acknowledgement

We would like to thank our editor, “Fis Citra Ariyanto”.

References

- [1] U. Boehm, P.M. Bouloux, M.T. Dattani, N. de Roux, C. Dodé, L. Dunkel, et al., Expert consensus document: European Consensus Statement on congenital hypogonadotropic hypogonadism—pathogenesis, diagnosis and treatment, *Nature reviews Endocrinology* 11 (9) (2015) 547–564, <https://doi.org/10.1038/nrendo.2015.112>.
- [2] A.M. Sugiarto, S.A. Soelistijo, A female with isolated hypogonadotropic hypogonadism: a case report and review article, *Annals of medicine and surgery* 74 (2022) (2012), 103289, <https://doi.org/10.1016/j.amsu.2022.103289>.
- [3] D. Cassatella, S.R. Howard, J.S. Acierno, C. Xu, G.E. Papadakis, F.A. Santoni, et al., Congenital hypogonadotropic hypogonadism and constitutional delay of growth and puberty have distinct genetic architectures, *European journal of endocrinology* 178 (4) (2018) 377–388, <https://doi.org/10.1530/eje-17-0568>.
- [4] P. Cennikon, A. Bella, H. Berliana, Y. Rina, Case report : a woman 27 Year old with Mosaic turner syndrome associate hypogonadotropic hypogonadism, *Indonesian Andrology and Biomedical Journal* 1 (2) (2020) 42–47, <https://doi.org/10.20473/iabj.v1i2.32>.
- [5] M.S.P. Wijanarko, C. Stella, G. Oktavianto, Adult Male’s penile size Measurement and its affecting factors, *Indonesian Andrology and Biomedical Journal* 2 (2) (2021) 55–62, <https://doi.org/10.20473/iabj.v2i2.124>.
- [6] R.A. Agha, T. Franchi, C. Sohrabi, G. Mathew, A. Kerwan, The SCARE 2020 guideline: updating consensus surgical CAse REport (SCARE) guidelines, *International journal of surgery (London, England)* 84 (2020) 226–230, <https://doi.org/10.1016/j.ijsu.2020.10.034>.
- [7] A. Ross, S. Bhasin, Hypogonadism: its prevalence and diagnosis, *The Urologic clinics of North America* 43 (2) (2016) 163–176, <https://doi.org/10.1016/j.ucl.2016.01.002>.
- [8] M. Chen, E.A. Eugster, Central precocious puberty: update on diagnosis and treatment, *Paediatric drugs* 17 (4) (2015) 273–281, <https://doi.org/10.1007/s40272-015-0130-8>.
- [9] M.I. Stamou, N.A. Georgopoulos, Kallmann syndrome: phenotype and genotype of hypogonadotropic hypogonadism, *Metabolism: clinical and experimental* 86 (2018) 124–134, <https://doi.org/10.1016/j.metabol.2017.10.012>.
- [10] S. Basaria, Male hypogonadism, *Lancet (London, England)* 383 (9924) (2014) 1250–1263, [https://doi.org/10.1016/s0140-6736\(13\)61126-5](https://doi.org/10.1016/s0140-6736(13)61126-5).
- [11] D.S. Swee, R. Quinton, Managing congenital hypogonadotropic hypogonadism: a contemporary approach directed at optimizing fertility and long-term outcomes in males, *Therapeutic advances in endocrinology and metabolism* 10 (2019), 2042018819826889, <https://doi.org/10.1177/2042018819826889>.
- [12] R. Balasubramanian, W.F. Crowley, *Isolated Gonadotropin-Releasing Hormone (GnRH) Deficiency*. GeneReviews, University of Washington, 2007.
- [13] R. Fraietta, D.S. Zylberstein, S.C. Esteves, Hypogonadotropic hypogonadism revisited, *Clinics (Sao Paulo, Brazil)* 68 (Suppl 1) (2013) 81–88, [https://doi.org/10.6061/clinics/2013\(sup01\)09](https://doi.org/10.6061/clinics/2013(sup01)09). Suppl 1.
- [14] E. Safitri, Hariadi Mu, Comparison of biotechnological culture of hypoxia-conditioned rat mesenchymal stem cells with conventional in vitro culture of normoxia-conditioned rat mesenchymal stem cells for testicular failure therapy with low libido in rats, *Veterinary World* 12 (6) (2019) 916–924, <https://doi.org/10.14202/vetworld.2019.916-924>.
- [15] S.R. Howard, L. Dunkel, Management of hypogonadism from birth to adolescence, *Best practice & research Clinical endocrinology & metabolism* 32 (4) (2018) 355–372, <https://doi.org/10.1016/j.beem.2018.05.011>.