

## Case and Review

# A Case of Loose Anagen Hair Syndrome in a Southeast Asian Boy

Kanchana Leerunyakul Poonkiat Suchonwanit

Division of Dermatology, Faculty of Medicine, Ramathibodi Hospital, Mahidol University, Bangkok, Thailand

## Keywords

Alopecia · Floppy sock appearance · Hair loss · Pluckable hair · Ruffling cuticle

## Abstract

Loose anagen hair syndrome is an uncommon hair disorder, particularly in non-Caucasian children. We report the case of a 13-year-old Thai boy who presented with a single patch of hair thinning on the frontal scalp with excessive shedding, and the hairs did not grow long. Microscopic examination showed naked anagen bulbs with ruffling of the cuticle, which is compatible with loose anagen hair syndrome. To our knowledge, there is no reported case in Southeast Asian children.

© 2019 The Author(s)  
Published by S. Karger AG, Basel

## Introduction

Loose anagen hair syndrome (LAS) was first introduced as “easily pluckable hair” in children in 1984 by Zuan and was later fully described as LAS by Price and Gummer [1]. Classically, the condition presents in young children who have blond sparse hairs that do not grow long and are easily retracted. Parents usually report that the child needs few haircuts, and often complain that the hair is difficult to manage. Here, we present a case report of a Thai boy with LAS.

## Case Report

A healthy 13-year-old boy with black-colored hair presented with a patch of hair thinning that did not grow over time. The symptom started at the age of 5 years. His parents reported having normal hair and scalp. A family history of hair disease was denied. On physical examination, a patch of hair thinning was observed on the frontal scalp (Fig. 1). Within the patch, there was no scalp lesion. No hair shaft abnormality such as brittleness or lusterless was observed. The hairs in the patch were easily pulled by gentle traction. The hair pull test was negative on the rest of the scalp. The trichogram showed 88% of abnormal anagen hairs, 10% of telogen hairs, and 2% of broken hairs. Under microscopy, naked anagen hair bulbs with ruffling of the hair cuticle were observed (Fig. 2). Other physical examinations including nails and teeth were unremarkable. Based on the history and physical examination, his hair condition was compatible with LAS. The parents and child were advised on the natural course of the disease and to avoid activities that would result in further hair loss such as pulling.

## Discussion

LAS is a sporadic or autosomal dominant disorder with incomplete or variable penetrance. The key features of the condition are short hair length, excessive shedding of hair and alteration of hair texture. There have been three different phenotypes proposed by Olsen et al. [2]: (A) sparse hair that does not grow long, (B) diffuse or patchy unruly hair, and (C) normal hair appearance with increased shedding that is generally found in adults. Patients with type A and B can turn to have type C when they are older, causing the underdetection in adults, and may diminish the phenotype from the autosomal dominant trait. LAS is isolated in most cases, but it occasionally occurs in association with hereditary or developmental disorders such as coloboma, ectrodactyly-ectodermal dysplasia-cleft lip/palate syndrome, FG syndrome, hypohidrotic ectodermal dysplasia, nail-patella syndrome, Noonan syndrome, trichorhinophalangeal syndrome, and uncombable hair syndrome [3]. In addition, LAS is considered to be a severity factor for trichotillomania [4].

LAS is typically diagnosed in children who are between 2 and 6 years of age. Most cases are Caucasian with Fitzpatrick skin type I–II and blond hair, but according to a retrospective study, the condition also affects patients with black or brown hair and those with multiracial backgrounds [5]. This is supported by two case series from Egypt and India, and a case report in an African-American girl [6–8]. Our patient who is the first case from Southeast Asia also confirms that LAS can occur in other ethnicities. LAS has a female predominance. However, this might be due to the fact that males usually have a short hairstyle which leads to lesser evident hair disorders and underdiagnoses.

The affected hair often presents with a dull, lusterless, unruly, or matted appearance that sometimes mimics woolly hair or uncombable hair. The condition is usually restricted to the scalp, but the involvement of eyebrows and body hair has been reported in 1 case [9]. The loose anagen hair is not a diagnostic feature of LAS as it can be found in a healthy individual [2]. Tosti and Piraccini [10] proposed that the diagnosis should be made when the trichogram shows more than 70% of loose anagen hairs. Later, Cantatore-Francis and Orlov [5] conducted a retrospective study and suggested that LAS should be diagnosed when at least 50% of loose anagen hairs are seen on the trichogram. With light microscopic examination, LAS presents with anagen hairs that have misshapen bulbs, ruffled cuticles, and absent inner root sheaths. Pseudotrichothiodystrophy under a polarized microscope was also reported. The

alternating light and dark horizontal bands were detected corresponding to the kinks between each undulating hair shaft [5]. A recent study evaluating the trichoscopic features of LAS demonstrated that rectangular black granular structures, solitary yellow dots, and a high degree of follicular units with single hairs are favorable characteristics for diagnosis [11].

The main pathogenesis of the disease is weakened adhesion between the inner root sheath and the cuticle of anagen follicles. Electron microscopy detected vacuolization and intercellular edema in Huxley cells, and dyskeratotic changes of Henle cells and cuticle cells of both the inner root sheath and hair shaft [12]. These abnormalities result in losing the anchoring function of the inner root sheath which persists throughout the lifetime. We believed that the keratin genes are important determinants to understand the pathogenesis of the disease. Interestingly, mutations in the *K6hf* gene encoding for companion-layer keratin were identified in some familial cases [13]. Another possible candidate may be the *K6irs* gene which is specific for inner root sheath keratin formation [14].

The new growing hair can replace the shedded hair normally. The length of hair is determined by the duration of the anagen phase. With progressing age, the child seems to have a longer anagen duration leading to longer hair length [12]. LAS usually improves over the years and does not require treatment. However, the topical minoxidil might help fasten the resolution and decrease the severity as it lengthens the duration of anagen. A case report of applying 5% topical minoxidil solution with a tapering regimen for 20 months showed significant improvement in hair density. The effect was still observed 28 months after cessation of medication [15]. Another report of oral minoxidil use in a girl who did not respond to the topical form also showed improvement in hair color, hair pattern, hair density, and hair length. Her hair remained normal after the discontinuation at the 12-month follow-up visit [16].

In conclusion, establishing the correct diagnosis of LAS is important for appropriate management and counseling to patients and parents. We present this case to raise the awareness in considering the diagnosis of LAS in Asian children who present with nonscarring alopecia.

### Statement of Ethics

The authors have no ethical conflicts to disclose. The patient's legal guardian provided consent.

### Disclosure Statement

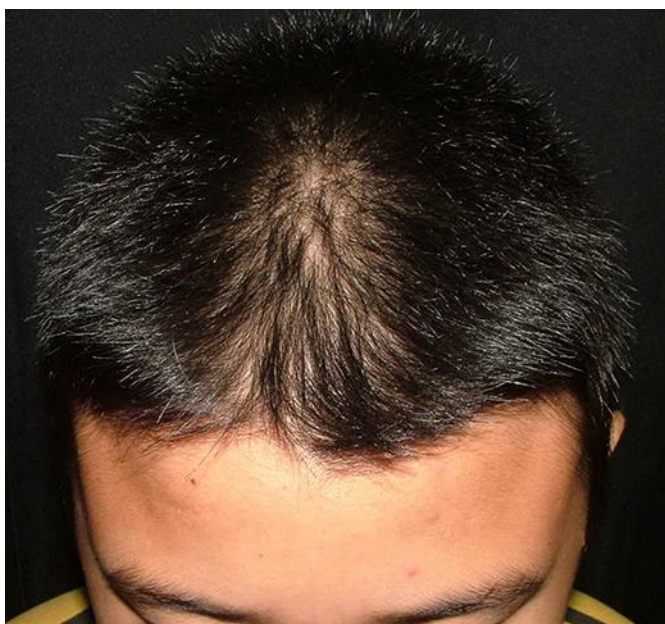
The authors have no conflicts of interest to declare.

### Author Contributions

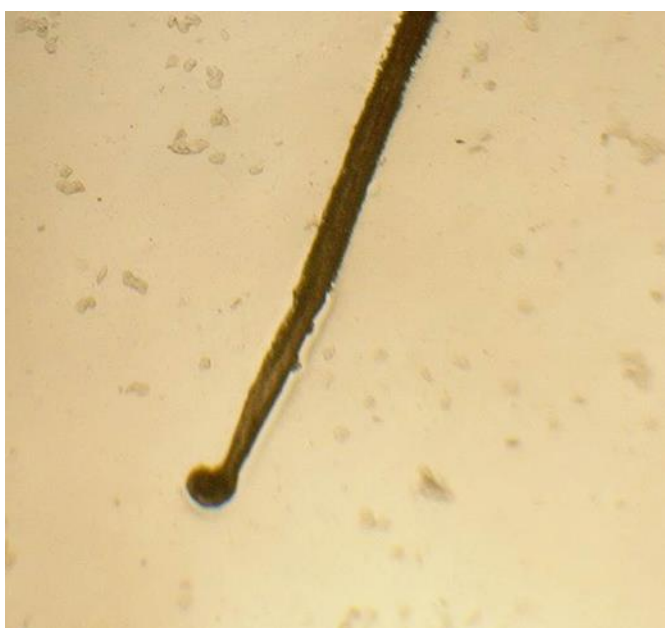All named authors meet the International Committee of Medical Journal Editors (ICMJE) criteria for authorship for the manuscript, take responsibility for the integrity of the work as a whole, and have given final approval to the version to be published.

## References

- 1 Price VH, Gummer CL. Loose anagen syndrome. *J Am Acad Dermatol*. 1989 Feb;20(2 Pt 1):249–56.
- 2 Olsen EA, Bettencourt MS, Coté NL. The presence of loose anagen hairs obtained by hair pull in the normal population. *J Investig Dermatol Symp Proc*. 1999 Dec;4(3):258–60.
- 3 Lee AJ, Maino KL, Cohen B, Sperling L. A girl with loose anagen hair syndrome and uncombable, spun-glass hair. *Pediatr Dermatol*. 2005 May-Jun;22(3):230–3.
- 4 Thai KE, Sinclair RD. Loose anagen syndrome as a severity factor for trichotillomania. *Br J Dermatol*. 2002 Oct;147(4):789–92.
- 5 Cantatore-Francis JL, Orlov SJ. Practical guidelines for evaluation of loose anagen hair syndrome. *Arch Dermatol*. 2009 Oct;145(10):1123–8.
- 6 Agi C, Cohen B. A case of loose anagen syndrome in an African American girl. *Pediatr Dermatol*. 2015 May-Jun;32(3):e128–9.
- 7 Abdel-Raouf H, El-Din WH, Awad SS, Esmat A, Al-Khiat M, Abdel-Wahab H, et al. Loose anagen hair syndrome in children of Upper Egypt. *J Cosmet Dermatol*. 2009 Jun;8(2):103–7.
- 8 Dey V, Thawani M. Loose anagen hair syndrome in black-haired Indian children. *Pediatr Dermatol*. 2013 Sep-Oct;30(5):579–83.
- 9 Chapman DM, Miller RA. An objective measurement of the anchoring strength of anagen hair in an adult with the loose anagen hair syndrome. *J Cutan Pathol*. 1996 Jun;23(3):288–92.
- 10 Tosti A, Piraccini BM. Loose anagen hair syndrome and loose anagen hair. *Arch Dermatol*. 2002 Apr;138(4):521–2.
- 11 Rakowska A, Zadurska M, Czuwara J, Warszawik-Hendzel O, Kurzeja M, Maj M, et al. Trichoscopy findings in loose anagen hair syndrome: rectangular granular structures and solitary yellow dots. *J Dermatol Case Rep*. 2015 Mar;9(1):1–5.
- 12 Mirmirani P, Uno H, Price VH. Abnormal inner root sheath of the hair follicle in the loose anagen hair syndrome: an ultrastructural study. *J Am Acad Dermatol*. 2011 Jan;64(1):129–34.
- 13 Chapalain V, Winter H, Langbein L, Le Roy JM, Labrèze C, Nikolic M, et al. Is the loose anagen hair syndrome a keratin disorder? A clinical and molecular study. *Arch Dermatol*. 2002 Apr;138(4):501–6.
- 14 Porter RM, Corden LD, Lunny DP, Smith FJ, Lane EB, McLean WH. Keratin K6irs is specific to the inner root sheath of hair follicles in mice and humans. *Br J Dermatol*. 2001 Oct;145(4):558–68.
- 15 Chandran NS, Oranje AP. Minoxidil 5% solution for topical treatment of loose anagen hair syndrome. *Pediatr Dermatol*. 2014 May-Jun;31(3):389–90.
- 16 Cranwell WC, Sinclair R. Loose anagen hair syndrome: treatment with systemic minoxidil characterised by marked hair colour change. *Australas J Dermatol*. 2018 Nov;59(4):e286–7.



**Fig. 1.** A patch of hair thinning on the frontal area of the scalp without scale or erythema.



**Fig. 2.** Microscopic examination shows a naked anagen hair bulb with ruffling of the hair cuticle (original magnification  $\times 20$ ).