

Inserting the Ulnar Prosthesis into Radius as a Novel Salvage Surgery for Revision Total Elbow Arthroplasty with Massive Bone Defect

Mao-Qi Gong, Ji-Le Jiang, Xie-Yuan Jiang, Ye-Jun Zha, Ting Li

Department of Orthopedic Trauma, Beijing Jishuitan Hospital, Beijing 100035, China

Abstract

Background: Infection and aseptic loosening are common complications of total elbow arthroplasty (TEA) and often require revision surgery. However, bone defects, along with other complications, bring an extra difficulty to the second surgery, especially for patients with a massive bone defect in the proximal ulna. Several methods including allograft or autograft have been introduced into practice, but none sufficiently solves these problems.

Methods: We conducted a new surgical method for patients with a massive ulnar bone defect needing revision TEA. During revision arthroplasty, the ulnar prosthesis was inserted into the radius as a salvage procedure. Four consecutive patients received revision arthroplasty with this method between 2013 and 2016. Patients' data were collected to evaluate the clinical outcome.

Results: All patients had a Grade III ulnar bone defect. At the last follow-up session, all patients reported a painless, functional elbow joint. Three patients suffered from a periprosthetic infection that was completely cured using the two-stage method. No major complications, including infection, aseptic loosening, or wound problems were found. One patient had a transient ulnar neuritis, and another had a transient radial neuritis. Both patients had full recovery at the last follow-up session.

Conclusions: Inserting an ulnar prosthesis into the radius is a novel procedure for patients with a massive bone defect due to infection or aseptic loosening. It is a safe, quick, and effective treatment with a promising short-term outcome. This method should be provided as a salvage procedure for patients with a nonreconstructable ulnar bone defect.

Key words: Massive Bone Defect; Prosthesis; Radius; Revision Surgery; Salvage Surgery; Total Elbow Arthroplasty

INTRODUCTION

Total elbow arthroplasty (TEA) has been successfully used for treating complex distal humeral fractures.^[1] The prevalence of TEA in the USA is surging, with a 248% increase in primary arthroplasty and a 500% increase in revision arthroplasty during the past few years. In addition, the annual rate for revision surgery is reported to be as high as 12.8%.^[2] Studies have shown that TEA has the same efficacy for treating distal humeral fractures as open reduction and internal fixation in terms of both short- and long-term outcomes.^[3] However, similar to the complications surrounding knee or hip prostheses, infection and aseptic loosening are the main concerns of TEA with long-term use.^[4] The bone loss subsequent to infection or loosening is more catastrophic in the elbow. The infection, which is usually detected on average at 45 months, is insidious.^[5]

In addition, the ulnar is much thinner than the femur or tibia, making revision surgery more difficult. Finally, in the Chinese population, the most commonly used ulnar prosthesis size is extra small (XS),^[6] making it impossible to insert a larger prosthesis during revision surgery.

Several methods have been developed to deal with massive bone defects during revision surgery. Surgeons have tried using an allograft-prosthesis composite to repair the bone

Address for correspondence: Dr. Xie-Yuan Jiang,
Department of Orthopedic Trauma, Beijing Jishuitan Hospital,
Beijing 100035, China
E-Mail: jxy0845@sina.com

This is an open access article distributed under the terms of the Creative Commons Attribution-NonCommercial-ShareAlike 3.0 License, which allows others to remix, tweak, and build upon the work non-commercially, as long as the author is credited and the new creations are licensed under the identical terms.

For reprints contact: reprints@medknow.com

© 2016 Chinese Medical Journal | Produced by Wolters Kluwer - Medknow

Received: 06-05-2016 **Edited by:** Qiang Shi

How to cite this article: Gong MQ, Jiang JL, Jiang XY, Zha YJ, Li T. Inserting the Ulnar Prosthesis into Radius as a Novel Salvage Surgery for Revision Total Elbow Arthroplasty with Massive Bone Defect. Chin Med J 2016;129:1917-21.

Access this article online

Quick Response Code:



Website:
www.cmj.org

DOI:
10.4103/0366-6999.187863

defect;^[7] however, the associated complication rate is rather high. Complex surgical steps also bring more injury, thus increasing soft tissue-related complications. Autografting with the iliac crest bone is another method that has been successfully used in revision TEA; however, the experience is limited and complications related to the bone harvest site are inevitable.^[8] Arthrodesis has also been tried in patients with deep infection as a salvage solution; unfortunately, the outcome has been poor, with none of the reported patients achieving bony union.^[9] Resection arthroplasty is another method that has been utilized; however, most patients receiving this surgery have fair or poor long-term results; thus, the authors have suggested that it should only be considered when all other attempts have failed.^[10]

We have developed a novel method for TEA revision surgery, involving the insertion of the ulnar part of the prosthesis into the radius, which has not yet been reported worldwide. This method could maintain flexion and extension of the elbow joint without further damage to the soft tissue. It is an effective treatment for TEA revision with a massive bone loss in the proximal ulna due to infection or aseptic loosening. We have practiced this method in the clinic for selected patients and, herein, analyze the surgical outcomes and complications associated with this novel surgery.

METHODS

We retrospectively evaluated four patients treated with this method at our hospital between 2013 and 2016. The indication for the surgery included the need for TEA revision, massive bone loss in the proximal ulna, poor soft-tissue condition, and a relatively intact radius. Three patients had a periprosthetic infection, and one had aseptic loosening. All surgeries were conducted by the same surgical team. The study protocol was approved by the Hospital Ethics Committee. Patients were informed of possible complications, and written consents were obtained before the operation.

Patients' demographic data and perioperation information, including age, sex, reason for injury, and surgery times, were collected. Follow-up was conducted in an outpatient clinic. A radiograph was obtained 3 months after the operation, and further follow-up was conducted through a phone call.

Surgical technique

The Coonrad-Morrey elbow prosthesis was used for all patients during the revision surgery. For patients who suffered from a periprosthetic infection, a two-stage method was used. The first step involved the removal of the previous prosthesis with full debridement. Cement containing vancomycin was inserted to fill the cavity as a temporary spacer, and oral antibiotics were given to the patients as well. After 3 months, when the C-reactive protein, erythrocyte sedimentation rate, and white blood cell count were normal, the second surgery was performed. During the revision surgery, the patient was put in the supine position, and an incision was made through a posterior approach along the previous surgical scar. The ulnar nerve was first

identified and protected during surgery. The cement was taken out, and the local soft-tissue scar and stiffened joint capsule were also incised to release the joint. The humeral was dealt with first as previously described.^[6] As to the forearm, we performed osteotomy in the proximal 1 cm of the radius, thus no need to isolate the radial nerve existed, as the nerve was wrapped around the radius neck. After inserting the prosthesis fitting, we maintained the forearm in the neutral position and balanced the tension and range of motion (ROM). Then, we inserted the ulnar prosthesis into the radius with antibiotic-containing cement. Unlike in standard procedure, we chose to insert the contralateral side of the ulnar prosthesis into the radius because the radius has a reverse curve as compared with the ulna. The forearm was maintained in the neutral position after the operation. The elbow was held in 90° flexion by a cast for 3 weeks, and patients were encouraged to perform passive supervised movements. After 3 weeks, they were allowed to perform active flexion and extension. Patients were advised to permanently avoid lifting >1 kg on a repetitive basis or 5 kg in a single event.

RESULTS

The patients included three males and one female, with an average age of 55 years (48–60 years), 5 (3–8) surgeries per person on average, and an average time interval between fracture and TEA revision of 13 years (3–32 years). Bone loss of the proximal ulna before TEA revision was categorized as previously described,^[11] and all patients had a Grade III bone defect distal to the previous prosthesis. For patients with a periprosthetic infection, the two-stage method was used. The average surgery time for the revision TEA was 211 min (150–300 min).

A 56-year-old male suffered a complicated distal humeral fracture and received TEA 33 years ago (case 1). Local pain and tenderness were felt after a minor injury, and purulent discharge was found around the elbow joint 1 year later. At the time the patient came to our hospital, the flexion-extension ROM was 70–20°, and the pronation-supination ROM was –10 to 10°. He received a two-stage TEA revision surgery with an ulnar prosthesis in the radius. At the last follow-up session, the patient reported a painless elbow joint with an almost complete restoration in ROM. The main complaints were triceps weakness and slight feeling of instability [Figures 1-4].

A 58-year-old male had an open complicated distal humeral fracture 10 years ago (case 2). One month after the accident, the patient received a TEA but did not regain full ROM after the operation. The prosthesis worked well until 2 years ago when the patient felt local swelling with decreased ROM. A deep infection was confirmed using radiological and pathological evidence. The patient received a two-stage TEA revision. Due to the proximal ulna bone defect, we inserted the ulnar prosthesis into the radius. The patient had a transient radial neuritis.

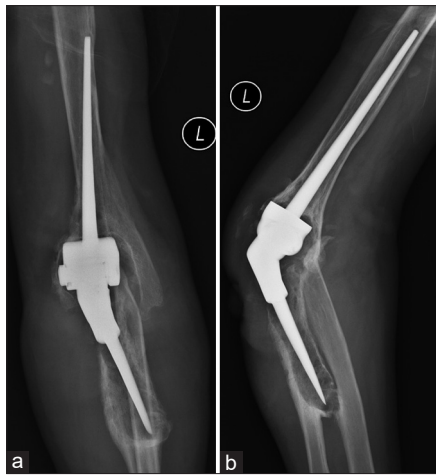

Figure 1: Radiographs of the elbow of patient who underwent the revision total elbow arthroplasty (case 1). The preoperation anterior-posterior view (a) and lateral view (b). The malposition of the ulnar prosthesis is indicated within the lucent line. A massive bone defect in the proximal ulna distal to prosthesis can be seen.

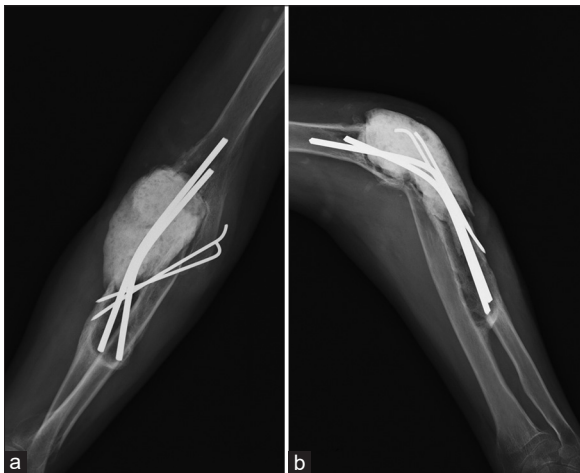

Figure 3: Radiographs of the elbow taken after the first step of revision surgery. Anterior-posterior view (a) and lateral view (b). Antibiotic-containing cement and K-wires were inserted as a temporary spacer.

A 60-year-old female received an open reduction and internal fixation due to an olecranon fracture and a radial head resection due to a radial head fracture 8 years ago (case 3). Because the elbow was still stiff after massive physiotherapy, she received TEA 4 years later. However, after the TEA, stiffness and fever still bothered her, and she underwent debridement three times. During the second debridement, the prosthesis was changed at one stage, but infection recurred. When she came to us in 2013, the flexion-extension ROM was 10–90°, and pronation-supination ROM was –10 to 10°. We initiated a two-stage TEA revision with an ulnar prosthesis in the radius; however, the proximal humeral shaft broke when we tried to remove the humeral prosthesis. Conservative treatment for the fracture was offered, and after 3 months, a plate was placed in the humerus to fix the fracture site at the same time of the TEA revision surgery. The patient reported a painless, functional elbow joint after

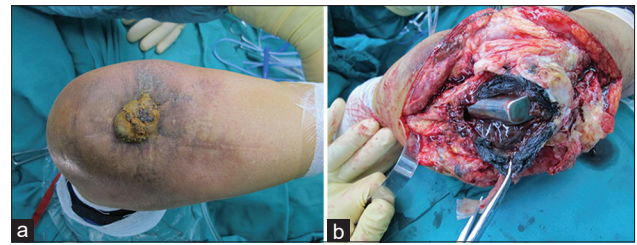


Figure 2: Photos of the debridement of patient who underwent the revision total elbow arthroplasty. (a) A sinus posterior to the elbow joint. (b) The loose implant, surrounded by necrotic tissue, was found and removed.

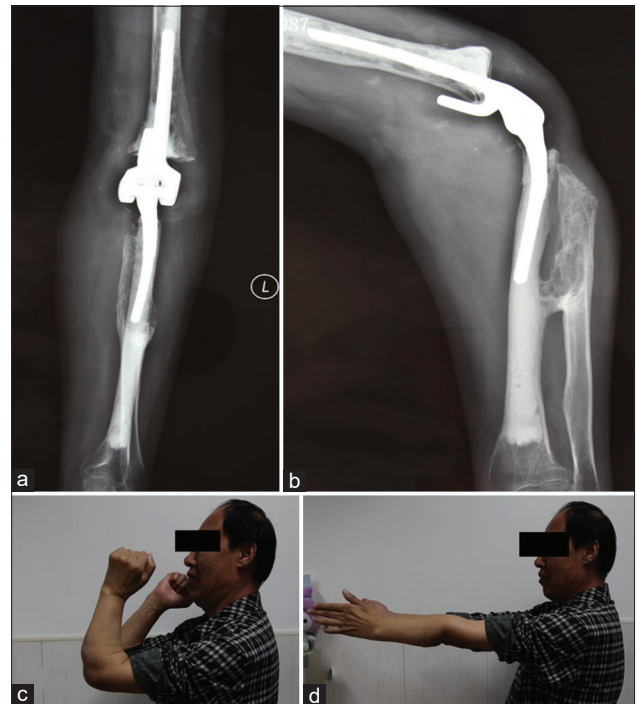

Figure 4: Radiographs and photos taken 3 months after the operation of the revision total elbow arthroplasty and radiographs of the elbow taken 3 months after the surgery. The anterior-posterior view (a) and lateral view (b). The ulnar prosthesis was inserted into the radius. A bone union was found between the proximal ulna and radius. (c and d) Body images taken 3 months after the operation, the patient had a good range of motion compared with the normal side.

the operation. A temporary ulnar neuritis with numbness in the lateral two fingers was experienced; however, symptoms had subsided 1 year after the operation.

A 48-year-old male had an open elbow fracture due to a car accident in 2013 (case 4). An external fixator was temporarily used for 2 months. The patient received an open reduction and internal fixation with an autograft from the iliac crest. However, loosening of the internal fixation occurred 2 months later with screw malposition. When the patient came to us, he had a decreased ROM (flexion to extension: 45–120°) and local tenderness. We performed TEA and released the elbow joint, but aseptic loosening was found 3 months later. Due to a massive bone defect in the proximal ulna, we performed TEA revision surgery

and inserted an ulnar prosthesis into the radius. The patient regained the same ROM as experienced preoperation, and no complications, such as ulnar neuritis or triceps weakness, were found.

DISCUSSION

The long-term survival rate of elbow arthroplasty is still lower than that for hip or knee arthroplasty,^[12] and almost half of the patients need revision surgery within 10 years.^[13] Bone defects are a critical problem in arthroplasty because both humerus and ulna are smaller than the femur and tibia. Furthermore, less bone storage exists in the ulna, thus making it more difficult to stabilize the prosthesis during revision surgery. Several methods have been suggested for patients with a massive bone defect, including an allograft-prosthesis composite, autograft from the iliac crest, arthrodesis, resection arthroplasty, and Ilizarov frame,^[7,9,11,14,15] however, none of these methods is completely satisfactory. The three methods for reconstruction using allograft-prosthesis composite, all have complex steps; thus, patients suffer from a high complication rate as well as risk for nonunion in the long-term.^[16] The intricate surgery and large volume of the implant also increase infection rate, especially for patients with a periprosthetic infection. Simple procedures such as arthrodesis and resection arthroplasty are safe and quick; however, they are destructive solutions, with patients having to lose complete elbow function.

Inserting the ulnar prosthesis into the radius is a novel method for the reconstruction of an artificial elbow joint. The indication for this surgery includes: (1) massive bone loss in the proximal ulna, thus requiring a revision surgery; (2) the radius is relatively intact with good bone stock; and (3) the patient wants to regain flexion and extension of the elbow joint at the expense of sacrificing forearm rotation. The contraindications include active infection, joint neuropathy, and excessive skin scarring. The procedure is similar to the primary arthroplasty, with difference being that the operation is mainly focused on the radius instead of the ulna. The average surgical time is around 3 h (211 min). From our clinical experience, all patients could regain flexion and extension ROM of the elbow postoperation. During follow-up, no complications such as periprosthetic infection or loosening recurred, which is greatly improved compared with a previous report.^[17] Furthermore, for patients who underwent numerous prior surgeries (eight times at most), no soft tissue-related complications, including wound infection or skin necrosis, occurred. During the last follow-up session, all patients reported having a painless functional elbow joint. Thus, in our experience, this surgery has proven to be a safer, rapid, and less invasive method for patients with a massive bone defect compared with other methods.

There are several surgical considerations and techniques involved in inserting the ulnar prosthesis into the radius as outlined in the following: (1) surgery is indicated for patients who have had several surgeries in the past, leaving a massive bone defect in the proximal ulna, to which the prosthesis is

unable to fix, and a poor soft-tissue condition such that the prosthesis is barely covered. Therefore, this method should be provided to patients as a salvage procedure, not as the first choice for revision surgery. (2) The XS size for the ulnar prosthesis of the contrary side must be chosen as this shape and size just fit the radius medullary cavity, and usually does not require further bending. Size is not a problem in the Chinese population, because even in the primary TEA, most patients can only receive an XS or smaller.^[3,6] (3) Given that the radius is connected to the elbow for improved extension and flexion, the rotation function of the radius is sacrificed. We usually put the forearm in the neutral position. No obvious functional disability has been reported as most of the patients already had a stiff elbow before the operation. (4) Due to the loss of an anatomical landmark, the insertion depth is not reliable. We prefer inserting the prosthesis fitting and trying to move the elbow to feel the tension, which requires surgeons with sufficient experience in primary TEA.

Periprosthetic infection is difficult to eradicate, especially in the elbow joint. A deep infection is insidious and could happen 1 year after the operation.^[18] Although surgeries such as cemented arthrodesis have been reported,^[19] a two-stage revision is the most popular treatment for an infected TEA, with 26 out of 33 (76%) patients who underwent a two-stage revision reported to have successfully recovered from infection.^[20] These results are consistent with the current study as no infections recurred after the two-stage surgery. For patients with a massive bone defect in the proximal ulna, arthrodesis appears to be another possible solution; however, the outcome has been poor, and elbow function is lost and cannot be compensated through shoulder motion.^[21] A study on the complications of arthrodesis showed that the infection rate of revision TEA is twice that of a primary TEA.^[22] Wound problems are another common complication after arthroplasty,^[23] with a reported rate as high as 5.5%. Furthermore, 27% of delayed healing or wound hematoma progresses into a deep infection.

Compared with other methods for dealing with a massive bone defect, this novel surgery is much safer. It could, to the greatest extent possible, preserve soft tissue and avoid infection. Because these patients have already had several surgeries, there was very little healthy skin and soft tissue left. Inserting a large prosthesis in a relatively small volume of soft tissue has a high risk of infection, especially for patients with a prior periprosthetic infection. From the past experience, the most common complication of an allograft-prosthesis surgery is reinfection.^[16] Our surgical method involves less soft-tissue trauma, is simpler procedure requiring less surgery time, and the bone marrow cavity of the radius is theoretically a completely clean environment, which could prevent periprosthetic infection after the operation.

There are several drawbacks associated with our surgical method. Loss of pronation and supination is the most obvious drawback. However, this does not cause many complaints

as most patients have already lost forearm rotation due to a stiffened elbow before the operation. Furthermore, a well-functioning shoulder can compensate for part of the loss in forearm rotation. Another issue concerning our surgical method is that it is not an anatomical reconstruction. The radius is smaller than the ulna proximally and is mainly worked during forearm rotation. After we insert the prosthesis into the radius, it becomes a part of the flexion and extension mechanism, which will bring extra abnormal stress. In our current study, no aseptic loosening or periprosthetic fractures were found; however, the relative short follow-up may have contributed to this finding. On the other hand, patients were told to strictly restrict forearm weight-bearing, decreasing stress on the radius. Finally, our surgical method is still a salvage procedure for patients unable to receive the standard revision TEA and a longer follow-up is needed.

In conclusion, inserting an ulnar prosthesis into the radius is a new method for TEA revision surgery. It is indicated for patients with a massive bone defect in the proximal ulna due to infection or aseptic loosening. Although patients lose forearm rotation, all have regained painless and functional elbows as assessed in the short-term. This surgical method should be considered a salvage procedure for patients with a nonreconstructable ulnar bone defect.

Declaration of patient consent

The authors certify that they have obtained all appropriate patient consent forms. In the form the patient(s) has/have given his/her/their consent for his/her/their images and other clinical information to be reported in the journal. The patients understand that their names and initials will not be published and due efforts will be made to conceal their identity, but anonymity cannot be guaranteed.

Financial support and sponsorship

This work was supported by the Ministry of Health Special Fund for Scientific Research in the Public Interest: Efficacy and Safety Evaluation of Novel Clinical Technique: Efficacy and Safety of Arthroplasty (No. 201302007).

Conflicts of interest

There are no conflicts of interest.

REFERENCES

- Mansat P, Nouaille Degorce H, Bonnevalle N, Demezon H, Fabre T, SOFCOT. Total elbow arthroplasty for acute distal humeral fractures in patients over 65 years old – Results of a multicenter study in 87 patients. *Orthop Traumatol Surg Res* 2013;99:779-84. doi: 10.1016/j.otsr.2013.08.003.
- Day JS, Lau E, Ong KL, Williams GR, Ramsey ML, Kurtz SM. Prevalence and projections of total shoulder and elbow arthroplasty in the United States to 2015. *J Shoulder Elbow Surg* 2010;19:1115-20. doi: 10.1016/j.jse.2010.02.009.
- Huang C, Jiang XY, Wang MY. Double plate fixation vs. total elbow arthroplasty in treating type C elderly distal humeral intercondylar fracture, early clinical outcome comparison. *Chin J Orthop* 2011;31:243-8. doi: 10.3760/cma.j.issn.0253-2352.2011.03.009.
- Toulemonde J, Ancelin D, Azoulay V, Bonnevalle N, Rongières M, Mansat P. Complications and revisions after semi-constrained total

- elbow arthroplasty: A mono-centre analysis of one hundred cases. *Int Orthop* 2016;40:73-80. doi: 10.1007/s00264-015-3008-z.
- Achermann Y, Vogt M, Spormann C, Kolling C, Remschmidt C, Wüst J, *et al.* Characteristics and outcome of 27 elbow periprosthetic joint infections: Results from a 14-year cohort study of 358 elbow prostheses. *Clin Microbiol Infect* 2011;17:432-8. doi: 10.1111/j.1469-0691.2010.03243.x.
- Jiang JL, Gong MQ, Zha YJ, Liu XH, Li T, Zhang LD, *et al.* Evaluation of total elbow arthroplasty in treatment of distal humeral fracture in the elderly. *Natl Med J China* 2015;95:3848-51. doi: 10.3760/cma.j.issn.0376-2491.2015.47.011.
- Kamini S, Morrey BF. Proximal ulnar reconstruction with strut allograft in revision total elbow arthroplasty. *J Bone Joint Surg Am* 2004;86-A:1223-9.
- Bicknell RT, Hughes JS. A new technique for management of ulnar bone loss in revision total elbow arthroplasty using a tubularized tricortical iliac crest autograft: A case report. *J Shoulder Elbow Surg* 2008;17:e15-8. doi: 10.1016/j.jse.2007.11.019.
- Otto RJ, Mulieri PJ, Cottrell BJ, Mighell MA. Arthrodesis for failed total elbow arthroplasty with deep infection. *J Shoulder Elbow Surg* 2014;23:302-7. doi: 10.1016/j.jse.2013.11.007.
- Zarkadas PC, Cass B, Throckmorton T, Adams R, Sanchez-Sotelo J, Morrey BF. Long-term outcome of resection arthroplasty for the failed total elbow arthroplasty. *J Bone Joint Surg Am* 2010;92:2576-82. doi: 10.2106/JBJS.I.00577.
- Mansat P, Adams RA, Morrey BF. Allograft-prosthesis composite for revision of catastrophic failure of total elbow arthroplasty. *J Bone Joint Surg Am* 2004;86-A:724-35.
- Krenek L, Farnig E, Zingmond D, SooHoo NF. Complication and revision rates following total elbow arthroplasty. *J Hand Surg Am* 2011;36:68-73. doi: 10.1016/j.jhsa.2010.09.036.
- Prasad N, Ali A, Stanley D. Total elbow arthroplasty for non-rheumatoid patients with a fracture of the distal humerus: A minimum ten-year follow-up. *Bone Joint J* 2016;98-B: 381-6. doi: 10.1302/0301-620X.98B3.35508.
- Rhee YG, Cho NS, Park JG, Song JH. Resection arthroplasty for periprosthetic infection after total elbow arthroplasty. *J Shoulder Elbow Surg* 2016;25:105-11. doi: 10.1016/j.jse.2015.08.045
- Sala F, Catagni M, Pili D, Capitani P. Elbow arthrodesis for post-traumatic sequelae: Surgical tactics using the Ilizarov frame. *J Shoulder Elbow Surg* 2015;24:1757-63. doi: 10.1016/j.jse.2015.07.030.
- Morrey ME, Sanchez-Sotelo J, Abdel MP, Morrey BF. Allograft-prosthetic composite reconstruction for massive bone loss including catastrophic failure in total elbow arthroplasty. *J Bone Joint Surg Am* 2013;95:1117-24. doi: 10.2106/JBJS.L.00747
- Shi LL, Zurakowski D, Jones DG, Koris MJ, Thornhill TS. Semiconstrained primary and revision total elbow arthroplasty with use of the Coonrad-Morrey prosthesis. *J Bone Joint Surg Am* 2007;89:1467-75. doi: 10.2106/JBJS.F.00715.
- Somerson JS, Morrey ME, Sanchez-Sotelo J, Morrey BF. Diagnosis and management of periprosthetic elbow infection. *J Bone Joint Surg Am* 2015;97:1962-71. doi: 10.2106/JBJS.O.00170.
- Lui TH. Infected total elbow arthroplasty treated by cemented arthrodesis. *BMJ Case Rep* 2014;2014. doi: 10.1136/bcr-2013-203481.
- Peach CA, Nicoletti S, Lawrence TM, Stanley D. Two-stage revision for the treatment of the infected total elbow arthroplasty. *Bone Joint J* 2013;95-B: 1681-6. doi: 10.1302/0301-620X.95B12.31336.
- O'Neill OR, Morrey BF, Tanaka S, An KN. Compensatory motion in the upper extremity after elbow arthrodesis. *Clin Orthop Relat Res* 1992;281:89-96.
- Lovy AJ, Keswani A, Dowdell J, Koehler S, Kim J, Hausman MR. Outcomes, complications, utilization trends, and risk factors for primary and revision total elbow replacement. *J Shoulder Elbow Surg* 2016;25:1020-6. doi: 10.1016/j.jse.2015.12.012.
- Jeon IH, Morrey BF, Anakwenze OA, Tran NV. Incidence and implications of early postoperative wound complications after total elbow arthroplasty. *J Shoulder Elbow Surg* 2011;20:857-65. doi: 10.1016/j.jse.2011.03.005.