

Pneumocephalus and Pneumorrhachis after Spinal Surgery: Case Report and Review of the Literature

Ergun KARAVELIOGLU,¹ Olcay ESER,² and Alpay HAKTANIR³

Departments of ¹Neurosurgery and ³Radiology, Afyon Kocatepe University, School of Medicine, Afyonkarahisar, Turkey;

²Department of Neurosurgery, Balikesir University, School of Medicine, Balikesir, Turkey

Abstract

Trauma is a common cause of pneumocephalus, or air in the cranial cavity, and of pneumorrhachis, or the presence of intraspinal air. After spinal surgery, occurrence of pneumocephalus, especially with pneumorrhachis, is extremely rare. We report the case of a patient who developed pneumocephalus and pneumorrhachis after lumbar disc surgery and pedicle screw fixation. There was no cerebrospinal fluid leakage during surgery. On postoperative day 1, the patient complained of headache, nausea, and dizziness. Brain and lumbar computed tomography scans revealed pneumocephalus and pneumorrhachis. With conservative treatment, the patient's complaints resolved within 10 days.

Key words: pneumocephalus, pneumorrhachis, spinal surgery

Introduction

Pneumorrhachis, or air in the spinal canal, and pneumocephalus, or air in the cranial cavity, are very rare and unusual conditions. The term pneumorrhachis was first used by Newbold to define the condition in their patient who had air in the subarachnoid space at the cervical level.¹⁾ Pneumorrhachis is usually asymptomatic, and the diagnosis is primarily radiologic. Pneumorrhachis is always seen after trauma and iatrogenic manipulations.^{2,3)} Wollf et al. first used the term pneumocephalus in 1914.⁴⁾ Various conditions can cause pneumocephalus.

After a spinal operation, the occurrence of pneumorrhachis, pneumocephalus, or both is very rare. We present an unusual case of development of pneumocephalus and pneumorrhachis after spinal surgery.

Case

A 56-year-old man was admitted with a 4-year history of low back pain and bilateral radicular pain. At admission, he complained of motor weakness in his right foot. The patient had no significant medical history. A neurological examination revealed a positive straight-leg-raising sign in both legs, hypoesthesia in the right L4 and left L5–S1 dermatomes, decreased motor strength during ankle dorsiflexion (2/5), and reduced left and right ankle reflexes. Furthermore, he

had neurological claudication after walking 100 m. Magnetic resonance imaging (MRI) of the lumbar spine showed a giant, inferiorly migrated, sequestered disc fragment at the right L3–4 level and a disc herniation at the left L4–5 and left L5–S1 levels (Fig. 1). The patient underwent surgery for right L3, left L4, and left L5 hemilaminectomy and discectomy. The patient was on prone position and the head was flat. A giant, sequestered disc fragment was removed from the right L3 level. The fragment was so huge and big that medial facetectomy was done. Pedicle screws were placed bilaterally in the L3, L4, and L5 pedicles. A suction drain was placed into the surgical area. There was no leakage of cerebrospinal fluid (CSF) during surgery.

On postoperative day 1, his motor strength during ankle dorsiflexion had recovered (4/5), but the patient began to complain of a severe headache, nausea, and dizziness. Cranial computed tomography (CT) revealed pneumocephalus involving the suprasellar and basal cisterns (Fig. 2). Additionally, lumbar CT revealed pneumorrhachis at the L4 level (Fig. 3). There was no leakage of CSF from the suction drain. The patient was successfully managed conservatively with 100% oxygen, bed rest, hydration, analgesics, and close monitoring. On the tenth postoperative day, the patient was discharged with no neurological deficits or pain.

Discussion

Pneumocephalus can be localized in the subdural, subarachnoid, epidural, intraventricular, and intraparenchymal spaces.³⁾

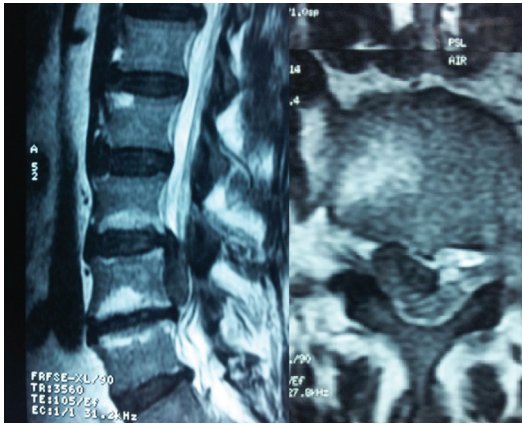

Fig. 1 Lumbar magnetic resonance imaging shows a giant, inferiorly migrated, sequestered disc fragment at the right L3-4 level.

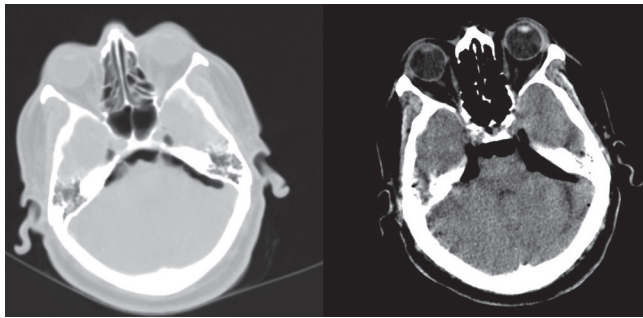


Fig. 2 Air densities are seen anterior to the brain stem and Meckel cave cisterns simulating an air cisternogram with discernible trigeminal nerves in the lung window settings. Air can be seen also in brain window settings.

The most common causes of pneumocephalus are trauma, neoplasm, infection, and diagnostic and therapeutic procedures, such as lumbar puncture or surgical intervention.⁵⁾ Pneumocephalus usually occurs after fracture of the skull base, temporal bone, or paranasal sinus. Spontaneous pneumocephalus has also been observed after anesthetic intervention. Spinal causes of pneumocephalus during spinal surgeries are very rare. Spinal surgeons are faced with an increasing number of CSF leakages due to recent advances in spinal instrumentation. However, the incidence of dural tears during spinal surgeries ranges from 0.3% to 5.9%, and dural tears that occur during spinal surgeries do not usually cause pneumocephalus, pneumorrhachis, or both.⁶⁾ A CSF leakage can cause meningitis, arachnoiditis, epidural abscess, pneumocephalus, or dural fistula. A literature review revealed six cases of symptomatic pneumocephali secondary to spinal surgeries (Table 1).³⁻⁸⁾

Two theories have been used to describe the pathophysiology of pneumocephalus: the inverted bottle mechanism and the ball-valve mechanism.⁶⁾ In the inverted bottle

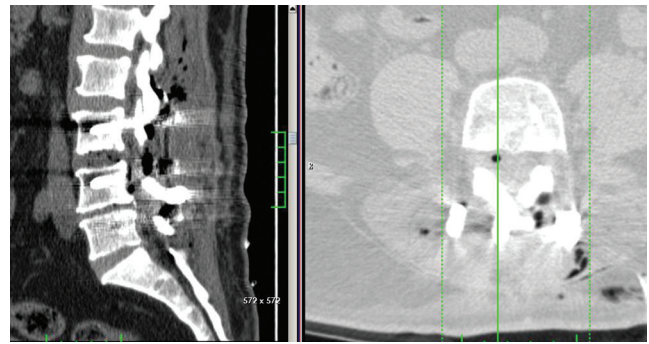


Fig. 3 Sagittal reformation of the postoperative lumbar computed tomography in soft tissue window (left) and transverse cut from the L4 level at lung window (right) showing air densities in L3-4 intervertebral space, anterior-right to the dural sac, and in the posterior extradural regions.

mechanism, it is postulated that as CSF flows out of the subarachnoid space through a dural-arachnoid tear, negative pressure is created within the subarachnoid space. The negative pressure prevents the leakage of more CSF, until air enters to take its place and equilibrates the pressure differential. In the second theory, the ball-valve mechanism hypothesizes that air enters through a fracture next to an air-containing space.⁶⁾ A vacuum drainage system predisposes a patient to a pneumocephalus in the presence of a CSF leakage.^{4,6)} Ayberk et al. reported a symptomatic pneumocephalus case after a spinal fusion that did not involve dural tears.⁵⁾ They concluded that increased intra-abdominal pressure due to the prone position may have caused the tension pneumocephalus. In our case, we postulate that the end of the giant, inferiorly migrated, sequestered, and calcified disc fragment may have been located intradurally and tear the arachnoid at the axilla of the root sleeve; therefore, as we removed the disc fragment, a dural and arachnoid tear occurred at the anterior part of the spinal cord. Then air flowed into subarachnoid space from its injury point. Axillary perineurium laceration of root sleeve was check-valve therefore it allows air to enter but not exit the spinal cavity. The pneumorrhachis at the L4 level, as visualized on postoperative lumbar CT, supports this opinion. Furthermore, the suction drain may have predisposed the patient to develop pneumocephalus and pneumorrhachis by the inverted bottle mechanism.

Symptoms of pneumocephalus are mostly nonspecific. The most clinically apparent sign of a pneumocephalus is headache. The other clinical signs are nausea, vomiting, dizziness, lethargy, and consciousness. The nonspecific complaints of these clinical symptoms by patients who have just undergone general anesthesia are mostly considered to be insignificant. Spinal surgeons should be more aware of the potential for patients to develop pneumocephalus

Table 1 Previous cases

	A	S	Surgery	Dural tear	Drain	Symptoms	Treatment
Ozturk et al. ⁶⁾	23	F	Pedicule screw placement for thoracolumbar scoliosis	+	+	Headache, nausea, and deterioration	Conservative
Turgut and Akyüz ⁴⁾	47	M	L4 right hemilaminectomy and disectomy	+	+	Headache, photophobia	Conservative
Yun et al. ³⁾	59	M	L4 subtotal laminectomy and L5 total laminectomy with pedicle screw fixation	+	–	Headache, dizziness, psychological depression	Conservative
Ayberk et al. ⁵⁾	55	F	L4 total, L3 and L5 partial laminectomy with pedicle screw fixation and intervertebral cage	–	+	Headache, nausea,	Conservative
Nowak et al. ⁸⁾	12	F	T2–T4 pedicle screw fixation	+	+	Somnolence, aphasia	Surgical
Dhamija et al. ⁷⁾	63	F	L3–L4–L5 laminectomy	+	–	Headache, confusion and disorientation	Conservative
Present case	56	M	Right L3, left L4 and L5 hemilaminectomy with pedicle screw fixation	–	+	Headache, nausea, dizziness	Conservative

A: age, S: sex.

after spinal surgeries.

CT can be used to detect as little as 0.55 mL of air in the brain and is very useful in the detection of a pneumocephalus. A plain skull radiograph can only detect as little as 2 mL of air. MRI can also be used to detect a pneumocephalus, but CT is more effective.⁶⁾

The most common causes of pneumorrhachis are trauma and iatrogenic manipulations; other rare causes include respiratory complications, malignancies, cardiopulmonary resuscitation, inhalational drug abuse, diabetic ketoacidosis-associated emesis, degenerative disc disease, and spontaneous pneumorrhachis.²⁾

From a technical viewpoint, a watertight dural closure with different surgical methods using various tissue adhesives including cyanoacrylate, albumin, collagen, and glutaraldehyde glues, minimizes the risk of this complication.⁴⁾ Also head down position lower than the operative field prevents pneumocephalus.³⁾

Currently, after a spinal surgery, no set treatment guidelines exist for pneumocephalus and pneumorrhachis. Spontaneous absorption of the air can be seen in 85% of patients with pneumocephalus.⁶⁾ The general approach is conservative, with hydration, bed rest, inhalation of 100% oxygen to increase the speed of diffusion of nitrogen, and analgesics. In the majority of patients with pneumocephalus, a conservative treatment consisting of bedrest and hyperhydration is adequate and symptoms resolve in 2–3 weeks.⁴⁾ Prophylactic treatment for meningitis must also be considered for patients with CSF leakage.

Conflicts of Interest Disclosure

The authors state that there are no conflicts of interest. All

authors disclose that there are no financial and personal relationships with other people or organizations.

References

- 1) Prabhakar H, Bithal PK, Ghosh I, Dash HH: Pneumorrhachis presenting as quadriplegia following surgery in the prone position. *Br J Anesth* 97: 901–903, 2006
- 2) Dolgun H, Gurer B, Sari O, Sekerci Z: Isolated subarachnoid pneumorrhachis. *Neurol India* 59: 139–141, 2011
- 3) Yun JH, Kim YJ, Yoo DS, Ko JH: Diffuse pneumocephalus: a rare complication of spinal surgery. *J Korean Neurosurg Soc* 48: 288–290, 2010
- 4) Turgut M, Akyüz O: Symptomatic tension pneumocephalus: an unusual post-operative complication of posterior spinal surgery. *J Clin Neurosci* 14: 666–668, 2007
- 5) Ayberk G, Yaman ME, Ozveren MF: Symptomatic spontaneous pneumocephalus after spinal fusion for spondylolisthesis. *J Clin Neurosci* 17: 934–936, 2010
- 6) Ozturk E, Kantarci M, Karaman K, Basekim CC, Kizilkaya E: Diffuse pneumocephalus associated with infratentorial and supratentorial hemorrhages as a complication of spinal surgery. *Acta Radiol* 47: 497–500, 2006
- 7) Dhamija B, Saxena A: Pneumocephalus—a possible cause of post-spinal surgery confusion. *J R Soc Med* 104: 81–83, 2011
- 8) Nowak R, Maliszewski M, Krawczyk L: Intracranial subdural hematoma and pneumocephalus after spinal instrumentation of myelodysplastic scoliosis. *J Pediatr Orthop B* 20: 41–45, 2011

Address reprint requests to: Ergun Karavelioglu, MD, Koacatepe University, İzmir Road 8.Km, Afyonkarahisar, Turkey.
e-mail: ergunkara@hotmail.com