

Original Article



OPEN ACCESS

Received: Oct 17, 2021

Revised: Feb 12, 2022

Accepted: Feb 13, 2022

Published online: Mar 2, 2022

Address for Correspondence:

Edward Araujo Júnior, PhD


Department of Obstetrics, Paulista School of Medicine, Federal University of São Paulo (EPM-UNIFESP), Rua Belchior de Azevedo, 156 apto. 111 Torre Vitoria, São Paulo 05089-030, Brazil.


Email: araujojred@terra.com.br


Copyright © 2022 Korean Society of Echocardiography


This is an Open Access article distributed under the terms of the Creative Commons Attribution Non-Commercial License (<https://creativecommons.org/licenses/by-nc/4.0/>) which permits unrestricted non-commercial use, distribution, and reproduction in any medium, provided the original work is properly cited.

ORCID iDs

Nathalie Jeanne Bravo-Valenzuela 
<https://orcid.org/0000-0003-1491-4877>

Alberto Borges Peixoto 
<https://orcid.org/0000-0002-1655-3609>

Rosiane Mattar 
<https://orcid.org/0000-0003-1405-5371>

Edward Araujo Júnior 
<https://orcid.org/0000-0002-6145-2532>

Conflict of Interest

The authors have no financial conflicts of interest.

<https://e-jcvi.org>

Fetal Interventricular Septum Volume Evaluated by Three-Dimensional Ultrasound Using Spatiotemporal Image Correlation and Virtual Organ Computer-Aided Analysis in Fetuses From Pre-Gestational Diabetes Mellitus Pregnant Women

Nathalie Jeanne Bravo-Valenzuela  PhD¹, Alberto Borges Peixoto  PhD^{2,3}, Rosiane Mattar  PhD⁴, and Edward Araujo Júnior  PhD⁴

¹Department of Pediatrics, Pediatric Cardiology, School of Medicine, Federal University of Rio de Janeiro (UFRJ), Rio de Janeiro, Brazil

²Department of Obstetrics and Gynecology, Federal University of Triângulo Mineiro (UFTM), Uberaba, Brazil

³Gynecology and Obstetrics Service, Mario Palmério University Hospital, University of Uberaba (UNIUBE), Uberaba, Brazil

⁴Department of Obstetrics, Paulista School of Medicine, Federal University of São Paulo (EPM-UNIFESP), São Paulo, Brazil

ABSTRACT

BACKGROUND: To assess the interventricular septum (IVS) volume of fetuses from pre-gestational diabetes mellitus (DM) pregnant women by 3-dimensional ultrasound using spatiotemporal image correlation (STIC) and virtual organ computer-aided analysis (VOCAL) methods.

METHODS: This was a prospective cross-sectional study of 45 fetuses from pre-gestational DM and 45 fetuses from healthy pregnant women (controls). Only singleton pregnancies between 20 and 34 + 6 weeks of gestation were included. The fetal IVS volumes were obtained off-line using STIC and VOCAL methods. To analyze differences among variables, the Student's t-test and Mann-Whitney U test were used. The correlation among continuous variables was determined using Spearman's correlation test (r).

RESULTS: The median of fetal IVS volume was significantly higher in pre-gestational DM than in healthy pregnant women (0.3 cm^3 vs. 0.2 cm^3 , $p = 0.032$). A strong positive correlation was observed between fetal IVS volume and gestational age at the time of ultrasound examination ($r = 0.75$, $R^2 = 0.48$, $p < 0.0001$) and between fetal IVS volume and estimated fetal weight ($r = 0.63$, $R^2 = 0.37$, $p < 0.0001$). No significant correlation was noted between fetal IVS volume and glycated hemoglobin levels ($r = -0.16$, $R^2 = 0.01$, $p = 0.540$) in the pre-gestational DM pregnant women.

CONCLUSIONS: Significant differences were observed in fetal IVS volumes between pre-gestational and healthy mothers, with higher values in the fetuses of pre-gestational DM pregnant women.

Keywords: Fetus; Heart; Cardiac septum; Diabetes mellitus; Three-dimensional image

Author Contributions

Conceptualization: Araujo Júnior E; Data curation: Bravo-Valenzuela NJ; Formal analysis: Peixoto AB; Investigation: Bravo-Valenzuela NJ; Project administration: Mattar R; Validation: Peixoto AB; Writing - review & editing: Araujo Júnior E.

INTRODUCTION

Diabetes mellitus (DM) is a health problem that affects 1 (16.8%) in 6 of all pregnancies worldwide; however, its prevalence may vary depending on the population characteristics and diagnostic criteria. Pregnant women with DM and their fetuses are exposed to long-term consequences with transgenerational effects such as children with a higher risk of obesity and its related complications.¹⁾

Furthermore, DM is associated with fetal cardiac defects and a higher risk of stillbirth. A wide variety of factors can result to this adverse outcome. Fetal cardiomyopathy is reported to be an important etiology of intrauterine fetal demise due to the findings on fetal autopsy examinations in DM, compared with controls.²⁾ A great variety of studies have demonstrated the prevalence of myocardial hypertrophy in fetuses of mothers with DM in comparison to non-DM pregnancies presenting a risk of heart failure *in utero*.³⁻⁵⁾

Classically, myocardial thickness can be assessed by the measurements of ventricular walls and interventricular septum (IVS) using M-mode and a 2-dimensional (2D) ultrasound. Reference ranges of fetal interventricular thickness in low-risk population using the 2D ultrasound have been published. The reference ranges have enabled important assessments for conditions at risk of myocardial hypertrophy such as DM.^{6,7)} In addition to the reference ranges for the IVS expressed in percentiles, reference ranges in Z-scores were also published.⁸⁾

However, the 2D technique may have limited sensitivity, especially for mild cases. The 3-dimensional (3D) ultrasound with spatiotemporal image correlation (STIC) and virtual organ computer-aided analysis (VOCAL) methods allows a better identification of the fetal heart ventricular wall edges. Studies demonstrate that 3D ultrasound provides more accurate measurements of the fetal IVS thickness which may enable earlier diagnosis of myocardial hypertrophy.^{9,10)} Reference ranges for fetal IVS volumes in low-risk pregnant women were obtained using 3D ultrasound with STIC and VOCAL methods, which could enable early diagnosis of myocardial hypertrophy.¹¹⁾ However, to the best of our knowledge, no studies have evaluated the fetal IVS volumes in pre-gestational DM mothers.

Therefore, this study aimed to evaluate the fetal IVS volumes in pre-gestational DM and healthy pregnant women using 3D ultrasound with STIC and VOCAL methods.

METHODS

We conducted a prospective cross-sectional study to assess fetal IVS volumes using 3D ultrasound with STIC and VOCAL methods in the fetuses of pre-gestational DM and healthy pregnant women with a gestational age ranging from 20 to 34 + 6 weeks of gestation. The study protocol was approved by the Research Ethics Committee of the Federal University of São Paulo (UNIFESP), (CAE: 87111116.4.0000.5505). On October 2016 and July 2019, pregnant women were recruited from the Diabetes Sector of the Department of Obstetrics at the UNIFESP in São Paulo-SP, Brazil. Consent forms were obtained from all the participants.

The data was divided into 2 groups, i.e., pre-gestational DM, and controls. The first group comprised fetuses of pregnant women with pre-gestational DM (types 1, 2 or MODY—Maturity-Onset Diabetes of the Young), and the second group comprised normal fetuses

from healthy mothers. The inclusion criterion was singleton pregnancies with gestational age being between 20 and 34 + 6 weeks of gestation. The gestational age was based on the last menstrual period and confirmed by an ultrasound examination performed in the first trimester using the crown-rump length measurement. The exclusion criteria incorporated fetuses whose mothers had other comorbidities besides pre-gestational DM, fetuses with cardiac, extra cardiac anomalies or chromosomal abnormalities, an estimated fetal weight (EFW) of less than 10% for the gestational age and 3D fetal cardiac volumes of inadequate quality i.e. fetal movements, acoustic shadows and mother breathing.

All pregnant women included in this study were examined once using the Voluson E8 apparatus (General Electric Medical System, Zipf, Austria) with a convex (3.5–7.0 MHz) and volumetric (RAB 4-8 L) probes. Fetal echocardiograms were performed along with the ultrasound examinations which included the morphology, amniotic fluid assessment and fetal biometry. All fetal echocardiograms were performed by one specialist in perinatal cardiology with expertise in 3D ultrasound. Initially, a systematic evaluation of the fetal heart using 2D ultrasound with color Doppler had been obtained in all patients. Subsequently, the 3D cardiac volumes were acquired at the 4-chamber view level, using the STIC method. The 3D cardiac volumes were obtained during fetal rest and maternal apnea, according to the 3D scan acquisition standard, proposed by Gonçalves et al.¹²⁾ The following parameters were evaluated: speed time ranging from 7.5 to 15 seconds and an open angle ranging from 20° to 25° and 35° to 40° in the second and third trimesters, respectively. From each examination, three 3D cardiac volumes were obtained and stored, according to the method proposed by Paladini.¹³⁾ Previously, only one of three 3D cardiac volumes was selected by a single examiner to be analyzed off-line using maximum quality 3D images.

The axial plane of the multiplanar mode (plane A) was selected to perform the off-line measurements of the fetal IVS using the 4D view version 10.0 (General Electric Medical System). Sequentially, the cinelop mode reduced the velocity to 6% and retrieved it to obtain the IVS at the ventricular end of both ventricles (identified by the larger ventricular lumen). Sepia color selection and gamma curve adjustments were made to obtain the best contrast between the edges of the inner walls of the ventricles and their internal content. The 3D cardiac volume was rotated around the “z” axis to position the apex of the fetal heart to 12 o'clock. The caliper was positioned on the inner side of the atrioventricular valves (crux of the heart) and on the mid-point of the fetal heart apex, being respectively defined as the upper and the lower border of fetal IVS. The VOCAL button was activated, and the calipers were positioned to the upper and lower borders of the fetal IVS. Sequentially, 6 sequential planes at a 30° rotation were manually delimited. After the final plan, the software provided the fetal IVS volume at the end of the ventricular diastole (**Figure 1**).

These clinical variables were collected; maternal age, number of previous pregnancies, parity, miscarriage, gestational age at the time of the ultrasound examination, EFW, and the fetal heart rate. Glycated hemoglobin (HbA1c) level was obtained from pre-gestational DM pregnant women during the first trimester.

A power analysis was performed to calculate the sample size on the basis of the Cohen effect of 0,5 to achieve a power of 80% and an alpha of 5% to detect the differences in the evaluated parameters. Using the software G 3.1, the results suggested a sample size of 44 fetuses from each group. The data were stored in an Excel spreadsheet 2010 (Microsoft Corp., Redmond, WA, USA) using the Prisma Graph Pad version 7.0 (Graph Pad Software, San Diego, CA, USA).

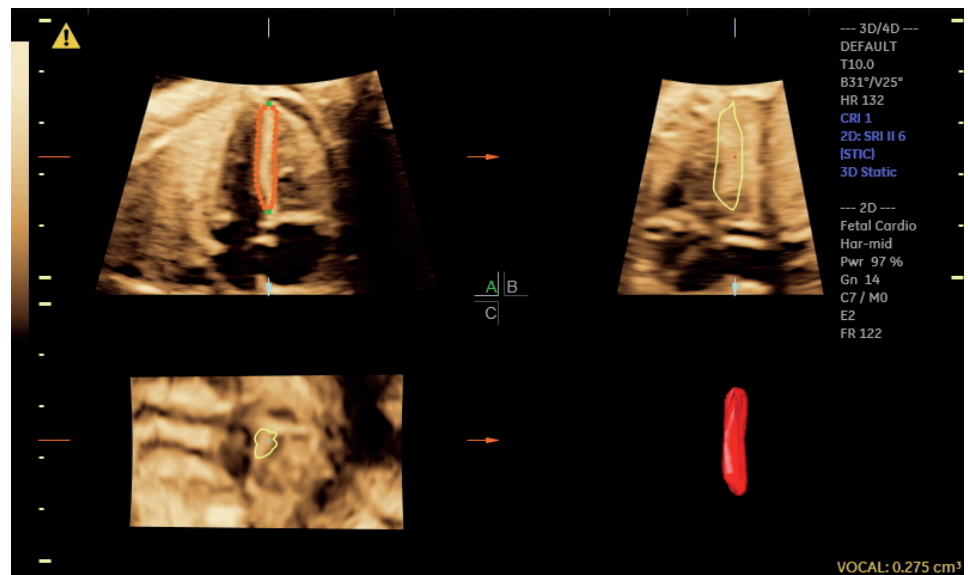


Figure 1. Fetal IVS volume using STIC and VOCAL methods in the fetus of a pregnant woman with pre-gestational diabetes mellitus at 29 + 5 weeks of gestation. Fetal IVS volume was obtained from the end-diastole and was determined based on the maximum diameter of the ventricles. The calipers were positioned on the inner side of the atrioventricular valves (crux of the heart) and on the fetal heart's apex mid-point of the, being respectively defined as the IVS upper and lower borders. After 6 sequential planes, the VOCAL methods provided the fetal IVS volume and the reconstructed 3D image.

D: dimensional, HR: heart rate, IVS: interventricular septum, STIC: spatiotemporal image correlation, VOCAL: virtual organ computer-aided analysis.

The quantitative variables were initially subjected to the D'Agostino & Pearson normality test. The parametric distribution variables were presented from the mean and standard deviations. The nonparametric distribution variables were presented from the median, minimum and maximum values. To assess the difference between variables, the Student's t-test and Mann-Whitney U test were used. To analyze the correlation between continuous variables, Spearman's correlation test (r) was used. The level of significance being (p) < 0.05.

RESULTS

Ninety-five singleton pregnancies were eligible, however five of them were excluded due to a poor quality of the 3D cardiac volume acquisition. Finally, 45 pre-gestational DM and 45 healthy mothers were included. There was significant effect of pre-gestational DM on maternal age ($p = 0.0195$), number of pregnancies ($p < 0.0001$), number of deliveries ($p = 0.0032$), number of miscarriages ($p = 0.0009$) and fetal IVS volume ($p = 0.0032$). Mean maternal age was significantly lower in patients with pre-gestational DM compared with controls (28.7 vs. 32 years, respectively). Pre-gestational DM pregnant women had significantly higher median number of pregnancies compared with controls. The number of pregnancies were 2.0 vs. 1.0, respectively, whereas the number of deliveries were 1.0 vs. 0.0, respectively. Significant differences were noted in fetal IVS volumes of pre-gestational DM compared with healthy mothers. The median value of the fetal IVS volume was significantly higher in pre-gestational DM than in controls (0.3 cm^3 vs. 0.2 cm^3). The clinical and ultrasonographic characteristics of the study population are described in **Table 1**. The equations for the fetal IVS volume according to the gestational age at the time of ultrasound examination, EFW, and HbA1 levels are shown in **Table 2** and **Figure 2**.

Table 1. Clinical and ultrasonographic characteristics of the studied population

Maternal and ultrasonographic characteristics	Healthy (n = 45)				Pre-gestational diabetes mellitus (n = 45)				p-value
	Median	Min	Max	Mean ± SD	Median	Min	Max	Mean ± SD	
Age (years)	33.0	19.0	43.0	32.0 ± 6.3	28.0	17.0	43.0	28.7 ± 6.6	0.0195*
Gestation	1.0	1.0	4.0	1.4 ± 0.8	2.0	1.0	6.0	2.5 ± 1.4	< 0.0001†
Parity	0.0	0.0	3.0	0.4 ± 0.8	1.0	0.0	3.0	1.0 ± 1.1	0.0032†
Miscarriage	0.0	0.0	1.0	0.0 ± 0.2	0.0	0.0	5.0	0.6 ± 0.1	0.0009†
Gestational age (weeks)	27.1	20.0	33.5	27.3 ± 4.1	27.5	20.2	34.6	27.6 ± 4.0	0.7283†
Glycated HB (%)					7.6	4.8	15.5	8.0 ± 2.6	
EFW (g)	949.0	322.0	2,137.0	1,065.0 ± 530.0	1,143.0	333.0	2,689.0	1,230.0 ± 632.0	0.1926*
IVS (cm ³)	0.2	0.0	0.5	0.2 ± 0.1	0.3	0.1	1.0	0.3 ± 0.2	0.0032†
FHR (bpm)	142.0	121.0	160.0	142.0 ± 10.8	144.0	113.0	166.0	142.0 ± 12.4	0.9501†

EFW: estimated fetal weight, FRH: fetal heart rate, HB: hemoglobin, IVS: interventricular septum, Max: maximum, Min: minimum.

*Student t-test; †Mann-Whitney U test.

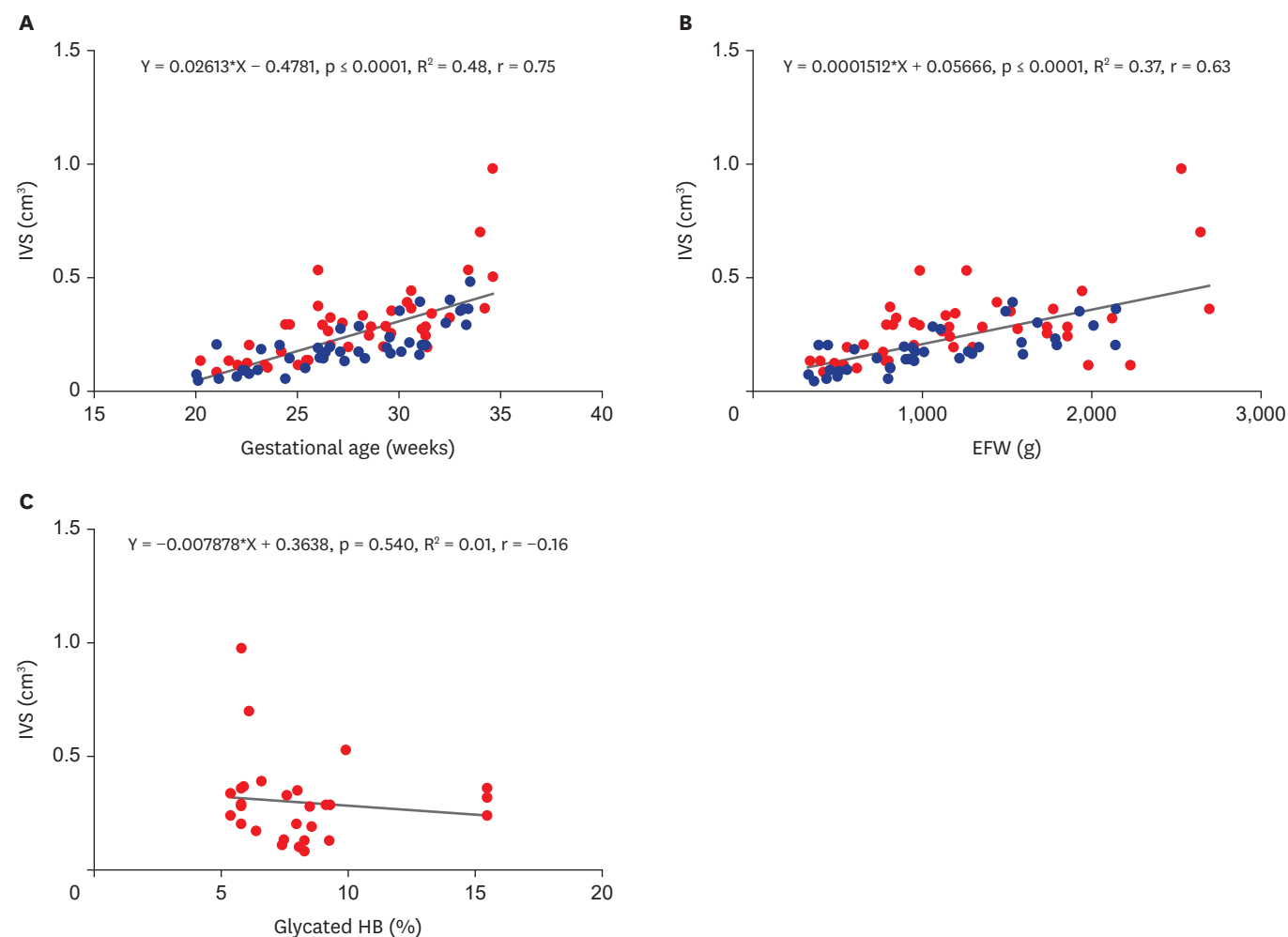


Figure 2. Correlations among fetal IVS volume, gestational age, EFW and glycated HB in healthy and pre-gestational diabetes mellitus mothers. (A) The correlation between the gestational age at the time of the ultrasound examination and fetal IVS volume in both pre-gestational diabetes mellitus (red dots) and the healthy (blue dots) mothers. (B) The correlation between EFW and fetal IVS in both pre-gestational diabetes mellitus (red dots) and healthy (blue dots) mothers. (C) The correlation between glycated hemoglobin (glycated HB) and fetal IVS among mothers with pre-gestational diabetes mellitus (red dots). Spearman's correlation test, $p < 0.05$.

EFW: estimated fetal weight, HB: hemoglobin, IVS: interventricular septum.

A strong positive correlation was observed between the fetal IVS volume and the gestational age at the time of the ultrasound examination ($r = 0.75$, $R^2 = 0.48$, $p < 0.0001$) (**Figure 2A**), and the EFW ($r = 0.63$, $R^2 = 0.37$, $p < 0.0001$) (**Figure 2B**). There was no significant correlation

Table 2. Equations for predicting fetal interventricular septum volume based on gestational age and estimated fetal weight, considering all cases included, and glycated HB value in pre-gestational diabetes mellitus pregnant women

Variables	Equation	R ²	r	p-value
Gestational age (weeks)	$Y = 0.02613 \times X - 0.4781$	0.48	0.75	< 0.0001
EFW (g)	$Y = 0.0001512 \times X + 0.05666$	0.37	0.63	< 0.0001
Glycated HB (%)	$Y = -0.007878 \times X + 0.3638$	0.01	-0.16	0.54

Spearman correlation test, $p < 0.05$.

EFW: estimated fetal weight, HB: hemoglobin.

between fetal IVS volume and HbA1 level ($r = -0.16$, $R^2 = 0.01$, $p = 0.540$) in fetuses from pre-gestational DM pregnant women (**Figure 2C**).

In controls, fetal IVS volume increased by 0.0212 cm^3 ($Y = 0.0212 \times X - 0.3838$, $p < 0.0001$, $R^2 = 0.65$, $r = 0.79$) per week. In pre-gestational DM fetuses, the one-week increase of the fetal IVS volume was by 0.0298 cm^3 ($Y = 0.0298 \times X - 0.542$, $p < 0.0001$, $R^2 = 0.48$, $r = 0.69$) (**Figure 3**). Regarding the correlation between the EFW and the fetal IVS volume, an increase in one gram of the EFW increases the fetal IVS volume by 0.00012 cm^3 ($Y = 0.00012 \times X + 0.04505$, $p < 0.0001$, $R^2 = 0.54$, $r = 0.73$) in controls and by 0.00015 cm^3 ($Y = 0.00015 \times X + 0.09542$, $p = 0.0001$, $R^2 = 0.31$, $r = 0.51$) of the fetal IVS volume in the pre-gestational DM group (**Figure 4**).

DISCUSSION

The prevalence of fetal hypertrophic cardiomyopathy, conotruncal anomalies, ventricular septal defects, and other cardiac malformations is increased in mothers with DM and is associated with higher rates of perinatal morbidity and mortality.²⁾¹⁴⁾¹⁵⁾ The hypertrophy of IVS is the most common structural cardiac anomaly in fetuses from mothers with DM, and with a deleterious risk on the fetal heart function. In this scenario, several studies have been published including ultrasound/echocardiographic fetal cardiac functional parameters by M-mode, Doppler, 2D and 3D ultrasound in the fetuses of mothers with DM.⁴⁾¹⁶⁻¹⁹⁾ Recently, a meta-analysis reviewed 39 studies on fetal IVS thickness and Doppler cardiac functional parameters focusing on analyzing the effects of DM on the fetal heart. In regard to the

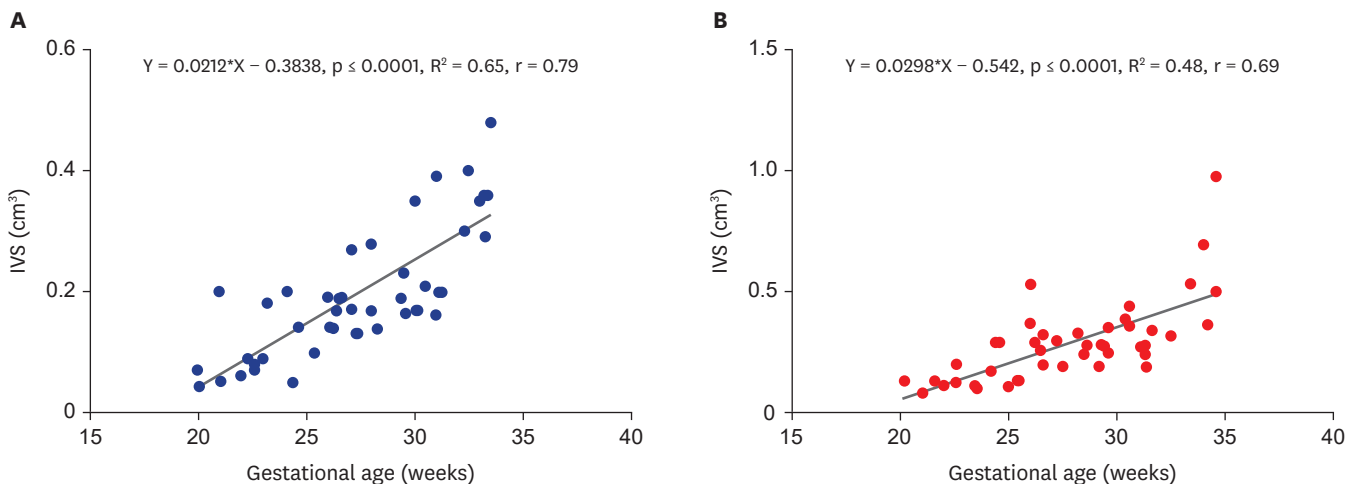


Figure 3. The correlation between the gestational age at the time of the examination and fetal IVS volume was stronger in healthy (blue dots, A) than pre-gestational diabetes mellitus mothers (red dots, B). Spearman's correlation test, $p < 0.05$. IVS: interventricular septum.

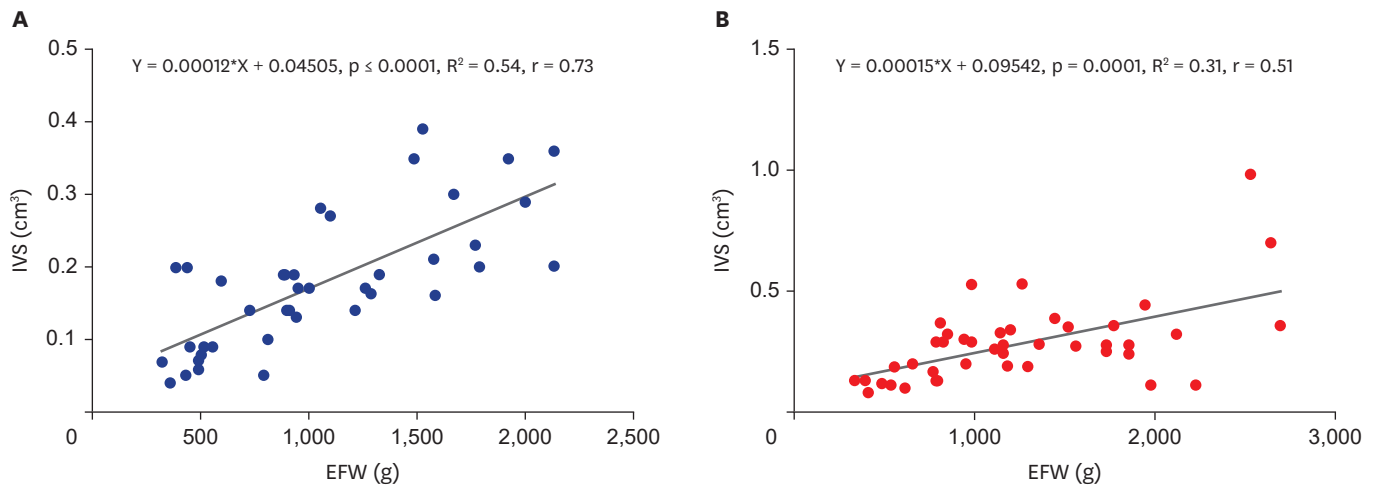


Figure 4. Correlations between fetal IVS volume and EFW in healthy and pre-gestational diabetes mellitus mothers. (A) The correlation between EFW and fetal IVS volume among healthy (blue dots). (B) The correlation between EFW and fetal IVS volume among mothers with pre-gestational diabetes mellitus (red dots). Spearman's correlation test, $p < 0.05$. EFW: estimated fetal weight, IVS: interventricular septum.

2D ultrasound and Doppler cardiac function parameters in this review, the E/A ratio was decreased in the DM group. However, no differences were observed in the myocardial performance index between DM and control groups. Moreover, fetal cardiac hypertrophy was more prevalent in pre-gestational and gestational mothers with DM than healthy mothers, mainly during the third trimester.³⁾

It has been well established that DM is associated with the fetal myocardial hypertrophy. The measurements of the fetal IVS are usually performed at the 4-chamber view using 2D ultrasound and M-mode.²⁰⁾²¹⁾ However, since the irregular shape of the fetal IVS, its measurements may be more accurately performed by a 3D ultrasound other than by a conventional 2D ultrasound. In this scenario, Rolo et al.¹¹⁾ showed that a 3D ultrasound with STIC and VOCAL methods is a reproducible strategy and offers a positive correlation between the fetal IVS volume and the gestational age. In the current study, fetal IVS volume was higher in DM group with a positive correlation between gestational age and fetal IVS volume in both groups.

Reference ranges for fetal heart atrial and ventricular walls volumes using 3D ultrasound with STIC and VOCAL methods have previously been published.²²⁾²³⁾ Bravo-Valenzuela et al.¹⁹⁾ evaluated the fetal atrial and ventricular volumes of 106 fetuses between 20 and 34 weeks of gestation by 3D ultrasound with STIC and VOCAL methods. In this study, the ventricular volumes were similar both in the DM and control groups. The left atrial volumes were significantly lower in the pregnant women with pre-gestational DM compared with controls (0.62 mL in DM vs. 0.68 mL in control, $p < 0.001$). Fetal IVS volume was not, however, assessed in this study. Recently, Melo Júnior et al.²⁴⁾ assessed the total myocardial volume of the fetal heart by 3D ultrasound with STIC and VOCAL methods and did not observe a significant difference in the mean fetal myocardial volume between mothers with pre-gestational DM and healthy mothers ($p = 0.64$).

Rolo et al.¹¹⁾ using 3D ultrasound with STIC and VOCAL methods, established reference values for the fetal IVS volume in low-risk pregnant women. The fetal IVS volume ranged from $0.13 \pm 0.03 \text{ cm}^3$ at 18 weeks to $1.33 \pm 0.37 \text{ cm}^3$ at 33 weeks and 6 days of gestation. The authors suggested that the inclusion of the assessment of the fetal IVS volume in the routine

might be useful for early detection of myocardial hypertrophy in mothers with DM. Similar to Rolo et al.,¹¹⁾ we also observed a positive correlation between fetal IVS volume and gestational age in pre-gestational DM compared to healthy pregnant women with higher mean values of fetal IVS volume in pre-gestational DM mothers.

Studies on fetal myocardial hypertrophy in gestational DM and its correlation with metabolic control have shown inconsistent results. Although, some studies have shown positive correlation between fetal IVS thickness and HbA1c, since the myocardial hypertrophy can also occur in fetuses of pregnant woman with well-controlled DM.²⁰⁾²⁵⁻²⁷⁾ As per our research, no significant correlation between the IVS volume and HbA1c levels were observed in fetuses from pregnant women with pre-gestational DM. Recently, a study about cardiac dysfunction in pregnant women with gestational and pre-gestational DM showed that increased levels of biochemical markers such as B-type natriuretic peptide and troponin I obtained through an umbilical cord sample, were associated with increased fetal myocardial thickness.²⁸⁾

The limitations of this study were that the patients were evaluated once and there was an exclusion of pregnant women with over 34 weeks of gestation. Therefore, after the gestational period no follow-up was done for cardiac hypertrophy progression and there were no perinatal outcomes available. Furthermore, heterogeneous samples including well-controlled and uncontrolled pre-gestational DM in pregnant women may have been interfered with in the results about the impact of metabolic disturbances in the fetuses.

In conclusion, fetal IVS volume assessed by 3D ultrasound with STIC with VOCAL methods showed significant differences in fetal IVS volumes between pre-gestational DM and healthy mothers between 20 to 34 + 6 weeks of gestation with higher values for pregnant women with pre-gestational DM.

REFERENCES

1. International Diabetes Federation. Guidelines [Internet]. Brussels: International Diabetes Federation; 2017 [cited 2017 Apr 10]. Available at: <https://www.idf.org/e-library/guidelines/77-idf-gdm-model-of-care-implementation-protocol-guidelines-for-healthcare-professionals.html>.
2. Lynch TA, Westen E, Li D, Katzman PJ, Malshe A, Drennan K. Stillbirth in women with diabetes: a retrospective analysis of fetal autopsy reports. *J Matern Fetal Neonatal Med* 2020;1-8.
[PUBMED](#) | [CROSSREF](#)
3. Depla AL, De Wit L, Steenhuis TJ, et al. Effect of maternal diabetes on fetal heart function on echocardiography: systematic review and meta-analysis. *Ultrasound Obstet Gynecol* 2021;57:539-50.
[PUBMED](#) | [CROSSREF](#)
4. Zielinsky P, Piccoli AL Jr. Myocardial hypertrophy and dysfunction in maternal diabetes. *Early Hum Dev* 2012;88:273-8.
[PUBMED](#) | [CROSSREF](#)
5. Al-Biltagi M, El Razaky O, El Amrousy D. Cardiac changes in infants of diabetic mothers. *World J Diabetes* 2021;12:1233-47.
[PUBMED](#) | [CROSSREF](#)
6. Chanthasenanont A, Somprasit C, Pongrojpaew D. Nomograms of the fetal heart between 16 and 39 weeks of gestation. *J Med Assoc Thai* 2008;91:1774-8.
[PUBMED](#)
7. García-Otero L, Gómez O, Rodríguez-López M, et al. Nomograms of fetal cardiac dimensions at 18–41 weeks of gestation. *Fetal Diagn Ther* 2020;47:387-98.
[PUBMED](#) | [CROSSREF](#)

8. Rocha LA, Zielinsky P, Nicoloso LHS, Araujo Junior E. Development of the Z-score for the measurement of myocardial thickness by two-dimensional echocardiography in normal fetuses. *Echocardiography* 2021;38:97-102.
[PUBMED](#) | [CROSSREF](#)
9. Rolo LC, Marcondes Machado Nardoza L, Araujo Júnior E, Simioni C, Maccagnano Zamith M, Fernandes Moron A. Reference curve of the fetal ventricular septum area by the STIC method: preliminary study. *Arq Bras Cardiol* 2011;96:386-92.
[PUBMED](#) | [CROSSREF](#)
10. Luewan S, Yanase Y, Tongprasert F, Srisupundit K, Tongsong T. Fetal cardiac dimensions at 14–40 weeks' gestation obtained using cardio-STIC-M. *Ultrasound Obstet Gynecol* 2011;37:416-22.
[PUBMED](#) | [CROSSREF](#)
11. Rolo LC, Santana EF, da Silva PH, et al. Fetal cardiac interventricular septum: volume assessment by 3D/4D ultrasound using spatio-temporal image correlation (STIC) and virtual organ computer-aided analysis (VOCAL). *J Matern Fetal Neonatal Med* 2015;28:1388-93.
[PUBMED](#) | [CROSSREF](#)
12. Gonçalves LF, Lee W, Espinoza J, Romero R. Examination of the fetal heart by four-dimensional (4D) ultrasound with spatio-temporal image correlation (STIC). *Ultrasound Obstet Gynecol* 2006;27:336-48.
[PUBMED](#) | [CROSSREF](#)
13. Paladini D. Standardization of on-screen fetal heart orientation prior to storage of spatio-temporal image correlation (STIC) volume datasets. *Ultrasound Obstet Gynecol* 2007;29:605-11.
[PUBMED](#) | [CROSSREF](#)
14. Palmieri CR, Simões MA, Silva JC, Santos AD, Silva MR, Ferreira B. Prevalence of hypertrophic cardiomyopathy in fetuses of mothers with gestational diabetes before initiating treatment. *Rev Bras Ginecol Obstet* 2017;39:9-13.
[PUBMED](#) | [CROSSREF](#)
15. Donofrio MT, Moon-Grady AJ, Hornberger LK, et al. Diagnosis and treatment of fetal cardiac disease: a scientific statement from the American Heart Association. *Circulation* 2014;129:2183-242.
[PUBMED](#) | [CROSSREF](#)
16. Lee-Tannock A, Hay K, Gooi A, Kumar S. Longitudinal assessment of ventricular strain, tricuspid and mitral annular plane systolic excursion (TAPSE and MAPSE) in fetuses from pregnancies complicated by diabetes mellitus. *Eur J Obstet Gynecol Reprod Biol* 2021;256:364-71.
[PUBMED](#) | [CROSSREF](#)
17. Atiq M, Ikram A, Hussain BM, Saleem B. Assessment of cardiac function in fetuses of gestational diabetic mothers during the second trimester. *Pediatr Cardiol* 2017;38:941-5.
[PUBMED](#) | [CROSSREF](#)
18. Bravo-Valenzuela NJM, Peixoto AB, Mattar R, Araujo Júnior E. Fetal cardiac function by mitral and tricuspid annular plane systolic excursion using spatio-temporal image correlation M-mode and left cardiac output in fetuses of pregestational diabetic mothers. *Obstet Gynecol Sci* 2021;64:257-65.
[PUBMED](#) | [CROSSREF](#)
19. Bravo-Valenzuela NJ, Peixoto AB, Mattar R, Melo Júnior JF, da Silva Pares DB, Araujo Júnior E. Fetal cardiac function and ventricular volumes determined by three-dimensional ultrasound using STIC and VOCAL methods in fetuses from pre-gestational diabetic women. *Pediatr Cardiol* 2020;41:1125-34.
[PUBMED](#) | [CROSSREF](#)
20. Schneider C, McCrindle BW, Carvalho JS, Hornberger LK, McCarthy KP, Daubeney PE. Development of Z-scores for fetal cardiac dimensions from echocardiography. *Ultrasound Obstet Gynecol* 2005;26:599-605.
[PUBMED](#) | [CROSSREF](#)
21. Gagnon C, Bigras JL, Fouron JC, Dallaire F. Reference values and Z scores for pulsed-wave Doppler and M-mode measurements in fetal echocardiography. *J Am Soc Echocardiogr* 2016;29:448-460.e9.
[PUBMED](#) | [CROSSREF](#)
22. Araujo Júnior E, Novoa Y, Novoa VA, Barros FS, et al. Reference values for the volumes of foetal heart atrial wall by three-dimensional ultrasound using STIC and VOCAL methods between 20w0d and 33w6d weeks of gestation. *J Matern Fetal Neonatal Med* 2016;29:3076-83.
[PUBMED](#) | [CROSSREF](#)
23. Barros FS, Rolo LC, Rocha LA, et al. Reference ranges for the volumes of fetal cardiac ventricular walls by three-dimensional ultrasound using spatiotemporal image correlation and virtual organ computer-aided analysis and its validation in fetuses with congenital heart diseases. *Prenat Diagn* 2015;35:65-73.
[PUBMED](#) | [CROSSREF](#)
24. Melo Júnior JF, Bravo-Valenzuela NJ, Nardoza LMM, et al. Reference values of fetal heart myocardial volume by three-dimensional ultrasound using spatiotemporal image correlation and virtual organ

- computer-aided analysis methods and their applicability in pregestational diabetic women. *Am J Perinatol* 2021;38:721-7.
[PUBMED](#) | [CROSSREF](#)
25. Samanth J, Nayak K, Vasudeva A, et al. Myocardial hypertrophy in fetuses of women with gestational diabetes. *J Appl Pharm Sci* 2020;10:105-10.
26. Leipold H, Worda C, Schwindt J, Kautzky-Willer A, Bancher-Todesca D, Husslein PW. Severe diabetic fetopathy despite strict metabolic control. *Wien Klin Wochenschr* 2005;117:561-4.
[PUBMED](#) | [CROSSREF](#)
27. Gardiner HM, Pasquini L, Wolfenden J, Kulinskaya E, Li W, Henein M. Increased periconceptual maternal glycated haemoglobin in diabetic mothers reduces fetal long axis cardiac function. *Heart* 2006;92:1125-30.
[PUBMED](#) | [CROSSREF](#)
28. Lee-Tannock A, Hay K, Kumar S. Differences in biomarkers of cardiac dysfunction in cord blood between normal pregnancies and pregnancies complicated by maternal diabetes. *Aust NZ J Obstet Gynaecol* 2022;62:79-85.
[PUBMED](#) | [CROSSREF](#)