

Dental Pulp Revascularization in a Replanted Avulsed Immature Maxillary Permanent Central Incisor

 Peter M. DI FIORE,  Gary R. HARTWELL

ABSTRACT

An 8-year-old girl sustained an accidental traumatic avulsion of her right maxillary permanent central incisor. She arrived with her mother at a hospital dental clinic with the right maxillary central incisor tooth wrapped in a wet paper towel over 1 hour after the injury. Replantation was accomplished without root surface alteration or root canal intervention. Clinical and radiographic follow-up examinations for over 1 year revealed continued root growth and apical development of the replanted avulsed immature maxillary central incisor with no signs or symptoms of pulpal or periapical pathosis. Excellent outcomes were achieved for periodontal ligament reattachment without removal of the periodontal membrane and pulp revascularization without endodontic intervention.

Keywords: Immature, incisor, pulp, replanted, revascularization

HIGHLIGHTS

- Dental pulp revascularization can occur in replanted avulsed immature teeth.
- Root growth and development can continue for replanted avulsed immature teeth.
- Replanted avulsed immature teeth can be retained in a state of health without removal of the periodontal membrane or endodontic intervention even under less than optimal conditions.

INTRODUCTION

Traumatic dental injuries to the permanent dentition predominantly occur during the 10-year period of 6 to 16 years of age, with a mean age of 11 years and overwhelmingly affect the maxillary incisor teeth (1-8). Dental avulsion, the most severe type of dental traumatic injury, is the disarticulation of a tooth from its socket. The term extra-articulation has also been used to describe this injury, to emphasize that the


tooth completely came out of its alveolar socket (9). Tooth avulsion accounts for an average of 8% of all traumatic dental traumatic injuries sustained among different patient populations (1-8). In an extensive investigation of 10,166 traumatically injured permanent teeth in 4,754 patients, 8.8% were avulsions (10).

When the teeth are traumatically avulsed, two essential dental tissues immediately sustain serious injury. The vascular blood supply to the dental pulp is completely severed at the apical foramen, causing the pulpal tissue to undergo necrosis and the periodontal ligament attachment at the lamina dura of the alveolar bone socket is separated, causing the periodontal membrane on the root surface cementum to lose viability (11-13).

Replantation of avulsed teeth as soon as possible after avulsion is essential to maintain the viability of the periodontal membrane for reattachment and prevention of replacement root resorption (11, 14, 15). For replanted mature teeth with fully developed root apices, it is also essential that the necrotic pulpal tissue be removed in a timely manner after replantation to prevent inflammatory root resorption (16, 17). However, for replanted immature teeth with incomplete root formation and wide open apices, the pulpal tissue should not be removed, as there is a potential for dental pulp revascularization (16, 17).

The authors report a case of successful pulp revascularization with continued root growth and apical development of an avulsed immature permanent maxillary central incisor replanted over

Please cite this article as "Di Fiore PM., Hartwell GR. Dental pulp revascularization in a replanted avulsed immature maxillary permanent central incisor. *Eur Endod J* (2017) 1:18

From the Department of Endodontics (P.M.D. ) petermdifiore@aol.com), University of Texas School of Dentistry, Houston, TX, USA; Department of Endodontics (G.R.H.), Rutgers University School of Dental Medicine, Newark, NJ, USA

Received 16 May 2017, revision requested 16 June 2017, last revision received 19 June 2017, accepted 21 June 2017

Published online: 21 July 2017
DOI: 10.5152/eej.2017.17031

This work is licensed under a Creative Commons Attribution-NonCommercial 4.0 International License.



1 hour after traumatic avulsion in an 8-year-old child and followed for over 1 year.

CASE PRESENTATION

History

An 8-year-old girl and her mother arrived at a hospital dental clinic with the child's front tooth wrapped in a wet paper towel. The tooth had been completely "knocked-out of the mouth" in a sledding accident that occurred over 1 hour ago, as estimated by the mother. Medical history revealed that the child was in good general health with no known allergies, was not taking any medications and had an up-to-date tetanus immunization.

Examination

The child was alert and responsive but somewhat apprehensive. The completely intact avulsed immature permanent maxillary central incisor with approximately two thirds of its normal root length formed was placed in physiologic saline and a radiograph of the tooth socket was taken. Clinical oral examination revealed that the maxillary left central incisor was missing due to traumatic avulsion. The child was in the mixed dentition stage of dental development with maxillary anterior over-jet protrusion and rotated eruption of the right central incisor. There was a 1-cm labial mucosal laceration and a contusion of the upper lip. The mother gave informed consent for treatment and replantation of her child's tooth. Radiographic examination revealed the missing avulsed maxillary left central incisor, the empty alveolar socket with no fractures and the presence of the adjacent intact immature maxillary incisors (Figure 1).

Treatment

Local anesthesia was administered by supra-periosteal labial infiltration of one cartridge lidocaine 2% 1:100,000 epinephrine. The alveolar socket was irrigated with physiologic saline, the blood clot removed and bleeding encountered. The avulsed incisor was replanted into its socket and splinted with 0.032-gauge arch wire bonded to the adjacent incisors with composite resin. The mucosal lip laceration was sutured with three interrupted 04 silk sutures. Penicillin VK 500 mg q8h for 5 days and Tylenol 325 mg q6h prn were prescribed and home care instructions given.

Follow-up

One week after replantation, the patient was asymptomatic. Clinical examination revealed that the maxillary incisors and splint were stable, the maxillary labial alveolar mucosa was normal and the gingival attachment around the maxillary left central incisor was well adapted (Figure 2). Radiographic examination revealed that the replanted and splinted maxillary left central incisor was in normal position in its socket (Figure 3).

The lip sutures were removed and the laceration was healing. Five weeks after replantation, the patient was asymptomatic and the splint was removed. Clinical examination revealed that the lip laceration had completely healed, the alveolar mucosa was normal with no swelling or tenderness to palpation, and the maxillary incisors were stable with normal functional mobility, intact gingival attachments and no pain on percus-

sion (Figure 4). Pulp vitality tests were negative for the maxillary incisors, a usual finding for developing immature teeth. Radiograph examination revealed normal alveolar bone with no periapical or periradicular radiolucencies (Figure 5). Five

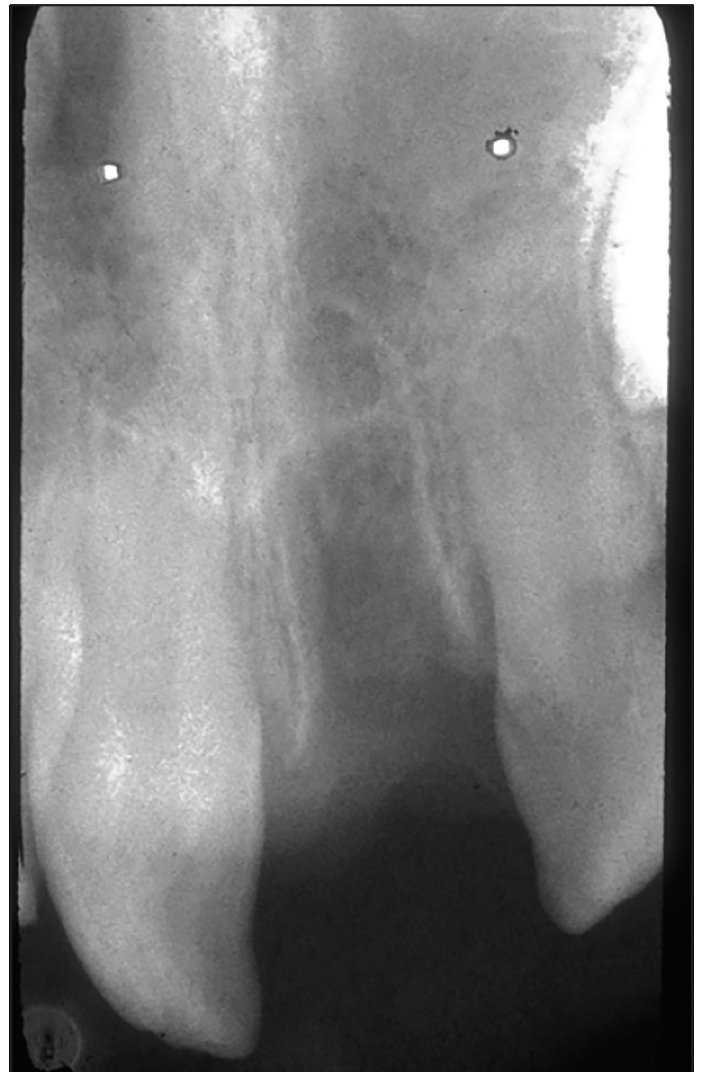

Figure 1. Radiograph of avulsed maxillary left central incisor alveolar socket

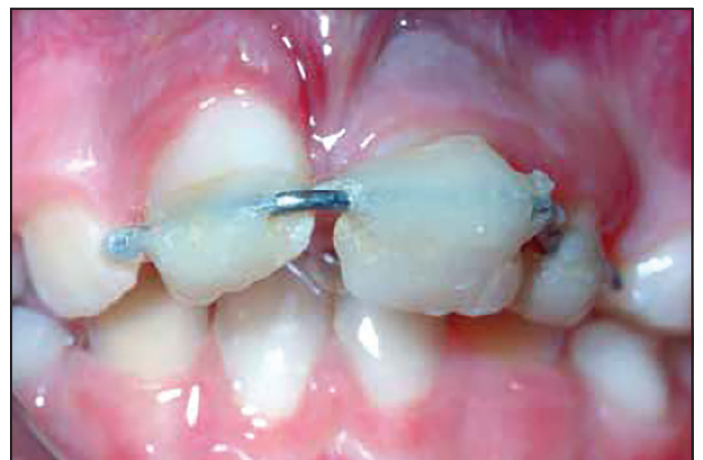

Figure 2. Photograph of replanted and splinted maxillary left central incisor 1 week after avulsion

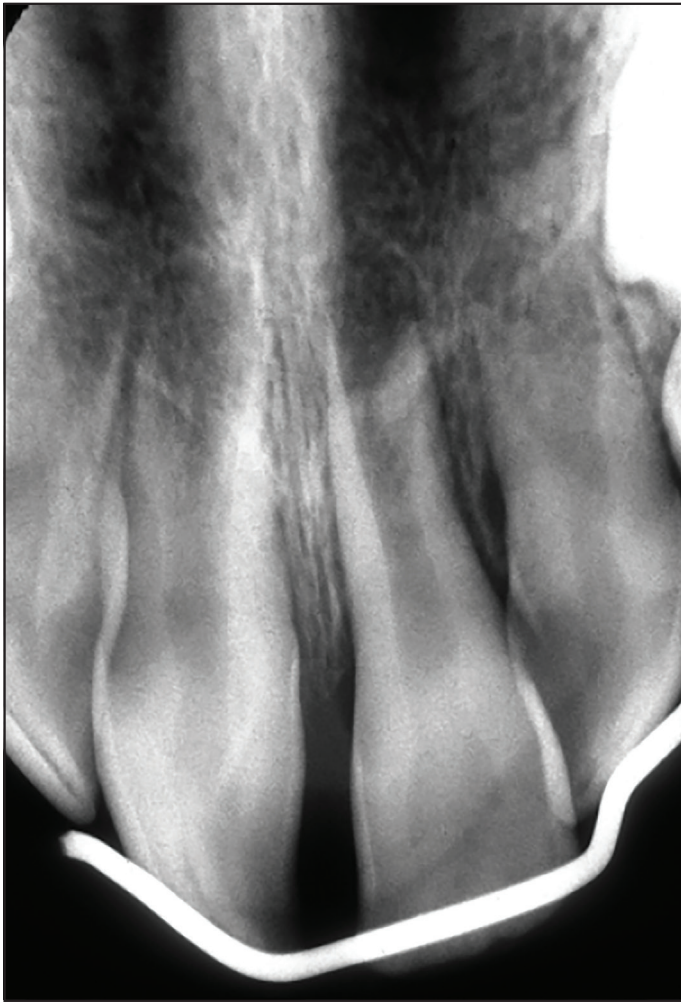

Figure 3. Radiograph of replanted and splinted maxillary left central incisor 1 week after avulsion

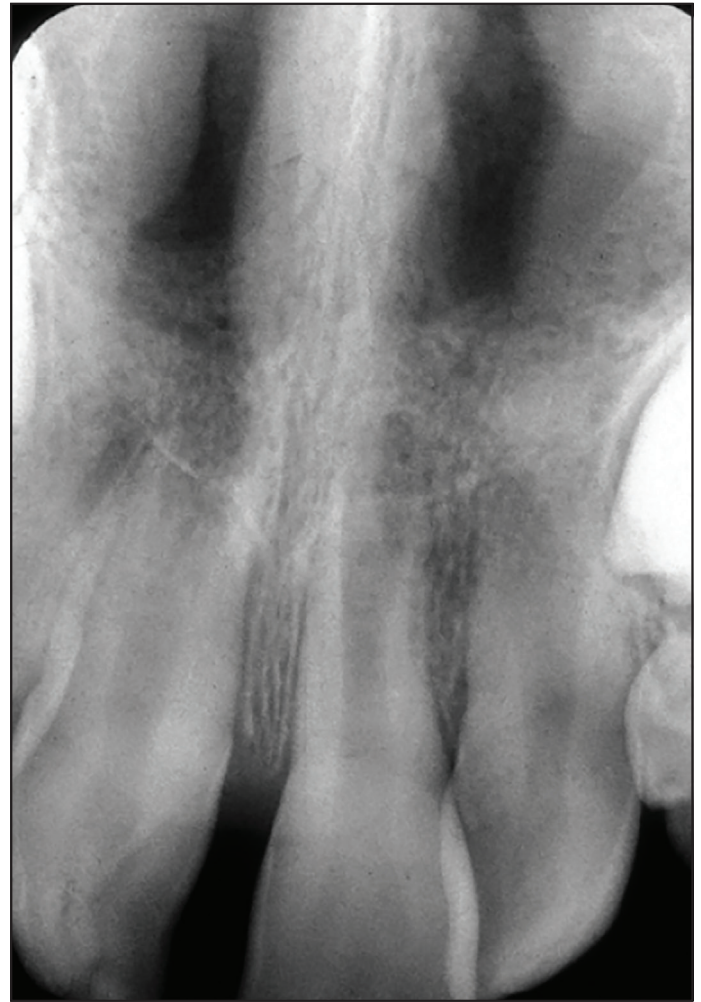

Figure 5. Radiograph of replanted maxillary left central incisor 5 weeks after avulsion

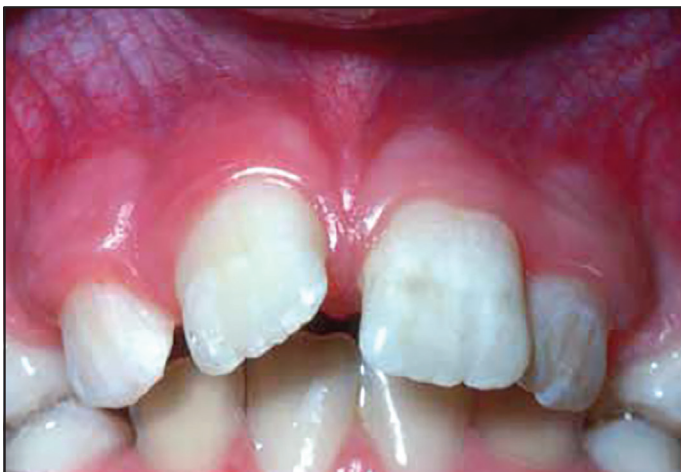

Figure 4. Photograph of replanted maxillary left central incisor 5 weeks after avulsion

months after replantation, all clinical examination parameters for the mucogingival tissues and the maxillary incisors were normal; however, pulp vitality tests continued to be inconclusive. Radiograph examination revealed progressive root growth and apical development of the maxillary incisors with normal-appearing root surfaces and alveolar bone (Figure 6).

Fifteen months after replantation, while the patient was undergoing orthodontic treatment for her Class II malocclusion, clinical examination revealed that the maxillary incisors were asymptomatic without pain on percussion or tenderness to palpation and had normal functional tooth mobility, intact gingival attachments and positive pulp vitality tests. Radiographic examination of the replanted left central incisor revealed continued root growth and apical development consistent with that of the right central incisor, normal periapical and periradicular bone, slight narrowing of the root canal and mild partial pulp calcification (Figure 7).

DISCUSSION

Based on current guidelines for the management traumatic dental injuries, avulsed immature teeth should be replanted and monitored over time for pulp revascularization (16, 17). In a classic study of 110 avulsed human teeth stored in wet and dry environments for extra-alveolar time periods of up to 2 hours, it was found that 57% of the immature teeth that were replanted after accidental avulsion clinically and radiographically showed a pulpal revascularization response and except for one, all showed no root resorption (18). It should be mentioned, however, that the revascularized pulps later exhibited partial pulp calcification (18, 19).

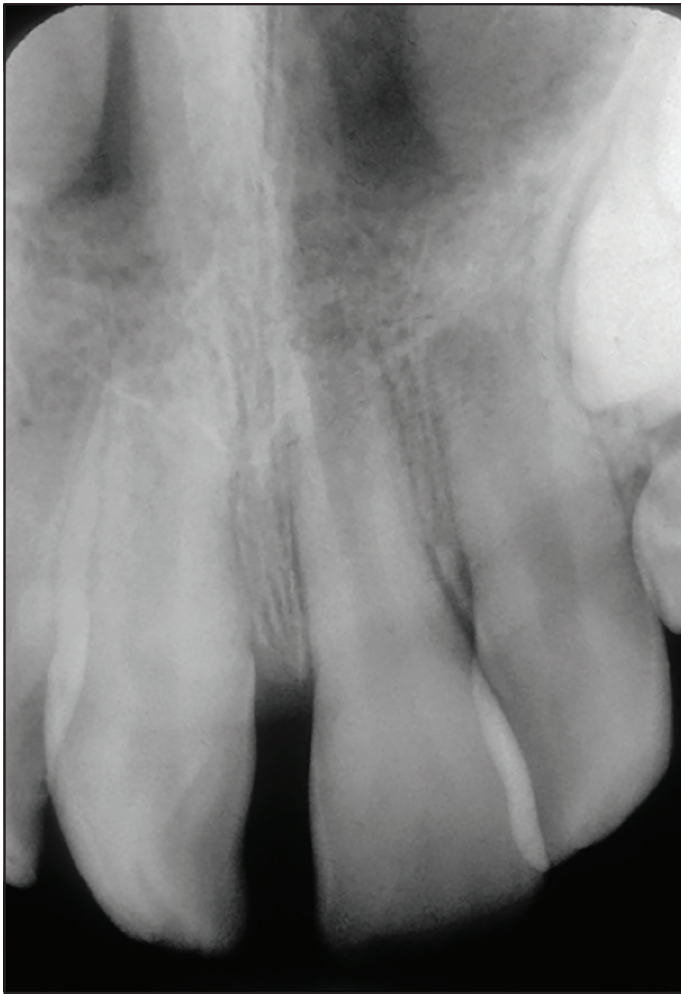

Figure 6. Radiograph of replanted maxillary left central incisor 5 months after avulsion

In a comprehensive four-part clinical study on the prognosis of 400 replanted avulsed incisor teeth in 322 patients, whose ages ranged from 5 to 52 years with a mean age of 14 years and a median age of 11 years, and who were prospectively followed for pulpal and periodontal healing over a 23-year period with a mean observation period of 5 years, it was found that 70% of the teeth were retained (20-23). Pulpal healing among all 400 teeth was 8%, whereas pulpal healing among 94 of 110 immature teeth, in which pulpal revascularization was deemed to be possible, was 34% and increased with decreased root development for teeth in the very early stages of root formation with wide open apices (21). It was determined, according to the root formation stages (1, root length $\frac{1}{4}$; 2, root length $\frac{1}{2}$; 3, root length $\frac{3}{4}$; 4, root length complete; 5, apex $\frac{1}{2}$ closed and 6, apex completely closed) as described by Moorrees (24), that the rate of pulp revascularization was: 16% at stage 5, 35% at stage 4, 40% at stage 3 and 60% at stage 2 (21). It was also found that among 28 avulsed immature teeth replanted at stages of incomplete root development, 25% showed complete root development, 29% showed partial root development and 46% showed arrested root development (22). With respect to periodontal reattachment among all teeth studied, it was found that periodontal healing with no signs of root resorption occurred

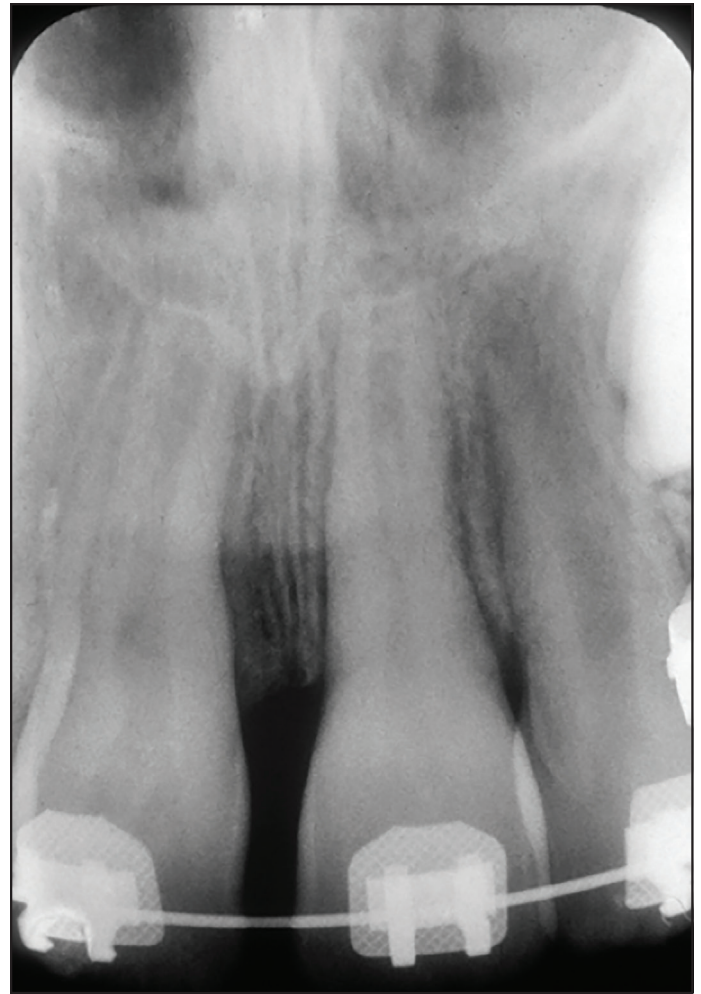

Figure 7. Radiograph of replanted maxillary left central incisor 15 months after avulsion

in 24%, and periodontal healing with no signs of progressive root resorption occurred in 36% (23). Additionally, the overall rate of periodontal healing was related to the stage of root development and was better for teeth with incomplete apical closure (23).

Four further clinical investigations on the frequency of pulpal revascularization and periodontal reattachment of replanted immature permanent anterior teeth in the developing dentition of children have demonstrated that these teeth had a reasonable prognosis for the retention (25-28). In an assessment of 154 replanted avulsed permanent incisors that correlated pulp revascularization with respect to the width of the apical foramen, the rate of revascularization in the entire sample studied was 8% with a difference between immature teeth (which was 18%) and mature teeth (which was 0%). However, the rate of revascularization was highest at 25% among the group of immature teeth with an apical foramen width of 2 to 3 mm (25). A clinical and radiographic retrospective study of 33 teeth with fully formed root lengths but with open apices at Moorrees (24) stages 5 and 6, replanted within 1 to 3 hours or more after avulsion and followed for up to 5 years, found that only 24% were diagnosed with pulp necrosis and endodontically treated. For those

teeth replanted within 1 hour after avulsion, the periodontal healing rate was 67%, whereas for teeth replanted three or more hours after avulsion, 83% had root resorption (26). In an investigation of 103 replanted permanent incisors in different age groups that were examined after being followed for an average of 2.5 years, it was found that pulp revascularization occurred in 41% of the teeth of children, 9% of the teeth of adolescents and 0% of the teeth of adults (27). Also, in a follow-up treatment assessment of 45 replanted avulsed permanent anterior teeth, periodontal healing was found to occur in 63% of teeth with open apices compared to 55% of teeth with closed apices (28).

In light of these clinical studies (25-28), it is clear that pulp revascularization and periodontal reattachment can be considered viable outcomes with favourable prognoses for replanted avulsed immature permanent teeth among children, within the parameters of current guidelines for the management of tooth avulsions (16, 17).

In the clinical case presented, this 8-year-old child, in the mixed dentition stage of dental development, had anterior maxillary over-jet protrusion. This type of malocclusion is considered to be a predisposing factor for traumatic dental injuries (29, 30). Because of the short root lengths of the replanted and adjacent incisors, a standard, functionally flexible composite bonded wire splint was applied and left in place for an extended time period of 5 weeks to ensure adequate stabilization during the healing process (31). In vitro and in vivo investigations that measured the lateral tooth movement of teeth with this type of splint have demonstrated that its immobilization effect did not exceed normal tooth firmness during use and that it provided a degree of tooth mobility similar to non-splinted teeth (32-35). Therefore, the extended splinting time for this immature tooth with a short root and a wide, open apex was reasonable.

Although vital pulpal responses were elicited for all of the maxillary incisors at the last recall examination, the pulpal vitality responses at examinations during the earlier follow-up periods were inconclusive. Findings of this type for pulp vitality testing are not uncommon for traumatized teeth, as there can be a temporary loss of sensory nerve function which can return later even in replanted avulsed immature teeth (36-40). Also, pulp vitality test results with immature teeth can be misleading because full development of the Plexus of Raschkow and full pulpal innervation with A-delta nerve fibers takes place after root formation has been completed (41-43). Radiographic examination at the last recall assessment 1 year after avulsion revealed that root growth and apical development of the replanted maxillary left central incisor had progressed and was comparable to that of the adjacent maxillary central incisor (Fig. 7). It was also observed that there was a slight narrowing of the root canal and a mild degree of partial pulp calcification of the replanted left central incisor. However, pulp calcification of this type is not an unusual finding following replantation of avulsed immature permanent teeth and is not considered to be an adverse sequela for long-term periapical health (18, 19, 25, 44).

At the time of a traumatic event, the out-of-mouth time is often difficult to exactly determine and is usually an approximate estimation. In the case presented, the extra-alveolar period from the time of the accident to the time that the patient arrived for treatment was approximately estimated at over 1 hour. The tooth was kept wrapped in a moist environment during that period and then placed in physiological saline until it was replanted. Treatment guidelines are extremely important in providing the clinician with the most current evidence-based information for the management of traumatic dental injuries and form the basis for treatment decisions (45). The treatment guidelines for the replantation of avulsed immature teeth with an extra oral time of less than 1 hour recommend immediate replantation, whereas the guidelines for teeth with an extra-oral time of more than 1 hour recommend one or more of the following procedures: removal of the periodontal ligament, soaking in 2% sodium fluoride and possibly performing root canal treatment prior to replantation (16, 17). Under the circumstances of this particular case, it was determined that the guidelines for the replantation of immature teeth with an extra oral period of less than 1 hour were appropriate. Therefore, the tooth was replanted without disrupting the periodontal membrane or disturbing the dental pulp, with excellent outcomes for periodontal ligament reattachment and pulpal revascularization. A systemic antibiotic was prescribed, consistent with the recommended treatment guidelines (16, 17) and based on evidence that the presence of microorganisms hindered pulp revascularization (46) and that systemic antibiotics administered at the time of replantation prevented inflammatory root resorption (47).

CONCLUSION

This clinical case demonstrated that an immature maxillary permanent central incisor, replanted under less than optimal conditions, underwent pulp revascularization and periodontal reattachment and was retained in a state of health. In the treatment of children with traumatic avulsions of immature permanent anterior teeth, when extra-alveolar time periods and storage media conditions are not optimal, consideration should be given to replantation without root surface alteration or root canal intervention. Treatment decisions should be patient-centered and made in consideration of accepted evidence-based treatment guidelines, the clinical circumstances presented at the time of the injury, the clinical judgement of the attending dentist and the dental and oral health needs of the patient.

Disclosures

Ethical Approval: N/A.

Informed Consent: N/A.

Peer-review: Externally peer-reviewed.

Authorship Contributions: Concept - P.M.D., G.R.H.; Design - P.M.D., G.R.H.; Supervision - P.M.D., G.R.H.; Resource - P.M.D., G.R.H.; Materials - P.M.D., G.R.H.; Data Collection and/or Processing - P.M.D., G.R.H.; Analysis and/or Interpretation - P.M.D., G.R.H.; Literature Review - P.M.D.; Writer - P.M.D.; Critical Review - P.M.D., G.R.H.

Conflict of Interest: No conflict of interest was declared by the authors.

Financial Disclosure: The authors declared that this study has received no financial support.

REFERENCES

- Andreasen JO. Etiology and pathogenesis of traumatic dental injuries: A study of 1,298 cases. *Scand J Dent Res* 1970; 78(4): 329-42.
- Andreasen JO, Ravn JJ. Epidemiology of traumatic dental injuries to the primary and permanent teeth in a Danish population sample. *Int J Oral Surg* 1972; 1(5): 235-9.
- Oikarinen K, Kassila O. Causes and types of traumatic tooth injuries treated in a public dental health clinic. *Endod Dent Traumatol* 1987; 3(4): 172-7.
- Oikarinen K. Pathogenesis and mechanism of traumatic injuries to teeth. *Endod Dent Traumatol* 1987; 3(5): 220-3.
- Zerman N, Cavalleri G. Traumatic injuries to permanent incisors. *Endod Dent Traumatol* 1991; 9(2): 61-4.
- Schatz JP, Joho JP. A retrospective study of dento-alveolar injuries. *Endod Dent Traumatol* 1994; 10(1): 11-4.
- Luz JG, Di Mase F. Incidence of dentoalveolar injuries in hospital emergency room patients. *Endod Dent Traumatol* 1994; 10(4): 188-90.
- Skaare AB, Jacobsen I. Dental injuries in Norwegians aged 7-18 years. *Dent Traumatol* 2003; 19(2): 67-71.
- Andersson L. Tooth avulsion and replantation. *Dental Traumatol* 2007; 23(3): 129.
- Lauridsen E, Hermann NV, Gerds TA, Kreiborg S, Andreasen JO. Pattern of traumatic dental injuries in the permanent dentition among children, adolescents, and adults. *Dental Traumatol* 2012; 28(5): 358-63.
- Barrett EJ, Kenny DJ. Avulsed permanent teeth: a review of the literature and treatment guidelines. *Endod Dent Traumatol* 1997; 13(4): 153-63.
- Trope M. Clinical management of the avulsed tooth: Present strategies and future directions. *Dental Traumatol* 2002; 18(1): 1-11.
- Trope M. Avulsion of permanent teeth: theory to practice. *Dental Traumatol* 2011; 27(4): 281-94.
- Andersson L, Bodin I. Avulsed human teeth replanted within 15 minutes - a long-term clinical follow-up study. *Endod Dent Traumatol* 1990; 6(1): 37-42.
- Turkistani J, Hanno A. Recent trends in the management of dentoalveolar traumatic injuries to primary and young permanent teeth. *Dental Traumatol* 2011; 27(1): 46-54.
- Flores MT, Andersson L, Andreasen JO, Bakland LK, Malmgren B, Barnett F, et al. Guidelines for the management of traumatic dental Injuries. II. Avulsion of permanent teeth. *Dental Traumatol* 2007; 23(3): 130-6.
- Andersson L, Andreasen JO, Day P, Heithersay G, Trope M, DiAngelis AJ, et al. International Association of Dental Traumatology Guidelines for the management of traumatic dental injuries: 2. Avulsion of permanent teeth. *Dental Traumatol* 2012; 28(2): 88-96.
- Andreasen JO, Hjorting-Hansen E. Replantation of teeth. I. Radiographic and clinical study of 110 human teeth replanted after accidental loss. *Acta Odontol Scand* 1966; 24(3): b263-86.
- Andreasen JO, Hjorting-Hansen E. Replantation of teeth. II. Histological study of 22 replanted anterior teeth in humans. *Acta Odontol Scand* 1966; 24(3): 287-306.
- Andreasen JO, Borum MK, Jacobsen HL, Andreasen FM. Replantation of 400 avulsed permanent incisors. 1. Diagnosis of healing complications. *Endod Dent Traumatol* 1995; 11(2): 51-8.
- Andreasen JO, Borum MK, Jacobsen HL, Andreasen FM. Replantation of 400 avulsed permanent incisors. 2. Factors related to pulpal healing. *Endod Dent Traumatol* 1995; 11(2): 59-68.
- Andreasen JO, Borum MK, Jacobsen HL, Andreasen FM. Replantation of 400 avulsed permanent incisors. 3. Factors related to root growth. *Endod Dent Traumatol* 1995; 11(2): 69-75.
- Andreasen JO, Borum MK, Jacobsen HL, Andreasen FM. Replantation of 400 avulsed permanent incisors. 4. Factors related to periodontal ligament healing. *Endod Dent Traumatol* 1995; 11(2): 76-89.
- Moorrees CFA, Fanning EA, Hunt EE Jr. Age variation for formation stages for ten permanent teeth. *J Dent Res* 1963; 42: 1490-502.
- Kling M, Cvek M, Mejare I. Rate and predictability of pulp revascularization in therapeutically reimplanted permanent incisors. *Endod Dent Traumatol* 1986; 2(3): 83-9.
- Schatz JP, Hausherr C, Joho JP. A retrospective clinical and radiographic study of teeth re-implanted following traumatic avulsion. *Endod Dent Traumatol* 1995; 11(5): 235-9.
- Ebeleseder KA, Friehs S, Ruda C, Pertl C, Glockner K, Hulla H. A study of replanted permanent teeth in different age groups. *Endod Dent Traumatol* 1998; 14(6): 274-8.
- Chappuis V, von Arx T. Replantation of 45 avulsed permanent teeth: a 1-year follow-up study. *Dent Traumatol* 2005; 21(5): 289-96.
- Jarvinen S. Incisal overjet and traumatic injuries to upper permanent incisors. A retrospective study. *Acta Odontol Scand* 1978; 36(6): 359-62.
- Jarvinen S. Traumatic injuries to the upper permanent incisors related to age and incisal overjet. A retrospective study. *Acta Odontol Scand* 1979; 37(6): 335-8.
- Oikarinen K. Tooth splinting: a review of the literature and considerations of the versatility of a wire-composite splint. *Endod Dent Traumatol* 1990; 6(6): 237-50.
- Oikarinen K. Functional fixation for traumatically luxated teeth. *Endod Dent Traumatol* 1987; 3(5): 224-8.
- Oikarinen K. Comparison of the flexibility of various splinting methods for tooth fixation. *Int J Oral Maxillofac Surg* 1988; 17(2): 125-7.
- Oikarinen K, Andreasen JO, Andreasen FM. Rigidity of various fixation methods used as dental splints. *Endod Dent Traumatol* 1992; 8(3): 113-9.
- Ebeleseder KA, Glockner K, Stadler P. Splints made of wire and composite: an investigation of lateral tooth mobility in vivo. *Endod Dent Traumatol* 1995; 11(6): 288-93.
- Skieller V. The prognosis for young teeth loosened after mechanical trauma. *Acta Odontol Scand* 1960; 18:117-81.
- Teitler D, Tzadik D, Eidelman E, Odont, Chosack A. A clinical evaluation of vitality tests in anterior teeth following fracture of enamel and dentin. *Oral Surg Oral Med Oral Pathol* 1972; 34(4): 649-52.
- Rock WP, Grundy MC. The effect of luxation and subluxation upon the prognosis of traumatized incisor teeth. *J Dent* 1981; 9(3): 224-30.
- Mesaros SV, Trope M. Revascularization of traumatized teeth assessed by laser Doppler flowmetry: case report. *Endod Dent Traumatol* 1997; 13(1): 24-30.
- Ohman A. Healing and sensitivity to pain in young replanted human teeth. An experimental clinical and histological study. *Odontol Tidskr* 1965; 73: 166-227.
- Fulling HJ, Andreasen JO. Influence of maturation status and tooth type of permanent teeth upon electrometric and thermal pulp testing. *Scand J Dent Res* 1976; 84(5):286-90.
- Klein H. Pulp responses to an electric pulp stimulator in the developing permanent anterior dentition. *ASDC J Dent Child* 1978; 45(3): 199-201.
- Harris R, Griffin CJ. Fine structure of nerve endings in the human dental pulp. *Arch Oral Biol* 1968; 13: 773-8.
- Jacobsen I, Kerekes K. Long-term prognosis of traumatized permanent anterior teeth showing calcifying processes in the pulp cavity. *Scand J Dent Res* 1977; 85(7): 588-98.
- Andersson L. The importance of guidelines. *Dent Traumatol* 2007; 23(2): 65.
- Cvek M, Cleaton-Jones P, Austin J, Lownie J, Kling M, Fatti P. Pulp revascularization in reimplanted immature monkey incisors - predictability and the effect of antibiotic systemic prophylaxis. *Endod Dent Traumatol* 1990; 6(4): 157-69.
- Hammarstrom L, Blomlöf L, Feiglin B, Andersson L, Lindskog S. Replantation of teeth and antibiotic treatment. *Endod Dent Traumatol* 1986; 2(2): 51-7.