

# Ptotic versus Nonptotic Breasts in Nipple-sparing Mastectomy and Immediate Prepectoral Breast Reconstruction

Edvin Ostapenko, MD\*†  
 Larissa Nixdorf, MD\*  
 Yelena Devyatko, MD\*  
 Ruth Exner, MD\*  
 Pia Math, MD\*  
 Kerstin Wimmer, MD\*  
 Theresa Haeusler, MD\*  
 Florian Fitzal, MD\*

**Background:** In recent years, nipple-sparing mastectomy followed by implant-based breast reconstruction has gained popularity due to improved cosmetic and psychological benefits. However, patients with ptotic breasts remain the main challenge for surgeons, owing to the potential risk of postoperative complications.

**Methods:** A retrospective chart review was performed for patients who underwent nipple-sparing mastectomy and prepectoral implant-based breast reconstruction between March 2017 and November 2021. Patient demographics, incidence of complications, and quality of life assessed using the BREAST-Q questionnaire were compared between the two different incisions [inverted-T for ptotic versus infra-mammary fold (IMF) for nonptotic breasts].

**Results:** A total of 98 patients were examined: 62 in the IMF cohort and 36 in the inverted-T cohort. The results demonstrated equivalence in the safety metrics between the two groups, including hematoma ( $p=0.367$ ), seroma ( $p=0.552$ ), infection ( $P=1.00$ ), skin necrosis ( $P=1.00$ ), local recurrence ( $P=1.00$ ), implant loss ( $P=0.139$ ), capsular contracture ( $P=1.00$ ), and nipple-areolar complex necrosis ( $P=0.139$ ). The BREAST-Q scores were equally high in both groups.

**Conclusion:** Our results suggest that inverted-T incision for ptotic breasts is a safe modality with similar complication rates and high aesthetic results compared with IMF incision for nonptotic breasts. A higher rate of nipple-areolar complex necrosis in the inverted-T group, although not significant, should be considered during careful preoperative planning and patient selection. (*Plast Reconstr Surg Glob Open* 2023; 11:e5032; doi: [10.1097/GOX.0000000000005032](https://doi.org/10.1097/GOX.0000000000005032); Published online 26 May 2023.)

## INTRODUCTION

Within the last century, mastectomy rates are increasing.<sup>1</sup> The reasons for this are multifactorial, including increased rates of breast cancer and genetic testing, raised awareness, and improved diagnosis methods.<sup>2</sup> Better understanding of mastectomy flap perfusion has resulted in more frequent use of reconstructive techniques such as skin- (SSM) and nipple-sparing mastectomy (NSM). These

techniques can offer better reconstructive outcomes after mastectomy.

NSM is an alternative to SSM, as it allows for preservation of the nipple-areolar complex (NAC) while removing glandular and ductal tissues. Accordingly, over the past few years, there has been an increase in NSMs followed by immediate implant-based breast reconstruction (IBBR) due to better aesthetic outcomes and a decrease in the rate of postoperative complications.<sup>3</sup> However, NSM and immediate IBBR have been largely limited to patients with relatively small, nonptotic, or minimally ptotic breasts. A detailed technique of NSM and “skin reduction” in large and ptotic breasts was described in 1987, and was controversial due to unknown incidence of cancer following the procedure and frequent occurrence of postoperative complications.<sup>4</sup> Nowadays, patients with large

From the \*Department of Surgery and Comprehensive Cancer Center, Medical University of Vienna, Vienna, Austria; and †Faculty of Medicine, Vilnius University, Vilnius, Lithuania.

Received for publication February 9, 2023; accepted April 6, 2023. Drs Edvin Ostapenko and Larissa Nixdorf contributed equally to this work.

Copyright © 2023 The Authors. Published by Wolters Kluwer Health, Inc. on behalf of The American Society of Plastic Surgeons. This is an open-access article distributed under the terms of the [Creative Commons Attribution-Non Commercial-No Derivatives License 4.0 \(CCBY-NC-ND\)](https://creativecommons.org/licenses/by-nc-nd/4.0/), where it is permissible to download and share the work provided it is properly cited. The work cannot be changed in any way or used commercially without permission from the journal.

DOI: [10.1097/GOX.0000000000005032](https://doi.org/10.1097/GOX.0000000000005032)

Disclosure statements are at the end of this article, following the correspondence information.

Related Digital Media are available in the full-text version of the article on [www.PRSGlobalOpen.com](https://www.PRSGlobalOpen.com).

and ptotic breasts still present a technical challenge for surgeons in terms of aesthetic outcomes and postoperative complications.<sup>5,6</sup>

Over the past decade, at our breast health center, we have had increasing experience performing NSM for ptotic and nonptotic breasts using more and more immediate prepectoral IBBR. In an effort to increase aesthetic outcomes and decrease postoperative complications for women with ptotic breasts, we present a modification of the “skin reducing” NSM, performed through an inverted T-incision, and compare it with inframammary fold (IMF) incision for nonptotic breasts.

In this article, we present the feasibility of our most recent techniques for NSM followed by prepectoral IBBR in ptotic and in nonptotic breasts. Oncological safety, postoperative morbidity, and aesthetic outcomes were recorded and documented.

## PATIENT AND METHODS

### Data Collection

A retrospective electronic chart review was performed in patients who underwent prepectoral IBBR after NSM at the Department of General Surgery, Medical University of Vienna, and the private clinic between March 2017 and November 2021. This study followed the Declaration of Helsinki on Medical Protocols and Ethics, and the ethics committee of the Medical University of Vienna approved this study (no. 1597/2021).

This analysis included women undergoing NSM and prepectoral IBBR performed by the same senior breast surgeon (F.F.). In every patient, NSM was performed with immediate implant based-breast reconstruction (IBBR) using a single-stage, direct-to-implant approach, or a two-staged approach with a tissue expander placed initially, followed by tissue expander to implant exchange.

For the analysis, we divided the patients into two groups according to the surgical incision (inverted-T versus IMF). Forty patients were operated on using inverted-T incisions, and the remaining 62 patients underwent IMF incisions. An inverted-T incision was preferable for the ptotic breasts, whereas an IMF incision was preferable for the nonptotic breasts. The results of the two groups were compared. Only patients who received inverted-T incisions and IMF incisions were included in this study. Patients who received other mastectomy incisions were excluded from the study.

Postreconstruction complication rates were subsequently evaluated. The outcomes of interest were any complications, including breast infection, seroma, hematoma, skin and NAC necrosis, capsular contraction (graded using the four-grade Baker scale,<sup>7</sup> with only grades II, III, and IV considered in the study), implant loss (removal of implant was classified as implant loss), and local and distant recurrence. To assess the impact of postoperative radiation on various complication rates, analyses were performed, separating patients into post-mastectomy radiation therapy (PMRT) and non-PMRT groups.

### Takeaways

**Question:** Is inverted-T incision safe for ptotic breasts in NSM after prepectoral IBBR?

**Findings:** Inverted-T incision is a safe modality for ptotic breasts in nipple-sparing mastectomy. Inframammary incision shows low rates of NAC necrosis in nonptotic breasts. Both techniques provide high levels of quality of life outcomes.

**Meaning:** This demonstrates that patients who are candidates for prepectoral IBBR and have ptotic breasts can achieve similar complication rates and high aesthetic results with their reconstruction as patients with nonptotic breasts.

Operative characteristics, including prophylactic or therapeutic indication, single- or two-stage approach, implant location, NSM incision type (inverted-T versus IMF), axillary management (axillary lymph node dissection or sentinel node biopsies), grade of breast ptosis (evaluated according to the Regnault classification<sup>8</sup>), and follow-up time, were recorded. The minimum follow-up was 12–60 months. Photographs were taken before surgery and at follow-up visits at 6, 12, 24, 36, 48, and 60 months postoperatively.

To assess patients' quality of life, they were asked prospectively to complete the BREAST-Q questionnaire after breast reconstruction.<sup>9</sup> The questionnaire involves a module measuring postreconstruction satisfaction on four subscales: (1) sexual well-being, (2) satisfaction with breasts, (3) psychosocial well-being, (4) physical well-being. For each scale, item responses were summed and transformed into scores, ranging from 0 to 100.

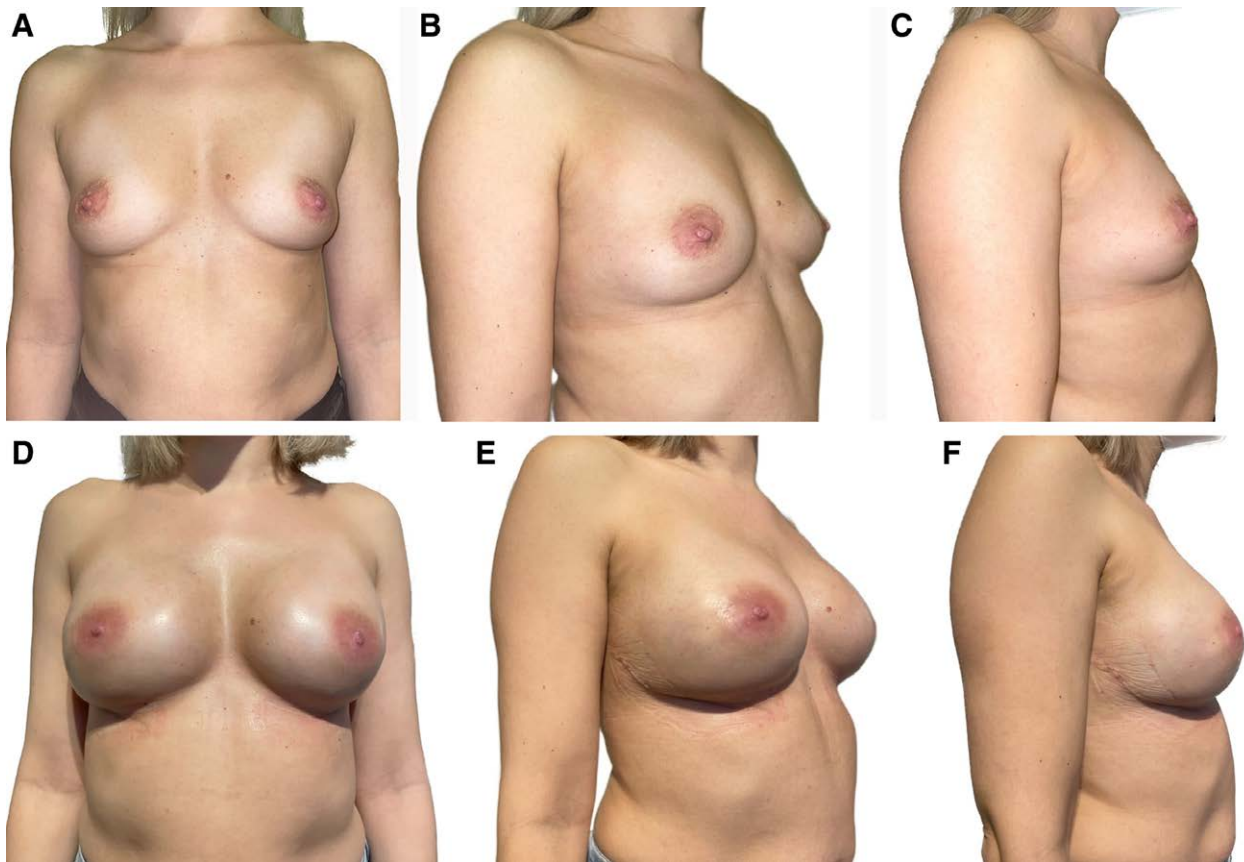
## SURGICAL TECHNIQUE

### Nipple-sparing Mastectomy

#### IMF Incision

This is a preferable method for cup A–B sized breasts, ptosis grade 0–I (Fig. 1). Ordinarily, we used the IMF for the incision laterally from the medioclavicular line leading up to 5 cm medially along the IMF. After the incision, we searched the right plane, which is just above the Scarpa fascia. This fascia splits into two distinct parts: the anterior lamella, which becomes the superficial fascia between the subcutaneous tissue and breast parenchyma, and the posterior lamella, which grows to the pectoralis fascia. At the point where both fascia divert, we found the IMF, which should not be destroyed in order to diminish implant malposition. Next, we dissected between skin and superficial lamella following the fascia. We stopped the preparation around 2 cm toward the nipple, dissected the fascia at this margin end, and followed it back again at the inner part down to the IMF. Finally, the resulting fascial flap covered the implant (Fig. 2).

After this step, dissection was continued directly to the posterior lamella of the fascia at the pectoralis muscle (Fig. 2A). The breast parenchyma was removed from the



**Fig. 1.** Representative reconstructive outcome. A–C, Preoperative photographs of a 32-year-old female patient who underwent bilateral NSM IMF followed by prepectoral IBBR. D–F, 18-months postoperative photographs after immediate prepectoral IBBR.

pectoralis muscle due to dissection between the posterior lamella and pectoralis muscle alongside the footprint of the breast. Subsequently, the breast tissue was detached from the skin. For this dissection between the subcutaneous skin and breast parenchyma, we used scissors (cold dissection) to avoid thermal injury.

We tracked the breast with two Kocher clamps, and then started sharp dissection (Fig. 2B). After finishing the dissection between the skin flap and breast parenchyma, a retroareolar tissue sample was taken and examined by frozen section with marked margins. In cases of no atypical cells or cancer cells, the nipple can be spared. Finally, the remaining breast tissue was dissected.

#### *Inverted-T Incision*

This is a preferable method for cup C–D sized breast, ptosis grade II–III (Fig. 3). We marked the patients preoperatively while standing for NSM through inverted-T incision with a new preplanned position for the NAC. After de-epithelialization, the skin was carefully lifted from the breast parenchyma (Fig. 4A). The NAC was harvested as a full-thickness skin graft and grafted to the new position, depending on the preoperative sternum-nipple distance and intraoperative findings (Fig. 4C). Regarding preparation, we performed the surgery with no differences from nonptotic breasts.

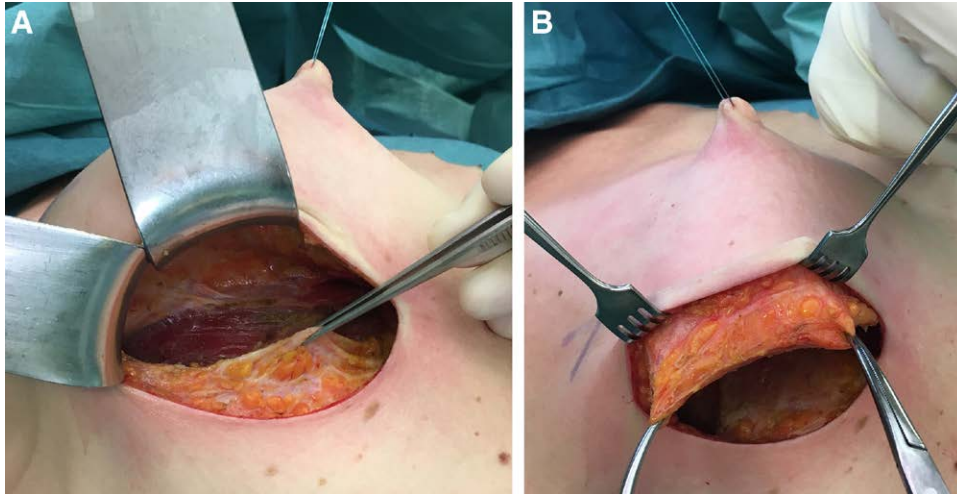
#### *Prepectoral Direct-to-Implant Reconstruction*

Upon completion of the mastectomy, we performed prepectoral direct-to-implant reconstruction. The plane of the mastectomy must be correct, between the superficial dermis fascia and Cooper ligaments. The pocket should fit the used implant size, which should be measured first by a ruler, than by a sizer. If a synthetic mesh was not used, the implant was inset into the prepared prepectoral pocket (Fig. 4B). If synthetic mesh was used (TiLOOP Bra Pocket), we sutured the mesh to the upper pole and the lateral pole and inserted the implant. The mesh was wrapped around the prosthesis at the medial and lower borders, and then we closed everything with 4/0 resorbable white color and 4/0 monofilament (Monocryl or V-Lock).

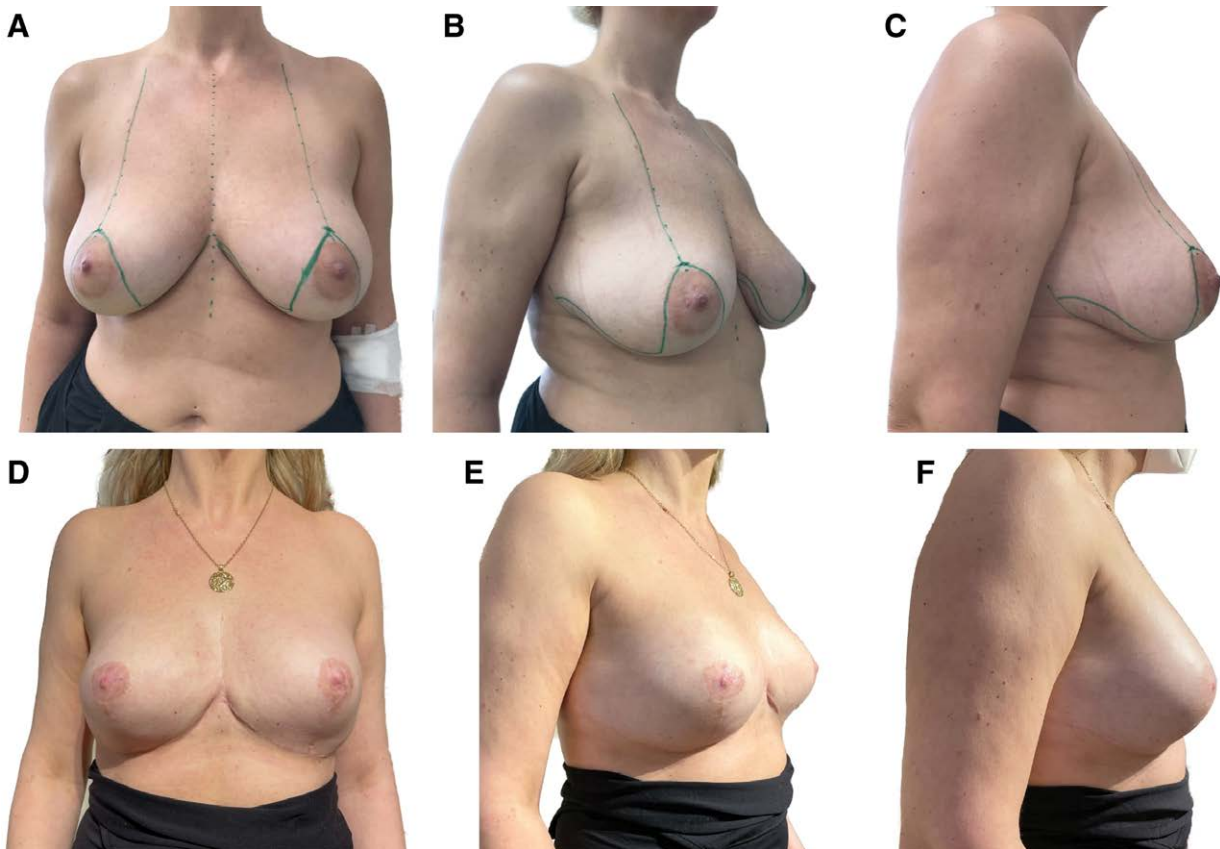
#### *Statistical Analysis*

Data were analyzed using IBM SPSS Version 24 (IBM Corp., Armonk, N.Y.). Clinical characteristics of the two groups were compared with adequate matching and described using descriptive statistics. Mean, median and standard deviation were calculated.  $\chi^2$  and Fisher exact tests were used to evaluate associations between categorical values and complication rates. Numerical variables among the groups were analyzed and compared either with independent-samples *t* test or Mann-Whitney U test depending on





**Fig. 2.** IMF incision. A, Dissection between the posterior lamella and the pectoralis muscle. B, Dissection between the skin and superficial lamella.



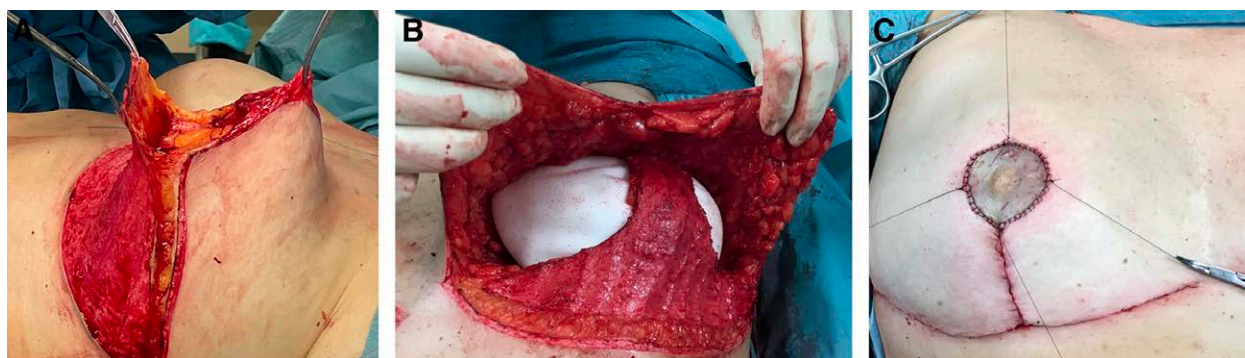**Fig. 3.** Representative reconstructive outcome. A–C, Preoperative photographs of a 41-year-old female patient who underwent bilateral NSM inverted-T followed by prepectoral IBBR. D–F, 2-year postoperative photographs after immediate prepectoral IBBR.

the normality. The Kaplan-Meier method was used to estimate and additional pointwise 95% confidence intervals for several timepoints of interest. Additionally, a log-rank test was calculated. Odds ratios, 95% confidence intervals, and *P* values were calculated for each outcome. A *P* value less than 0.05 was considered to indicate statistical significance.

## RESULTS

### Clinical Characteristics

A retrospective chart review identified 98 patients who underwent NSM and prepectoral IBBR between March 2017 and November 2021. NSM was mostly



**Fig. 4.** Inverted-T incision. A, The de-epithelialization was made, and NAC was harvested as a full-thickness skin graft. B, The implant is placed and the skin flaps are sutured. C, The nipple graft has been positioned, and the bolster will be placed for better immobilization.

performed as a treatment for invasive breast cancer without suspected NAC invasion; consequently, most of operations were therapeutic. The patients' demographic and clinical characteristics are summarized in Supplemental Digital Content 1. (See figure, Supplemental Digital Content 1, which shows demographic and clinical characteristics. <http://links.lww.com/PRSGO/C586>.) IMF incision was performed in 62 (63.3%) patients, whereas the remaining 36 (36.7%) patients underwent inverted-T incision. The patients in the two groups had similar age at the time of surgery ( $46.14 \pm 11.15$  versus  $45.17 \pm 10.30$ ;  $P = 0.766$ ). The mean follow-up period was longer for the inverted-T group, but the difference was not statistically significant ( $31.24 \pm 14.11$  versus  $30.84 \pm 12.13$ ;  $P = 0.912$ ). Almost all the prepectoral reconstructions in the two groups were performed with a single-stage, direct-to-implant approach (91.7% versus 80.6%;  $P = 0.243$ ). Synthetic mesh was used for IBBR in 13 (13.2%) patients (11.1% versus 14.5%,  $P = 0.763$ ). The rate of neoadjuvant chemotherapy (47.2% versus 38.7%;  $P = 0.524$ ), adjuvant radiotherapy (36.1% versus 25.4%;

$P = 0.359$ ), lymph node biopsy (63.9% versus 71%;  $p=0.504$ ), and axillary lymph node dissection (33.3% versus 22.6%;  $P = 0.342$ ) were not significantly different among the two groups. (See figure, Supplemental Digital Content 1, <http://links.lww.com/PRSGO/C586>.)

## COMPLICATIONS

The procedural complications are summarized in Table 1. Among the 98 patients, 25 (25.5%) had at least one complication. NAC necrosis was one of the most common postoperative complications occurring in a total of four patients (8.3% versus 1.61%;  $P = 0.139$ ). In the inverted-T group, three (8.3%) patients experienced NAC necrosis, which included three cases of partial NAC necrosis, and one case of full NAC necrosis. The IMF group had one (1.61%) partial NAC necrosis. The rates of hematoma (2.7% versus 0%;  $p=0.367$ ), skin necrosis (2.7% versus 4.84%;  $P=1.00$ ), seroma (5.5% versus 1.61%;  $P=0.552$ ), infection (5.5% versus 4.84%;  $P = 1.00$ ), and capsular contracture (5.5% versus 9.7%;  $P = 1.00$ ) were also comparable between the two groups.

**Table 1. Postoperative Complications**

Complication	Inverted-T (%) (n = 36)	IMF (%) (n = 62)	Total (%) (n = 98)	P
Overall complication	10 (27.8)	15 (24.2)	25 (25.5)	0.811
Hematoma	1 (2.7)	0	1 (1.02)	0.367
Skin necrosis	1 (2.7)	3 (4.84)	4 (4.08)	1.00
NAC necrosis*	3 (8.3)	1 (1.61)	4 (4.08)	0.139
Seroma	2 (5.5)	1 (1.61)	3 (3.06)	0.552
Infection	2 (5.5)	3 (4.84)	5 (5.1)	1.00
Implant loss	3 (8.3)	1 (1.61)	4 (4.08)	0.139
Local recurrence, n	2 (5.5)	3 (4.84)	5 (5.1)	1.00
Distant recurrence, n	1 (2.7)	1 (1.61)	2 (2.04)	1.00
Capsular contracture	2 (5.5)	6 (9.7)	8 (8.16)	1.00
Baker II	0	2 (3.22)	2 (2.04)	0.538
Baker III	1 (2.7)	3 (4.84)	4 (4.08)	1.00
Baker IV	1 (2.7)	1 (1.61)	2 (2.04)	1.00
Clavien-Dindo classification				
0	21 (58.3)	47 (75.8)	68 (69.4)	0.110
1	6 (16.7)	8 (12.91)	14 (14.3)	0.766
2	5 (13.9)	4 (6.45)	9 (9.2)	0.282
3	4 (11.1)	3 (4.84)	7 (7.1)	0.417

\*NAC, nipple-areola complex.

**Table 2. Postoperative Complications Based on PMRT**

Complication	Non-PMRT (%) (n = 70)				PMRT (%) (n = 28)			
	Total No. (%)	Inverted-T (n = 24) No. (%)	IMF (n = 46) No. (%)	P	Total No. (%)	Inverted-T (n = 12) No. (%)	IMF (n = 16) No. (%)	P
Hematoma	1 (1.42)	1 (4.2)	0 (0)	0.342	0 (0)	0 (0)	0 (0)	1.000
Skin necrosis	2 (2.86)	1 (4.2)	1 (2.17)	1.000	2 (7.14)	0 (0)	2 (12.5)	0.492
NAC necrosis	3 (4.29)	2 (8.3)	1 (2.17)	0.269	1 (3.57)	1 (8.3)	0 (0)	0.427
Seroma	2 (2.86)	1 (4.2)	1 (2.17)	1.000	1 (3.57)	1 (8.3)	0 (0)	0.427
Infection	2 (2.86)	0 (0)	2 (4.34)	0.543	3 (10.7)	2 (16.7)	1 (6.25)	0.560
Implant loss	1 (1.42)	1 (4.2)	0 (0)	0.343	3 (10.7)	2 (16.7)	1 (6.25)	0.560
Local recurrence, n	3 (4.29)	1 (4.2)	2 (4.34)	1.000	2 (7.14)	1 (8.3)	1 (6.25)	1.000
Distant recurrence, n	1 (1.42)	0 (0)	1 (2.17)	1.000	1 (3.57)	1 (8.3)	0 (0)	0.427
Capsular contracture	3 (4.29)	1 (4.2)	2 (4.34)	1.000	5 (17.9)	1 (8.3)	4 (25)	0.08
Baker II	2 (2.86)	0 (0)	2 (4.34)	0.543	0 (0)	0 (0)	0 (0)	1.000
Baker III	1 (1.42)	1 (4.2)	0 (0)	0.343	3 (10.7)	0 (0)	3 (18.8)	0.238
Baker IV	0 (0)	0 (0)	0 (0)	1.000	2 (7.14)	1 (8.3)	1 (6.25)	1.000

Implant loss was observed in a total of four patients, of whom three patients were from the inverted-T group (8.3% versus 1.61%;  $P = 0.139$ ). Two losses occurred after infection and complete NAC necrosis (both after adjuvant radiotherapy). One further patient had the implant removed after local cancer recurrence. In the IMF group, one patient (1.61%) had the implant removed because of full skin necrosis over the suture line.

As expected, the patients who received PMRT after prepectoral IBBR had higher rates of capsular contracture (4.29% versus 14.3%;  $P = 0.09$ ) and implant loss (1.42% versus 17.9%;  $P = 0.07$ ) than the nonradiated patients, although the difference was not significant (Table 2).

### ONCOLOGICAL OUTCOME

The median follow-up time was 31.24±14.11 months for the inverted-T group and 30.84±12.13 months for the IMF group. Local recurrence events were identified in five (5.1%) patients: two (5.5%) in the inverted-T group, and three (4.84%) in the IMF group. No significant difference in local recurrence was noted between the two incisions ( $P = 1.00$ ). The 3-year overall survival was 97.4% in inverted-T group and 98.5% in IMF group. Each group had one patient with distant recurrence.

### AESTHETIC OUTCOMES

Aesthetic outcomes were evaluated at an average of 2 years after mastectomy and IBBR using the postreconstruction module of the BREAST-Q questionnaires. Among the 98 women, the BREAST-Q scores on all domains were high for both groups (Table 3). There were no significant differences in BREAST-Q scores between the two groups for the satisfaction with breasts domain ( $P = 0.364$ ), psychosocial well-being domain ( $P = 0.162$ ), sexual well-being domain ( $P = 0.113$ ), and physical well-being domain ( $P = 0.696$ ).

### DISCUSSION

Nowadays, with an increasing rate of breast reconstruction after NSM, cosmetic satisfaction can be achieved more easily. The use of NSM followed by IBBR for

**Table 3. BREAST-Q: Postoperative Assessment**

Postoperative BREAST-Q Evaluation	Inverted-T (%) (n = 36)	IMF (%) (n = 62)	Total % (n = 98)	P
Satisfaction with breast (scale 0–100)	72.14±21.37	77.58±21.43	74.95±21.35	0.364
Psychosocial well-being (scale 0–100)	81.36±15.51	77.10±17.39	78.97±16.50	0.162
Sexual well-being (scale 0–100)	63.91±22.77	68.61±22.78	65.35±23.42	0.113
Physical well-being (scale 0–100)	56.42±25.24	61.80±30.08	58.65±28.09	0.696

surgical treatment of breast cancer has gained increased acceptance. However, patients who will undergo NSM and have ptotic breasts present a technical challenge for surgeons in terms of aesthetic outcomes and oncological safety.<sup>10,11</sup>

In this article, we present the feasibility of our most recent techniques for NSM followed by prepectoral IBBR in ptotic and nonptotic breasts. To our knowledge, the current study is the first to focus specifically on surgical techniques, aesthetic results, and oncological safety during the follow-up period (>31 months).

The selection of the implant plane during breast reconstruction has recently become a subject of debate.<sup>12,13</sup> Mostly, in our institution, we perform prepectoral IBBR. We believe that with adequate preoperative planning, prepectoral IBBR can be performed successfully in patients with ptotic and nonptotic breasts. Multiple studies have shown comparable results between prepectoral and subpectoral IBBR techniques. However, the mean number of complication was significantly higher in subpectoral IBBR.<sup>14–18</sup>

The use of acellular dermal matrices (ADMs) and synthetic meshes in IBBR is becoming more preferable every day, especially with promising opportunities for prepectoral single-stage placement. Early reports showed several benefits, including less skin flap necrosis and capsular contracture, less need for tissue expander, superior aesthetic



results, and lower reoperations rates.<sup>19,20</sup> Surgeons have started using ADMs and synthetic meshes in IBBR to avoid a theoretical increase in complication rates. However, the advantages of ADM and synthetic meshes have not been universally accepted, and additional causes for doubt have been created by reports concerning harm, specifically higher rates of infection and implant loss.<sup>21</sup> Eventually, in a randomized clinical trial, Lohmander et al<sup>22</sup> found that immediate IBBR with ADM did not yield fewer reoperations than conventional IBBR without ADM. Several studies also found no difference in IBBR with or without biological or synthetic mesh.<sup>23–25</sup> In our study, the combination of prepectoral IBBR with synthetic meshes was in 13 (13.2%) patients, when the pocket was too large for the planned implant (TiLOOP Bra Pocket).

The incision type is a very important factor for the skin flap and NAC necrosis rate in NSM. Daar et al<sup>26</sup> performed a systematic literature review and meta-analysis, including 51 studies with 9975 NSM, and identified that the IMF incision could be the preferred choice with fewer complications and better aesthetic outcome. IMF incision had a comparably low NAC necrosis rate of 6.82%. In our series, complications characterized by partial or full NAC necrosis were observed in 1.61% of the IMF and 8.3% of the inverted-T group, respectively ( $P = 0.139$ ). The reason for this difference could be that more patients in the inverted-T group had the NAC harvested as a free graft and grafted to the new location at the time of NSM, followed by prepectoral IBBR ( $P = 0.002$ ).

During NSM, due to breast cancer, the main aim is to achieve oncological safety. Surgeons are worried about the residual breast tissue left behind within the subcutaneous tissue as well as behind the nipple, especially in ptotic breasts. In fact, in the SKINI trial, Tausch et al<sup>27</sup> found that almost every second SSM or NSM had residual breast tissue in the subcutaneous tissue, with the most likelihood in NSM and behind the nipple. However, new evidence has shown that NSM is as oncologically safe as SSM. A recent study of 944 patients by Wu et al<sup>28</sup> reported 39 cases (4.1%) of cancer recurrence at the NAC. The 5-year cumulative incidence rate of cancer recurrence at the NAC was 3.5%. Another study by Galimberti et al<sup>29</sup> revealed that among 1989 patients, 36 (1.8%) had NAC recurrence. Overall survival at 5 years was 96.1% in women with invasive cancer and 99.2% in women with in situ disease. In our study, at a follow-up of 31 months, five (5.1%) local recurrences and two (2.04%) distant recurrences were observed. The three-year overall survival was 97.4% and 98.5% in the inverted-T and IMF groups.

PMRT is a well-known risk factor that increases the risk of complications and decreases aesthetic outcomes and quality of life after IBBR.<sup>30</sup> PMRT is necessary for locoregional recurrence control and to improve the overall survival rate in locally advanced breast cancer. Our findings showed that patients in the PMRT group had higher rates of implant loss ( $P = 0.07$ ) and capsular contracture ( $P = 0.09$ ), than nonirradiated patients. These results are consistent with previous studies.<sup>12,31</sup> Despite the advantages of prepectoral IBBR, we should be careful in selecting patients who are candidates for PMRT.

In the present study, we examined quality of life using the BREAST-Q subscales in women who underwent NSM with prepectoral IBBR. Patients reported high Q-scores in all four categories of the postreconstruction module of the BREAST-Q questionnaire (Table 3). We believe that preservation of the NAC increased the reported high Q-scores in both groups. However, we had a few patients with minor animation deformity and implant malposition (Fig. 3D), which are not reflected in the Q-scores. Despite minor complications, we found no significant differences in aesthetic outcomes between inverted-T and IMF incisions. This demonstrates that patients who are candidates for prepectoral IBBR and have ptotic breasts can achieve similarly high aesthetic outcomes with their reconstruction as patients with nonptotic breasts.

Study limitations include relatively small sample size and a retrospective analysis, although from a prospectively maintained database. Patients were not randomized to procedure types; consequently, our results may have been subject to confounding by unrecognized demographic or clinical covariates. Further high-quality multicenter prospective studies with a larger number of patients and a longer follow-up are necessary to verify these results.

## CONCLUSIONS

Our results suggest that inverted-T incision for ptotic breasts is a safe modality with similar complication rates and high aesthetic results compared with IMF incision for nonptotic breasts. A higher rate of NAC necrosis in the inverted-T group, although not significant, should be considered during careful preoperative planning and patient selection.

**Florian Fitzal, MD**

Breast Health Center  
Comprehensive Cancer Center Vienna  
21C Department of Surgery  
Medical University Vienna  
A-1090 Vienna, Waehringer Guertel 18-20  
E-mail: [florian.fitzal@meduniwien.ac.at](mailto:florian.fitzal@meduniwien.ac.at)

## DISCLOSURES

*Dr. Fitzal received personal honoraria and educational grants from Pfizer, Novartis, Roche, Astra Zeneca, Springer, Medtronic, and Bondimed. All the other authors have no financial interests to declare in relation to the content of this article. No funding was received for this study.*

## ACKNOWLEDGMENT

*The ethics committee of the Medical University of Vienna approved this study (no. 1597/2021).*

## REFERENCES

- Garcia-Etienne CA, Forcellini D, Sagona A, et al. Breast reconstruction: a quality measure for breast cancer care? *Breast*. 2012;21:105–106.
- Łukasiewicz S, Czezelewski M, Forma A, et al. Breast cancer—epidemiology, risk factors, classification, prognostic markers, and current treatment strategies—an updated review. *Cancers*. 2021;13:4287.

3. Krajewski AC, Boughey JC, Degnim AC, et al. Expanded indications and improved outcomes for nipple-sparing mastectomy over time. *Ann Surg Oncol*. 2015;22:3317–3323.
4. Woods JE. Detailed technique of subcutaneous mastectomy with and without mastopexy. *Ann Plast Surg*. 1987;18:51–61.
5. Rodriguez-Feliz J, Codner MA. Embrace the change: incorporating single-stage implant breast reconstruction into your practice. *Plast Reconstr Surg*. 2015;136:221–231.
6. Corso G, De Lorenzi F, Vicini E, et al. Nipple-sparing mastectomy with different approaches: surgical incisions, complications, and cosmetic results. Preliminary results of 100 consecutive patients at a single center. *J Plast Reconstr Aesthet Surg*. 2018;71:1751–1760.
7. De Bakker E, Rots M, Buncamper ME, et al. The Baker classification for capsular contracture in breast implant surgery is unreliable as a diagnostic tool. *Plast Reconstr Surg*. 2020;146:956–962.
8. Regnault P. Breast ptosis. Definition and treatment. *Clin Plast Surg*. 1976;3:193–203. PMID: 1261176.
9. Pusic AL, Klassen AF, Scott AM, et al. Development of a new patient-reported outcome measure for breast surgery: the BREAST-Q. *Plast Reconstr Surg*. 2009;124:345–353.
10. Jakub JW, Peled AW, Gray RJ, et al. Oncologic safety of prophylactic nipple-sparing mastectomy in a population with BRCA mutations. *JAMA Surg*. 2018;153:123–129.
11. Bennett KG, Qi J, Kim HM, et al. Comparison of 2-year complication rates among common techniques for postmastectomy breast reconstruction. *JAMA Surg*. 2018;153:901–908.
12. Sinnott CJ, Persing SM, Pronovost M, et al. Impact of postmastectomy radiation therapy in prepectoral versus subpectoral implant-based breast reconstruction. *Ann Surg Oncol*. 2018;25:2899–2908.
13. Ribuffo D, Berna G, De Vita R, et al. Dual-plane retro-pectoral versus pre-pectoral dti breast reconstruction: an italian multi-center experience. *Aesthetic Plast Surg*. 2021;45:51–60.
14. Ostapenko E, Nixdorf L, Devyatko Y, et al. Prepectoral versus subpectoral implant-based breast reconstruction: a systematic review and meta-analysis. *Ann Surg Oncol*. 2023;30:126–136.
15. King CA, Bartholomew AJ, Sosin M, et al. A critical appraisal of late complications of prepectoral versus subpectoral breast reconstruction following nipple-sparing mastectomy. *Ann Surg Oncol*. 2021;28:9150–9158.
16. Li L, Su Y, Xiu B, et al. Comparison of prepectoral and subpectoral breast reconstruction after mastectomies: a systematic review and meta analysis. *Eur J Surg Oncol*. 2019;45:1542–1550.
17. Nealon KP, Weitzman RE, Sobti N, et al. Prepectoral direct-to-implant breast reconstruction: safety outcome endpoints and delineation of risk factors. *Plast Reconstr Surg*. 2020;145:898e–908e.
18. Kappos EA, Schulz A, Regan MM, et al. Prepectoral versus subpectoral implant-based breast reconstruction after skin-sparing mastectomy or nipple-sparing mastectomy (OPBC-02/PREPEC): a pragmatic, multicentre, randomised, superiority trial. *BMJ Open*. 2021;11:e045239.
19. Salzberg CA, Ashikari AY, Berry C, et al. Acellular dermal matrix-assisted direct-to-implant breast reconstruction and capsular contracture: a 13-year experience. *Plast Reconstr Surg*. 2016;138:329–337.
20. Potter S, Browning D, Savović J, et al. Systematic review and critical appraisal of the impact of acellular dermal matrix use on the outcomes of implant-based breast reconstruction. *Br J Surg*. 2015;102:1010–1025.
21. Dikmans REG, Negenborn VL, Bouman M-B, et al. Two-stage implant-based breast reconstruction compared with immediate one-stage implant-based breast reconstruction augmented with an acellular dermal matrix: an open-label, phase 4, multicentre, randomised, controlled trial. *Lancet Oncol*. 2017;18:251–258.
22. Lohmander F, Lagergren J, Johansson H, et al. Effect of immediate implant-based breast reconstruction after mastectomy with and without acellular dermal matrix among women with breast cancer: a randomized clinical trial. *JAMA Network Open*. 2021;4:e2127806.
23. Reitsamer R, Peintinger F, Klaassen-Federspiel F, et al. Prepectoral direct-to-implant breast reconstruction with complete ADM or synthetic mesh coverage - 36-months follow-up in 200 reconstructed breasts. *Breast*. 2019;48:32–37.
24. DeLong MR, Tandon VJ, Bertrand AA, et al. Review of outcomes in prepectoral prosthetic breast reconstruction with and without surgical mesh assistance. *Plast Reconstr Surg*. 2021;147:305–315.
25. Sewart E, Turner NL, Conroy EJ, et al; implant Breast Reconstruction Evaluation (iBRA) Steering Group and the Breast Reconstruction Research Collaborative. Patient-reported outcomes of immediate implant-based breast reconstruction with and without biological or synthetic mesh. *BJS Open*. 2021;5:zraa063.
26. Daar DA, Abdou SA, Rosario L, et al. Is there a preferred incision location for nipple-sparing mastectomy? A systematic review and meta-analysis. *Plast Reconstr Surg*. 2019;143:906e–919e.
27. Papassotiropoulos B, GÜth U, Chiesa F, et al. Prospective evaluation of residual breast tissue after skin- or nipple-sparing mastectomy: results of the SKINI-Trial. *Ann Surg Oncol*. 2019;26:1254–1262.
28. Wu Z-Y, Kim H-J, Lee J-W, et al. Breast cancer recurrence in the nipple-areola complex after nipple-sparing mastectomy with immediate breast reconstruction for invasive breast cancer. *JAMA Surg*. 2019;154:1030–1037.
29. Galimberti V, Morigi C, Bagnardi V, et al. Oncological outcomes of nipple-sparing mastectomy: a single-center experience of 1989 patients. *Ann Surg Oncol*. 2018;25:3849–3857.
30. Ricci JA, Epstein S, Momoh AO, et al. A meta-analysis of implant-based breast reconstruction and timing of adjuvant radiation therapy. *J Surg Res*. 2017;218:108–116.
31. Awadeen A, Fareed M, Elameen AM. The impact of postmastectomy radiation therapy on the outcomes of prepectoral implant-based breast reconstruction: a systematic review and meta-analysis. *Aesth Plast Surg*. 2022;47:81–91.