

[CASE REPORT]

Ceritinib Treatment for Carcinomatous Meningitis with a Secondary Mutation at I1171T in Anaplastic Lymphoma Kinase

Hironori Ashinuma¹, Masato Shingyoji¹, Yuzo Hasegawa², Sana Yokoi³ and Yasushi Yoshida¹

Abstract:

The mechanisms underlying anaplastic lymphoma kinase (ALK) resistance have not been well investigated in clinical practice. We herein report the case of a lung cancer patient with carcinomatous meningitis who had an ALK I1171T resistance mutation revealed by direct DNA sequencing of the cerebrospinal fluid after treatment with cytotoxic chemotherapy, crizotinib, and alectinib. I1171T is considered to be sensitive to ceritinib. Although ceritinib was not effective initially, we chose ceritinib again after whole-brain radiotherapy and ventriculoperitoneal shunting. Although the response duration was short, spinal magnetic resonance imaging revealed a marked response. The identification of an acquired ALK resistance mutation will aid in choosing the optimum sequence therapy.

Key words: ALK, alectinib, ceritinib, I1171T, CSF

(Intern Med 57: 3153-3155, 2018)

(DOI: 10.2169/internalmedicine.0397-17)

Introduction

Although most anaplastic lymphoma kinase (ALK)-positive lung cancer patients respond to ALK tyrosine kinase inhibitors (TKIs), they ultimately relapse while undergoing therapy due to the emergence of drug resistance. Experimental approaches have led to the identification of several ALK TKI resistance mechanisms: 1) ALK-dependent mechanisms, including ALK secondary resistance mutations or amplification, where tumor cell dependence on ALK signaling persists; 2) ALK-independent mechanisms, including the activation of bypass tracks and lineage changes, where tumor cells effectively escape dependence on ALK; and 3) Others, including pharmacological properties of TKIs, especially cerebrospinal fluid (CSF) penetration (1).

ALK resistance mechanisms have not been well investigated in clinical practice, unlike those for epidermal growth factor receptor (EGFR)-TKI resistance. We herein report a case of alectinib resistance with a secondary ALK mutation at I1171T that was identified using a CSF analysis and

treated with ceritinib.

Case Report

A 36-year-old never-smoking woman was diagnosed with stage IV lung adenocarcinoma (left lower lobe nodule, multiple pulmonary metastases, and multiple bone metastases) without an EGFR mutation. She was treated with carboplatin, docetaxel, and bevacizumab, achieving partial response (PR). Six months later, the primary nodule and mediastinal lymph nodes had enlarged. She underwent ultrasound-guided transbronchial needle aspiration at the left inferior paratracheal station, and immunohistochemical staining revealed ALK gene rearrangement. Fluorescence *in situ* hybridization of the archived primary nodule specimens also revealed ALK gene rearrangement. Thereafter, she was treated with the ALK TKI crizotinib, achieving PR.

Approximately one year later, left pleural effusion developed, and carcinomatous pleurisy was confirmed by cytology. She was switched to treatment with cisplatin, pemetrexed, and bevacizumab. The primary tumor and left

¹Division of Respiratory Medicine, Chiba Cancer Center, Japan, ²Division of Neurological Surgery, Chiba Cancer Center, Japan and ³Division of Translational Genomics, Chiba Cancer Center, Japan

Received: October 24, 2017; Accepted: March 22, 2018; Advance Publication by J-STAGE: June 6, 2018

Correspondence to Dr. Hironori Ashinuma, hashinuma@chiba-cc.jp

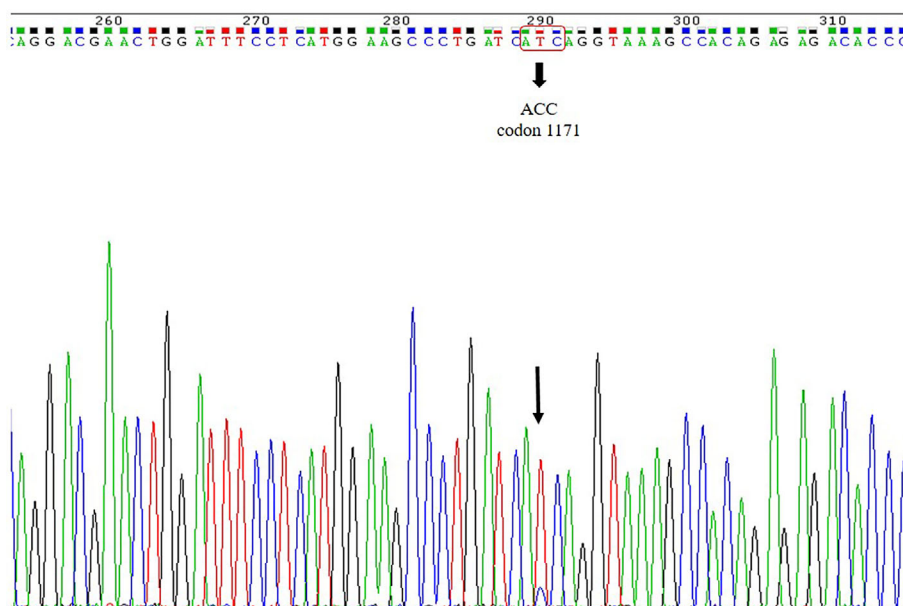


Figure 1. Direct sequencing of the cerebrospinal fluid after alectinib failure identified a secondary mutation of the anaplastic lymphoma kinase gene at codon 1171 (I1171T).

pleural effusion were controlled using maintenance therapy with pemetrexed and bevacizumab. However, approximately two years later, she developed diplopia. Although no brain metastasis was found on brain magnetic resonance imaging (MRI), CSF cytology revealed adenocarcinoma cells, thus confirming carcinomatous meningitis. She was then treated with the second-generation ALK TKI alectinib. Central nervous system (CNS) symptoms were controlled for approximately one year, but she developed headache, nausea, and failing eyesight. Brain and spinal MRI revealed worsened meningitis. She was switched to treatment with another second-generation ALK TKI ceritinib. Although brain MRI revealed a slight improvement after two weeks, her symptoms did not improve. Therefore, a CSF drainage system was inserted. Because thrombocytopenia developed, ceritinib had to be discontinued after a month. She was then treated with whole-brain radiotherapy (WBRT) (30 Gy/10 Fr) and underwent ventriculoperitoneal (VP) shunting.

Approximately two months after discontinuing ceritinib, her symptoms improved due to WBRT and the VP shunt. During that time, the ALK status in the CSF after exposure to ceritinib for 12 days was analyzed using direct DNA sequencing, revealing an ALK I1171T mutation (Fig. 1). Because the ALK I1171T mutation was reported to be sensitive to ceritinib (2), she was again treated with ceritinib, and spinal MRI revealed marked improvement (Fig. 2). Sites other than the CSF were stable initially and showed no changes after ceritinib treatment. However, G2 neutropenia developed, and ceritinib had to be discontinued after three weeks. Soon thereafter, urinary retention and paraplegia developed. Although a reduced dose of ceritinib (600 mg/body) was restarted, her symptoms worsened, and spinal MRI also revealed a worsened status.

Discussion

This is the seventh case report in the English literature to identify a missense mutation at isoleucine 1171 in ALK conferring resistance to alectinib (3-7) and the first case report to reveal to identify an I1171T mutation in CSF. I1171T is considered to be resistant to both crizotinib and alectinib, but sensitive to ceritinib (2). However, the response duration to ceritinib treatment was short in this case.

Alectinib treatment was able to control CNS symptoms for approximately one year, indicating I1171T emergence during the course of alectinib treatment, although we did not perform a rebiopsy after crizotinib failure. In EGFR-TKI failure, much lower frequencies of the resistance mutation T790M have been described in the CSF than in extracranial lesions (8). Lower CSF penetration rates of EGFR-TKI concentration have been reported (9), suggesting that EGFR-TKI failure in CNS may be due to EGFR-independent mechanisms. Crizotinib has a low CSF penetration rate (0.26%), whereas alectinib has a high rate (86%) (9). Therefore, alectinib was able to control carcinomatous meningitis for a long period in this case. However, because alectinib was able to penetrate the CSF, the resistance mutation in ALK may have occurred even in the CSF. Since the CNS was the only site of relapse after alectinib treatment in this case, the I1171T mutation was unlikely to have occurred at a site other than the CNS and then to have been carried to the CNS by metastasizing cancer cells.

Ceritinib is considered to be sensitive to I1171 (2, 3, 6). The I1171T mutation distorts the C-helix in ALK, shifting glutamic acid at 1167 to an inferior position, and this downward shift may disrupt the binding of alectinib to the I1171T mutant (3). However, compared with its potency toward wild-type ALK, ceritinib shows a slightly increased

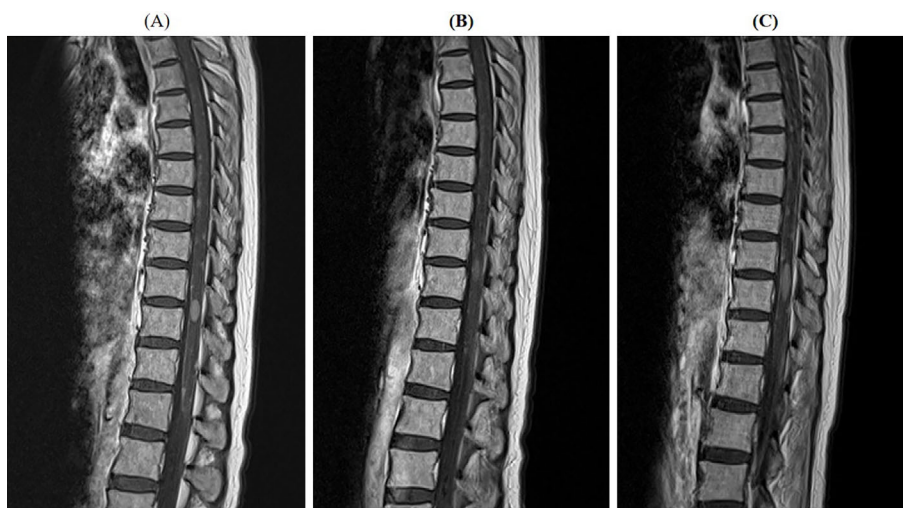


Figure 2. Spine magnetic resonance imaging showed multiple intramedullary metastases and meningeal dissemination before resuming ceritinib treatment (A). Three weeks after resuming ceritinib, the multiple intramedullary metastases and meningeal dissemination had markedly improved (B). However, after discontinuing ceritinib, the intramedullary metastases and meningeal dissemination worsened again (C).

potency toward I1171T (10). Ceritinib has a higher CSF penetration rate (15%) than that of crizotinib but a much lower rate than that of alectinib (9). Although ceritinib was not effective initially, the patient responded to retreatment. Although WBRT and VP shunting helped improve her symptoms, they did not seem to contribute to the changes in the spinal MRI findings; therefore, the change in the imaging findings was thought to be mainly due to the ceritinib treatment. However, WBRT and VP shunting might have altered the CSF penetration rate of ceritinib. In addition to the interruptions in ceritinib treatment due to its side effects, insufficient ceritinib levels in CSF may have contributed to the shorter response duration in the present patient.

In conclusion, this is the first case report that identified the I1171T ALK mutation in CSF after alectinib failure. Because alectinib has a relatively high CSF penetration rate, it was able to control carcinomatous meningitis for a prolonged period before a resistance mutation in ALK emerged. Although the ceritinib response duration was short due to insufficient penetration into the CSF in this case, the identification of an acquired ALK resistance mutation will aid in choosing the optimum sequence therapy.

The authors state that they have no Conflict of Interest (COI).

Acknowledgement

Writing assistance was provided by the International Medical Information Center, Translation Section. This service was paid for by internal funding.

References

- Lin JJ, Riely GJ, Shaw AT. Targeting ALK: precision medicine takes on drug resistance. *Cancer Discov* 7: 137-155, 2017.
- Lin YT, Yu CJ, Yang JC, Shih JY. Anaplastic lymphoma kinase (ALK) kinase domain mutation following ALK inhibitor(s) failure in advanced ALK positive non-small-cell lung cancer: analysis and literature review. *Clin Lung Cancer* 17: e77-e94, 2016.
- Katayama R, Friboulet L, Koike S, et al. Two novel ALK mutations mediate acquired resistance to the next-generation ALK inhibitor alectinib. *Clin Cancer Res* 20: 5686-5696, 2014.
- Ou SH, Klemptner SJ, Greenbowe JR, et al. Identification of a novel HIP1-ALK fusion variant in Non-Small-Cell Lung Cancer (NSCLC) and discovery of ALK I1171 (I1171N/S) mutations in two ALK-rearranged NSCLC patients with resistance to Alectinib. *J Thorac Oncol* 9: 1821-1825, 2014.
- Toyokawa G, Hirai F, Inamasu E, et al. Secondary mutations at I1171 in the ALK gene confer resistance to both Crizotinib and Alectinib. *J Thorac Oncol* 9: e86-e87, 2014.
- Ou SH, Greenbowe J, Khan ZU, et al. I1171 missense mutation (particularly I1171N) is a common resistance mutation in ALK-positive NSCLC patients who have progressive disease while on alectinib and is sensitive to ceritinib. *Lung Cancer* 88: 231-234, 2015.
- Ou SH, Milliken JC, Azada MC, Miller VA, Ali SM, Klemptner SJ. ALK F1174V mutation confers sensitivity while ALK I1171 mutation confers resistance to alectinib. The importance of serial biopsy post progression. *Lung Cancer* 91: 70-72, 2016.
- Li YS, Jiang BY, Yang JJ, et al. Leptomeningeal metastases in patients with NSCLC with EGFR mutations. *J Thorac Oncol* 11: 1962-1969, 2016.
- Bui N, Woodward B, Johnson A, Husain H. Novel treatment strategies for brain metastases in non-small-cell lung cancer. *Curr Treat Options Oncol* 17: 25, 2016.
- Ni Z, Zhang TC. Computationally unraveling how ceritinib overcomes drug-resistance mutations in ALK-rearranged lung cancer. *J Mol Model* 21: 175, 2015.

The Internal Medicine is an Open Access journal distributed under the Creative Commons Attribution-NonCommercial-NoDerivatives 4.0 International License. To view the details of this license, please visit (<https://creativecommons.org/licenses/by-nc-nd/4.0/>).