

Implantation of a leadless cardiac pacemaker for recurrent pocket infections



Philip M. Chang, MD, FHRS, CEPS, Rahul N. Doshi, MD, FHRS, FACC

From the Keck School of Medicine of University of Southern California (USC), Keck Medical Center of USC, Los Angeles, California.

Introduction

Infections involving cardiovascular implantable electronic devices (CIEDs) remain an unfortunate indication for repeated device-related procedures, including extractions and reimplantations.¹ Recurrent infections involving transvenous leads and superficial device pockets may eventually lead to epicardial lead implantation and generator placement in deeper tissue planes, both of which require a more invasive surgical approach. We present a unique case of a patient with recurrent CIED-related pocket infections involving both transvenous and epicardial pacing systems that was ultimately addressed with implantation of an investigational leadless cardiac pacemaker.

Case report

A 35-year-old patient with congenital complete heart block and Hansen's disease (leprosy, infection with *Mycobacterium leprae*) has been followed for years in our institution's device program. While the patient's conduction disorder resulted in pacemaker dependency, the coexisting Hansen's disease resulted in extreme skin and soft tissue fragility, which predisposed to skin breakdown, device erosion, secondary bacterial infections, and sepsis (Figure 1).

The patient had prior transvenous pacing systems and leads, all of which became infected following pocket site breakdown and subsequent bacteremia and sepsis. Each occurrence was managed in accordance with accepted treatment guidelines. Multiple reimplantations with transvenous systems at alternate sites ensued following initial infection clearance, only to require explant owing to repeated infections. Eventually, a single-chamber (VVI) epicardial pacing system was implanted with special attention given to implanting the pulse generator and proximal lead slack under the rectus muscle. This system unfortunately suffered a similar fate as prior pacemakers, necessitating surgical

removal. Given the patient's successful clearance of infections with appropriate antimicrobial therapy, and to reduce risk of developing antibiotic-resistant organisms, chronic prophylactic antibiotic therapy was never recommended. Further consideration of surgical epicardial device reimplantation was deferred in favor of exploring alternative management strategies. Conservative management without device reimplantation was not considered suitable, given the patient's baseline wide complex escape rhythm of only 20 beats per minute. In a chronic VVI paced state, transthoracic echocardiogram demonstrated a left ventricular ejection fraction of 45%–50%. The Nanostim leadless cardiac pacemaker (St Jude Medical, Sylmar, CA) was proposed as the best option for providing permanent pacing support with theoretically less risk of CIED infection, given that the pacemaker is entirely confined to the right ventricular (RV) cavity without communication with the skin or superficial soft tissues.

Given that the device was still under investigational study (NIH clinical trial identifier NCT02030418), as well as the proposed off-label indication for its implantation in this case, compassionate use approval was requested from the U.S. Food and Drug Administration and our local institutional review board to implant the leadless pacemaker in this patient. While awaiting approval, the patient was supported with temporary pacing systems using a traditional active fixation pacing electrode connected to an external pulse generator. Allergy skin testing to standard pacemaker component materials including nickel was also performed to confirm absence of an allergic response as a possible explanation for the patient's condition.

After compassionate use approval was received, the patient underwent standard implantation of the leadless pacemaker without complication (Figure 2). The device was implanted using its delivery ensemble via the right femoral vein following contrast injections demonstrating lower systemic venous patency and RV cavity size and borders. The device was fixated and deployed at the apical RV septum. Initial pacing threshold was 0.75 volts at 0.4 ms pulse width with an impedance of 600 ohms. Sensed native escape rhythm R waves were 12 mV in amplitude. The device was programmed to a VVIR mode at 60 beats per

KEYWORDS Cardiovascular implantable electronic devices; Infection (Heart Rhythm Case Reports 2016;2:339–341)

Address reprints and correspondence: Philip M. Chang, Keck School of Medicine of University of Southern California (USC), Keck Medical Center of USC, 1510 San Pablo St, Suite 322, Los Angeles, CA 90033. E-mail address: philip.chang@med.usc.edu.

KEY TEACHING POINTS

- Infections involving cardiovascular implantable electronic devices (CIEDs) remain a challenging problem causing significant morbidity, mortality, and need for reintervention in recipients.
- The leadless pacemaker provides reliable single-chamber pacing while eliminating complications related to transvenous leads and reducing infection risks, given its placement entirely within the heart.
- Implanting physicians should be aware of scenarios where novel CIED technologies can potentially be applied to address unusual circumstances and complications.

minute, and the patient was discharged home on postprocedure day 1. On subsequent ambulatory visits, pacing function and device location have remained satisfactory, with an excellent pacing threshold of 0.5 V at 0.4 ms at 1 year postimplantation. The patient has shown no evidence of cutaneous or systemic infection and has resumed all normal activity.

Discussion

The presented case represents a highly unusual and rare set of circumstances in a patient requiring permanent pacemaker support. Conventional approaches to addressing and circumventing recurrent CIED infections, specifically involving the device pocket, were not effective in preventing repeated occurrences, given a primary infectious and dermatologic condition that predisposed to secondary bacterial infections. Repeated infections were not due to poor implantation

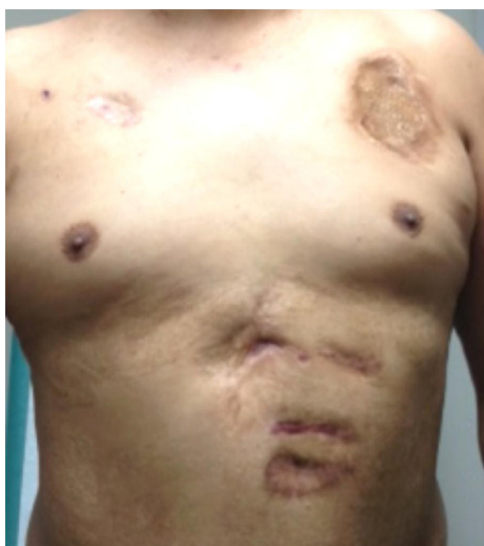

Figure 1 Photograph of patient's chest and abdomen demonstrating significant scarring in both the left and right chest walls and abdomen from prior pacemaker implantation and removal secondary to recurrent device erosions and infections.

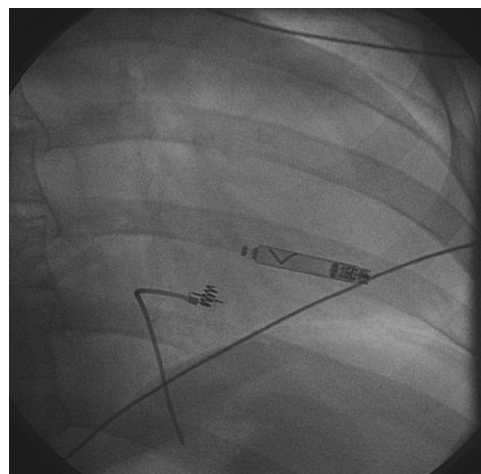


Figure 2 Fluoroscopic image of final leadless pacemaker position at the distal septal aspect of the right ventricular cavity. A retained fragment of a previously placed (and subsequently removed) epicardial pacing lead is also present.

technique, poor wound care following implantation, or intentional efforts to cause infection.

The incidence of infections involving CIEDs has steadily increased over time, owing to a continually increasing number of CIED recipients, longer cumulative time living with CIEDs, and implantation in patients with risk factors that predispose to infection. In a contemporary survey on the incidence of CIED infections using a Nationwide Inpatient Sample (NIS) discharge records query, Greenspon et al² found an incidence of infection of 1.61% over a 16-year period (1993–2008). The annual rate of infection rose dramatically between 2004 and 2008 (1.53% in 2004 to 2.41% in 2008), coinciding with a substantial increase in placement of implantable defibrillators. With its associated risks of significant complications, morbidity, and mortality, endocarditis is seen in approximately 10% of pacemaker-related infections. Infection risk is further augmented in the presence of recognized patient-related risk factors including heart failure, renal dysfunction, diabetes mellitus, and respiratory failure. Finally, it has also been demonstrated that CIED explant owing to infection is substantially higher with greater numbers of CIED-related procedures, including generator replacement.³ The costs of managing CIED-related infections, including long-duration antimicrobial therapy, hospitalization, and invasive procedures including extractions and CIED reimplantation, is nothing short of substantial.

Recurrent pocket infection in the same patient is an unusual situation, particularly if guideline-based management at the time of CIED infection is undertaken with appropriate removal of infected hardware, appropriate duration of antimicrobial therapy, and appropriate timing of and approach to CIED reimplantation. In general, with confirmed CIED pocket infections, removal of all implanted hardware including leads is recommended, along with reimplantation at an alternate site distant from the site of infection.¹ In addition to our patient's condition, which predisposed to significant skin and soft tissue fragility as the dominant risk

factor for repeated infection, other conditions may also predispose to a higher risk of repeated pocket infections, including patients with CIEDs and extensive burn injury, as well as immunocompromised and malnourished patients with diminished skin integrity and increased risk of colonization and secondary infection with unusual microorganisms.^{4,5} In such patients, these conditions significantly alter natural, physical barrier protections against infection and dramatically impair the systemic immune response to infection containment and treatment.

Implantation of the Nanostim leadless pacemaker is currently performed in patients meeting a standard indication for a VVI(R) pacemaker as outlined in the 2012 ACC/AHA/HRS/ESC published guidelines.⁶ Early implant experience has been favorable in terms of implant safety and success and short-term follow-up of device performance.⁷ Off-label implantation in this presented case was requested, as there is no current recommended indication for the leadless pacemaker in individuals with recurrent infections. While there is insufficient comparative data evaluating CIED infections associated with traditional CIED implants (with both epicardial and transvenous leads) vs the leadless pacemaker, one would assume that the infection risk should be substantially lower with the leadless device, given its lack of direct communication and contact with subcutaneous tissue. Dual-chamber pacing^{8–10} or even cardiac resynchronization therapy, given depressed left ventricular ejection fraction,¹¹ would be more ideal pacing strategies in the context of this patient's conduction disease. However, the leadless pacemaker was considered to have the most ideal technological properties to address the risk of recurrent infection in this patient's difficult set of circumstances and to allow for reliable, permanent pacing support.

There are approximately 200,000 new cases of infection with *M leprae* or Hansen's disease (leprosy) worldwide and 150 new cases in the United States annually. Infection primarily involves the skin and peripheral nerves. Alterations in local immune response in affected tissues, primarily in the dermis, can cause "reactions" that result in the classic cutaneous manifestations of the disease.¹² We presume that this is the underlying mechanism for this patient's susceptibility to CIED pocket infections.

Conclusion

Progress in CIED technology has yielded devices that can provide cardiac rhythm support with expectations of minimizing or eliminating problems encountered with transvenous leads, including lead failure, venous obstruction, loss or absence of venous access, and infection. While this case is representative of a very small subset of patients, it demonstrates an expanded opportunity for novel applications of emerging CIED technology and will hopefully encourage further development.

References

1. Baddour LM, Epstein AE, Erickson CC, et al. AHA Scientific Statement: update on cardiovascular implantable electronic device infections and their management. a scientific statement from the American Heart Association. *Circulation* 2010;121:458–477.
2. Greenspon AJ, Patel JD, Lau E, Ochoa JA, Frisch DR, Ho RT, Pavri BB, Kurtz SM. 16-year trends in the infection burden for pacemakers and implantable cardioverter-defibrillators in the United States. *J Am Coll Cardiol* 2011;58:1001–1006.
3. Johansen JB, Jørgensen OD, Møller M, Arnsbo P, Mortensen T, Nielsen JC. Infection after pacemaker implantation: infection rates and risk factors associated with infection in a population-based cohort study of 46299 consecutive patients. *Eur Heart J* 2011;32:991–998.
4. Church D, Elsayad S, Reid O, Winston B, Lindsay R. Burn wound infections. *Clin Microbiol Rev* 2006;19:403–434.
5. Stevens DL, Bisno AL, Chambers HF, Everett ED, Dellinger P, Goldstein EJC, Gorbach SL, Hirschmann JV, Kaplan EL, Montoya JG, Wade JC. Practice guidelines for the diagnosis and management of skin and soft-tissue infections. *Clin Infect Dis* 2005;41:1373–1406.
6. Epstein AE, DiMarco JP, Ellenbogen KA, et al. ACCF/AHA/HRS focused update incorporated into the ACCF/AHA/HRS guidelines for device-based therapy of cardiac rhythm abnormalities. *J Am Coll Cardiol* 2012;2013(61):e6–75.
7. Reddy VY, Exner DV, Cantillon DJ, et al. Percutaneous implantation of an entirely intracardiac leadless pacemaker. *N Engl J Med* 2015;373:1125–1135.
8. Andersen HR, Thuesen L, Bagger JP, Vesterlund T, Thomsen PE. Prospective randomized trial of atrial versus ventricular pacing in sick-sinus syndrome. *Lancet* 1994;344:1523–1528.
9. Lamas GA, Lee KL, Sweeney MO, Silverman R, Leon A, Yee R, Marinichak RA, Flaker G, Schron E, Orav EJ, Hellkamp AS, Goldman L, for the Mode Selection Trial in Sinus-Node Dysfunction. Ventricular pacing or dual-chamber pacing for sinus-node dysfunction. *N Engl J Med* 2002;346:1854–1862.
10. Gillis AM, Russo AM, Ellenbogen KA, Swerdlow CD, Olshansky B, Al-Khatib SM, Beshai JF, McComb JM, Nielsen JC, Philpott JM, Shen WK. HRS/ACCF expert consensus statement on pacemaker device and mode selection. *Heart Rhythm* 2012;9:1344–1365.
11. Yu CM, Chan JY, Zhang Q, Omar R, Yip GW, Hussin A, Fang F, Lam KH, Chan HC, Fung JW. Biventricular pacing in patients with bradycardia and normal ejection fraction. *N Engl J Med* 2009;361:2123–2134.
12. Legendre DP, Muzny CA, Swiatlo E. Hansen's disease (leprosy): current and future pharmacotherapy and treatment of disease-related immunologic reactions. *Pharmacotherapy* 2012;32:27–37.