

Original Article

Connective tissue graft vs. emdogain: A new approach to compare the outcomes

Ferena Sayar¹, Nasrin Akhundi², Sanaz Gholami³

¹Department of Periodontology, Islamic Azad University, Dental Branch, Tehran, Iran, ²Department of Mathematics, South Tehran Branch, Islamic Azad University, ³Dentist, Private Practice, Tehran, Iran

ABSTRACT

Background: The aim of this clinical trial study was to clinically evaluate the use of enamel matrix protein derivative combined with the coronally positioned flap to treat gingival recession compared to the subepithelial connective tissue graft by a new method to obtain denuded root surface area.

Materials and Methods: Thirteen patients, each with two or more similar bilateral Miller class I or II gingival recession (40 recessions) were randomly assigned to the test (enamel matrix protein derivative + coronally positioned flap) or control group (subepithelial connective tissue graft). Recession depth, width, probing depth, keratinized gingival, and plaque index were recorded at baseline and at one, three, and six months after treatment. A stent was used to measure the denuded root surface area at each examination session. Results were analyzed using Kolmogorov-Smirnov, Wilcoxon, Friedman, paired-sample *t* test.

Results: The average percentages of root coverage for control and test groups were 63.3% and 55%, respectively. Both groups showed significant keratinized gingival increase ($P < 0.05$). Recession depth decreased significantly in both groups. Root surface area was improved significantly from baseline with no significant difference between the two study groups ($P > 0.05$). The results of Friedman test were significant for clinical indices ($P < 0.05$), except for probing depth in control group ($P = 0.166$).

Conclusion: Enamel matrix protein derivative showed the same results as subepithelial connective tissue graft with relatively easy procedure to perform and low patient morbidity.

Key Words: AutoCAD software, connective tissue, enamel matrix proteins, gingival recession/surgery, grafts, root coverage

Received: April 2012
Accepted: September 2012

Address for correspondence:
Dr. Ferena Sayar,
Department of
Periodontology, Islamic Azad
University, Dental Branch,
Tehran, Iran.
E-mail: sayar_f@yahoo.com

INTRODUCTION

Primary goals of mucogingival surgery have changed with time. For many years, the free gingival graft was considered as a widely used, versatile and predictable mucogingival surgical procedure. Its main objective was to increase the apical-coronal dimension of keratinized tissue to extend the vestibular fornix, to dissipate muscle pull, and to provide an adequate zone of attached

gingiva to maintain gingival health and to prevent gingival recession to occur. Once it was shown that periodontal health could be maintained even without gingiva, as long as good plaque control was maintained; the goals of the treatment of gingival recession have changed from preventing further progression of gingival recession to achieving predictable root coverage to solve patients' esthetic demands, root sensitivity, decrease potential for root caries.^[1,2]

The exposure of root surfaces maybe due to periodontal diseases, mechanical forces such as faulty tooth brushing, iatrogenic factors such as orthodontic movement, poor restorations, and anatomical factors such as tooth malposition and frenum pull.^[3]

Several surgical techniques have been described to cover the root: Lateral or pedicle sliding flap that has

Access this article online



Website: www.drj.ir

several limitations there should be adequate dimension of gingival tissue lateral to the site of recession and the area to be treated should be localized. The advantage of this procedure is in the esthetics because the color match is ideal.

The coronally positioned flap (CPF) is another surgical technique used with many variations. This technique is limited by the amount of height and thickness of the gingival tissues; however, the resulting esthetics are usually good and can be used to treat localized or generalized recession defects.^[4] This technique was shown to be a predictable method for recession coverage with apparently satisfactory esthetic results. This is a relatively easy procedure for the clinician to perform and for the patient due to reduced morbidity because donor tissue need not be procured.^[2,3] This technique has been performed with or without use of root conditioners such as citric acid or tetracycline.^[5]

A CPF with an adjunctive subepithelial connective tissue graft (CTG) is also used in treating gingival recession. The removal of a CTG results in only minor palatal denudation. This technique usually results in a good color blend of the augmented area and increased graft vascularization from the underlying periosteum and the overlying flap to the graft.^[4] CPF + CTG have demonstrated great predictability and versatility, even when treating severe recessions and thin tissues. Sometimes a second surgery is needed to reduce thickness and obtain a good esthetic result.^[6] A histological study showed that recessions treated by CPF + CTG can partially heal with regeneration.^[7] This technique appears to offer significant improvement in predictability.^[8] Current literature indicates that the CTG offers increased predictability.^[9] This procedure has a high degree of success and predictability on teeth that present with Miller cl I and II gingival recession.^[10]

Guided tissue regeneration (GTR) is based on the principle of guiding various cells to proliferate and to form new periodontal tissues during healing through the use of resorbable or non-resorbable membrane. This technique has been used to treat localized gingival recession defects.^[4] Several problems have arisen with the membrane technique. These included the technical difficulties in optimally placing the barrier, membrane exposure in the course of healing, and possible damage of the newly formed tissue due to membrane removal or absorption.^[6]

Enamel matrix derivative (EMD) preparation consists of a group of proteins thought to be important in

the development of the dental organ, particularly as it relates to the formation of cementum, periodontal ligament, and alveolar bone.^[10] A major component of the EMD, amelogenin has been shown by immunohistochemistry to be expressed in human teeth not only in enamel formation, but also in root formation. When mesenchymal cells of the dental follicle are exposed to the enamel matrix, a non-cellular hard tissue matrix is formed on the enamel surface. A commercially available product, Emdogain, consists of amelogenins that are extracted from developing embryonal tooth buds of porcine origin.^[4] It has been shown that EMD enhances the proliferation and protein production by human periodontal ligament cells *in vitro*. It has also been tested as a periodontal regenerative treatment modality in animals and humans and was shown to be safe and effective on improving clinical attachment levels and radiographic bone fill. Human biopsy reports revealed that true periodontal regeneration could be achieved with topical application of EMD.^[10] Two histological studies showed formation of new cementum, organizing PDL fibers, and newly formed woven bone after treating recession by CTG + EMD or CPF + EMD.^[9,10]

Root coverage outcomes in almost all studies are based on linear measurement of the recession depth and recession width obtained by a periodontal probe. Today, by use of different software programmes, a new horizon to diagnosis and treatment plan in periodontics has been opened. AutoCAD is a software programme that could be used for obtaining two-dimensional views in the treatment of gingival recession.^[11]

The aim of the present prospective, randomized, split-mouth, clinical study on teeth with Miller cl I or II gingival recession was to clinically evaluate the use of EMD in association with CPF to cover gingival recession compared to subepithelial CTG alone. The covered surface area was obtained and compared by AutoCAD programme for the first time.

MATERIALS AND METHODS

Thirteen non-smoking patients (eight females and five males) aged 16-52 years (40.6 ± 12.5) with two or more similar bilateral Miller cl I or II gingival recessions of ≥ 3 mm and ≥ 3 mm width on incisors, canines, or premolars were selected among patients referred to the periodontics department of

Islamic Azad University-Dental branch and private periodontal clinic. Twenty pairs of gingival recession were treated. Before therapy, all patients agreed to participate in the study signed a written informed consent according to ethical principles No 12053 Islamic Azad University-Dental branch. Inclusion criteria were that vital teeth free from decay, crown, or buccal restorations, no radiographic signs of periapical infection, no occlusal trauma, no previous periodontal surgery in the area.

All patients were healthy, not taking any medication, pregnant, and/or lactating women were excluded from the study. All patients received oral hygiene instructions associated with full mouth scaling. One patient refused to continue the study. Therefore, eighteen pairs of gingival recessions fulfilled the 6 months examination.

Clinical evaluation

One clinician blinded to the surgical procedure collected the pre-and post-operative data. The clinical parameters evaluated with Williams Probe at baseline, 1, 3, 6 months were as follows:

Recession depth (RD)

Distance between the cement enamel junction (CEJ) and the gingival margin measured at the mid-buccal aspect of the tooth.

Recession width (RW)

Distance between the mesial and distal aspects of the gingival margins of the tooth measured in a horizontal direction at the level of the mid-buccal point of the CEJ.

Keratinized tissue (KG)

Distance between the gingival margin and the MGJ.

Clinical attachment level (CAL)

Distance between the CEJ and the bottom of the pocket measured at the mid-buccal aspect of the tooth.

Probing depth (PD)

Distance between the gingival margin and the bottom of the pocket measured at the level of the mid-buccal point of the CEJ. All measurements rounded up to the nearest millimeter.

Plaque index (PLI)[O'leary]

The teeth surfaces which were coloured by the disclosing agent were calculated and divided by total teeth surfaces multiplied by 100.

An alginate impression was taken at baseline and an

acrylic stent was made, according to mesial-distal dimension of the tooth under treatment, three to five grooves were made on the stent by a thin cylindrical bur at mid-buccal, mesial and distal line angles and at 1.5 mm from mesial and distal line angles toward mid-buccal in order to measure the recession depth in several points at base line and follow-up visits. The measured pre-operative points on the stent were processed by the AutoCad programme and «Points» and «Spline» rules were used to make a curved line. This line showed the pre-operative gingival margin position. New gingival margin position at follow-up intervals (1, 3, 6 months) were made by the aforementioned rules. «Boundary» rule was used to make an area between the curved lines at different interval examinations and the pre-operative curved line. This area, which is referred to the covered root surface after treatment was measured by the «Region» and «Area» rules. In other words, these points were used to make an area of the recession defect by the Autocad programme and changes of the area over time could be assessed and calculated by overlapping the figures obtained at different follow-up examinations [Figure 1].

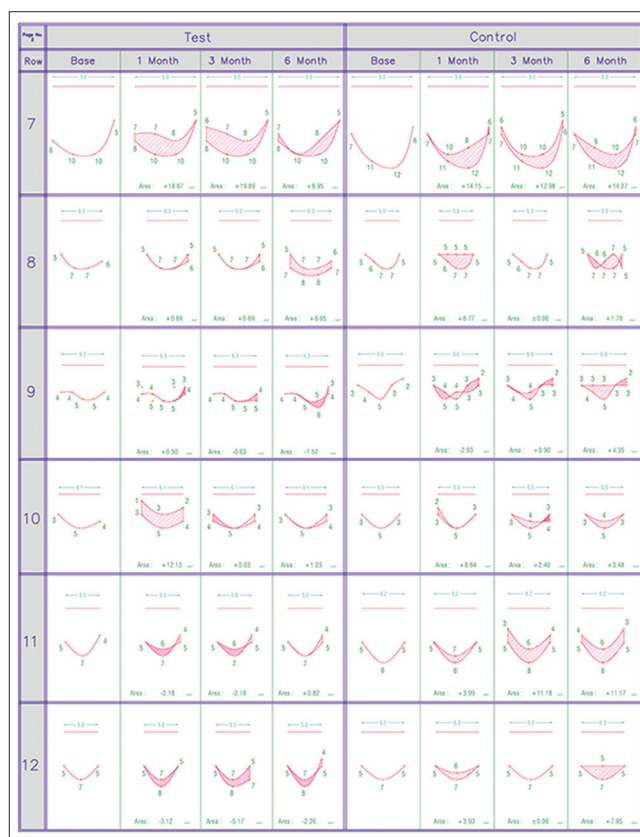


Figure 1: Root surface area coverage by AutoCAD evaluation from baseline to 6 month

Surgical procedure

Pre-operative photographs of the cases and surgical procedures were performed between September 2008 and June 2009. In each patient, the tooth with gingival recession was randomly assigned to one of the surgical procedures. Randomization was performed by coin toss. Surgical procedures were performed by one clinician with over 10 years of clinical experience in periodontal surgery. The test treatment consisted of a CPF technique plus EMD. Before elevation of the flap, the exposed and the intrasulcular root surfaces were gently scaled and planed with Gracy curettes. After local anesthesia with Lidocaine 1:80000, a no. 15 blade was used to make intrasulcular incision on the buccal aspect of the tooth. The incision was extended horizontally up to the adjacent tooth both mesial and distal to the involved tooth or teeth at the level of the CEJ. Two oblique releasing incisions were carried out from the mesial and distal extremities of the horizontal incisions across the mucogingival junction reaching the alveolar mucosa. A trapezoidal partial thickness flap was raised and the root surface was scaled and debrided with hand instruments

properly. The papillae adjacent to the involved tooth were deepithelialized to create a connective tissue bed. For the test group, the root surface was conditioned with 24% EDTA gel (prefgel, emdogain) for two minutes to remove the smear layer and to obtain a surface devoid of organic debris. The root surfaces was copiously rinsed with normal saline.

EMD (straumann, swiss) was then applied, starting from the most apical bone level and covering the entire root surface. The CPF was secured coronally slightly above the CEJ and sutured tension free with 5/0 silk suture along the vertical and horizontal initial incisions [Figures 2 and 4].

On the control tooth, a trapezoidal partial thickness flap with vertical incisions was elevated on the buccal surface of the tooth and the root was scaled and planed with curet. A CTG was harvested from the maxillary palate and positioned with 5/0 resorbable suture. Then, the flap was sutured with 5/0 silk over the CTG. Some coronal repositioning was always carried out, but there was no intent to cover the whole graft [Figures 3 and 5].

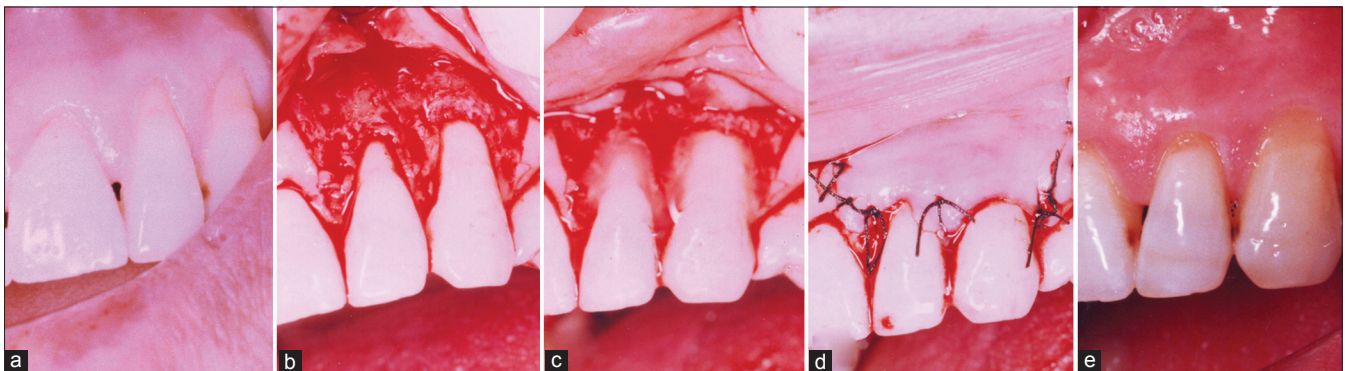


Figure 2: (a) Test site^[22,23] at baseline, (b-d) during surgery, (e) after 6 months

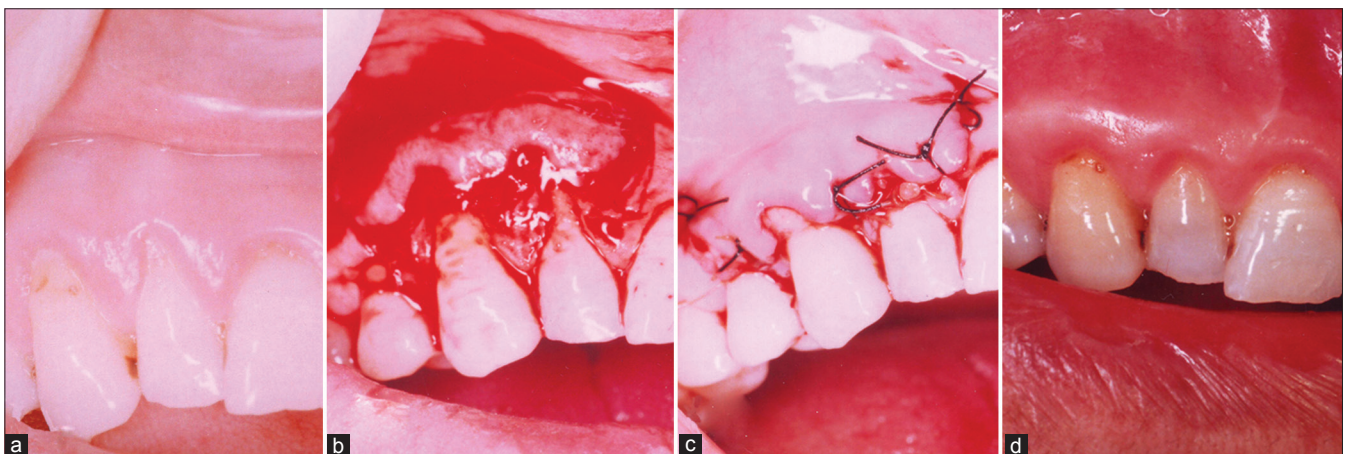


Figure 3: (a) Control site^[12,13] at baseline, (b, c) during surgery, (d) after 6 months

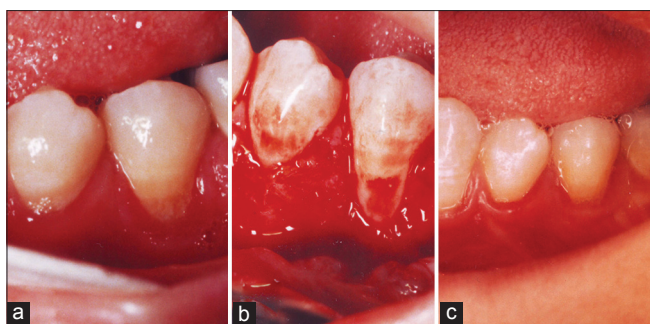


Figure 4: (a) Test site^[35] at baseline, (b) during surgery, (c) after 6 months

Post-operative care was similar for both groups: Patients were instructed to discontinue tooth brushing and flossing in the treated areas for the first four weeks, during this period the patients used of chlorhexidine 2% mouth wash twice daily, analgesics were prescribed when necessary.

Suture removal was done after two weeks and after four weeks the patients were instructed to brush with a soft toothbrush. Measurements and photographic documentation were obtained presurgically and after 1, 3, 6 months postoperatively. At these visits, oral hygiene instruction were reviewed and prophylaxis was performed.

Statistical method

Summary statistical measures (mean, standard deviation) were calculated for clinical indices. Distribution normality assumptions for clinical indices were assessed by the Kolmogorov-Smirnov test. For comparison of clinical indices between groups paired-sample *t* test was used. In some comparisons when normality would not hold, non-parametric Wilcoxon and Friedman test were used. The level of statistical significance was established at $P \leq 0.05$.

RESULTS

The result of paired-sample *t* test in baseline was not significant ($P > 0.05$). The value of clinical parameters at the baseline and 6-month examinations in both treatment groups are reported in [Table 1].

Percentage of root coverage obtained for control and test sites was evaluated. At the end of 6 months, 63.3% of the root surfaces treated with CTG were covered, whereas 55% of the root surfaces treated with CPF + EMD were covered. The result of paired-sample *t* test in percentage of root coverage in control and test

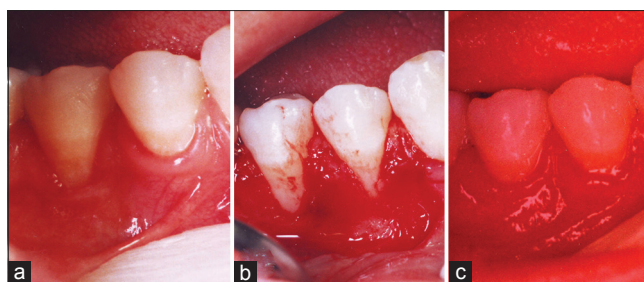


Figure 5: (a) Control site^[45] at baseline, (b) during surgery, (c) after 6 months

group was significant ($P = 0.001 < 0.05$), percentage of root coverage in the control was better than the test group.

The other width under investigation was the change in width of the recession defects. At the end of 6 months, 56.5% of the root surfaces in the control group were covered, whereas 60% of the root surfaces in the test group were covered. This difference was statistically better for the test group ($P = 0.001$).

In the test group, recession depth (RD) decreased from $3.05 \pm 0.97\text{mm}$ at baseline to $1.39 \pm 1.29\text{mm}$ at 6 months, corresponding to a root coverage of $48.81\% \pm 45.51\%$.

At the control sites, RD shrank from $3 \pm 1.247\text{mm}$ at baseline to $1.17 \pm 1.2\text{mm}$ at 6 months, corresponding to a root coverage of $61.65\% \pm 43.37\%$. There was no significant difference between the groups ($P = 0.206$) [Table 1].

RW was also significantly reduced in both groups, although with no difference between them ($P = 0.79$) [Table 1].

No significant difference in the width of keratinized gingival (KG) was found between the test and control groups at six months ($P = 0.166$) [Table 1].

At the test sites, PD changed from $1.63 \pm 0.684\text{mm}$ to $1.06 \pm 0.24\text{mm}$ representing a reduction of $0.57 \pm 0.698\text{mm}$. In the control group, PD changed from $1.526 \pm 0.611\text{mm}$ to $1.28 \pm 0.46\text{mm}$.

Equal to a reduction of $0.246 \pm 0.894\text{mm}$. The changes were significant within the test group ($P = 0.005$), but between the groups, the changes were not significant ($P = 0.102$) [Table 2].

Stent measurements showed no significant difference between the study groups at all time intervals ($P = 0.09$). However, the values were slightly better for the control group at 6 months [Table 3].

Table 1: Clinical variables (RD, RW, KG) at baseline and at postoperative intervals in both treatment groups (split-mouth design, n=18); data are expressed in mm (mean±SD)

Time (months)	Groups	RD	P value	RW	P value	KG	P value
Base	Control	3±1.247	0.655	3.526±0.9	0.429	2.63±1.86	0.38
	Test	3.05±0.97		3.63±0.895		2.47±1.837	
1	Control	1.26±1.326	0.272	1.68±1.56	0.767	4.58±1.77	0.05
	Test	1±1.29		1.58±1.57		3.63±2.166	
3	Control	1.58±1.068	1	1.737±1.58	0.858	3.526±1.867	0.000
	Test	1.158±1.21		1.68±1.6		2.79±1.78	
6	Control	1.17±1.2	0.206	1.56±1.58	0.79	4.05±2.39	0.166
	Test	1.39±1.29		1.5±1.54		3.56±2.31	
Base-1	Control	3±1.247	0.0001	3.526±0.9	0.0001	2.63±1.86	0.0001
	Test	1.26±1.326		1.68±1.56		4.58±1.77	
Base-3	Control	3±1.247	0.000	3.526±0.9	0.000	2.63±1.86	0.003
	Test	1.58±1.068		1.737±1.58		3.526±1.867	
Base-6	Control	3±1.247	0.001	3.526±0.9	0.0001	2.63±1.86	0.002
	Test	1.17±1.2		1.56±1.58		4.05±2.39	
1-3	Control	1.26±1.326	0.56	1.68±1.56	0.848	4.58±1.77	0.003
	Test	1.58±1.068		1.737±1.58		3.526±1.867	
1-6	Control	1.26±1.326	0.785	1.68±1.56	0.889	4.58±1.77	0.197
	Test	1.17±1.2		1.56±1.58		4.05±2.39	
3-6	Control	1.58±1.068	0.000	1.737±1.58	0.79	3.526±1.867	0.102
	Test	1.17±1.2		1.56±1.58		4.05±2.39	
		1.39±1.29		1.5±1.54		3.56±2.31	
		1.158±1.21		1.68±1.6		2.79±1.78	
		1.39±1.29		1.5±1.54		3.56±2.31	
		1.158±1.21		1.68±1.6		2.79±1.78	
		1.39±1.29		1.5±1.54		3.56±2.31	
		1.158±1.21		1.68±1.6		2.79±1.78	
		1.39±1.29		1.5±1.54		3.56±2.31	
		1.158±1.21		1.68±1.6		2.79±1.78	
		1.39±1.29		1.5±1.54		3.56±2.31	
		1.158±1.21		1.68±1.6		2.79±1.78	
		1.39±1.29		1.5±1.54		3.56±2.31	

RD: Recession depth; RW: Recession width; KG: Keratinized gingival

PLI was similar between the groups during the study ($P = 0.942$) [Table 4].

Both treatment groups presented with significant post-surgical improvement in gingival recession (width, depth and surface area) and keratinized gingiva [Table 1].

The results of Friedman test in both groups was significant for clinical indices ($P < 0.05$), except for PD in control group ($P = 0.166$).

DISCUSSION

Numerous plastic surgical procedures are performed for root converge to reduce root sensitivity, improve esthetic and manage defects resulting from the removal of root caries and/or cervical abrasions.^[1,3,7,8,12]

The subepithelial CTG is preferred for treating most mucogingival recession defects and could be considered the gold standard. CPF, among other techniques is also a predictable surgical procedure in the treatment of Miller Cl I and II gingival recession^[3,13] and dose not require a second surgical site.^[3]

EMD was avocate to promote new attachment to denuded root surfaces.^[3,8-10]

The present study was designed to evaluate the use of CPF with the addition of EMD and compare the results by a new method with subepithelial CTG alone in the treatment of Miller Cl I and II gingival recession.

The results of this study showed that the clinical efficacy of EMD placed under a CPF (test) was effective in covering recession defects, representing a

Table 2: PD at baseline and at postoperative intervals in both treatment groups (split-mouth design, n=18); data are expressed in mm (mean±SD)

Time (months)	Groups	PD	P value
Base	Control	1.526±0.611	0.317
	Test	1.63±0.684	
1	Control	1.58±0.61	0.317
	Test	1.42±0.61	
3	Control	1.263±0.452	0.257
	Test	1.105±0.315	
6	Control	1.28±0.46	0.102
	Test	1.06±0.24	
Base-1	Control	1.526±0.611	0.655
	Test	1.58±0.61	
Base-3	Control	1.526±0.611	0.132
	Test	1.63±0.684	
Base-6	Control	1.526±0.611	0.197
	Test	1.28±0.46	
1-3	Control	1.58±0.61	0.058
	Test	1.42±0.61	
1-6	Control	1.263±0.452	0.083
	Test	1.105±0.315	
3-6	Control	1.58±0.61	1
	Test	1.28±0.46	
		1.06±0.24	0.317

simpler procedure for the clinician and a less invasive procedure for the patient.

We performed each of the techniques without considering the amount of keratinized tissue at baseline. At the end of the study, no difference in the amount of keratinized tissue was shown between the two study groups, although statistically significant difference were seen within the study groups from baseline to 6-month examinations ($P = 0.004$ and $P = 0.002$, respectively). It seems EMD promoted new attachment to denuded root surfaces, based on biologic properties that have been described.^[3,8]

By means of EMD, periodontal regeneration may be achieved.^[8,9] However, it does not occur on a predictable basis.^[10]

Table 3: Covered surface area at different postoperative intervals in both treatment groups (n=18); data are expressed in mm² (mean±SD)

Time (months)	Groups	Stent	P value
1	Control	8.112±6.655	0.454
	Test	6.61±10.235	
3	Control	8.226±6.899	0.237
	Test	5.536±10.606	
6	Control	9.287±5.764	0.09
	Test	5.22±8.92	
1-3	Control	8.112±6.655	0.926
	Test	8.226±6.899	
1-6	Control	6.61±10.235	0.283
	Test	5.536±10.606	
3-6	Control	8.112±6.655	0.521
	Test	9.287±5.764	
3-6	Control	6.61±10.235	0.348
	Test	5.22±8.92	
3-6	Control	8.226±6.899	0.592
	Test	9.287±5.764	
3-6	Control	5.536±10.606	0.831
	Test	5.22±8.92	

Table 4: PLI at baseline and at postoperative intervals (split-mouth design, n=18); data are expressed in mm (mean±SD)

Time (months)	PLI	P value
Base-1	34.316±14.73	0.525
	36.5±12.81	
Base-3	34.316±14.73	0.562
	36.84±16.399	
Base-6	34.316±14.73	0.942
	35.28±15.3	
1-3	36.5±12.81	0.947
	36.84±16.399	
1-6	36.5±12.81	0.655
	35.28±15.3	
3-6	36.84±16.399	0.736
	35.28±15.3	

PLI: Plaque index

CTG often results in periodontal repair.^[4,9,14] Several studies showed better amount of keratinized gingiva following use of EMD with other techniques for root coverage,^[2,5-7,9,14-16] whereas the others did not show this result^[17,18] or showed same results.^[19]

In a systematic review article by Koop and co-workers, there was a consensus of opinion on the results of root coverage by using these two techniques, although this review took place on two studies.^[20]

There was a significant increase in the mean width of KG (1.09 ± 1.46 mm) following CPF + EMD treatment. The result is consistent with those

reported by Castellanos,^[3] Hägewald,^[6] Del pizzo,^[14] McGuire,^[2] Modica,^[5] Pilloni,^[15] Berlucchi,^[7] whose results showed an increased amount from 0.21mm. to 1.8mm. Data from this study demonstrated that a significant improvement was found in RD at six months (1.39 ± 1.29 mm. for the test group and 1.17 ± 1.2 mm. for the control group) and in the percentage of root coverage (55% and 63.3%, respectively). These percentages are less than the results of several studies.^[2,3,5-7,13,14,16] The reason for this discrepancy maybe due to less than ideal oral hygiene of the study groups ($PLI = 35.28 \pm 15.3\%$).

The reason to have better percentage of root coverage (RD) in the control group than in the test group, while the surface area of root coverage was similar between the groups, is not clear exactly. This discrepancy maybe due to different methods of measurements. Surface area measures maybe more precise than one-point measurement.

CONCLUSION

In conclusion, a combination of CPF with EMD in the treatment of Miller cl I or II gingival recession produced root coverage similar to that provided by CTG without EMD and there were no statistically significant difference between the two groups.

REFERENCES

- Zucchelli G, De Sanctis M. Long-term outcome following treatment of multiple Miller class I and II recession defects in esthetic areas of the mouth. *J Periodontol* 2005;76:2286-92.
- McGuire MK, Nunn M. Evaluation of human recession defects treated with coronally advanced flaps and either enamel matrix derivative or connective tissue. Part 1: Comparison of clinical parameters. *J Periodontol* 2003;74:1110-25.
- Castellanos AT, de la Rosa MR, de la Garnez M, Caffesse RG. Enamel matrix derivative and coronal flaps to cover marginal tissue recessions. *J Periodontol* 2006;77:7-14.
- Chen L, Cha J, Guih R, Bouwsma OJ. Root coverage with enamel matrix derivatives. *Compend Contin Educ Dent* 2002;23:797-800.
- Modica F, Del Pizzo M, Rocuzzo M, Romagnoli R. Coronally advanced flap for the treatment of buccal gingival recessions with and without enamel matrix derivative: A split-mouth study. *J Periodontol* 2000;71:1693-8.
- Hägewald S, Spahr A, Rompola E, Haller B, Heijl L, Bemimoulin JP. Comparative study of Emdogain and coronally advanced flap technique in the treatment of human gingival recessions. *J Clin Periodontol* 2002;29:35-41.
- Berlucchi I, Francetti L, DelFabbro M, Testori T, Weinstein RL. Enamel matrix proteins (Emdogain) in combination with coronally advanced flap or subepithelial connective tissue graft in the treatment of shallow gingival recessions. *Int J Periodontics Restorative Dent* 2002;22:583-93.
- Rasperini G, Silvestri M, Schenk RK, Nevins ML. Clinical and histologic evaluation of human gingival recession treated with a subepithelial connective tissue graft and enamel matrix derivative (Emdogain): A case report. *Int J Periodontics Restorative Dent* 2000;20:269-75.
- McGuire MK, Cochran DL. Evaluation of human recession defects treated with coronally advanced flaps and either enamel matrix derivative or connective tissue. Part 2: Histological evaluation. *J Periodontol* 2003;74:1126-35.
- Carnio J, Camargo PM, Kenny EB, Schenk RK. Histologic evaluation of 4 cases of root coverage following a connective tissue graft combined with an enamel matrix derivative preparation. *J Periodontol* 2002;73:1534-43.
- Vahabi S. A new method for evaluation of denuded root surface following root coverage. *J Dent Sch* 2004;22:541-6.
- Jayavel K, Swaminathan M, Kumar S. Ridge augmentation and root coverage using acellular dermal matrix: A case report. *Dent Res J (Isfahan)* 2010;7:88-91.
- Moses O, Artzi Z, Sculean A, Tal H, Kozlovsky A, Romanos GE, *et al.* Comparative study of two root coverage procedures: A 24-month follow-up multicenter study. *J Periodontol* 2006;77:195-202.
- Del Pizzo M, Zucchelli G, Modica F, Villa R, Debernardi C. Coronally advanced flap with or without enamel matrix derivative for root coverage: A 2-year study. *J Clin Periodontol* 2005;32:1181-7.
- Pilloni A, Paolantonio M, Camargo PM. Root coverage with a coronally positioned flap used in combination with enamel matrix derivative: 18-month clinical evaluation. *J Periodontol* 2006;77:2031-9.
- Cheng YF, Chen JW, Lin SJ, Lu HK. Is coronally positioned flap procedure adjunct with enamel matrix derivative or root conditioning a relevant predictor for achieving root coverage? A systemic review. *J Periodontol Res* 2007;42:474-85.
- Nemcovsky CE, Artzi Z, Tal H, Kozlovsky A, Moses O. A multicenter comparative study of two root coverage procedures: Coronally advanced flap with addition of enamel matrix proteins and subepithelial connective tissue graft. *J Periodontol* 2004;75:600-7.
- Abolfazli N, Saleh-Saber F, Eskandari A, Lafzi A. A comparative study of the long-term results of root coverage with connective tissue graft or enamel matrix protein: 24-month results. *Med Oral Patol Oral Cir Bucal* 2009;14:E304-9.
- Rasperini G, Rocuzzo M, Francetti L, Acunzo R, Consonni D, Silvestri M. Subepithelial connective tissue graft for treatment of gingival recession with and without enamel matrix derivative: A multicenter randomized controlled clinical trial. *Int J Periodontics Restorative Dent* 2011;31:133-9.
- Koop R, Merheb J, Quirynen M. Periodontal regeneration with enamel matrix derivative (EMD) in reconstructive periodontal therapy: A systematic review. *J Periodontol* 2012;83:707-20.

How to cite this article: Sayar F, Akhundi N, Gholami S. Connective tissue graft vs. emdogain: A new approach to compare the outcomes. *Dent Res J* 2013;10:38-45.

Source of Support: The study was self-funded by the authors and their institution. **Conflict of Interest:** None declared.