

Role of Gd₂O₃-doped carbon-11-choline-lenvatinib nanoparticles contrast agent PET/CT in the diagnosis of patients with lung cancer

TONG ZHOU¹⁻³, DONGFANG HANG¹⁻³, YING LI¹⁻³, JIN ZHANG¹⁻³,
HUAYANG WU¹⁻³, HONGYAN WANG¹⁻³, ENBING TIAN¹⁻³ and JUN YAN¹⁻³

¹Department of Nuclear Medicine, Dongzhimen Hospital of Beijing University of Traditional Chinese Medicine;

²Department of Oncology, Beijing Chao-Yang Hospital Affiliated to Capital Medical University;

³Department of Respiratory Medicine, Dongzhimen Hospital of Beijing University of Traditional Chinese Medicine, Beijing 100700, P.R. China

Received September 26, 2018; Accepted May 31, 2019

DOI: 10.3892/ol.2019.11243

Abstract. Positron emission tomography-computed tomography (PET/CT) is an efficient method for the diagnosis of various types of human cancer. Studies have demonstrated that Gd₂O₃-doped carbon-11-choline (GdCho) can be used as a contrast nanoparticle for PET/CT in the diagnosis of patients with lung cancer. The aim of the present study was to evaluate the effect of GdCho-lenvatinib nanoparticles contrast-PET/CT (GdCho-Len-PET) in the diagnosis and treatment planning of a cohort of patients suspected of having lung cancer. The results of the present study demonstrated that GdCho-Len could be used as an efficient PET/CT contrast agent for the diagnosis of patients with lung cancer. GdCho-Len nanoparticles contrast agent exhibited a significantly improved longitudinal relaxivity compared with GdCho. The outcomes of the present study were that GdCho-Len-PET diagnosed 152 patients with lung cancer, whereas GdCho-PET diagnosed 130 patients with lung cancer among the 172 patients. GdCho-Len-PET presented with higher accuracy and sensitivity compared with GdCho-PET in diagnosing patients with lung cancer. All patients were further confirmed via histological analysis. GdCho-Len-PET contributed to the anticancer treatments in 56 out of 62 (90.3%) patients with lung cancer who were candidates for radiation therapy, 52 out of 57 (91.2%) patients with lung cancer undergoing adjuvant radiotherapy, and 13 out

of 17 (76.5%) patients with lung cancer undergoing comprehensive therapy. Patients diagnosed using GdCho-Len-PET improved the survival of patients with lung cancer during a 420-day follow up. In conclusion, GdCho-Len-PET increased the diagnostic efficacy and had a significant effect on survival for patients with lung cancer, and may therefore serve as a reliable method for human cancer diagnosis.

Introduction

Lung cancer is a major public health problem and is the leading cause of cancer-associated mortality worldwide (1-3). Cancer pathology often divides lung cancer into non-small cell lung cancer (NSCLC) and small cell lung cancer, which account for ~85 and ~15% of lung cancer cases, respectively (4). Statistics have estimated that there were ~1.8 million newly diagnosed lung cancer cases and ~1.6 million lung cancer-associated mortalities in 2012 worldwide (5). Lung cancer is the most frequently occurring human cancer and is the leading cause of cancer-associated mortality among males, followed by prostate and colorectal cancer for incidence, and liver and stomach cancer for mortality (6). Currently, although clinical therapeutic methods, including radiotherapy, chemotherapy, Chinese medicinal herb treatment, immunotherapy, gene therapy and targeted therapy, have been investigated and applied for the treatment of patients with lung cancer (7-10), the overall 5-year survival rate remains poor at <15% (11-13).

At present, lung tumor metastasis is the most difficult treatment barrier in cancer therapy (14-16). Therefore, obtaining an early diagnosis for human tumors is crucial for the effective treatment of human lung cancer (17). Clinically, ultrasound, positron emission tomography-computed tomography (PET/CT) and magnetic resonance imaging have been applied for diagnosing human cancer (18). Notably, PET/CT has become an efficient protocol for tumor diagnosis in human lung cancer cases (19-21). PET/CT also serves a vital role in the differentiation of adrenal metastasis from a benign adrenal mass in patients with lung cancer, with excellent diagnostic

Correspondence to: Professor Jun Yan, Department of Nuclear Medicine, Dongzhimen Hospital of Beijing University of Traditional Chinese Medicine, 5 Haiyuncang Road, Dongcheng, Beijing 100700, P.R. China
E-mail: yanjunbeijing@yeah.net

Key words: lung cancer, positron emission tomography-computed tomography, Gd₂O₃-doped carbon-11-choline-lenvatinib nanoparticles contrast-positron emission tomography-computed tomography

performance (22). However, the diagnostic efficacy in patients with early-stage lung cancer requires improvement.

It has been reported that developing multimodal contrast agent would enhance the diagnostic accuracy of PET/CT, as well as increase the diagnostic accuracy sensitivity in patients with lung cancer (23). A previous study reported that contrast-enhanced ultrasound with a novel nanoparticle contrast agent increases the diagnostic efficacy in patients with NSCLC (24). In addition, another study reported a composite nano-system composed of gadolinium-doped mesoporous silica nanoparticles and gold nanoparticles, which can be used as an efficient contrast agent for *in vivo* cancer imaging (25). In addition, previous studies have demonstrated that Gd₂O₃-doped nanoparticles are promising candidates of highly efficient contrast agents in diagnosing human cancer (26-28).

Lenvatinib (Len) is a small-molecule tyrosine kinase inhibitor that inhibits vascular endothelial growth factor receptors, platelet-derived growth factor receptor α , fibroblast growth factor receptors, stem cell factor receptor and rearranged during transfection (29). In the present study, Gd₂O₃-doped carbon-11-choline-Len (GdCho-Len) nanoparticles contrast combined with PET/CT (GdCho-Len-PET) was used to diagnose patients with lung cancer. The present study characterized GdCho-Len-PET to visualize the distribution of human lung tumor using PET/CT by performing *in vivo* trials. The survival rate of patients with lung cancer diagnosed by GdCho-Len-PET was identified during a 420-day follow up.

Materials and methods

Subjects. A total of 172 patients with suspected lung cancer were recruited from the Dongzhimen Hospital of Beijing University of Traditional Chinese Medicine (Beijing, China) between May 2016 and September 2017. Lung cancer diagnosis was confirmed by biopsy by three respiratory physicians who specialized in the interpretation of clinical and radiological lung cancer data. All patients with suspected lung cancer underwent GdCho-PET and GdCho-Len-PET, which was further confirmed by a tissue biopsy (n=172). The age range of patients was 36-60 years, and comprised an equal number of men and women. The characteristics of the patients are summarized in Table I. The exclusion criteria were as follows: i) Patients with cancer history; ii) patients with pulmonary infarction; iii) patients who had been diagnosed with acute respiratory disease within 6 months; iv) pregnant or lactating females; and v) patients with infection suspected to cause coughs. The inclusion criteria were as follows: i) age ≥ 25 years; and ii) individuals who were able to provide informed consent for participation. The Ethics Committee of the Dongzhimen Hospital of Beijing University of Traditional Chinese Medicine (Beijing, China) approved the present study. All participants provided written informed consent for inclusion.

Contrast agent. The GdCho and GdCho-Len contrast agents were synthesized as described previously (30). Briefly, cetyltrimethylammonium bromide (C₁₆TAB; 0.2 g) was dissolved in distilled water (50 ml). Subsequently, NH₃·H₂O (2 ml; 25%) and tetraethoxysilane (4.49 mmol) were added and stirred at room temperature for 10 min. Gd₂O₃ (0.5 mmol)

Table I. Characteristics of patients with suspected lung cancer.

| Characteristics | n (%) | Mean \pm standard deviation |
|-----------------------|--------------|-------------------------------|
| Sex | | |
| Male | 86.0 (50.0) | |
| Female | 86.0 (50.0) | |
| Age, years | | |
| Mean | 47.6 | |
| Range | 36.0-60.0 | |
| BMI | | 26.2 \pm 5.6 |
| Heart rate, beats/min | | 88.0 \pm 8.0 |
| Smoking status | | |
| Current/former | 160.0 (93.0) | |
| Never | 12.0 (7.0) | |

BMI, body mass index.

was then added to the solution and stirred at room temperature for 1 h, and carbon-11 (0.1 mmol), choline (0.1 mmol) or carbon-11-choline (0.1 mmol), and lenvatinib (0.2 mmol) were added to the solution and stirred at room temperature for 1 h. All these compounds were provided by Sigma-Aldrich; Merck KGaA. Samples were calcined at 37°C for 72 h, and the GdCho and GdCho-Len nanoparticles were harvested. The synthesized GdCho-Len nanoparticles were imaged by high-angle annular dark-field scanning electron microscopy (magnification, $\times 100$). The size distribution of the GdCho-Len nanoparticles was measured using a DynaPro NanoStar Dynamic Light Scattering Detector (Wyatt Technology Corporation). The nanoparticles contrast agent was visualized by a PET/CT system. The GdCho and GdCho-Len contrast agents were intravenously injected prior to PET/CT.

PET/CT. Static PET/CT with a GEMINI TF Big Bore PET/CT system (Philips Medical Systems, Inc.) was used to evaluate patients with suspected lung cancer. PET/CT was performed at 3 h following the administration of GdCho-Len (0.4-4.0 mg/kg; 0.4 mg interval). A low dose CT of 30 sec (mAs, 80-175; kV, 120; slice thickness, 5 mm) was performed and CT images were set at a 512 matrix. The emission time per bed position ranged between 1 and 2 min based on the body mass index of individuals.

Detection of GdCho-Len in plasma concentration. The serum concentration levels of Len were analyzed using an ELISA kit (cat. no. FAB357P; R&D Systems, Inc.), according to the manufacturer's protocol. The results were analyzed using an ELISA reader system (1775xMark™; Bio-Rad Laboratories, Inc.).

Hematoxylin and eosin staining. Biopsies of lung tissues were obtained from individuals following diagnosis by GdCho-Len-PET or GdCho-PET. Sections 4- μ m-thick were prepared, fixed with 10% paraformaldehyde for 15 min at room temperature and stained with hematoxylin and eosin

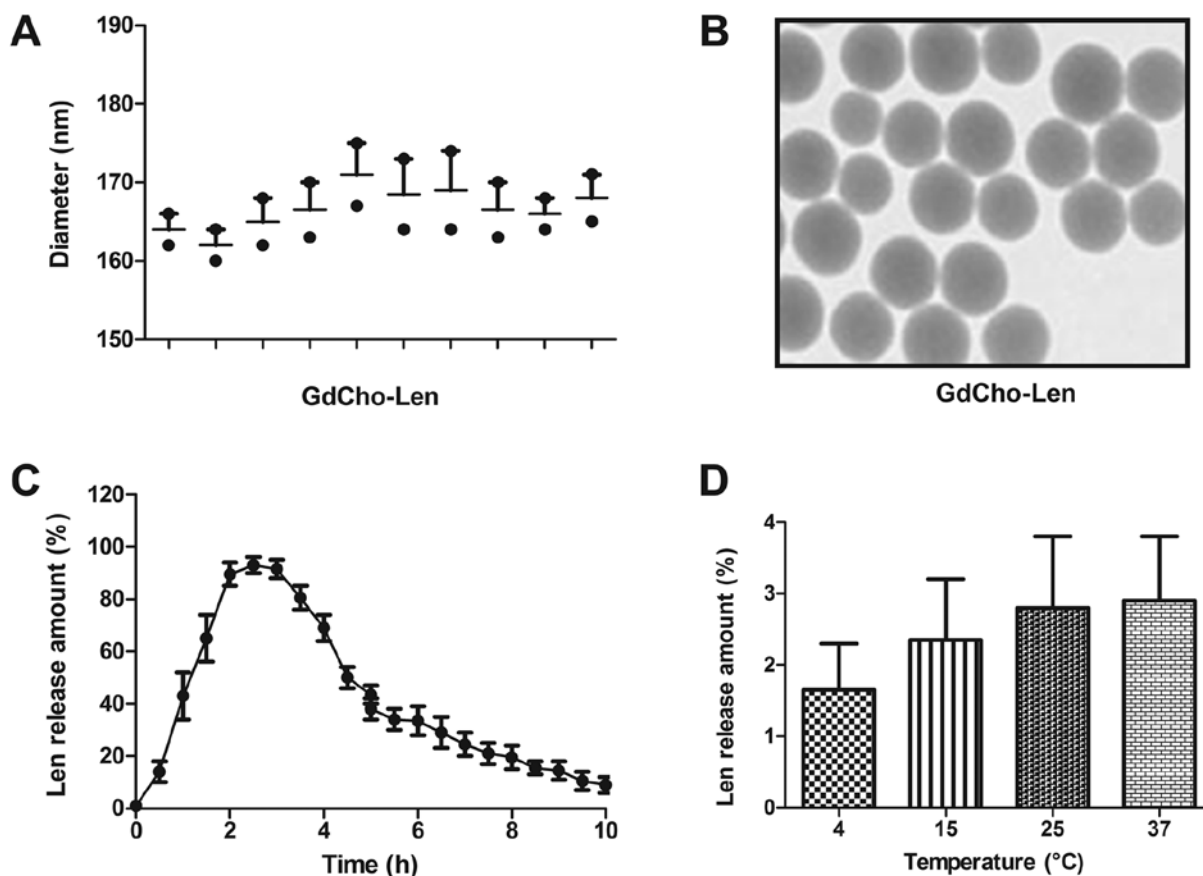


Figure 1. Characterization of GdCho-Len. (A) Diameter of GdCho-Len. (B) The spherical and uniform shape of GdCho-Len. Magnification, x100. (C) Release assay of Len from GdCho-Len. (D) The stability of GdCho-Len nanoparticles at 4, 15, 25 and 37°C. GdCho-Len, Gd₂O₃-doped carbon-11-choline-lenvatinib nanoparticles contrast; Len, lenvatinib.

for 30 min at room temperature. Sections were washed with PBS three times and then observed under a light microscope (Olympus Corporation; magnification, x100).

Stability assay. GdCho-Len nanoparticles were placed at 4, 15, 25 and 37°C for 7 days. Stability of GdCho-Len was analyzed by high performance size exclusion chromatography performed using a TSKgel G3000SWx1 column (Tosoh Bioscience) and an Agilent HPLC 1200 system (Agilent Technologies GmbH).

Statistical analysis. Statistical analyses were analyzed using SPSS 18.0 software (SPSS, Inc., Chicago, IL, USA). Data are presented as the mean ± standard error of the mean. All experiments were repeated at least three times. A receiver operator characteristic curve was generated to determine the cut-off point that optimized sensitivity and specificity. A paired Student's t-test was used to compare two independent groups of data. Survival curves were constructed using the Kaplan-Meier method and were compared using a log-rank test. P<0.05 was considered to indicate a statistically significant difference.

Results

Characterization of GdCho-Len. TEM revealed that the diameter of GdCho-Len was 168.2±6.8 nm (Fig. 1A). As presented

in Fig. 1B, GdCho-Len exhibited a spherical and uniform shape. The *in vitro* release of Len from the GdCho-Len was also investigated to determine its release profile (Fig. 1C). The stability assay demonstrated that GdCho-Len nanoparticles were stable particles at 4, 15, 25 and 37°C for multiple laser irradiations (Fig. 1D). These results indicate the successful encapsulation of Len into the GdCho, and GdCho-Len was demonstrated to be a stable nanoparticles contrast agent.

Diagnostic efficacy of GdCho-Len-PET in patients with suspected lung cancer. The diagnostic accuracy and sensitivity of GdCho-Len-PET was investigated in patients with suspected lung cancer. A clinical dose of GdCho-Len at 2.4 mg/kg was identified to achieve the optimum signal intensity for PET/CT detection (Fig. 2A). GdCho-Len nanoparticles contrast agent exhibited a markedly improved longitudinal relaxivity compared with GdCho (Fig. 2B). The results indicated that GdCho-Len-PET diagnosed 152/172 patients with lung cancer, while GdCho-PET diagnosed 130/172 patients with lung cancer (Table II), and that GdCho-Len-PET has higher accuracy and sensitivity compared with GdCho-PET in diagnosing patients with lung cancer (Fig. 3).

Histopathological diagnoses of patients with lung cancer. Immunohistochemistry was used to confirm the diagnostic outcomes of GdCho-Len-PET. Fig. 4 presents representative cancer and non-cancer tissues. Statistical analysis demonstrated

Table II. Diagnostic outcomes of GdCho-Len-PET and GdCho-PET.

| Presence of lung cancer | GdCho-PET, n (%) | GdCho-Len-PET, n (%) | P-value |
|-------------------------|------------------|----------------------|---------|
| Lung cancer | 130 (75.6) | 152 (88.4) | 0.035 |
| No lung cancer | 42 (24.4) | 20 (11.6) | 0.023 |

GdCho-Len-PET, Gd₂O₃-doped carbon-11-choline-lenvatinib nanoparticles contrast combined with positron emission tomography-computed tomography; GdCho-PET, Gd₂O₃-doped carbon-11-choline nanoparticles contrast combined with positron emission tomography-computed tomography.

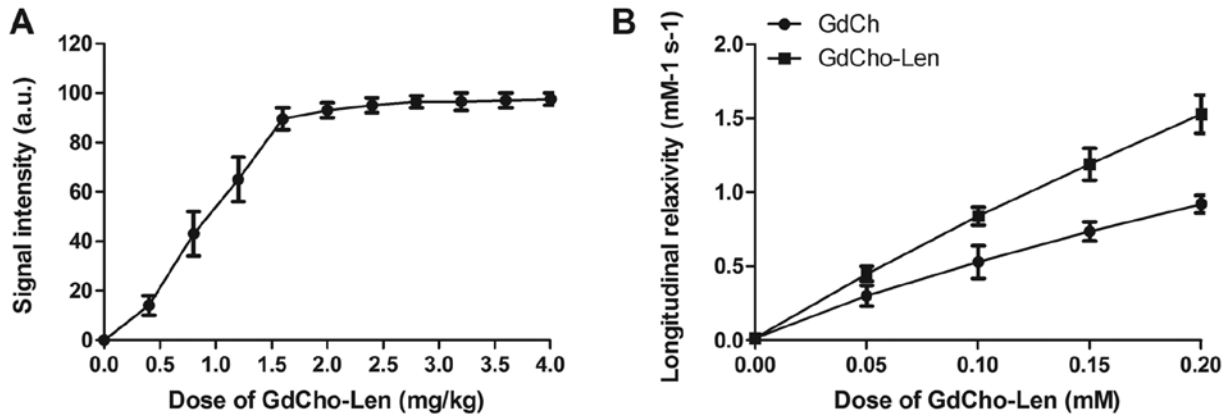


Figure 2. Diagnostic efficacy of GdCho-Len-PET in patients with suspected lung cancer. (A) Signal intensity of GdCho-Len at different concentrations in diagnosing patients with suspected lung cancer. (B) Longitudinal relaxivity of GdCho-PET at different concentrations. GdCh, Gd₂O₃-doped carbon-11; GdCho-Len, Gd₂O₃-doped carbon-11-choline-lenvatinib nanoparticles contrast; GdCho-Len-PET, Gd₂O₃-doped carbon-11-choline-lenvatinib nanoparticles contrast combined with positron emission tomography-computed tomography.

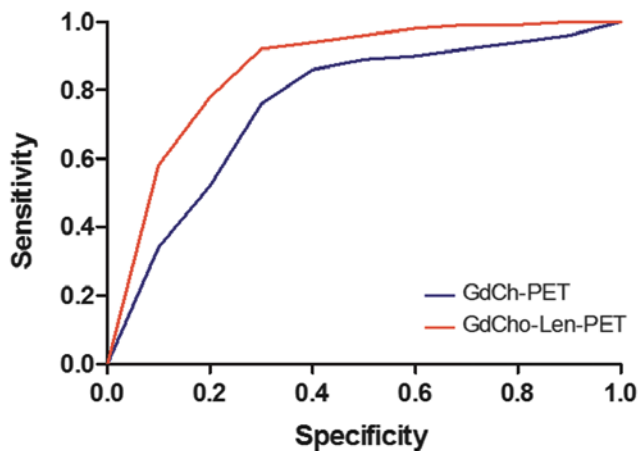


Figure 3. Accuracy and sensitivity of GdCho-Len-PET and GdCho-PET in diagnosing patients with suspected lung cancer. Receiver operating characteristic curve reveals the specificity and sensitivity of GdCho-Len-PET and GdCho-PET in diagnosing patients with lung cancer. GdCho-Len-PET, Gd₂O₃-doped carbon-11-choline-lenvatinib nanoparticles contrast combined with positron emission tomography-computed tomography; GdCho-PET, Gd₂O₃-doped carbon-11-choline nanoparticles contrast combined with positron emission tomography-computed tomography.

that there were 136 patients with lung cancer among 152 lung cancer patients diagnosed by GdCho-Len-PET, and there were two lung cancer cases in 20 non-lung cancer cases diagnosed by GdCho-Len-PET (data not shown).

Histopathological analyses revealed that there were 114 'true' lung cancer cases in 130 lung cancer cases diagnosed by GdCho-PET. This revealed that there were 102 patients with confirmed lung cancer, as diagnosed by GdCho-PET. There were 21 patients with false positive cases as diagnosed by GdCho-Len-PET, and 28 patients were false positive cases diagnosed by GdCho-PET. In addition, there were five false negative cases diagnosed by GdCho-Len-PET, while there were 34 false negative cases diagnosed by GdCho-PET (Table III). These outcomes indicate that GdCho-Len-PET exhibits higher accuracy compared with GdCho-PET in diagnosing patients with lung cancer.

Plasma concentrations of GdCho-Len in patients with lung cancer. The pharmacodynamics of GdCho-Len was analyzed in patients with lung cancer. The results revealed that GdCho-Len was metabolized from the blood 16 h following injection (Fig. 5). The clinical data suggested that GdCho-Len is a safe contrast agent when diagnosing patients with lung cancer.

Outcomes for patients diagnosed by GdCho-Len-PET. GdCho-Len-PET contributed to the anticancer treatments in 56 out of 62 (90.3%) patients with lung cancer who were candidates for radiation therapy, 52 out of 57 (91.2%) patients undergoing adjuvant radiotherapy, and 13 out of 17 (76.5%) patients undergoing comprehensive therapy (Table IV). Patients diagnosed by GdCho-Len-PET had a significantly

Table III. Diagnostic efficacy of GdCho-Len-PET for patients suspected of having lung cancer.

| Result | GdCho-PET, n (%) | GdCho-Len-PET, n (%) | P-value |
|----------------|------------------|----------------------|---------|
| False positive | 28 (16.3) | 21 (12.2) | 0.030 |
| True positive | 102 (59.3) | 131 (76.2) | 0.017 |
| False negative | 34 (19.8) | 5 (2.9) | 0.001 |
| True negative | 8 (4.7) | 15 (8.7) | 0.0026 |

GdCho-Len-PET, Gd₂O₃-doped carbon-11-choline-lenvatinib nanoparticles contrast combined with positron emission tomography-computed tomography; GdCho-PET, Gd₂O₃-doped carbon-11-choline nanoparticles contrast combined with positron emission tomography-computed tomography.

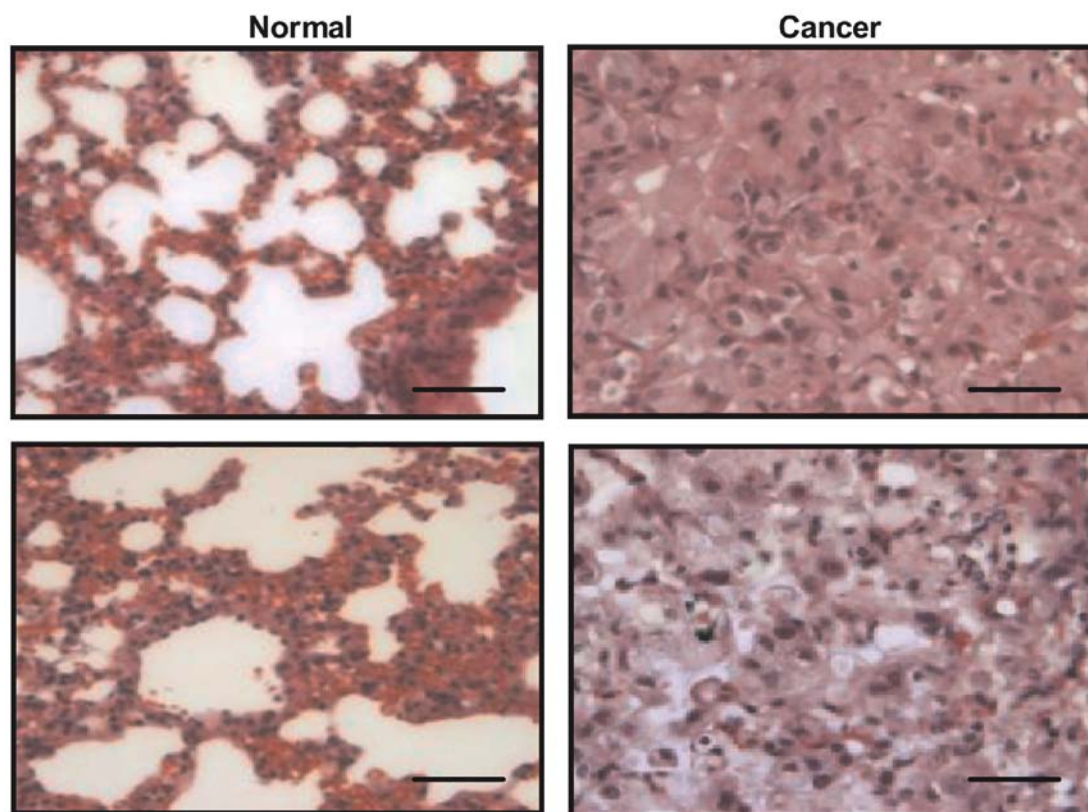


Figure 4. Histopathology confirms the diagnostic accuracy of GdCho-Len-PET for patients with lung cancer. Hematoxylin and eosin staining demonstrates the normal lung tissues and lung cancer tissues. Magnification, x40. Scale bar, 50 μ m. GdCho-Len-PET, Gd₂O₃-doped carbon-11-choline-lenvatinib nanoparticles contrast combined with positron emission tomography-computed tomography.

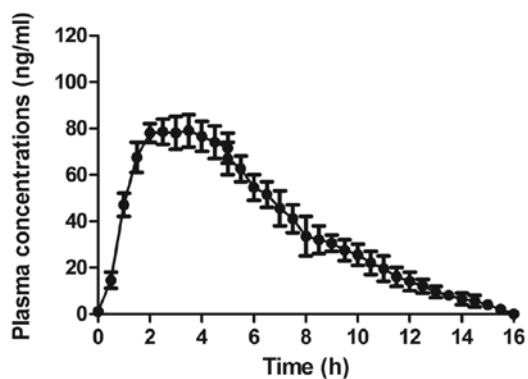


Figure 5. Plasma concentration of GdCho-Len in patients with lung cancer. An ELISA assay revealed that GdCho-Len is metabolized from plasma within 16 h. GdCho-Len, Gd₂O₃-doped carbon-11-choline-lenvatinib nanoparticles contrast.

improved mean overall survival during the 420-day follow up (Fig. 6A). It was observed that GdCho-Len-PET-diagnosed patients exhibited a significantly improved mean progression-free survival compared with the mean 5-year survival (Fig. 6B). The results demonstrated that 82 patients were alive and tumor-free, 14 patients were still alive with tumors, and 6 patients succumbed to the disease during the 420-day follow-up. These data suggested that patients with lung cancer diagnosed by GdCho-Len-PET had longer median overall survival times compared with the mean 5-year survival.

Discussion

Lung cancer diagnosis is crucial for reducing morbidity and increasing the quality of life of patients (24,31,32). An early

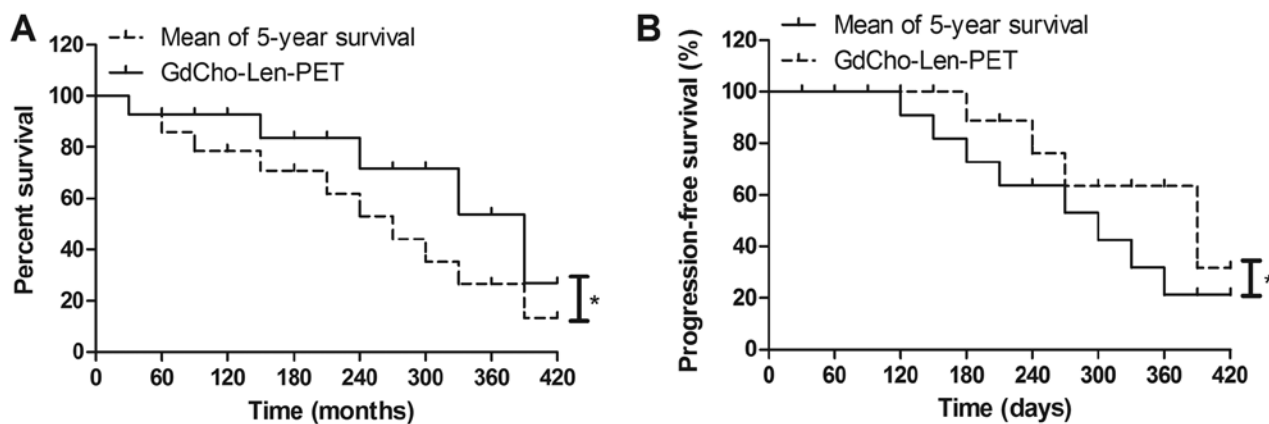


Figure 6. Survival of patients diagnosed by GdCho-Len-PET. (A) Kaplan-Meier curves compare the mean survival rate between patients diagnosed by GdCho-Len-PET and the mean 5-year survival time (log-rank test, $P=0.035$). (B) Kaplan-Meier curves for the mean progression-free survival revealed a significant difference between patients diagnosed by GdCho-Len-PET and the mean 5-year survival (log-rank test, $P=0.026$). $^*P<0.05$. GdCho-Len-PET, Gd_2O_3 -doped carbon-11-choline-levatinib nanoparticles contrast combined with positron emission tomography-computed tomography.

Table IV. Treatment of patients with lung cancer diagnosed by GdCho-Len-PET.

| Treatment | n (%) |
|-----------------------|-----------|
| Radiation therapy | 56 (42.7) |
| Adjuvant radiotherapy | 52 (39.7) |
| Comprehensive therapy | 23 (17.6) |

diagnosis of lung cancer may improve the administration of timely anticancer treatments, including surgery, chemotherapy and immunotherapy, for patients with lung cancer, which can further improve the overall survival and progression-free survival (33-35). Clinically, PET/CT has been widely used for diagnosing human lung cancer and evaluating metastatic lesions (36). Previous studies have indicated that contrast agent is useful in PET/CT scanning of human lung cancer (37-39). In the present study, the nanoparticle contrast agent GdCho-Len was administered and the diagnostic efficacy of GdCho-Len-PET was investigated in a total of 172 patients with lung cancer. GdCho-Len-PET provided a 13.8% false positive result in 152 cases. All cases excluded by GdCho-Len-PET were patients without lung cancer. Taken together, the data obtained in the present study indicates that GdCho-Len is a stable and safe nanoparticle contrast agent for diagnosing patients with lung cancer.

Contrast agent may increase the sensitivity and accuracy of CT imaging for the diagnosis of early stage NSCLC (23). A novel nano-sized chitosan/ Fe_3O_4 -enclosed bispecific antibody had been identified as an efficient contrast agent in lung cancer diagnosis (40). However, a previous study reported that a nonionic intravenous contrast agent did not cause clinically significant improvement to ^{18}F -FDG PET/CT in patients with lung cancer (41). Therefore, efficient nanoparticles contrast agent serves an important role in diagnosing patients with lung cancer. In the present study, successful encapsulation of Len into the GdCho was achieved and GdCho-Len was produced,

which was a stable nanoparticle contrast agent. GdCho-Len exhibited an increased accuracy and sensitivity when compared with GdCho-PET in diagnosing patients suspected of having lung cancer. Indeed, the GdCho-Len nanoparticles provided an improved resolution ratio for tumors than GdCho due to the targeting of Len for tumor cells (42).

Apart from the intracellular environment of lung tumor cells influencing the relaxivity of GdCho-Len, detection of lung tumor cells was difficult to see on the imaging volume within which these cells were embedded (43-45). The present study indicated that the GdCho-Len allowed Len to discriminate between lung cancer cells, which enhanced the diagnostic sensitivity of PET/CT. Ideally, following detection of a suspicious lesion on PET/CT, a plasma metabolic profile of contrast agent could be used to evaluate the clinical safety of drugs (46-48). The current study indicated that GdCho-Len could be metabolized from blood 36 h post-injection. In addition, GdCho-Len-PET contributed to the anticancer treatments for patients with lung cancer, which further improved the median overall survival and median progression-free survival compared with the mean of 5-year survival. However, further studies that investigate the effect GdCho-Len-PET on radiotherapy should be performed with more patients with lung cancer in the future.

In conclusion, the present study is a clinical report describing the characteristics of GdCho-Len and the diagnostic efficacy of GdCho-Len-PET in patients with suspected lung cancer. The results indicated that GdCho-Len-PET contributed to the anticancer treatments and improved the survival of patients with lung cancer. The results of the current study may aid the diagnosis of lung cancer and the development of effective treatment strategies.

Acknowledgements

Not applicable.

Funding

No funding was received.

Availability of data and materials

The datasets used and/or analyzed during the study are available from the corresponding author on reasonable request.

Authors' contributions

TZ, DH and YL performed experiments. JZ, HYW and HGW analyzed experimental data. ET and JY designed the current study and wrote the manuscript.

Ethics approval and consent to participate

The Ethical Committee of the Dongzhimen Hospital of Beijing University of Traditional Chinese Medicine (Beijing, China) approved the present study. Written informed consent was obtained from all participants.

Patient consent for publication

Not applicable.

Competing interests

The authors declare that they have no competing interests.

References

- Ridge CA and Boiselle PM: Optimizing the lung cancer screening interval: The world is waiting. *J Thorac Dis* 8: E1369-E1370, 2016.
- Xing P, Wang S, Hao X, Zhang T and Li J: Clinical data from the real world: Efficacy of Crizotinib in Chinese patients with advanced ALK-rearranged non-small cell lung cancer and brain metastases. *Oncotarget* 7: 84666-84674, 2016.
- Gao L, Xie S, Liu H, Liu P, Xiong Y, Da J, Que C, Dai H and Wang C: Lung cancer in patients with combined pulmonary fibrosis and emphysema revisited with the 2015 World Health Organization classification of lung tumors. *Clin Respir J* 12: 652-658, 2018.
- Zhukovsky M, Varaksin A and Pakholkina O: Statistical analysis of observational study of the influence of radon and other risk factors on lung cancer incidence. *Radiat Prot Dosimetry* 160: 108-111, 2014.
- Torre LA, Bray F, Siegel RL, Ferlay J, Lortet-Tieulent J and Jemal A: Global cancer statistics, 2012. *CA Cancer J Clin* 65: 87-108, 2015.
- Bray F, Ferlay J, Soerjomataram I, Siegel RL, Torre LA and Jemal A: Global Cancer Statistics 2018: GLOBOCAN estimates of incidence and mortality worldwide for 36 cancers in 185 countries. *CA Cancer J Clin* 68: 394-424, 2018.
- Liu B, Yuan M, Sun Y, Cheng Z, Zhang Z, Hou S, Wang X and Liu J: Incidence and risk of hepatic toxicities associated with anaplastic lymphoma kinase inhibitors in the treatment of non-small-cell lung cancer: A systematic review and meta-analysis. *Oncotarget* 9: 9480-9488, 2017.
- Leitinger M, Varosanec MV, Pikija S, Wass RE, Bandke D, Weis S, Studnicka M, Grinzing S, McCoy MR, Hauer L and Sellner J: Fatal necrotizing encephalopathy after treatment with nivolumab for squamous non-small cell lung cancer: Case report and review of the literature. *Front Immunol* 9: 108, 2018.
- Yang JC, Mok T, Han B, Orlando M, Puri T and Park K: A review of regimens combining pemetrexed with an epidermal growth factor receptor tyrosine kinase inhibitor in the treatment of advanced nonsquamous non-small-cell lung cancer. *Clin Lung Cancer* 19: 27-34, 2018.
- Takamori S, Toyokawa G, Takada K, Shoji F, Okamoto T and Maehara Y: Combination therapy of radiotherapy and Anti-PD-1/PD-L1 treatment in non-small-cell lung cancer: A Mini-review. *Clin Lung Cancer* 19: 12-16, 2018.
- Bamji-Stocke S, van Berkel V, Miller DM and Frieboes HB: A review of metabolism-associated biomarkers in lung cancer diagnosis and treatment. *Metabolomics* 14: 81, 2018.
- Vergnenègre A and Chouaid C: Review of economic analyses of treatment for non-small-cell lung cancer (NSCLC). *Expert Rev Pharmacoecon Outcomes Res* 18: 519-528, 2018.
- Yang X, Li M, Yang X, Zhao M, Huang Y, Dai X, Jiang T, Feng M, Zhan C and Wang Q: Uniport versus multiport video-assisted thoracoscopic surgery in the perioperative treatment of patients with T1-3N0M0 non-small cell lung cancer: A systematic review and meta-analysis. *J Thorac Dis* 10: 2186-2195, 2018.
- Suzuki H, Hyodo I and Hasegawa Y: Prediction of decannulation, oral intake recovery, overall survival and lung metastasis following oral malignant tumor resection and reconstruction. *Oncol Lett* 15: 2686-2694, 2018.
- Deng Y, Yang Y, Yao B, Ma L, Wu Q, Yang Z, Zhang L and Liu B: Paracrine signaling by VEGF-C promotes non-small cell lung cancer cell metastasis via recruitment of tumor-associated macrophages. *Exp Cell Res* 364: 208-216, 2018.
- Song W, Kuang J, Li CX, Zhang M, Zheng D, Zeng X, Liu C and Zhang XZ: Enhanced immunotherapy based on photodynamic therapy for both primary and lung metastasis tumor eradication. *ACS Nano* 12: 1978-1989, 2018.
- Du Q, Yu R, Wang H, Yan D, Yuan Q, Ma Y, Slamon D, Hou D, Wang H and Wang Q: Significance of tumor-associated autoantibodies in the early diagnosis of lung cancer. *Clin Respir J* 12: 2020-2028, 2018.
- Cormio A, Cormio G, Musicco C, Sardanelli AM, Gasparre G and Gadaleta MN: Mitochondrial changes in endometrial carcinoma: Possible role in tumor diagnosis and prognosis (review). *Oncol Rep* 33: 1011-1018, 2015.
- Cherkashin M, Aniskhin M, Berezina N and Puchkov D: CT and PET/CT fusion for lung cancer biopsy planning. *BMJ Case Rep* 2017: pii: bcr-2017-221972, 2017.
- Lim CG, Shin KM, Lim JS, Lim JK, Kim HJ, Kim WH, Cho SH, Cha SI, Lee EB, Seock Y and Jeong SY: Predictors of conversion to thoracotomy during video-assisted thoracoscopic surgery lobectomy in lung cancer: Additional predictive value of FDG-PET/CT in a tuberculosis endemic region. *J Thorac Dis* 9: 2427-2436, 2017.
- Gensheimer MF, Hong JC, Chang-Halpenny C, Zhu H, Eclow NCW, To J, Murphy JD, Wakelee HA, Neal JW, Le QT, *et al*: Mid-radiotherapy PET/CT for prognostication and detection of early progression in patients with stage III non-small cell lung cancer. *Radiother Oncol* 125: 338-343, 2017.
- Wu Q, Luo W, Zhao Y, Xu F and Zhou Q: The utility of 18F-FDG PET/CT for the diagnosis of adrenal metastasis in lung cancer: A PRISMA-compliant meta-analysis. *Nucl Med Commun* 38: 1117-1124, 2017.
- Yuan N, Zhang X, Cao Y, Jiang X, Zhao S, Feng Y, Fan Y, Lu Z and Gao H: Contrast-enhanced computerized tomography combined with a targeted nanoparticle contrast agent for screening for early-phase non-small cell lung cancer. *Exp Ther Med* 14: 5063-5068, 2017.
- Li N, Han L and Jing H: Contrast-enhanced ultrasound with a novel nanoparticle contrast agent for clinical diagnosis in patients with non-small cell lung cancer. *Exp Ther Med* 14: 3768-3773, 2017.
- Nicholls FJ, Rotz MW, Ghuman H, MacRenaris KW, Meade TJ and Modo M: DNA-gadolinium-gold nanoparticles for in vivo T1 MR imaging of transplanted human neural stem cells. *Biomaterials* 77: 291-306, 2016.
- Xiao L, Tian X, Harihar S, Li Q, Li L, Welch DR and Zhou A: Gd₂O₃-doped silica @ Au nanoparticles for in vitro imaging cancer biomarkers using surface-enhanced Raman scattering. *Spectrochim Acta A Mol Biomol Spectrosc* 181: 218-225, 2017.
- Deng H, Chen F, Yang C, Chen M, Li L and Chen D: Effect of Eu doping concentration on fluorescence and magnetic resonance imaging properties of Gd₂O₃:Eu³⁺ nanoparticles used as dual-modal contrast agent. *Nanotechnology* 29: 415601, 2018.
- Zhang H, Wang T, Zheng Y, Yan C, Gu W and Ye L: Comparative toxicity and contrast enhancing assessments of Gd₂O₃@BSA and MnO₂@BSA nanoparticles for MR imaging of brain glioma. *Biochem Biophys Res Commun* 499: 488-492, 2018.
- Wirth LJ, Tahara M, Robinson B, Francis S, Brose MS, Habra MA, Newbold K, Kiyota N, Dutcus CE, Mathias E, *et al*: Treatment-emergent hypertension and efficacy in the phase 3 Study of (E7080) lenvatinib in differentiated cancer of the thyroid (SELECT). *Cancer* 124: 2365-2372, 2018.

30. Shao Y, Tian X, Hu W, Zhang Y, Liu H, He H, Shen Y, Xie F and Li L: The properties of Gd₂O₃-assembled silica nano-composite targeted nanoprobe and their application in MRI. *Biomaterials* 33: 6438-6446, 2012.
31. Wojcik E and Kulpa JK: Pro-gastrin-releasing peptide (ProGRP) as a biomarker in small-cell lung cancer diagnosis, monitoring and evaluation of treatment response. *Lung Cancer (Auckl)* 8: 231-240, 2017.
32. Reck M and Rabe KF: Precision diagnosis and treatment for advanced non-small-cell lung cancer. *N Engl J Med* 377: 849-861, 2017.
33. Zhou GH, Yang WH and Sun B: Clinical impact of serum miR-661 in diagnosis and prognosis of non-small cell lung cancer. *Eur Rev Med Pharmacol Sci* 21: 5696-5701, 2017.
34. Labbé C, Anderson M, Simard S, Tremblay L, Laberge F, Vaillancourt R and Lacasse Y: Wait times for diagnosis and treatment of lung cancer: A single-centre experience. *Curr Oncol* 24: 367-373, 2017.
35. Tzouveleki A, Spagnolo P, Bonella F, Vancheri C, Tzilas V, Crestani B, Kreuter M and Bouros D: Patients with IPF and lung cancer: Diagnosis and management. *Lancet Respir Med* 6: 86-88, 2018.
36. Li Y, Jin G and Su D: Comparison of Gadolinium-enhanced MRI and 18FDG PET/PET-CT for the diagnosis of brain metastases in lung cancer patients: A meta-analysis of 5 prospective studies. *Oncotarget* 8: 35743-35749, 2017.
37. Wang H, Machtaler S, Bettinger T, Lutz AM, Luong R, Bussat P, Gambhir SS, Tranquart F, Tian L and Willmann JK: Molecular imaging of inflammation in inflammatory bowel disease with a clinically translatable dual-selectin-targeted US contrast agent: Comparison with FDG PET/CT in a mouse model. *Radiology* 267: 818-829, 2013.
38. Aschoff P, Plathow C, Beyer T, Lichy MP, Erb G, Öksüz MÖ, Claussen CD and Pfannenbergl C: Multiphase contrast-enhanced CT with highly concentrated contrast agent can be used for PET attenuation correction in integrated PET/CT imaging. *Eur J Nucl Med Mol Imaging* 39: 316-325, 2012.
39. Hyafil F, Cornily JC, Rudd JH, Machac J, Feldman LJ and Fayad ZA: Quantification of inflammation within rabbit atherosclerotic plaques using the macrophage-specific CT contrast agent N1177: A comparison with 18F-FDG PET/CT and histology. *J Nucl Med* 50: 959-965, 2009.
40. Gao J, Li L, Liu X, Guo R and Zhao B: Contrast-enhanced magnetic resonance imaging with a novel nano-size contrast agent for the clinical diagnosis of patients with lung cancer. *Exp Ther Med* 15: 5415-5421, 2018.
41. An YS, Sheen SS, Oh YJ, Hwang SC and Yoon JK: Nonionic intravenous contrast agent does not cause clinically significant artifacts to 18F-FDG PET/CT in patients with lung cancer. *Ann Nucl Med* 21: 585-592, 2007.
42. Nishio M, Horai T, Horiike A, Nokihara H, Yamamoto N, Takahashi T, Murakami H, Yamamoto N, Koizumi F, Nishio K, *et al*: Phase I study of lenvatinib combined with carboplatin and paclitaxel in patients with non-small-cell lung cancer. *Br J Cancer* 109: 538-544, 2013.
43. Wu Y, Zhang H, Xiang J, Mao Z, Shen G, Yang F, Liu Y, Wang W, Du N, Zhang J and Tang Y: Ultrasensitive and high specific detection of non-small-cell lung cancer cells in human serum and clinical pleural effusion by aptamer-based fluorescence spectroscopy. *Talanta* 179: 501-506, 2018.
44. Cai NL, Lau ATY, Yu FY, Wu DD, Dai LJ, Mo HY, Lin CM and Xu YM: Purification and characterization of a highly specific polyclonal antibody against human extracellular signal-regulated kinase 8 and its detection in lung cancer. *PLoS One* 12: e0184755, 2017.
45. Sun Y, Liu S, Qiao Z, Shang Z, Xia Z, Niu X, Qian L, Zhang Y, Fan L, Cao CX and Xiao H: Systematic comparison of exosomal proteomes from human saliva and serum for the detection of lung cancer. *Anal Chim Acta* 982: 84-95, 2017.
46. Ohliger MA, von Morze C, Marco-Rius I, Gordon J, Larson PEZ, Bok R, Chen HY, Kurhanewicz J and Vigneron D: Combining hyperpolarized¹³C MRI with a liver-specific gadolinium contrast agent for selective assessment of hepatocyte metabolism. *Magn Reson Med* 77: 2356-2363, 2017.
47. Uran S, Landmark K, Normann PT, Hals PA, Toft KG and Skotland T: A respiration-metabolism chamber system and a GC-MS method developed for studying exhalation of perfluorobutane in rats after intravenous injection of the ultrasound contrast agent Sonazoid. *J Pharm Biomed Anal* 39: 746-751, 2005.
48. Skotland T, Sontum PC and Oulie I: In vitro stability analyses as a model for metabolism of ferromagnetic particles (Clariscan), a contrast agent for magnetic resonance imaging. *J Pharm Biomed Anal* 28: 323-329, 2002.



This work is licensed under a Creative Commons Attribution-NonCommercial-NoDerivatives 4.0 International (CC BY-NC-ND 4.0) License.