

# Barium esophagogram in various esophageal diseases: A pictorial essay

Uma Debi, Madhurima Sharma, Lokesh Singh, Anindita Sinha

Department of Radiodiagnosis and Imaging, PGIMER Chandigarh, India

**Correspondence:** Dr. Uma Debi, Department of Radiodiagnosis and Imaging, PGIMER, Chandigarh, India. E-mail: debi\_uma@yahoo.co.in

## Abstract

Recent years have seen a decline in number of barium procedures due to wider availability of cross sectional imaging modalities. Though use of barium esophagography/barium swallow has decreased in day to day clinical practice, it still remains a valuable test for structural and functional evaluation of esophagus. It can be performed as single or double contrast examination or as a multiphasic examination comprising upright double contrast views followed by prone single contrast views. This pictorial essay demonstrates imaging features of various esophageal diseases on barium esophagogram.

**Key words:** Barium swallow; diverticula; esophagus; motility disorder; tumours; webs

## Introduction

More emphasis on cross-sectional imaging modalities in recent years has decreased the use of barium procedures. However, barium swallow can provide valuable information regarding functional evaluation of pharynx, mucosal abnormalities of the esophagus, and its motility disorders. It has the advantage of easy availability and inexpensive as compared with cross-sectional imaging modalities. Barium swallow still continues to be the initial imaging modality in the evaluation of dysphagia, gastroesophageal reflux, and other esophageal diseases beyond the scope of endoscopies. Also, simultaneous structural and functional evaluation of esophagus provides additional advantage over endoscopy and cross-sectional imaging. Barium swallow can be performed as single- or double-contrast study. Double-contrast swallow is useful in conditions requiring better mucosal details such as gastroesophageal reflux disease (GERD) and its complications, carcinoma of esophagus, and infectious esophagitis. Single-contrast swallow is useful in evaluation of motility disorders and

strictures. The purpose of this article is to review imaging findings of various esophageal diseases on barium swallow. Various esophageal diseases are discussed under five subheadings, viz., esophageal webs, rings, and diverticulae; motility disorders; esophagitis; esophageal tumors; and miscellaneous esophageal diseases.

## Imaging technique

All the barium examinations were carried out over a span of 10 years (2004--2013) in the Department of Radiology. The examinations were performed after per oral administration of high density barium sulphate (200% w/v) suspension obtained after diluting commercially available high density barium sulphate powder (microbar-HD; Eskay chemicals, Mumbai) with 70 ml of water. For double-contrast studies, patients were made to ingest effervescent granules followed by ingestion of barium suspension. Upright left posterior oblique (LPO) views were taken, followed by mucosal relief views to evaluate for fold thickness. Patients were asked to turn 360° so as to coat gastric fundus. Recumbent

This is an open access journal, and articles are distributed under the terms of the Creative Commons Attribution-NonCommercial-ShareAlike 4.0 License, which allows others to remix, tweak, and build upon the work non-commercially, as long as appropriate credit is given and the new creations are licensed under the identical terms.

**For reprints contact:** reprints@medknow.com

**Cite this article as:** Debi U, Sharma M, Singh L, Sinha A. Barium esophagogram in various esophageal diseases: A pictorial essay. Indian J Radiol Imaging 2019;29:141-54.

### Access this article online

#### Quick Response Code:



**Website:**  
www.ijri.org

**DOI:**  
10.4103/ijri.IJRI\_465\_18

right lateral views were taken to evaluate cardiac rosette and gastric fundus. Prone right anterior oblique (RAO) views were taken to evaluate esophageal motility. Finally, patients were turned from supine to right posterior oblique and right lateral position under fluoroscopy to see for gastroesophageal reflux.

**Esophageal webs, rings, and diverticulae**

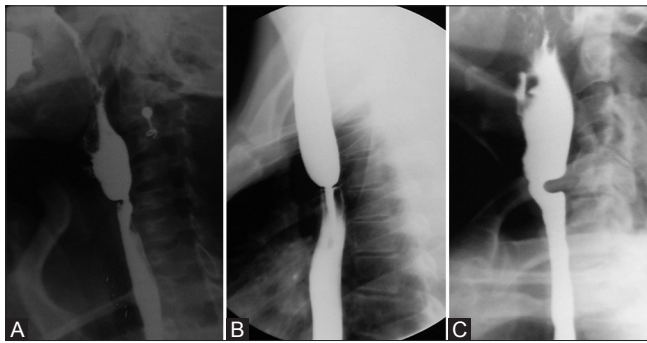
**Webs**

Webs are thin folds of mucosa seen along anterior wall of hypopharynx and proximal cervical esophagus.<sup>[1]</sup> On barium swallow, they manifest as shelf-like filling defect (1-2 mm in thickness) along the anterior wall of cervical esophagus [Figure 1A]. In cases of partial obstruction, jet phenomenon can be seen<sup>[2,3]</sup> [Figure 1B]. Occasionally, prominent cricopharyngeal muscle, seen as protrusion from posterior pharyngeal wall, can be confused for esophageal web [Figure 1C].

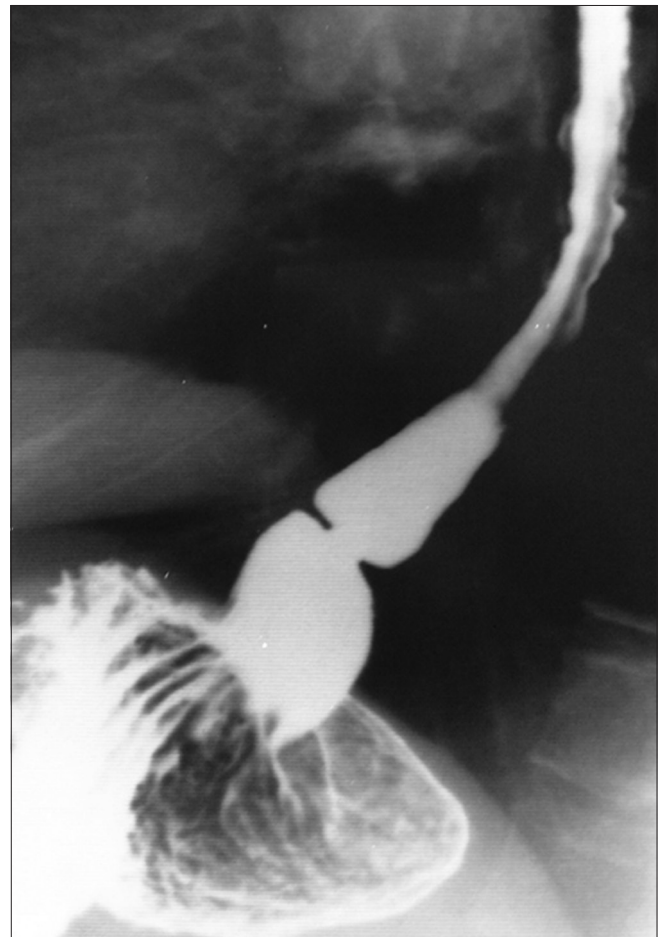
**Rings**

Lower esophageal rings are a common finding on barium swallow, mostly being asymptomatic. Schatzki's ring is a

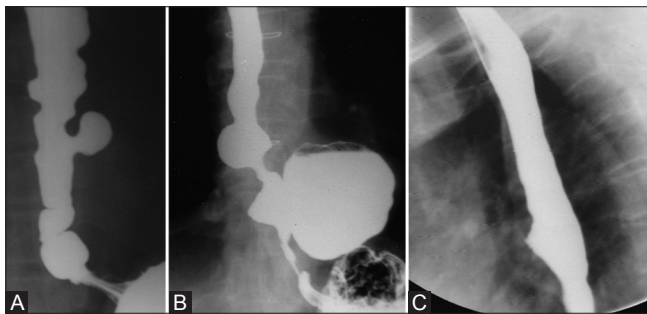
symptomatic esophageal ring, presenting as dysphagia. It is thought to develop from scarring in cases of reflux esophagitis. On barium swallow, ring manifests as smooth concentric segment of luminal narrowing (2-3 mm in thickness), usually located above hiatal hernia [Figure 2].<sup>[4]</sup> Rings more than 20 mm in diameter are asymptomatic,



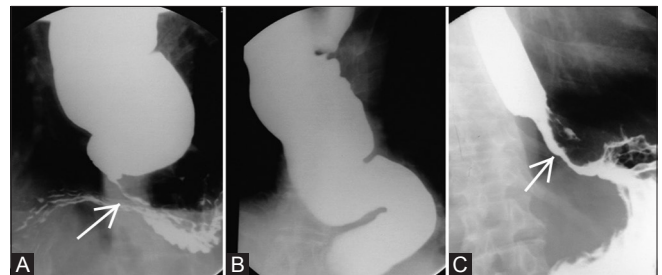
**Figure 1 (A-C):** (A) Upright LPO view of single-contrast barium swallow demonstrates a shelf-like filling defect along the anterior wall of hypopharynx, at pharyngo-esophageal junction s/o web. (B) Jet phenomenon associated with cervical web, usually seen in cases of partial obstruction. (C) Prominent cricopharyngeus muscle may mimic a web. However, it is seen along the posterior wall



**Figure 2:** Prone RAO view of single-contrast barium swallow demonstrating Schatzki ring



**Figure 3 (A-C):** (A) Upright AP view of single-contrast barium swallow shows a pulsion diverticulum. Also, note multiple nonperistaltic contractions associated with motility dysfunction. (B) Upright AP view of single-contrast barium swallow showing a large epiphrenic diverticulum. (C) Upright lateral view of single-contrast barium swallow demonstrating a traction diverticulum arising from anterior wall of mid esophagus. Note the triangular appearance of traction diverticulum



**Figure 4 (A-C):** (A) Primary achlasia: Prone single-contrast barium swallow showing dilated esophagus with tapered beak-like narrowing at GE junction (arrow). On fluoroscopy, primary peristalsis in esophagus was absent. (B) Dilated and tortuous esophagus in a case of primary achlasia (C) Secondary achlasia: Prone RAO view showing mildly dilated esophagus with narrowing involving lower thoracic esophagus and GE junction, with mucosal irregularity (arrow). Note greater length of narrowed segment and less dilatation of esophagus in comparison to (A)

whereas rings having diameter less than 13 mm invariably cause dysphagia.<sup>[4]</sup>

#### *Diverticulae*

Diverticulae of esophagus have been categorized as pulsion diverticulae, traction diverticulae, and intramural pseudodiverticulosis.

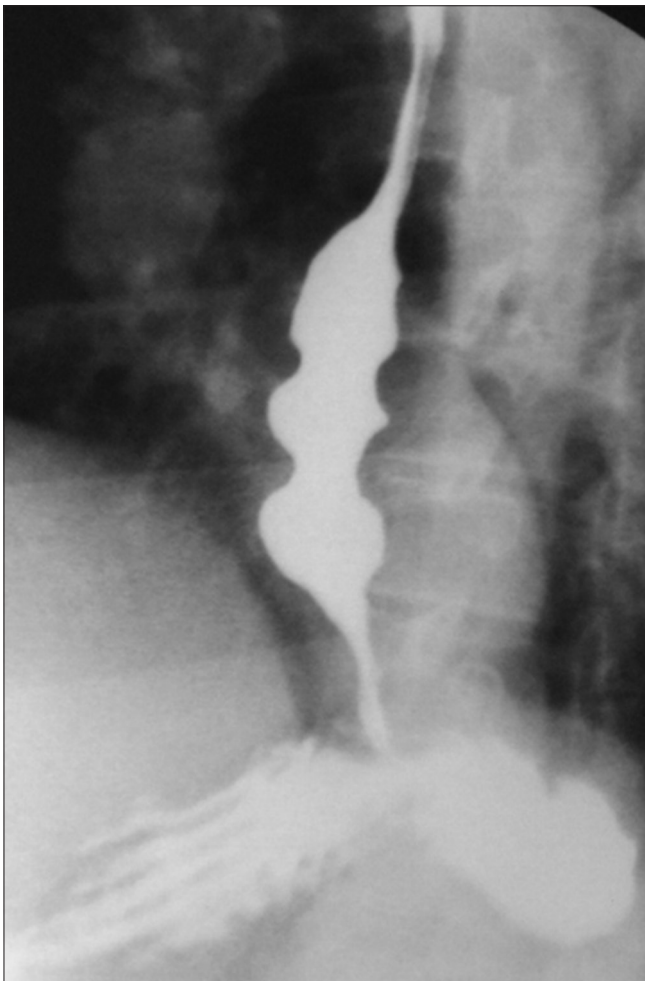
Pulsion diverticulae occur in lower esophagus and are usually associated with motility disorders of esophagus. These are false diverticulae, lacking the muscular layer. On barium swallow, they manifest as broad-based contrast-filled outpouchings showing barium retention after emptying of esophagus [Figure 3A, 3B].<sup>[5]</sup>

Traction diverticulae on the other hand are true diverticulae, seen in mid esophagus. They are usually caused by scarring in perihilar lymph nodes caused by tuberculosis or histoplasmosis.<sup>[5]</sup> On barium swallow, traction diverticulae have a triangular and tented appearance and show emptying with collapse of esophagus [Figure 3C] (as they contain all the esophageal layers).<sup>[5]</sup>

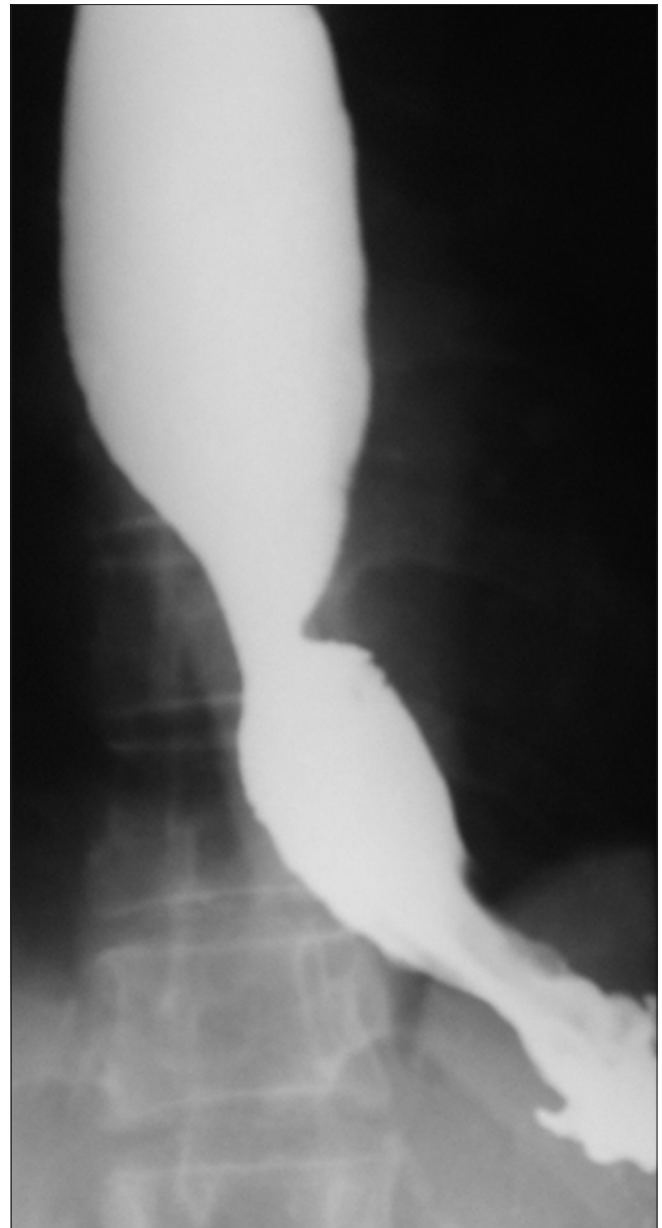
Esophageal intramural pseudodiverticulosis can be associated with esophageal strictures or occur in isolation. When occurring alone, it is asymptomatic. Intramural pseudodiverticulosis is dilatation of ducts of esophageal deep mucosal glands. On barium swallow, it appears as multiple contrast-filled outpouchings parallel to long axis of esophagus.<sup>[6]</sup>

#### **Motility disorders of esophagus**

Motility disorders can be of primary or secondary types. In primary motility disorders, esophagus is the main organ involved. Secondary motility disorders occur as manifestation

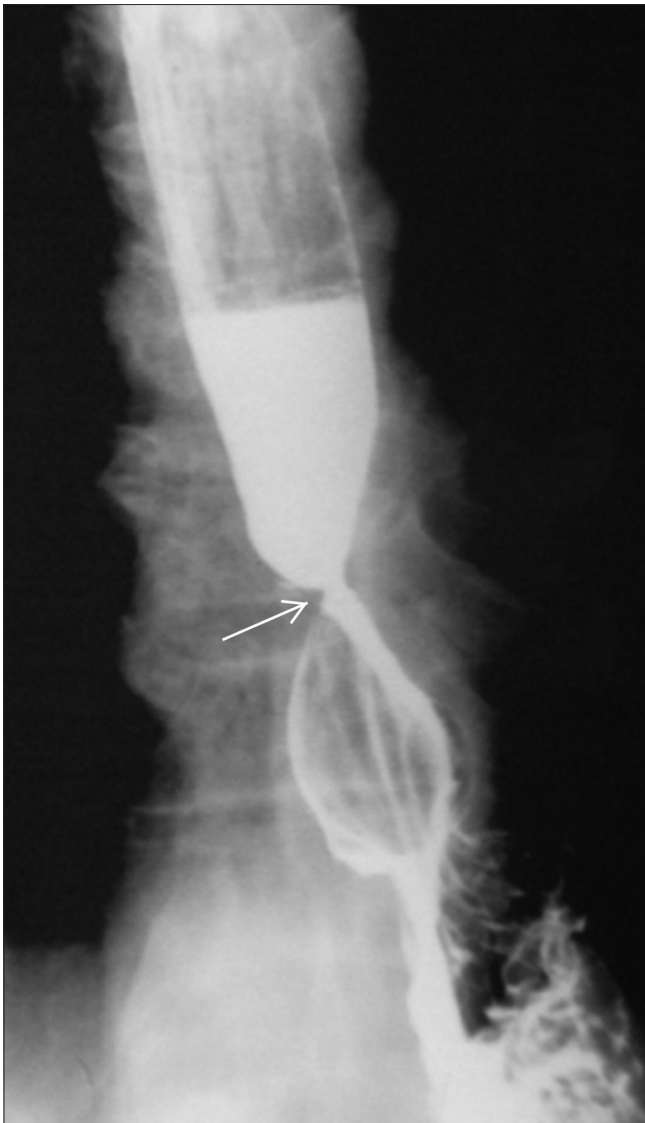

**Figure 5:** Diffuse esophageal spasm: upright single-contrast barium swallow image showing multiple nonperistaltic contractions in esophagus giving classic "corkscrew appearance"



**Figure 6:** Upright single-contrast barium swallow in a patient of scleroderma showed dilated esophagus with absent primary peristalsis in mid and lower esophagus. Also GE junction was patulous with presence of reflux and sliding hiatus hernia (differentiating it from achalasia)



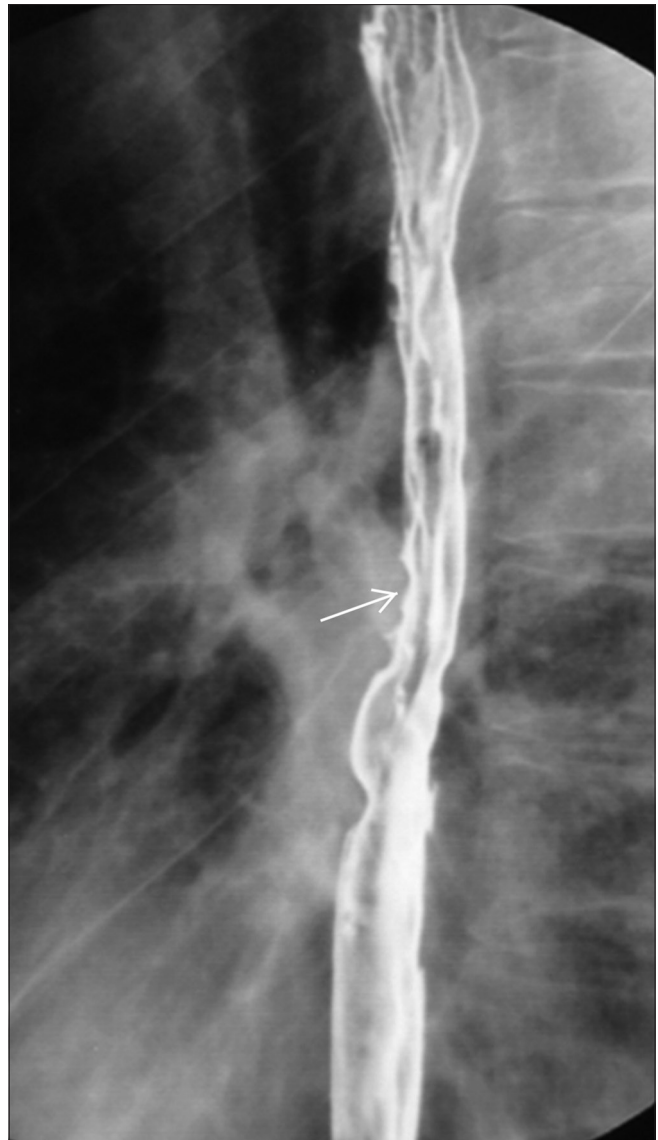


**Figure 7:** Peptic stricture (arrow) in a patient with long standing history of gastroesophageal reflux. Upright double-contrast barium swallow shows sliding hiatus hernia with segment of smooth, concentric narrowing in lower esophagus. Also note proximal hold up of the barium

of a variety of systemic diseases or secondary to injury to esophagus.<sup>[7]</sup> Primary motility disorders include achalasia and its variants, diffuse esophageal spasm (DES), nutcracker esophagus, nonspecific esophageal motility disorder, and hypertensive lower esophageal sphincter (LES).<sup>[7]</sup>

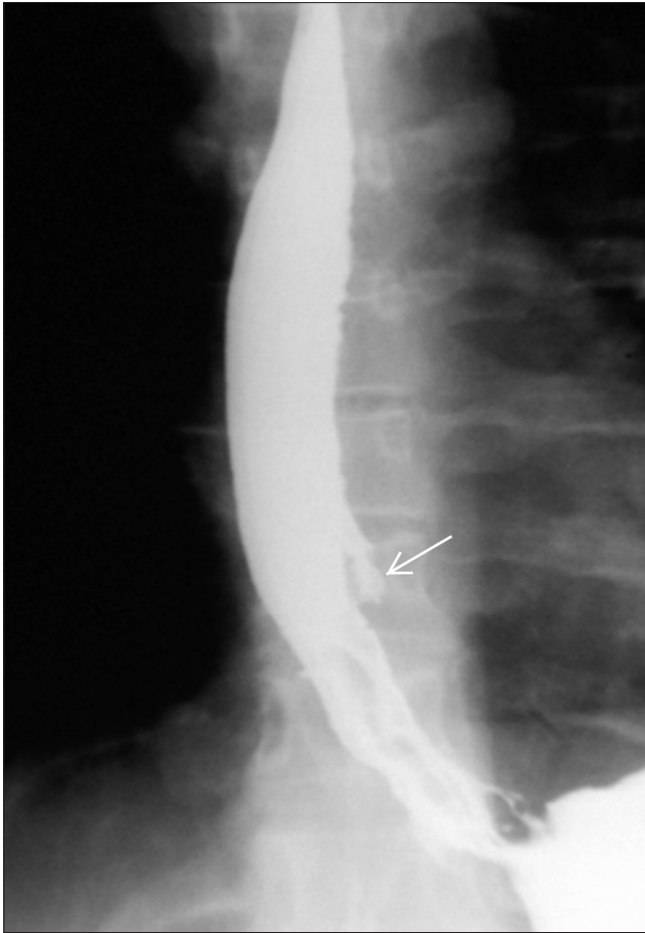
#### *Achalasia*

Primary achalasia is idiopathic condition occurring because of defect in myenteric plexus. On manometry, it is characterized by incomplete relaxation of LES, increased resting pressure of LES, and absent primary peristalsis. On barium swallow, esophagus is dilated with absent primary peristalsis and shows distal smooth beak-like tapering near GE junction [Figure 4A]. Sometimes, esophagus is grossly dilated and tortuous termed as "sigmoid esophagus"[Figure 4B].<sup>[7]</sup> Primary achalasia

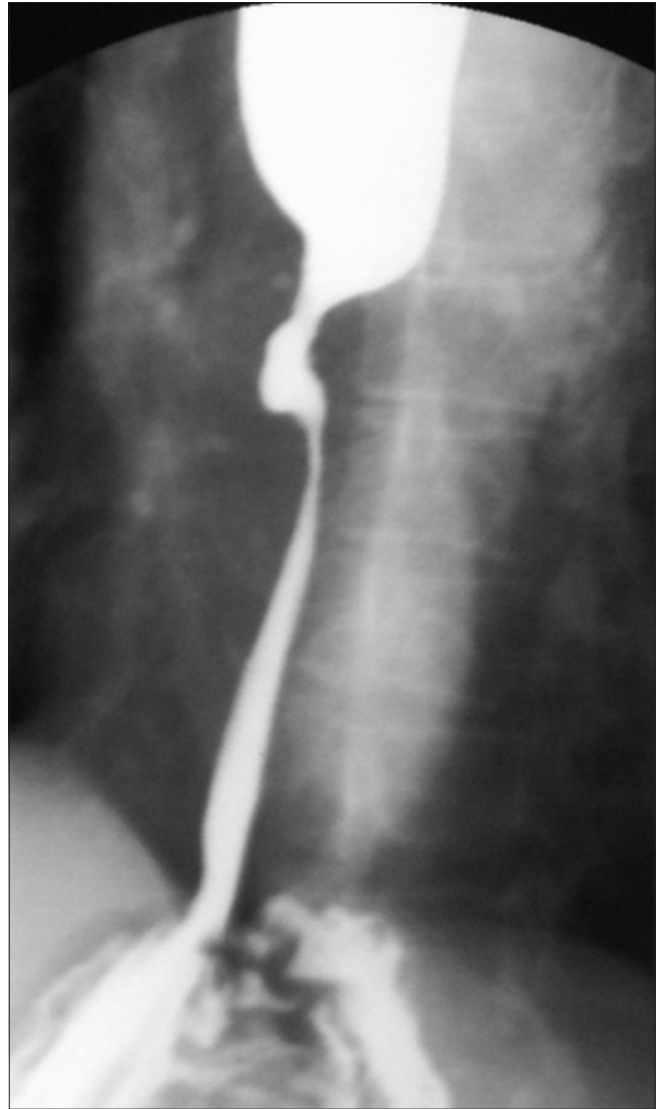


**Figure 8:** Barrett's esophagus: Upright LPO image of double-contrast barium swallow showing mild narrowing (arrow) and reticular pattern in columnar epithelium at mid thoracic esophagus. Gastroesophageal reflux was also present in the same patient. Endoscopic biopsy revealed columnar metaplasia

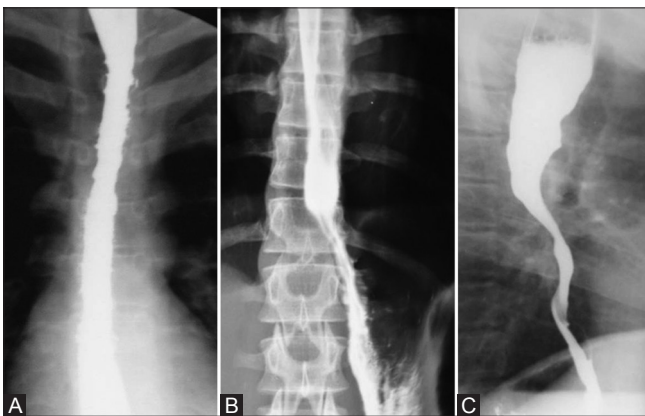
should be differentiated from secondary achalasia, which can occur secondary to tumors of GE junction or cardiac that can destroy the ganglion cells in GE junction, thereby interfering with normal peristaltic activity. In secondary achalasia, narrowed segment is greater in length (>3.5 cm) than in primary achalasia with presence of mucosal irregularity, nodularity, and ulceration [Figure 4C].<sup>[8]</sup> Also clinically, the patients with secondary achalasia are old (usually more than 60 years) and present with recent onset dysphagia (duration less than 6 months) with weight loss, in contrast to primary achalasia patients who present with history of long standing dysphagia at younger age.<sup>[9]</sup> Two variants of achalasia with atypical manometric findings have been described: vigorous achalasia and early achalasia.<sup>[7]</sup> In vigorous achalasia, multiple repetitive



**Figure 9:** HIV esophagitis: Upright single-contrast barium swallow image showing giant flat ulcer (arrow) arising from left posterolateral wall of mid esophagus in an HIV-positive patient



**Figure 10:** Stricture secondary to radiation: Case of squamous cell carcinoma of mid esophagus, postradiotherapy status. Barium swallow done 9 months after the completion of radiotherapy revealed long segment of concentric smooth narrowing involving distal esophagus



**Figure 11 (A-C):** Caustic esophagitis: Upright frontal (A and B) and lateral (C) single contrast barium swallow images demonstrating long segment stricture involving distal esophagus in a patient with history of accidental lye ingestion. Also note presence of intramural pseudodiverticulae associated with the stricture (B)

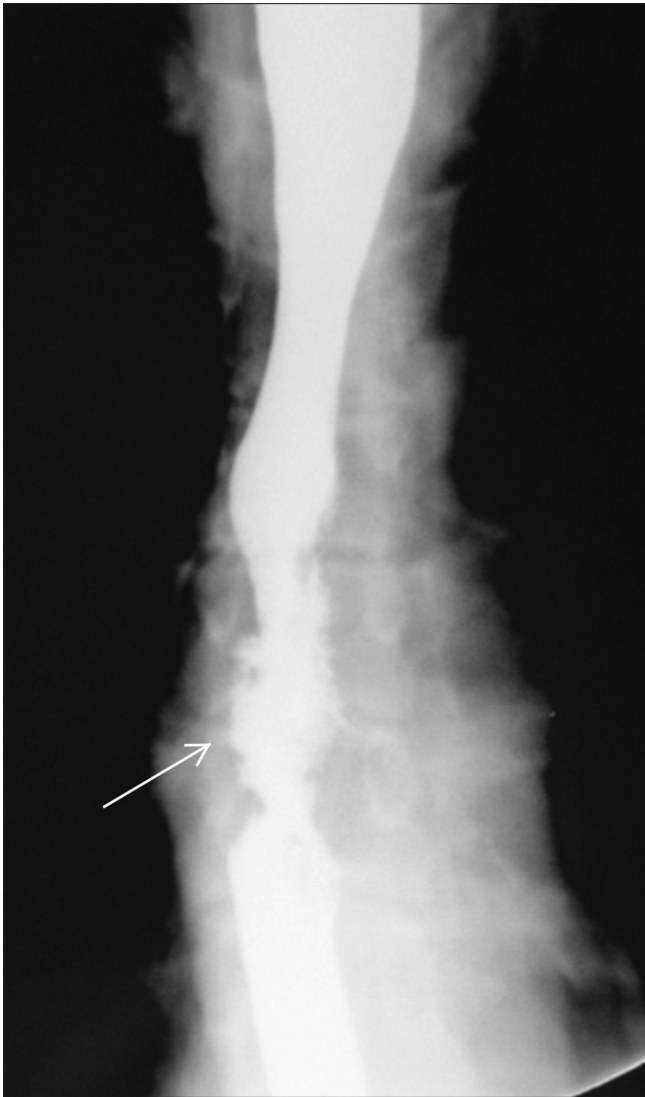contractions of LES are present and patient may complain of chest pain. In early achalasia, there is normal relaxation of LES with absent primary peristalsis. In both these variant, patients tend to present at younger age with less dilatation of esophagus on barium studies.<sup>[7]</sup>

#### *Diffuse esophageal spasm (DES)*

DES is characterized by intermittent absence of primary peristalsis with simultaneous nonperistaltic contractions, producing classic “corkscrew” or “rosary bead” appearance of esophagus on barium [Figure 5].<sup>[10]</sup> However, Prabhakar *et al.*<sup>[11]</sup> found that lumen obliterating nonperistaltic contractions were found in only 15% of patients. In rest of the patients, nonperistaltic contractions of mild to moderate severity were present without classic corkscrew esophagus.<sup>[11]</sup>

Other motility disorders such as nutcracker esophagus and nonspecific esophageal motility disorder are diagnosed on manometric studies. Barium swallow in these patients may be normal or may have nonspecific findings of nonperistaltic contractions.<sup>[7]</sup>

Secondary esophageal motility disorders can occur because of a variety of causes (collagen vascular diseases, infections, diabetes mellitus, alcoholism, endocrine diseases, neuromuscular disorders, physical and chemical agents)<sup>[7,12-18]</sup> and often have nonspecific radiographic findings. Most common collagen vascular disorders leading to esophageal motility disorder are scleroderma, mixed connective tissue disease, polymyositis, and dermatomyositis.<sup>[16-20]</sup> Manometric and radiological findings in these diseases are similar. Motility abnormalities in scleroderma occur because of fibrosis of smooth muscles in lower esophagus. Primary peristalsis is absent in smooth muscle portion of esophagus in scleroderma mimicking achalasia.<sup>[7]</sup> However, in scleroderma, LES is patulous (in contrast to narrowing at LES in achalasia) with presence of gastroesophageal reflux and hiatus hernia [Figure 6]. Peptic stricture secondary to reflux esophagitis can also be seen in these patients.<sup>[7]</sup>

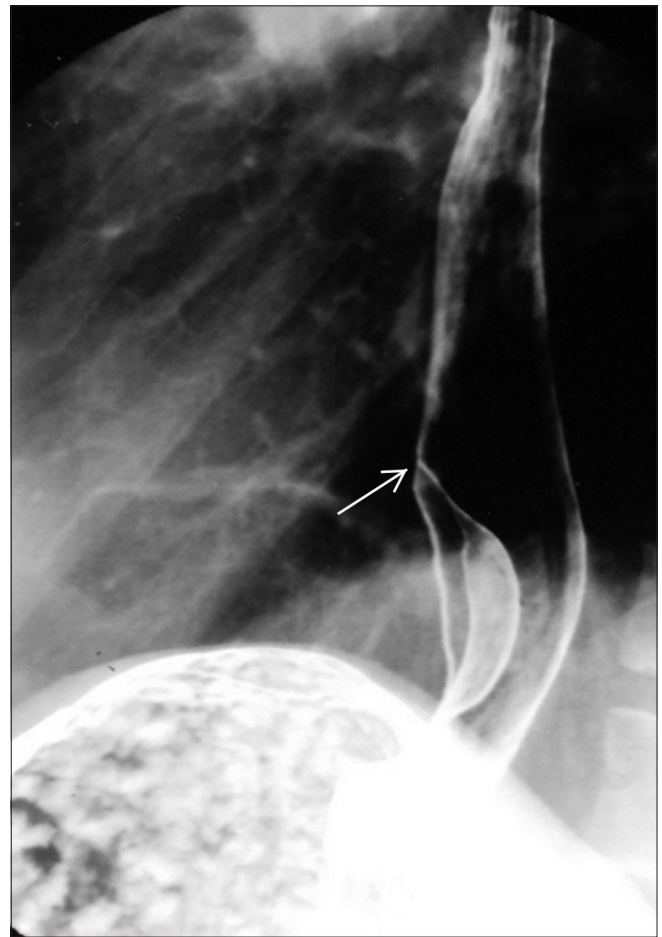


**Figure 12:** Drug-induced esophagitis: Upright barium swallow image demonstrating ulceration (arrow) in mid esophagus with esophageal spasm. The esophagitis was related to intake of doxycycline

## Esophagitis

### Reflux esophagitis

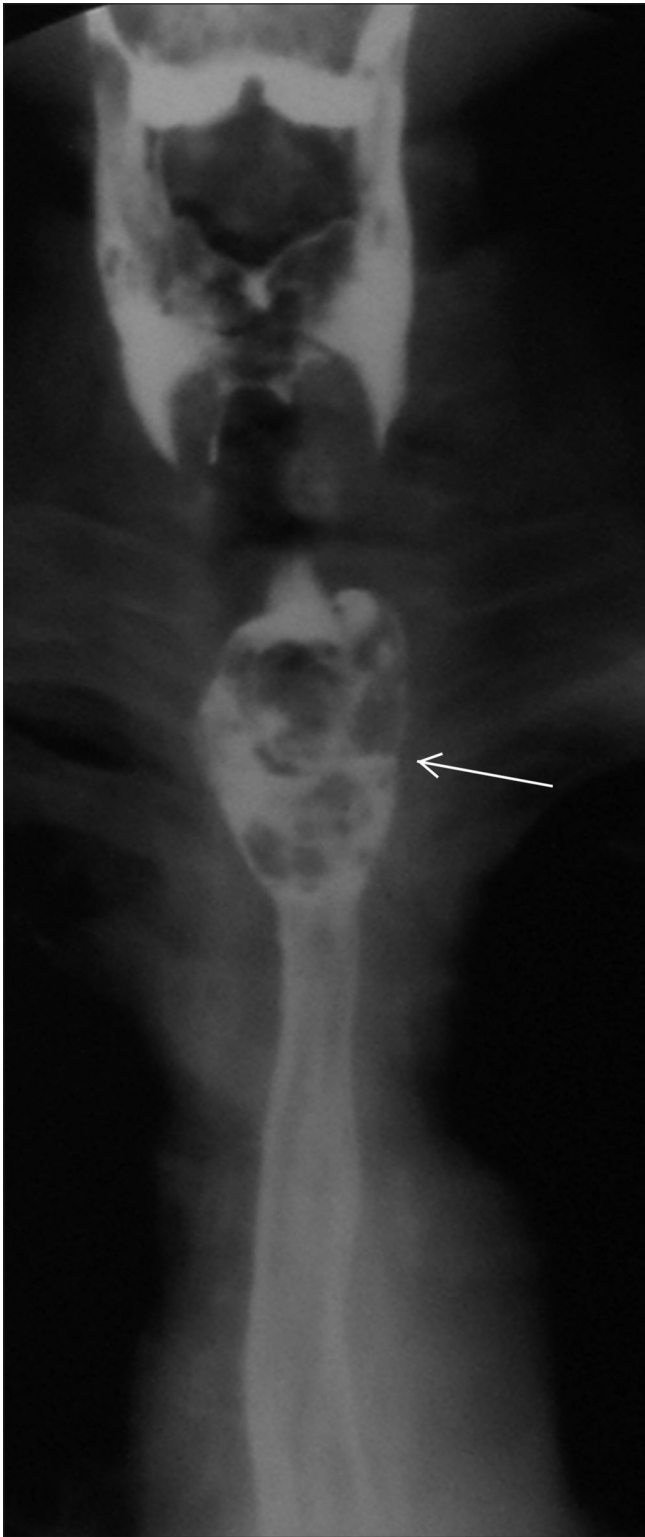Reflux esophagitis is most common manifestation of GERD and is the most common inflammatory condition of the esophagus. Because of its ability to provide better mucosal details, sensitivity of double contrast barium swallow has been shown to approach 90% in diagnosing reflux esophagitis.<sup>[21,22]</sup> In mild reflux esophagitis, finely nodular or granular mucosa is seen on barium swallow, which manifests as continuous area extending proximally from gastroesophageal junction.<sup>[23,24]</sup> Ulceration, erosions, longitudinal fold thickening, and esophagogastric polyp can be seen in moderate to severe reflux esophagitis. Ulceration in GERD is almost always seen in lower third of esophagus extending proximally from GE junction. On barium swallow, it can have a linear, stellate, or punctate configuration surrounded by edematous mucosa or radiating folds.<sup>[25]</sup> Longitudinal fold thickening is nonspecific feature of reflux esophagitis occurring because of extension of inflammation and edema to submucosa. Scarring of esophagus in reflux esophagitis manifests as puckering, flattening, or sacculations of adjacent



**Figure 13:** Leiomyoma: Upright double-contrast barium swallow image showing smooth crescentic filling defect in distal esophagus forming obtuse angle with esophageal wall (arrow) characteristic of a submucosal mass



esophageal wall. Fixed transverse folds can develop because of scarring, resulting in shortening of esophagus. This usually manifests as step ladder configuration on barium studies.<sup>[26]</sup>



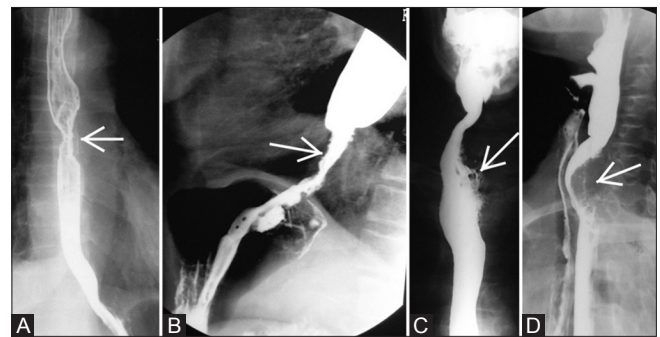
**Figure 14:** Fibrovascular polyp: Upright barium swallow image showing expansion of cervical and proximal thoracic esophagus with polypoidal filling defect (arrow)

Peptic stricture formation is the most significant finding in reflux esophagitis.<sup>[27]</sup> Peptic stricture is almost always present with associated sliding hiatus hernia and is seen as area of concentric luminal narrowing with smooth tapering [Figure 7]. Sometimes it can manifest as ring-like narrowing, mimicking Schatzki's ring in patients with dysphagia.<sup>[25]</sup> If stricture is associated with mucosal irregularity, nodularity, or ulceration, malignancy should be ruled out.

Barrett's esophagus occurs from columnar metaplasia of distal esophagus in reflux esophagitis. It develops in ~10% of all patients with reflux esophagitis,<sup>[28]</sup> and manifests as mid esophageal stricture [Figure 8], ulceration, and reticular mucosal pattern.<sup>[29]</sup> Reticular mucosal pattern is seen as small barium-filled crevices in esophagus resembling area gastricae, and is most specific finding in Barrett's esophagus. However, it is seen in only 5-10% of patients.<sup>[30,31]</sup>

#### *Infectious esophagitis*

*Candida albicans* is commonest cause of infectious esophagitis occurring in immunocompromised patients, particular in acquired immunodeficiency syndrome (AIDS). However, it can also be secondary to local stasis in esophageal motility disorders<sup>[32]</sup> or diabetes mellitus. On barium swallow, candida esophagitis presents with multiple irregular plaque such as lesions, oriented along the long axis of the esophagus with intervening normal mucosa.<sup>[33]</sup> A fulminant form can occur in AIDS patients producing a "shaggy esophagus" characterized by numerous plaques and pseudomembranes with trapping of barium.<sup>[34]</sup> "Foamy esophagus" can occur in patients with motility disorders (like achlasia, scleroderma), seen as numerous



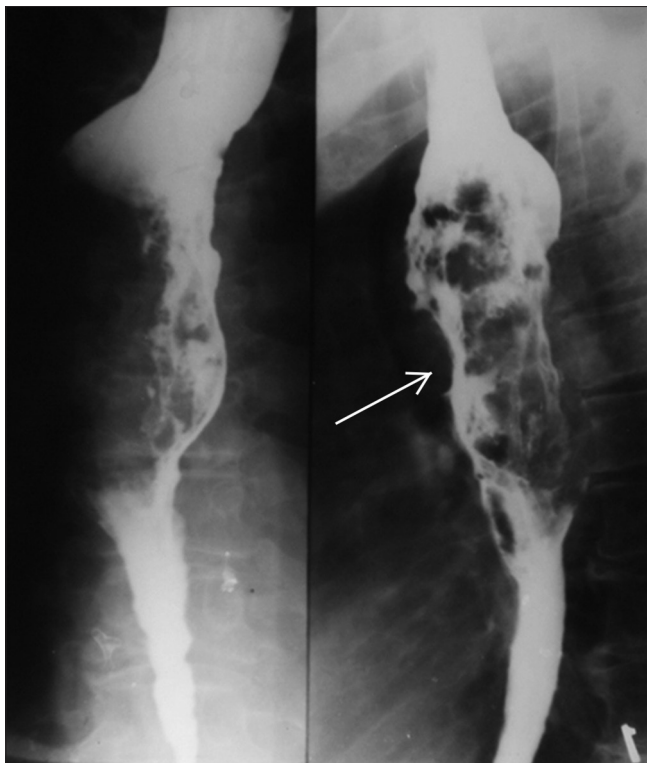**Figure 15 (A-D):** Esophageal carcinoma: (A) Early esophageal cancer seen as plaque-like lesion with mucosal irregularity and mild reduce distensibility (arrow) in mid thoracic esophagus on double-contrast barium swallow. (B) Infiltrative lesion: Prone RAO barium swallow image showing irregular infiltrative lesion (arrow) with shouldering in distal esophagus extending till GE junction. Also note proximal dilatation of esophagus. Endoscopic biopsy revealed the lesion to be adenocarcinoma. (C) Ulcerative lesion: Upright single-contrast barium swallow image demonstrating irregular ulcerative lesion in upper esophagus (arrow) without significant luminal narrowing. (D) Polypoidal lesion: Upright lateral view of single-contrast barium swallow showing polypoidal filling defect in upper esophagus (arrow). Patient had severe dysphagia and aspirated small amount of barium during the procedure

tiny bubbles in column of barium.<sup>[35]</sup> This results from yeast infection.

Herpes esophagitis occurs as opportunistic infection in immunocompromised patients. However, occasionally, it can occur in immunocompetent patients with a self-limiting course.<sup>[36]</sup> In herpes, esophagitis multiple small ulcers, surrounded by radiolucent halo, are seen on double-contrast barium swallow on a background of normal mucosa.<sup>[37,38]</sup> The ulcers can have a ring-like, stellate, or punctate configuration. In immunocompetent patients, multiple tiny clustered ulcers are seen in mid esophagus below the level of left main bronchus.<sup>[36]</sup>

Cytomegalovirus (CMV) is another important cause for esophagitis in AIDS patients. It manifests as multiple small or giant oval or diamond-shaped ulcers (several centimetres in length) on double-contrast barium swallow, surrounded by radiolucent halo (representing oedematous mucosa).<sup>[39]</sup>

HIV esophagitis also presents as giant ulcers on double-contrast barium swallow [Figure 9], surrounded by rim of edematous mucosa and is indistinguishable from CMV esophagitis. Sometimes, satellite ulcers can be seen around the giant ulcer.<sup>[40,41]</sup> Endoscopy with brushings or biopsy is required for differentiation between CMV and HIV esophagitis, as treatment of former entity requires relatively toxic antiviral drugs.<sup>[42]</sup>



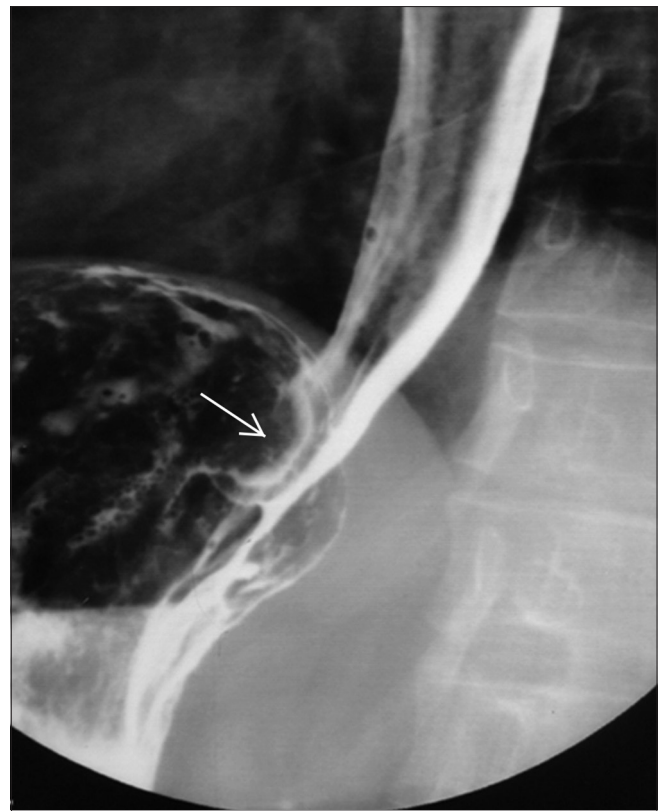**Figure 16:** Spindle cell carcinoma: Upright frontal and LPO images of barium swallow demonstrating irregular polypoidal filling defect (arrow) in mid esophagus causing expansion of esophageal lumen

### *Radiation-induced esophagitis*

High dose external beam radiotherapy used for treatment of malignant tumors involving lung, esophagus, or mediastinum can cause damage to the esophagus. A radiation dose of 45--60 Gy can cause severe esophagitis with irreversible damage. Smaller doses of 20--45 Gy can cause milder form of self-limiting esophagitis without permanent sequelae.<sup>[43]</sup> Acute radiation esophagitis usually occurs 2--4 weeks after the completion of radiotherapy and is self-limiting. On double-contrast studies, esophageal mucosa has granular appearance with ulceration and reduced luminal distensibility.<sup>[44]</sup> Chronic esophagitis manifests at 4--8 months after completion of radiotherapy in form of radiation strictures. On barium swallow, radiation strictures appear as long segments of concentric and smooth narrowing [Figure 10].<sup>[45]</sup>

### *Caustic esophagitis*

Ingestion of lye and other corrosives can cause severe esophagitis with formation of stricture at later stages. Endoscopy is considered the best modality to assess for esophageal damage. Contrast study in acute phase is performed with water-soluble contrast agent if perforation is suspected.<sup>[43]</sup> The study may demonstrate reduced distensibility of esophagus with ulceration and leak of contrast from the esophagus.<sup>[43]</sup> 10--40% of patients



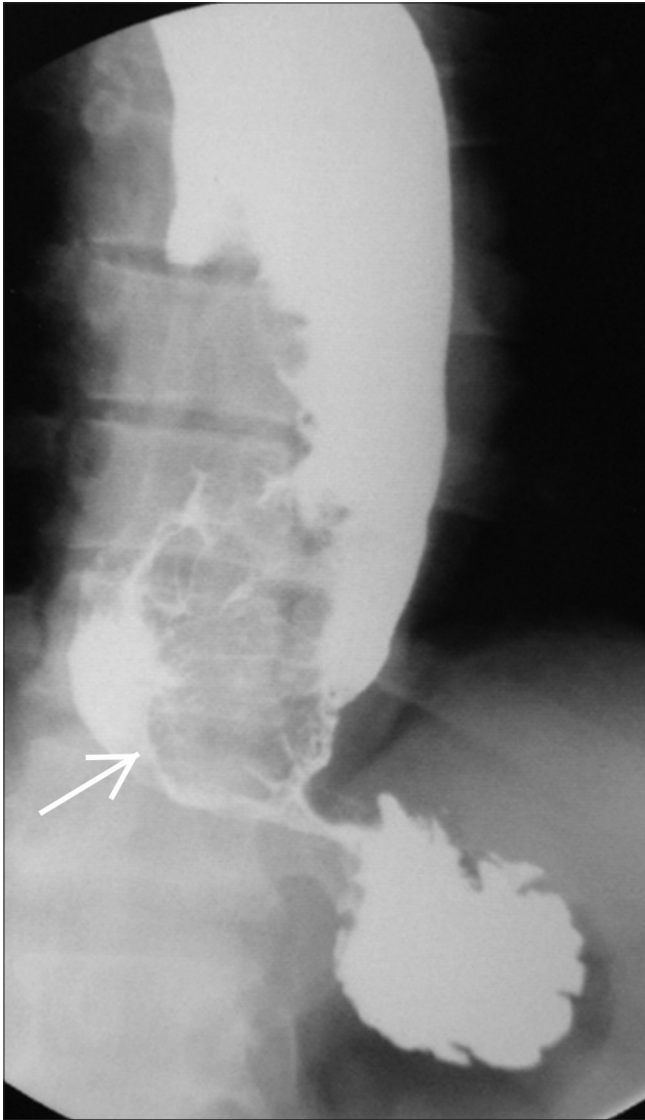
**Figure 17:** Leiomyosarcoma: Prone RAO double-contrast barium swallow image showing semilunar filling defect (arrow) in distal thoracic esophagus s/o submucosal mass. Endoscopic biopsy revealed leiomyosarcoma



with caustic esophagitis develop strictures,<sup>[46,47]</sup> usually 1–3 months after the injury. Barium swallow in these cases reveals long segment narrowing of esophagus with smooth tapering [Figure 11], usually in upper and mid esophagus. Eccentric narrowing and sacculations can be seen because of asymmetrical scarring.<sup>[43]</sup> In severe cases, esophagus may have thread-like filiform appearance.<sup>[48]</sup>

#### *Drug-induced esophagitis*

Doxycycline and tetracycline are most common drugs responsible for drug-induced esophagitis. The radiographic findings are small, superficial ulceration in upper or mid esophagus [Figure 12].<sup>[49,50]</sup> These ulcers usually heal without scarring. Other drugs responsible for esophagitis include potassium chloride, NSAIDs, quinidine, and alendronate sodium.<sup>[51-53]</sup>



**Figure 18:** Malignant melanoma: Upright frontal single-contrast barium swallow image showing irregular, large, polypoidal, expansile filling defect in distal esophagus (arrow). This may be difficult to distinguish from spindle cell carcinoma

## **Tumors of esophagus**

### *Benign tumors*

Benign tumors comprise ~ 20% of all tumors of esophagus at autopsy,<sup>[54]</sup> but only <1% of clinically symptomatic tumors.<sup>[55]</sup> Common imaging features of all benign tumors on barium swallow are smooth intraluminal or intramural filling defect without any ulceration or nodularity.

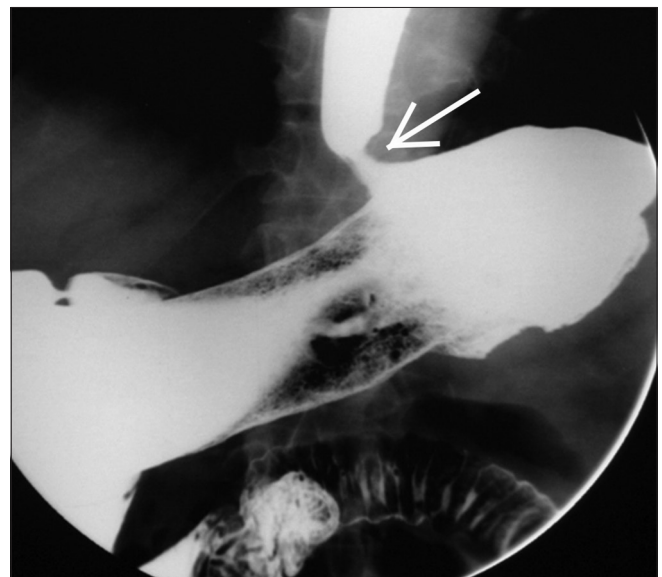
Leiomyomas are most common benign tumor of esophagus as well as most common mesenchymal tumor of esophagus.<sup>[56]</sup> Leiomyomas on barium swallow appear as smooth semilunar filling defect [Figure 13], forming right angle or slightly obtuse angle with esophageal wall.<sup>[57]</sup> On barium studies, these lesions are indistinguishable from other mesenchymal tumors of esophagus (like fibroma, neurofibromas, and hemangiomas).

Fibrovascular polyps are rare benign tumors of esophagus, arising from cervical esophagus, near cricopharynx. These patients may give typical history of regurgitation of fleshy mass in mouth which may at times cause asphyxia and death if the mass occludes the larynx.<sup>[58]</sup> On barium swallow, they appear as a smooth, expansile sausage-shaped mass [Figure 14], arising from cervical esophagus.<sup>[58]</sup>

Squamous papillomas are most common mucosal tumors of esophagus, appearing as small, smooth sessile polyp on barium swallow<sup>[59]</sup> that at times may be difficult to distinguish from esophageal carcinoma.

### *Malignant tumors*

Malignant esophageal tumours account for ~ 80% of all esophageal tumours, 90% of them being esophageal carcinoma (squamous cell or adenocarcinoma).<sup>[56]</sup> All



**Figure 19:** Non-Hodgkin's lymphoma of stomach involving GE junction: Concentric smooth narrowing involving distal esophagus (arrow). Multiple small polypoidal filling defects were also seen noted in stomach

malignant esophageal tumors have common imaging features of a mass or stricture with mucosal irregularity, ulceration, and nodularity.<sup>[56]</sup>

#### Esophageal carcinoma

Esophageal carcinoma can be squamous cell type or adenocarcinoma with their relative proportion varying by geographical location.<sup>[56]</sup> It is difficult to distinguish between squamous cell carcinoma (SCC) and adenocarcinoma on imaging. SCC usually involves upper or mid esophagus, whereas adenocarcinoma involves lower esophagus with propensity to extend into gastric fundus.<sup>[60]</sup> Sensitivity of double-contrast barium swallow in diagnosing esophageal cancers has been reported to be greater than 95%.<sup>[61]</sup> Early esophageal cancers may appear as plaque-like lesions [Figure 15A], small lobulated sessile polyp, or focal wall irregularity on double-contrast barium swallow.<sup>[62]</sup> Superficial spreading carcinoma can appear as poorly defined nodules, merging with one another.

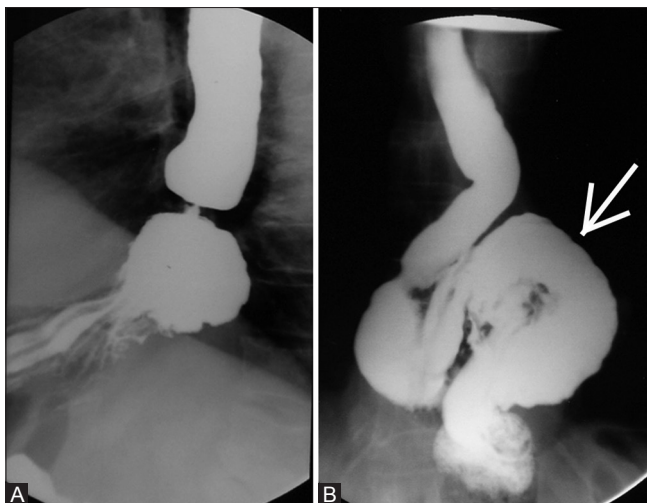
Advanced esophageal cancers can appear as infiltrative, ulcerative, polypoidal, or varicoid type on double-contrast barium swallow.<sup>[63]</sup> Infiltrative lesions (most common appearance) appear as luminal narrowing with mucosal irregularity, nodularity, and ulceration with shouldering of margins [Figure 15B]. Ulcerative carcinomas appear as giant ulcers with [Figure 15C] surrounding tumor rind.<sup>[64]</sup> Polypoid lesions appear as lobulated intraluminal masses with or without ulceration [Figure 15D]. Varicoid type appears as fixed, thickened longitudinal defects because of submucosal infiltration of tumor.<sup>[65]</sup>

#### Other esophageal tumors

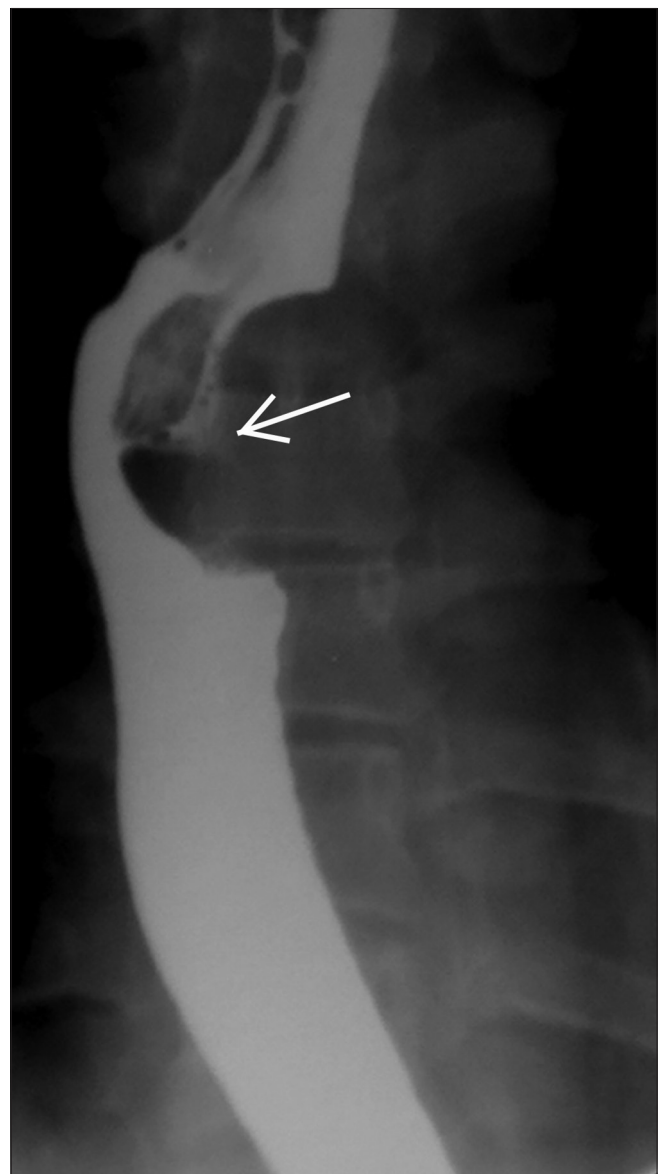
##### Spindle cell carcinoma

It contains both carcinomatous and sarcomatoid components. On barium examination, it appears as

a large polypoidal, expansile mass [Figure 16] with scalloped margins in mid and distal esophagus.<sup>[66,67]</sup> Unlike esophageal carcinoma, it expands the esophagus without causing obstruction.<sup>[68]</sup> Leiomyosarcoma, it is another rare esophageal tumor which appears as intramural polypoidal filling defect [Figure 17] with exophytic component and areas of calcification.<sup>[69]</sup> Primary malignant melanoma of the esophagus may appear as large polypoidal mass indistinguishable from spindle cell carcinoma [Figure 18].<sup>[70]</sup> Lymphoma can also involve the esophagus (more commonly non Hodgkin's lymphoma), which manifests on imaging as polypoidal lesions, submucosal masses, fold thickening, and strictures [Figure 19].<sup>[71]</sup>



**Figure 20 (A and B):** (A) Sliding hiatal hernia: Upward migration of GE junction with herniation of stomach into thoracic cavity. (B) Mixed hernia: Upright barium swallow image showing paraesophageal herniation of fundus and body of stomach (arrow). Also note higher position of GE junction



**Figure 21:** Esophageal tuberculosis: Upright barium swallow image of a patient with history of dysphasia showing extrinsic impression in mid esophagus with presence of mild mucosal ulceration and displacement of esophagus towards right side (arrow)

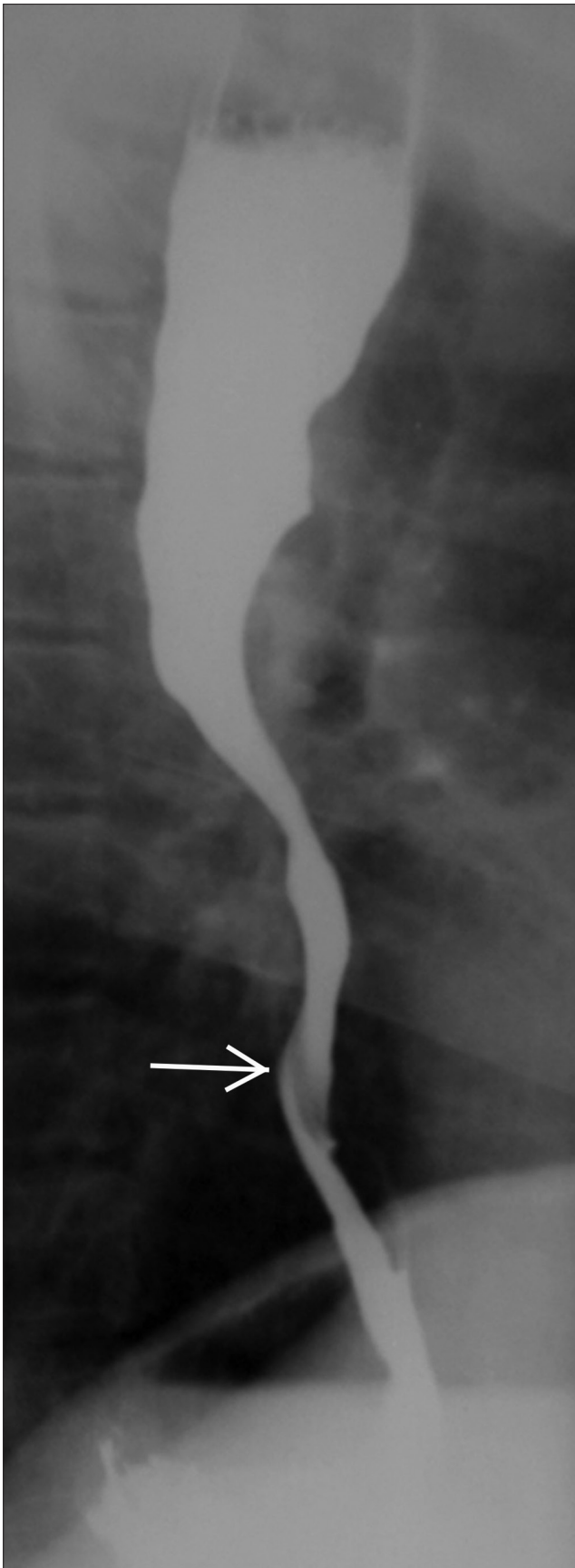
### Miscellaneous abnormalities of the esophagus

#### *Hiatus hernia*

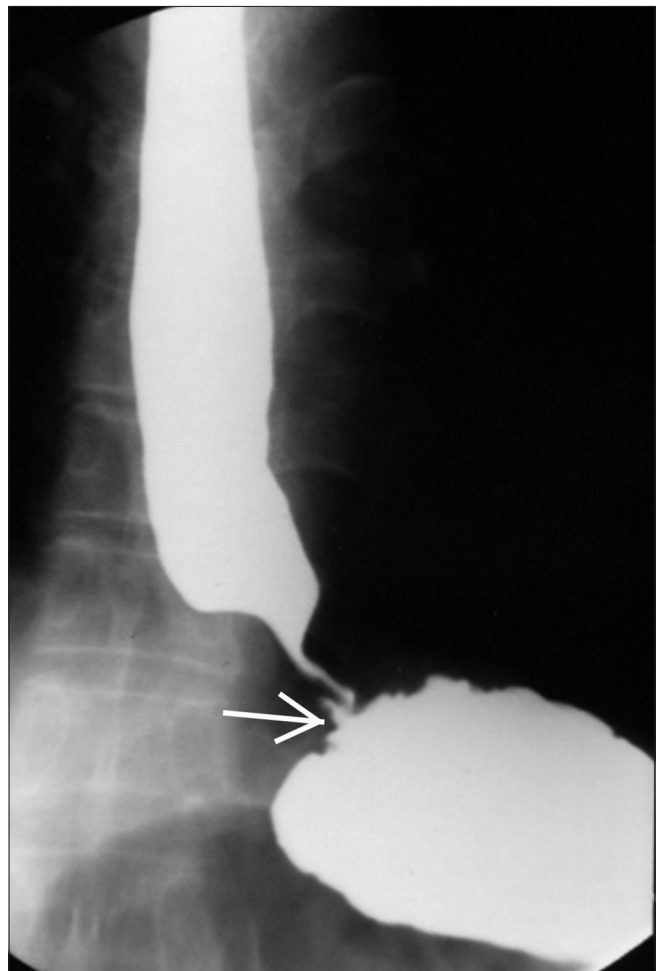
Hiatus hernia can be sliding type, rolling type (or paraesophageal), or mixed type. On barium swallow, sliding hiatus hernia is diagnosed when mucosal ring or B ring is ~ 2 cm above the hiatus with presence of gastric folds above the hiatus [Figure 20A].<sup>[72]</sup> On the other hand, in paraesophageal hernia, GE junction is usually normal in position with herniation of fundus of stomach into the thorax. In mixed hernia, GE junction is displaced upwards with herniation of fundus of stomach [Figure 20B].

#### *Esophageal tuberculosis*

Esophageal tuberculosis is rare and usually secondary to tuberculous infection at other sites. Most common site for involvement is mid third of esophagus, adjacent to tracheal bifurcation. Most common finding is extrinsic impression by adjacent lymph nodes [Figure 21]. Traction diverticulum may be seen because of adventitial involvement. Mucosal irregularity and ulceration can be seen because of involvement of esophageal mucosa. Rupture of necrotic



**Figure 22:** Esophageal Crohn's disease: Upright barium swallow image showing stricture of mid and lower esophagus (arrow)



**Figure 23:** Mallory Weiss tear: Upright single-contrast barium swallow image showing intramural contrast extravasation from esophagus at level of GE junction (arrow), in a patient with history of violent episode of vomiting



mediastinal lymph nodes may lead to formation of sinus or fistula.<sup>[73]</sup>

#### *Crohn's disease of esophagus*

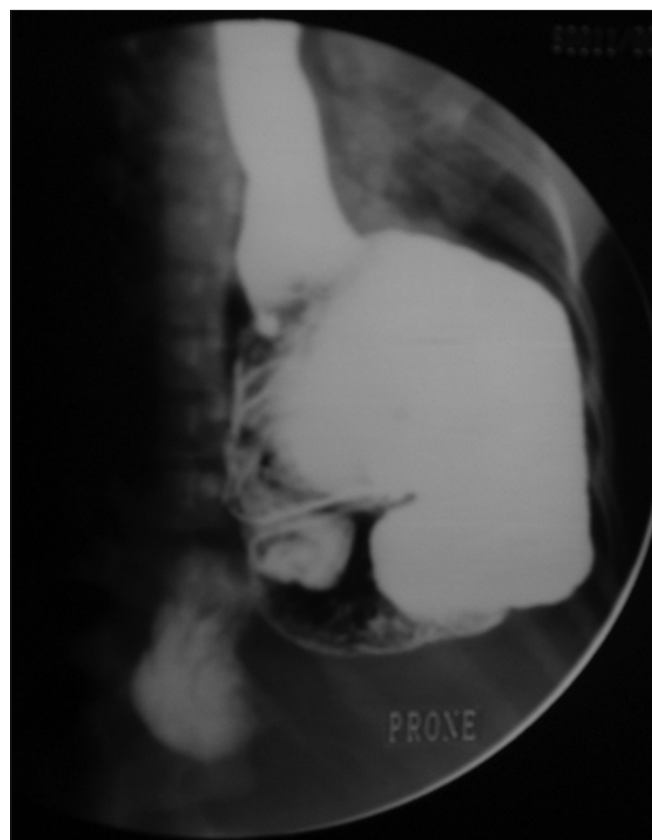
Esophageal involvement is rare and is associated with Crohn's disease elsewhere in gastrointestinal tract. Imaging findings are cobblestone mucosa with ulceration.<sup>[74]</sup> Stricture formation can be present in some cases [Figure 22], seen in distal third of esophagus and is usually greater than 1 cm in length.<sup>[74]</sup>

#### *Esophageal perforation*

Esophageal perforation can be iatrogenic or spontaneous. Spontaneous esophageal perforation (also known as Boerhaave's syndrome) is usually a result of full thickness esophageal wall tear because of forceful vomiting or retching. In cases of perforation, contrast study by water-soluble contrast is indicated. This may be followed by barium swallow, provided no leak is seen on initial study. Mallory-Weiss tear is a partial mucosal and submucosal tear (without transmural perforation), seen in lower esophagus near GE junction. Contrast swallow reveals intramural leak of contrast [Figure 23].

#### *Congenital short esophagus*

Congenital short esophagus is a very rare condition, associated with intrathoracic stomach [Figure 24].<sup>[75,76]</sup> It is



**Figure 24:** Congenital short esophagus: LPO view in an infant showing short esophagus with intrathoracic stomach

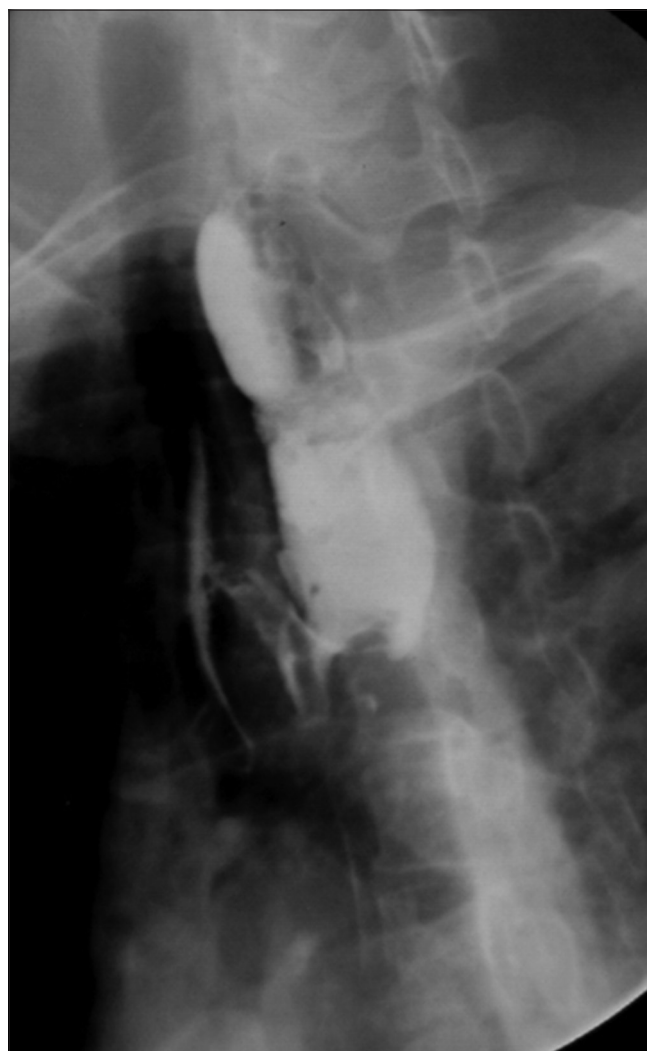thought to be due to underlying developmental anomaly. It needs to be differentiated from congenital hiatal hernia with intrathoracic herniation of stomach.<sup>[77]</sup>

#### *Foreign body in esophagus*

Although chest radiography is the initial investigation in patients with suspected esophageal foreign body, radiolucent foreign bodies may not be detected on plain radiography. Barium swallow in these cases may demonstrate intraluminal filling defect [Figure 25].

### Conclusion

Barium swallow is the initial imaging modality of choice for evaluation of suspected esophageal diseases. Besides providing excellent mucosal detail, it helps in functional evaluation of esophagus and accurate diagnosis of a variety of neoplastic and non-neoplastic conditions. Radiologist should be familiar with standard techniques and protocols



**Figure 25:** FB sequelae: LAO view barium swallow image of a patient with past history of denture impaction showing stricture at proximal esophagus with restricted passage of barium. Also note H-shaped tracheoesophageal fistula with opacification of trachea

of the procedure and imaging findings of various esophageal diseases on barium swallow.

### Financial support and sponsorship

Nil.

### Conflicts of interest

There are no conflicts of interest.

## References

- Rubenstein SE. Structural abnormalities of the pharynx. In: Gore RM, Levine MS, editors. Textbook of Gastrointestinal Radiology. 3<sup>rd</sup> ed. Philadelphia, Pa: Saunders; 2008. p. 271-308.
- Shauffer IA, Phillips HE, Sequeira J. The jet phenomenon a manifestation of esophageal web. *AJR* 1977;129:747-8.
- Taylor AI, Stewart ET, Dodds WJ. The esophageal jet phenomenon revisited. *AJR* 1990;155:289-90.
- Schatzki R. The lower esophageal ring: Long term follow-up of symptomatic and asymptomatic rings. *Am J Roentgenol* 1963;90:805-10.
- Levine MS. Miscellaneous abnormalities of the esophagus. In: Gore RM, Levine MS, editors. Textbook of Gastrointestinal Radiology. 3<sup>rd</sup> ed. Philadelphia, Pa: Saunders; 2000. p. 465-93.
- Cho SR, Sanders MM, Turner MA, Liu CI, Kipreos BE. Esophageal intramural pseudo-diverticulosis. *Gastrointest Radiol* 1981;6:9-16.
- Ott DJ. Motility disorders of the esophagus. In: Gore RM, Levine MS, editors. Textbook of Gastrointestinal Radiology. 3<sup>rd</sup> ed. Philadelphia, Pa: Saunders; 2008. p. 323-35.
- Woodfield CA, Levine MS, Rubenstein SE, Langlotz CP, Laufer I. Diagnosis of primary versus secondary achalasia: Reassessment of clinical and radiographic criteria. *AJR Am J Roentgenol* 2000;175:727-31.
- Tucker HJ, Snape WJ, Cohen S. Achalasia secondary to carcinoma: Manometric and clinical features. *Ann Intern Med* 1978;89:315-8.
- Chen YM, Ott DJ, Hewson EG, Richter JE, Wu WC, Gelfand DW, et al. Diffuse esophageal spasm: Radiographic and manometric correlation. *Radiology* 1989;170:807-10.
- Prabhakar AM, Levine MS, Rubenstein SE, Laufer I, Katzka DA. Relationship between diffuse esophageal spasm and lower esophageal sphincter dysfunction on barium studies and manometry in 14 patients. *AJR* 2004;183:409-13.
- Dodds WJ. Esophagus radiology. In Margulis AR, Burhenne HJ, editors. Alimentary Tract Radiology. 4<sup>th</sup> ed. vol 1. St. Louis, CV Mosby; 1989. p. 427-500.
- Ott DJ. Motility disorders of the esophagus. *Radiol Clin North Am* 1994;32:111-34.
- Levine MS, Rubenstein SE. Radiology of the pharynx and esophagus. In Castell DO, Richter RE editors. The Esophagus, 4<sup>th</sup> ed. Philadelphia, Lippincott Williams and Wilkins; 2004. p. 47-105.
- Schima W, Eisenhuber E. Radiologic evaluation of esophageal function. In: Ekberg O, editor. Radiology of the Pharynx and the Esophagus. Berlin, Springer; 2004. p. 109-25.
- Spechler SJ, Castell DO. Nonachalasia esophageal motility abnormalities. In: Castell DO, Richter RE, editors. The Esophagus, 4<sup>th</sup> ed. Philadelphia, Lippincott Williams and Wilkins; 2004. p. 262-74.
- Alrakawi A, Clouse RE. The changing use of esophageal manometry in clinical practice. *Am J Gastroenterol* 1998;93:2359-62.
- Clouse RE, Staiano A, Alrakawi A, Haroian L. Application of topographical methods to clinical esophageal manometry. *Am J Gastroenterol* 2000;95:2720-30.
- Wo JM. Esophageal involvement in systemic diseases. In: Castell DO, Richter RE, editors. The Esophagus, 4<sup>th</sup> ed. Philadelphia, Lippincott Williams and Wilkins; 2004. p. 611-33.
- Klein HA, Wald A, Graham TO, Campbell WL, Steen VD. Comparative studies of esophageal function in systemic sclerosis. *Gastroenterology* 1992;102:1551-56.
- Koehler RE, Weyman PJ, Oakley HF. Single- and double-contrast techniques in esophagitis. *AJR Am J Roentgenol* 1980;135:15-9.
- Creteur V, Thoeni RF, Federle MP, Cello JP, Moss AA, Ominsky SH, et al. The role of single- and double-contrast radiography in the diagnosis of reflux esophagitis. *Radiology* 1983;147:71-5.
- Graziani L, Bearzi I, Romagnoli A, Pesaresi A, Montesi A. Significance of diffuse granularity and nodularity of the esophageal mucosa at double-contrast radiography. *Gastrointest Radiol* 1985;10:1-6.
- Dibble C, Levine MS, Rubenstein SE, Laufer I, Katzka DA. Detection of reflux esophagitis on double-contrast esophagrams and endoscopy using the histologic findings as the gold standard. *Abdom Imaging* 2004;29:421-5.
- Levine MS. Gastroesophageal reflux disease. In: Gore RM, Levine MS, editors. Textbook of Gastrointestinal Radiology. 3<sup>rd</sup> ed. Philadelphia, Pa: Saunders; 2000. p. 337-57.
- Levine MS, Goldstein HM. Fixed transverse folds in the esophagus: A sign of reflux esophagitis. *AJR Am J Roentgenol* 1984;143:275-78.
- Ott DJ. Gastroesophageal reflux disease. *Radiol Clin North Am* 1994;32:1147-66.
- Winters C, Spurling TJ, Chobanian SJ, Curtis DJ, Esposito RL, Hacker JF 3<sup>rd</sup>, et al. Barrett's esophagus: A prevalent, occult complication of gastroesophageal reflux disease. *Gastroenterology* 1987;92:118-24.
- Gilchrist AM, Levine MS, Carr RF, Saul SH, Katzka DA, Herlinger H, et al. Barrett's esophagus: Diagnosis by double-contrast esophagography. *AJR Am J Roentgenol* 1988;150:97-102.
- Levine MS, Kressel HY, Caroline DF, Laufer I, Herlinger H, Thompson JJ. Barrett esophagus: Reticular pattern of the mucosa. *Radiology* 1983;147:663-7.
- Chen YM, Gelfand DW, Ott DJ, Wu WC. Barrett esophagus as an extension of severe esophagitis: Analysis of radiologic signs in 29 cases. *AJR Am J Roentgenol* 1985;145:275-81.
- Geftter WB, Laufer I, Edell S, Gohel VK. Candidiasis in the obstructed esophagus. *Radiology* 1981;138:25-8.
- Levine MS, Macones AJ, Laufer I. Candida esophagitis: Accuracy of radiographic diagnosis. *Radiology* 1985;154:581-7.
- Levine MS, Woldenberg R, Herlinger H, Laufer I. Opportunistic esophagitis in AIDS: Radiographic diagnosis. *Radiology* 1987;165:815-20.
- Sam JW, Levine MS, Rubenstein SE, Laufer I. The "foamy" esophagus: A radiographic sign of Candida esophagitis. *AJR Am J Roentgenol* 2000;174:999-1002.
- Shortsleeve MJ, Levine MS. Herpes esophagitis in otherwise healthy patients: Clinical and radiographic findings. *Radiology* 1992;182:859-61.
- Levine MS, Laufer I, Kressel HY, Friedman HM. Herpes esophagitis. *AJR Am J Roentgenol* 1981;136:863-6.
- Levine MS, Loevner LA, Saul SH, Rubenstein SE, Herlinger H, Laufer I. Herpes esophagitis: Sensitivity of double-contrast esophagography. *AJR Am J Roentgenol* 1988;151:57-62.
- Balthazar EJ, Megibow AJ, Hulnick D, Cho KC, Beranbaum E. Cytomegalovirus esophagitis in AIDS: Radiographic features in 16 patients. *AJR Am J Roentgenol* 1987;149:919-23.
- Levine MS, Loercher G, Katzka DA, Herlinger H, Rubenstein SE, Laufer I. Giant, human immunodeficiency virus-related ulcers in the esophagus. *Radiology* 1991;180:323-6.

41. Sor S, Levine MS, Kowalski TE, Laufer I, Rubesin SE, Herlinger H. Giant ulcers of the esophagus in patients with human immunodeficiency virus: Clinical, radio-graphic, and pathologic findings. *Radiology* 1995;194:447-51.
42. Levine MS, Rubesin SE. Diseases of the esophagus: Diagnosis with esophagography. *Radiology* 2005;237:414-27.
43. Levine MS. Other esophagitis. In: Gore RM, Levine MS, editors. *Textbook of Gastrointestinal Radiology*. 3<sup>rd</sup> ed. Philadelphia, Pa: Saunders; 2008. p. 375-99.
44. Collazzo LA, Levine MS, Rubesin SE, Laufer I. Acute radiation esophagitis: Ra diographic findings. *AJR Am J Roentgenol* 1997;169:1067-70.
45. Lepke RA, Libshitz HI. Radiation-induced injury of the esophagus. *Radiology* 1983;148:375-8.
46. Goldman LP, Weigert JM. Corrosive substance ingestion: A review. *Am J Gastroenterol* 1984;79:85-90.
47. Neimark S, Rogers AI. Chemical injury of the esophagus. In: Berk JA, editor. *Bockus Gastroenterology*, 4<sup>th</sup> ed. Philadelphia, WB Saunders; 1985. p. 769-76.
48. Franken EA. Caustic damage of the gastrointestinal tract: Roentgen features. *AJR* 1973;118:77-85.
49. Creteur V, Laufer I, Kressel HY, Caroline DF, Goren RA, Evers KA, *et al.* Drug-induced esophagitis detected by double-contrast radiography. *Radiology* 1983;147:365-8.
50. Bova JG, Dutton NE, Goldstein HM, Hoberman LJ. Medication-induced esophagitis: Diagnosis by double-contrast esophagography. *AJR Am J Roentgenol* 1987;148:731-2.
51. Kikendall JW, Friedman AC, Oyewole MA, Fleischer D, Johnson LF. Pill-induced esophageal injury: Case reports and review of the medical literature. *Dig Dis Sci* 1983;28:174-82.
52. Coates AG, Nostrand TT, Wilson JA, Elta GH, Agha FP. Esophagitis caused by non-steroidal anti-inflammatory medication: Case reports and review of the literature for pill-induced esophageal injury. *South Med J* 1986;79:1094-7.
53. De Groen PC, Lubbe DF, Hirsch LJ, Daifotis A, Stephenson W, Freedholm D, *et al.* Esophagitis associated with the use of alendronate. *N Engl J Med* 1996;335:1016-21.
54. Levine MS. Benign tumors of the esophagus. In: Gore RM, Levine MS, editors. *Textbook of Gastrointestinal Radiology*. 3<sup>rd</sup> ed. Philadelphia, Pa: Saunders; 2008. p. 401-16.
55. Rice TW. Benign esophageal tumors: Esophagoscopy and endoscopic esophageal ultrasound. *Semin Thorac Cardiovasc Surg* 2003;15:20-6.
56. Lewis RB, Mehrotra AK, Rodriguez P, Levine MS. From the radiology pathology archives: Esophageal neoplasms: Radiologic-pathologic correlation. *Radiographics* 2013;33:1083-108.
57. Levine MS. Benign tumors of the esophagus: Radiologic evaluation. *Semin Thorac Cardiovasc Surg* 2003;15:9-19.
58. Levine MS, Buck JL, Pantongrag-Brown L, Buetow PC, Hallman JR, Sobin LH. Fibrovascular polyps of the esophagus: Clinical, radiographic, and pathologic findings in 16 patients. *AJR Am J Roentgenol* 1996;166:781-7.
59. Montesi A, Pesaresi A, Graziani L, Salmis-traro D, Dini L, Bearzi I. Small benign tu-mors of the esophagus: Radiological diagnosis with double-contrast examination. *Gastrointest Radiol* 1983;8:207-12.
60. Levine MS, Caroline D, Thompson JJ, Kressel HY, Laufer I, Herlinger H. Adenocarcinoma of the esophagus: Relationship to Barrett mucosa. *Radiology* 1984;150:305-9.
61. Levine MS, Chu P, Furth EE, Rubesin SE, Laufer I, Herlinger H. Carcinoma of the esophagus and esophagogastric junction: Sensitivity of radiographic diagnosis. *AJR Am J Roentgenol* 1997;168:1423-6.
62. Levine MS, Dillon EC, Saul SH, Laufer I. Early esophageal cancer. *AJR Am J Roentgenol* 1986;146:507-12.
63. Levine MS, Halvorsen RA. Carcinoma of the esophagus. In: Gore RM, Levine MS, editors. *Textbook of Gastrointestinal Radiology*. 2<sup>nd</sup> ed. Philadelphia, Pa: Saunders; 2000. p. 403-33.
64. Gloyna RE, Zornoza J, Goldstein HM. Primary ulcerative carcinoma of the esophagus. *AJR Am J Roentgenol* 1977;129:599-600.
65. Yates CW, LeVine MA, Jensen KM. Varicoid carcinoma of the esophagus. *Radiol-ogy* 1977;122:605-8.
66. Agha FP, Keren DF. Spindle-cell squamous carcinoma of the esophagus: A tumor with biphasic morphology. *AJR Am J Roentgenol* 1985;145:541-5.
67. Olmsted WW, Lichtenstein JE, Hyams VJ. Polypoid epithelial malignancies of the esophagus. *AJR Am J Roentgenol* 1983;140:921-5.
68. Levine MS. Other malignant tumors of the esophagus. In: Gore RM, Levine MS, editors. *Textbook of Gastrointestinal Radiology*. 3<sup>rd</sup> ed. Philadelphia, Pa: Saunders; 2008. p. 447-64.
69. Levine MS, Buck JL, Pantongrag-Brown L, Buetow PC, Hallman JR, Sobin LH. Leiomyosarcoma of the esophagus: Radiographic findings in 10 patients. *AJR Am J Roentgenol* 1996;167:27-32.
70. Yoo CC, Levine MS, McLarney JK, Lowry MA. Primary malignant melanoma of the esophagus: Radiographic findings in seven patients. *Radiology* 1998;209:455-9.
71. Levine MS, Rubesin SE, Pantongrag-Brown L, Buck JL, Herlinger H. Non-Hodgkin's lymphoma of the gastrointestinal tract: Radiographic findings. *AJR Am J Roentgenol* 1997;168:165-72.
72. Levine MS. Abnormalities of the gastroesophageal junction. In: Gore RM, Levine MS, editors. *Textbook of Gastrointestinal Radiology*. 3<sup>rd</sup> ed. Philadelphia, Pa: Saunders; 2008. p. 495-506.
73. Nagi B, Lal A, Kochhar R, Bhasin DK, Gulati M, Suri S, Singh K. Imaging of esophageal tuberculosis: A review of 23 cases. *Acta radiol* 2003;44:329-33.
74. Karasick S, Lev- Toaff AS. Esophageal strictures: Findings on barium radiographs. *Am J Roentgenol* 1995;165:561-5.
75. Woodward M, Crabbe DC, Kiely EM, Spitz L. Congenital intrathoracic stomach. *Pediatr Surg Int* 1996;11:116-8.
76. Skandalakis JE, Gray SW, Ricketts R, Skandalakis LJ: *Embryology for Surgeons: The Embryological Basis for the Treatment of Congenital Abnormalities*. 2<sup>nd</sup> ed. Baltimore, Williams & Willkins; 1994. p. 98-100.
77. Leung AW, Lam HS, Chu WC, Lee KH, Tam YH, Ng PC: Congenital intrathoracic stomach: short esophagus or hiatal hernia? *Neonatology* 2008;93:178-81.