



Contents lists available at ScienceDirect

International Journal of Surgery Case Reports

journal homepage: www.casereports.com

Robot-assisted laparoscopic total gastrectomy for Epstein–Barr virus-associated multiple gastric cancer: A case report

Kotaro Kimura^a, Yuma Ebihara^{a,*}, Kimitaka Tanaka^a, Yoshitsugu Nakanishi^a, Toshimichi Asano^a, Takehiro Noji^a, Yo Kurashima^a, Soichi Murakami^a, Toru Nakamura^a, Takahiro Tsuchikawa^a, Keisuke Okamura^a, Toshiaki Shichinohe^a, Hiromi Kanno-Okada^b, Satoshi Hirano^a

^a Department of Gastroenterological Surgery II, Hokkaido University Faculty School of Medicine, North 15 West 7, Kita-ku, Sapporo, 0608638, Hokkaido, Japan

^b Department of Surgical Pathology, Hokkaido University Hospital, North 15 West 7, Kita-ku, Sapporo, 0608638, Hokkaido, Japan

ARTICLE INFO

Article history:

Received 13 July 2020

Received in revised form

21 September 2020

Accepted 21 September 2020

Available online 24 September 2020

Keywords:

Epstein–Barr virus-associated gastric cancer

Robot-assisted laparoscopic gastrectomy

Multiple gastric cancer

Case report

ABSTRACT

INTRODUCTION: Epstein–Barr virus-associated gastric cancer (EBVaGC) sometimes appears as multiple gastric cancer lesions. Here, we report a case of robot-assisted laparoscopic total gastrectomy (RTG) for a relatively rare disease with four synchronized lesions in EBVaGC and discuss the usefulness of robotic gastrectomy.

PRESENTATION OF CASE: A 60-year-old woman was diagnosed with multiple gastric cancer because she had five lesions in the stomach and biopsy showed the presence of adenocarcinoma in four of the five lesions. We performed robot-assisted laparoscopic total gastrectomy on the patient. The histopathological diagnosis was multiple gastric cancer T1bN0M0 pStage IA. The four lesions were positive for the Epstein–Barr virus encoding region in in-situ hybridization and were considered to be EBVaGC. The patient had no sign of recurrence without postoperative therapy for 24 months.

DISCUSSION: EBVaGC was found in about 10% of all gastric cancer cases worldwide. EBVaGC sometimes appears as multiple gastric cancer, suggesting that EBV infection is closely related to the early stages of tumor formation. Total gastrectomy may be necessary for multiple gastric cancer such as EBVaGC, and robotic surgery is useful in total gastrectomy in terms of high-resolution three-dimensional images and using forceps with multi-joint functions.

CONCLUSIONS: We performed RTG on a patient with four synchronous lesions of EBVaGC, which is relatively rare. Robot-assisted laparoscopic total gastrectomy is known to be a safe procedure, and we effectively performed total gastrectomy for multiple EBVaGC.

© 2020 Published by Elsevier Ltd on behalf of IJS Publishing Group Ltd. This is an open access article under the CC BY-NC-ND license (<http://creativecommons.org/licenses/by-nc-nd/4.0/>).

1. Introduction

Epstein–Barr virus (EBV) is known to cause gastric cancer, and EBV-associated gastric cancer (EBVaGC) accounts for approxi-

Abbreviations: EBV, Epstein–Barr virus; RTG, robot-assisted laparoscopic total gastrectomy; EBER, EBV-encoded RNA-1; EBVaGC, EBV-associated gastric cancer; GCLS, gastric carcinoma with lymphoid stroma.

* Corresponding author.

E-mail addresses: kokimura1217@gmail.com (K. Kimura), yuma-ebi@wc4.so-net.ne.jp (Y. Ebihara), kimitaka.t@gmail.com (K. Tanaka), y.nakanishi@mac.com (Y. Nakanishi), toasa0616@gmail.com (T. Asano), dnoji@med.hokudai.ac.jp (T. Noji), yo.kurashima@huhp.hokudai.ac.jp (Y. Kurashima), so-ichi@umin.ac.jp (S. Murakami), torunakamura@med.hokudai.ac.jp (T. Nakamura), tsuchi-t@med.hokudai.ac.jp (T. Tsuchikawa), keisukeo@qb4.so-net.ne.jp (K. Okamura), shichino@med.hokudai.ac.jp (T. Shichinohe), kanno-kanno-42010063@ion.ocn.ne.jp (H. Kanno-Okada), satto@med.hokudai.ac.jp (S. Hirano).

<https://doi.org/10.1016/j.ijscr.2020.09.147>

2210-2612/© 2020 Published by Elsevier Ltd on behalf of IJS Publishing Group Ltd. This is an open access article under the CC BY-NC-ND license (<http://creativecommons.org/licenses/by-nc-nd/4.0/>).

mately 10% of all gastric cancer cases [1]. The mechanism by which EBV causes gastric cancer is not completely understood; however, it is known that EBVaGC sometimes appears as multiple gastric cancers. Although there are many reports of robot-assisted laparoscopic total gastrectomy (RTG) for gastric cancer [1–3], there are no reports of RTG for multiple EBVaGC. Here, we report a case of RTG for a relatively rare disease with four synchronous lesions in EBVaGC and describe the utility of robotic gastrectomy. This work has been reported in line with the SCARE criteria [2].

2. Presentation of case

The 60-year-old woman had no major complaints but was referred to our hospital because an abnormal result was found in the barium test of the medical examination. An upper gastrointestinal endoscopy showed five lesions in the stomach—the first lesion was in the lower part of the stomach, the second on the lower anterior wall of the stomach, the third and fourth on the rear wall of

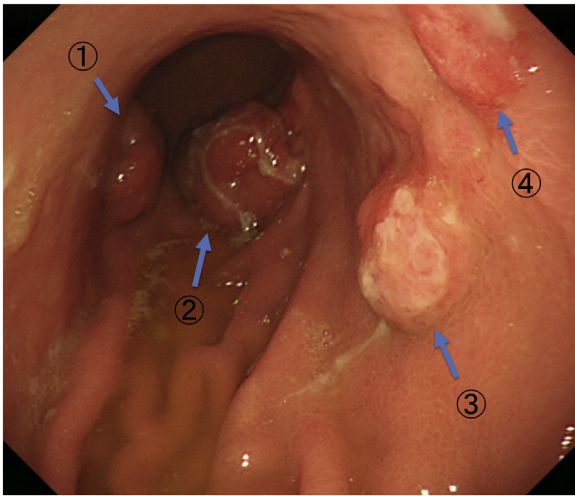


Fig. 1. Upper gastrointestinal endoscopy revealed five lesions in the stomach: (1) first in the lower part of the stomach, (2) second in the lower anterior wall of the stomach, (3) and (4) third and fourth on the rear wall of the middle part of the stomach, and (5) fifth lesion in the lesser curvature of the stomach (no picture).

the middle part of the stomach, and the fifth on the lesser curvature of the stomach [Fig. 1]. Biopsy results revealed that the first four lesions were adenocarcinomas, whereas the fifth lesion was an adenoma (Group 3). Abdominal CT showed two lesions in the lower stomach and one on the enlarged lymph node of the lesser

curvature [Fig. 2a–c]. The patient has had uterine myoma enucleation for uterine fibroids, is being treated for hypertension. Her sister has also had surgery for gastric cancer. Biochemical tests did not show an increase in tumor markers. We diagnosed the patient with multiple gastric cancers, T2N1M0 Stage IIA.

After providing a written informed consent, the patient underwent a robot-assisted laparoscopic total gastrectomy D1+ lymphadenectomy with Roux-en-Y reconstruction. The operation was performed under general anesthesia with lithotomy. Six ports were used during the operative procedures, and all gastrointestinal anastomoses were performed by intraperitoneal manipulation. The operation time was 302 min. There was little blood loss, and no intraoperative complications occurred. The postoperative course was generally uneventful. The patient resumed drinking water and eating on postoperative days 1 and 3, respectively, and was discharged on postoperative day 12.

The pathological diagnosis of the specimen confirmed multiple gastric cancers [Figs. 3 and 4]. The first lesion on the lower major stomach was type 1(T1a), and the second lesion on the lower anterior wall of the stomach was type 1(T1b1); these lesions were clearly tubular structures and had many well-differentiated components. The third and fourth lesions on the posterior wall of the middle part of the stomach were considered separate lesions before surgery, but they were one continuous lesion and were type 0-II a and 0-II c, respectively, with poor tubular structure formation and many poorly differentiated components. In particular, there was a part that showed race-like proliferation of atypical cells characteristic of lymphocyte infiltrating carcinoma and lymphocyte

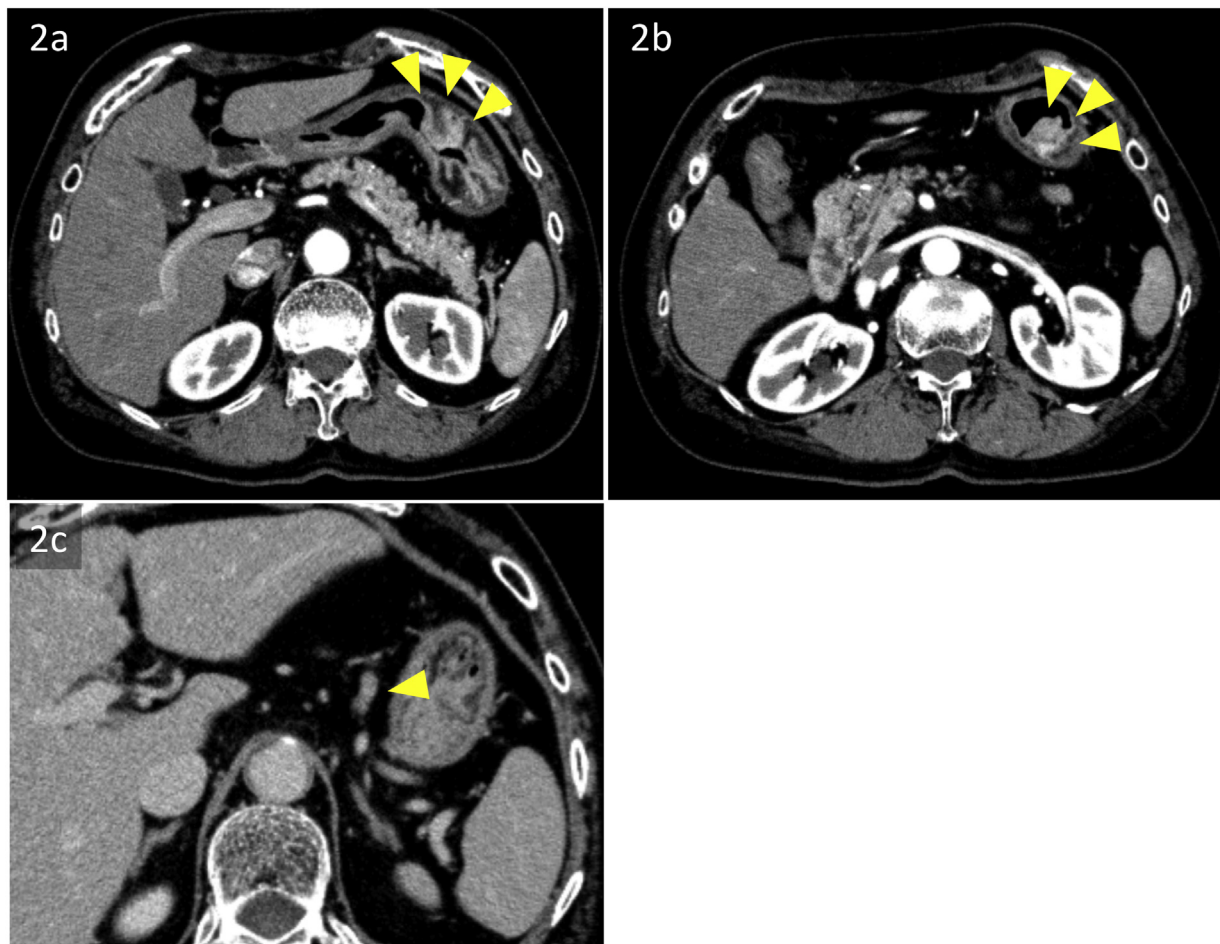


Fig. 2. Representative images from the abdominal CT scan; 2a and 2b show two lesions in the lower stomach, and 2c shows one on the enlarged lymph node of the lesser curvature.




Fig. 3. The pathological diagnosis of the specimen confirmed multiple gastric cancer. (1) The lesion on the lower major stomach was type 1 (T1a), and (2) the lesion on the lower anterior wall of the stomach was type 1 (T1b1). (3) and (4) The lesions on the rear wall of the middle part of the stomach were considered separate lesions before surgery, but they were one continuous lesion and were type 0-II a and 0-II c. In addition, (5) the lesion on the lesser curvature of the stomach was diagnosed as a tubular adenoma using preoperative biopsy, but it was a well-differentiated tubular adenocarcinoma on the pathological diagnosis of the specimen.

infiltration accompanied by lymphoid follicle formation. In addition, the fifth lesion on the lesser curvature of the stomach was diagnosed as a tubular adenoma using preoperative biopsy, but it was a well-differentiated tubular adenocarcinoma on pathological diagnosis. No lymph node metastases were seen. The first four lesions were EBV-encoded RNA-1 (EBER)-positive, based on the appearance of the atypical cell. Elastica-Masson staining showed partial venous invasion, and immunostaining with D2-40 showed partial lymphatic invasion.

She was diagnosed with multiple EBVaGC, which was early gastric cancer. As a result of proper informed consent, she was not given adjuvant therapy. She has had no recurrence 24 months after operation. We will follow up for 5 years after surgery. Ethics com-

mittee approval was waived for our case report, and the patient gave informed consent; her anonymity was preserved.

3. Discussion

EBV is one of the most common viruses belonging to the human herpes virus family that was originally discovered in Burkitt lymphoma [4]. EBVaGC was reported in 1990 as gastric cancer caused by EBV infection and is one of the most common malignant tumors caused by EBV infection.

As a clinicopathological feature of EBVaGC, EBVaGC accounts for about 10% of all gastric cancers [5]. In addition, EBVaGC is slightly more common in men and slightly younger than EBV-negative gastric cancer [6,7]. It has been reported that the incidence of EBVaGC is associated with smoking compared to other gastric cancers [8]. The occurrence of EBVaGC is widespread, with almost no regional differences, but it is known to be slightly higher prevalence in some countries in the American continents such as Chile and the United States than 15% [9,10]. Gastric cancer was divided into four molecular subtypes by TCGA: (1) EBVaGC; (2) Microsatellite instability; (3) Chromosome instability; (4) Genomeally stable tumors [5]. Among them, EBV was reported to be more involved than other subtypes in residual gastric cancer, which is defined as cancer that begins in the gastric stump at least 5 years after surgery for benign diseases such as gastric ulcer and duodenal ulcer [7,11].

It is not known in detail how EBV causes cancer. It has been reported that EBNA1, a nuclear antigen protein, destabilizes the p53 gene to suppress p53-mediated apoptosis [12,13], and EBER (EBV encoded small RNA) induces the expression of IGF-1, which causes autocrine action, as a growth factor for EBV-infected cells [14]. From a pathological point of view, EBVaGC has definite histological relevance to gastric carcinoma with lymphoid stroma (GCLS); it has been reported that 80%–90% of GCLS were positive for EBV [15]. EBV infection in gastric cancer is thought to be associated with increased inflammation, as seen in lymphoepithelioma-like gastric cancer, with its high degree of lymphocytic infiltration [16], and similar findings were obtained in our case.

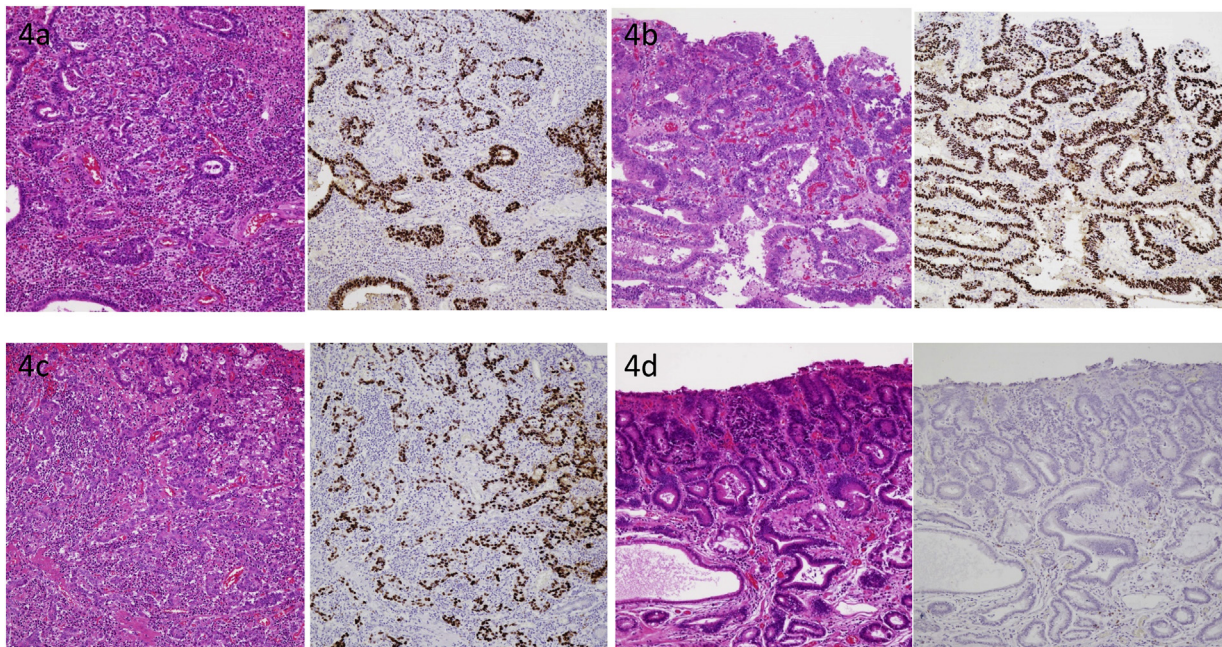


Fig. 4. Pathological diagnosis: 4a (1) and 4b (2) are clearly tubular structures and have many well-differentiated components. 4c (3) and (4) have a poor formation of tubular structure and many poorly differentiated components. 4d (5) had a diagnosis of tubular adenoma by preoperative biopsy, but it was a well-differentiated tubular adenocarcinoma in the specimen. (1)–(4), were EBER-positive according to in situ hybridization. Elastica-Masson staining showed partial venous infiltration, and immunostaining with D2-40 showed partial lymphatic vessels.

EBVaGC sometimes appears as multiple gastric cancer, suggesting that EBV infection is closely related to the early stages of tumor formation [17]. However, EBVaGC sometimes simultaneously expresses EBV-negative lesions, which may indicate that the tumor does not always require EBV infection at the early stages of tumor formation [16]. In addition to these reports, because multiple EBV-positive dysplastic lesions and cancer may recur synchronously or metachronously, total gastrectomy may be one of treatment option for multiple EBVaGC [17]. If partial gastrectomy is applied to such a case, long-term follow-up on the remnant stomach would be needed. Therefore, we think that total gastrectomy is one of an effective treatment for multiple EBVaGC.

Robot-assisted laparoscopic gastrectomy has been put into practical use since 2000. Advantages of robot surgery include motion scaling, less fatigue, tremor filtering, and three-dimensional vision [18]. Furthermore, in robotic surgery, high-resolution three-dimensional images and the use of forceps with multi-joint functions eliminate the limitations of conventional laparoscopic gastrectomy and enable sophisticated procedures [19]. In particular, it is expected that improvement in local operability will ensure lymph node dissection for malignant tumor surgery and reduce postoperative complications such as pancreatic leakage [20]. According to one review that compared laparoscopic and robotic surgery for gastrectomy for gastric cancer, robotic surgery was associated with longer operation time, less intraoperative blood loss, earlier time to oral intake, and a higher expense. However, postoperative complications, length of hospital stay, morbidity, mortality, harvested lymph nodes, and cancer recurrence were not different between laparoscopic and robotic surgery [21]. Furthermore, when limited to total gastrectomy for gastric cancer, it was reported that laparoscopic and robotic surgery were equivalent in postoperative hospital stay, operation time, number of dissected lymph nodes, and postoperative complications [22]. For these reasons, there is no obvious inferiority between laparoscopic total gastrectomy and robot-assisted laparoscopic gastrectomy (RTG) in terms of surgical outcomes. Because we think that the use of robots in surgery can improve three-dimensional vision and less fatigue, our department is actively engaged in RTG.

4. Conclusion

We performed robot-assisted laparoscopic total gastrectomy for a case with four synchronous lesions of EBVaGC, which is relatively rare. The number of reports using robotic gastrectomy is increasing, and it has become a common procedure. RTG has also been reported to be safe and useful, so we believe that RTG was also effective for multiple EBVaGC in this case.

Declaration of Competing Interest

The authors report no declarations of interest.

Sources of funding

The study sponsors had no such involvement.

Ethical approval

The study is exempt from ethical approval in my institution.

Consent

Written informed consent was obtained from the patient for the publication of this report and any accompanying images at Hokkaido University Faculty School of Medicine.

Author's contributions

Kotaro Kimura: Conceptualization; Data curation; Investigation; Visualization; Writing-original draft.

Yuma Ebihara: Conceptualization; Methodology; Project administration; Surgical treatment of the patient; Writing-review & editing.

Kimitaka Tanaka, Yoshitsugu Nakanishi, Toshimichi Asano, Takehiro Noji, Yo Kurashima, Soichi Murakami,

Toru Nakamura, Takahiro Tsuchikawa, Keisuke Okamura, Toshiaki Shichinohe, Hiromi Kannno-Okada: Conceptualization; Data curation; Writing-review & editing.

Satoshi Hirano: supervision.

All authors read and approved the final manuscript.

Registration of research studies

We performed informed consent fully and got consent from the patient.

Guarantor

Yuma Ebihara.

Provenance and peer review

Not commissioned, externally peer-reviewed.

Acknowledgements

The Authors declare that there is no conflict of interest. Ethics committee approval was unnecessary for our manuscript. The patient gave informed consent, and her anonymity was preserved.

References

- [1] E. Ignatova, D. Seriak, M. Fedyanin, A. Tryakin, I. Pokataev, S. Menshikova, et al., Epstein-Barr virus-associated gastric cancer: disease that requires special approach, *Gastric Cancer* (2020).
- [2] R.A. Agha, M.R. Borrelli, R. Farwana, K. Koshy, A.J. Fowler, D.P. Orgill, et al., The SCARE 2018 statement: updating consensus Surgical CAse REport (SCARE) guidelines, *Int. J. Surg.* 60 (2018) 132–136.
- [3] Y.-B. Kim, H. Hur, D. Lee, Frequent EBV positivity in conventional adenocarcinomas occurring simultaneously with EBV-associated gastric cancers, *Pathology* 48 (2016) 616–618.
- [4] A. Shinozaki-Ushiku, A. Kunita, M. Fukayama, Update on Epstein-Barr virus and gastric cancer (review), *Int. J. Oncol.* 46 (2015) 1421–1434.
- [5] Cancer Genome Atlas Research N, Comprehensive molecular characterization of gastric adenocarcinoma, *Nature* 513 (2014) 202–209.
- [6] G. Murphy, R. Pfeiffer, M.C. Camargo, C.S. Rabkin, Meta-analysis shows that prevalence of Epstein-Barr virus-positive gastric cancer differs based on sex and anatomic location, *Gastroenterology* 137 (2009) 824–833.
- [7] J.-H. Lee, S.-H. Kim, S.-H. Han, J.-S. An, E.-S. Lee, Y.-S. Kim, Clinicopathological and molecular characteristics of Epstein-Barr virus-associated gastric carcinoma: a meta-analysis, *J. Gastroenterol. Hepatol.* 24 (2009) 354–365.
- [8] M.C. Camargo, C. Koriyama, K. Matsuo, W.-H. Kim, R. Herrera-Goepfert, L.M. Liao, et al., Case-case comparison of smoking and alcohol risk associations with Epstein-Barr virus-positive gastric cancer, *Int. J. Cancer* 134 (2014) 948–953.
- [9] A. Corvalan, C. Koriyama, S. Akiba, Y. Eizuru, C. Backhouse, M. Palma, et al., Epstein-Barr virus in gastric carcinoma is associated with location in the cardia and with a diffuse histology: a study in one area of Chile, *Int. J. Cancer* 94 (2001) 527–530.
- [10] S. Akiba, C. Koriyama, R. Herrera-Goepfert, Y. Eizuru, Epstein-Barr virus associated gastric carcinoma: epidemiological and clinicopathological features, *Cancer Sci.* 99 (2008) 195–201.
- [11] Y. Kaizaki, O. Hosokawa, S. Sakurai, M. Fukayama, Epstein-Barr virus-associated gastric carcinoma in the remnant stomach: de novo and metachronous gastric remnant carcinoma, *J. Gastroenterol.* 40 (2005) 570–577.
- [12] G. Kennedy, J. Komano, B. Sugden, Epstein-Barr virus provides a survival factor to Burkitt's lymphomas, *Proc. Natl. Acad. Sci.* 100 (2003) 14269–14274.
- [13] V. Saridakis, Y. Sheng, F. Sarkari, M.N. Holowaty, K. Shire, T. Nguyen, et al., Structure of the p53 binding domain of HAUSP/USP7 bound to Epstein-Barr nuclear antigen 1, *Mol. Cell* 18 (2005) 25–36.

- [14] K. Takada, Epstein-Barr virus and gastric carcinoma, *Mol. Pathol.* 53 (2000) 255–261.
- [15] S.U.T. Nakamura, T. Yao, T. Ueyama, M. Tsuneyoshi, Epstein-Barr virus in gastric carcinoma with lymphoid stroma. Special reference to its detection by the polymerase chain reaction and in situ hybridization in 99 tumors, including a morphologic analysis, *Cancer* 73 (1994) 2239–2249.
- [16] J. Nishikawa, H. Iizasa, H. Yoshiyama, K. Shimokuri, Y. Kobayashi, S. Sasaki, et al., Clinical importance of Epstein(-)Barr virus-associated gastric cancer, *Cancers (Basel)* (2018) 10.
- [17] J. Arikawa, M. Tokunaga, Y. Tashiro, S. Tanaka, E. Sato, K. Haraguchi, A. Yamamoto, O. Toyohira, A. Tsuchimochi, Epstein-Barr virus-positive multiple early gastric cancers and dysplastic lesions: a case report, *Pathol. Int.* 47 (1997) 730–734.
- [18] T.A. Rockall, A. Darzi, Robot-assisted laparoscopic colorectal surgery, *Surg. Clin. North Am.* 83 (2003) 1463–1468.
- [19] S. Lee, J.K. Kim, Y.N. Kim, D.S. Jang, Y.N. Kim, T. Son, et al., Safety and feasibility of reduced-port robotic distal gastrectomy for gastric cancer: a phase I/II clinical trial, *Surg. Endosc.* 31 (2017) 4002–4009.
- [20] K. Suda, I.M. Man, Y. Ishida, Y. Kawamura, S. Satoh, I. Uyama, Potential advantages of robotic radical gastrectomy for gastric adenocarcinoma in comparison with conventional laparoscopic approach: a single institutional retrospective comparative cohort study, *Surg. Endosc.* 29 (2015) 673–685.
- [21] K. Chen, Y. Pan, B. Zhang, H. Maher, X.F. Wang, X.J. Cai, Robotic versus laparoscopic gastrectomy for gastric cancer: a systematic review and updated meta-analysis, *BMC Surg.* 17 (2017) 93.
- [22] H.M. Yoon, Y.W. Kim, J.H. Lee, K.W. Ryu, B.W. Eom, J.Y. Park, et al., Robot-assisted total gastrectomy is comparable with laparoscopically assisted total gastrectomy for early gastric cancer, *Surg. Endosc.* 26 (2012) 1377–1381.

Open Access

This article is published Open Access at [sciencedirect.com](https://www.sciencedirect.com). It is distributed under the [IJSCR Supplemental terms and conditions](#), which permits unrestricted non commercial use, distribution, and reproduction in any medium, provided the original authors and source are credited.