

Clinical Article



A Comparative Study on the Treatment of Osteoporotic Vertebral Compression Fractures With Early Ambulation and at Least 1 Week of Absolute Bed Rest

Gi Hun Kim and Tack Geun Cho

Department of Neurosurgery, Kangnam Sacred Heart Hospital, Hallym University College of Medicine, Seoul, Korea



Received: Dec 17, 2021
Revised: Jan 3, 2022
Accepted: Feb 23, 2022
Published online: Mar 10, 2022

Address for correspondence:

Tack Geun Cho

Department of Neurosurgery, Kangnam Sacred Heart Hospital, Hallym University College of Medicine, 1 Singil-ro, Yeongdeungpo-gu, Seoul 07441, Korea.
Email: jotak01@naver.com

Copyright © 2022 Korean Neurotraumatology Society

This is an Open Access article distributed under the terms of the Creative Commons Attribution Non-Commercial License (<https://creativecommons.org/licenses/by-nc/4.0/>) which permits unrestricted non-commercial use, distribution, and reproduction in any medium, provided the original work is properly cited.

ORCID iDs

Gi Hun Kim
<https://orcid.org/0000-0002-9767-2553>
Tack Geun Cho
<https://orcid.org/0000-0003-0420-3887>

Conflict of Interest

The authors have no financial conflicts of interest.

ABSTRACT

Objective: This study aimed to determine whether absolute bed rest (ABR) is essential for the conservative treatment of osteoporotic vertebral compression fractures (OVCFs).

Methods: This study included 115 patients diagnosed with OVCFs. The patients in group A were allowed to ambulate as soon as possible, while those in group B underwent ABR for at least 1 week. X-ray images at baseline and 1 week, 2 weeks, 1 month, 3 months, and 6 months after trauma were obtained from both groups for assessment. In each group, ABR-related complications including constipation, indigestion, Foley catheter insertion, urinary tract infection, cough/sputum, dizziness, and neurasthenia were investigated.

Results: In both groups, the compression rates, Cobb angles, and visual analog scale scores did not differ significantly at baseline and the first, second, third, fourth, and fifth follow-ups. In terms of constipation, indigestion, dizziness, and neurasthenia, group A reported a significantly higher complication rate than group B ($p < 0.05$).

Conclusion: The prognosis did not differ significantly between patients who underwent ABR for at least 1 week and those who started walking as soon as possible. The incidence of complications due to ABRs was lower in the early ambulatory group. Therefore, it may be helpful to start walking as early as possible during the conservative treatment of OVCFs.

Keywords: Fractures, compression; Bed rest; Complications; Treatment outcome

INTRODUCTION

Compression fractures are usually caused by osteoporosis, trauma, tumors, or infections.^{2,9,10,17} They are more common in older people since the bone mineral density (BMD) decreases with age,^{3,22,24} and often result in spinal deformities, such as loss of vertebral height, kyphosis, and kyphoscoliosis.^{13,15,18} However, in patients with osteoporotic vertebral compression fractures (OVCFs), the trauma is not severe or often occurs during walking.²⁹ In the conservative management of OVCFs, absolute bed rest (ABR) and the use of orthoses for some time have been suggested to prevent the deterioration of the fractures and relieve pain.^{12,15,20,22} Nevertheless, a protocol for the conservative treatment of OVCF has not

yet been established. Different doctors have different approaches to conservative treatment of compression fractures. Some doctors recommend ABR for a certain period to prevent fractures from worsening, while some doctors recommend early ambulation for patients with mild pain, assuming that the complications from ABR are more serious. Some patients often complain that ABR is associated with some discomfort. Constipation, gastrointestinal problems, difficulty voiding, urinary tract infections, cough/sputum, dizziness, neurasthenia, etc., have been reported as complications of ABR.^{6,8,21)} Considering that bed rest may be inconvenient and can cause various complications, the purpose of this study was to investigate the difference in prognosis and ABR-related complications between patients with OVCFs managed with bed rest and those allowed to ambulate as soon as they could, and to establish a protocol for conservative treatment of OVCF.

MATERIALS AND METHODS

Patients

From January 2019 to June 2020, a retrospective study was conducted on patients who were hospitalized in the Department of Neurosurgery and who were diagnosed with compression fractures. Cases of pathological fractures due to tumors, fractures due to infectious spondylitis, serious accidents (such as major traffic accident and falling from a height of 1.5 m or more), who underwent early surgery (post fixation/balloon kyphoplasty/vertebroplasty), spinal cord injury with neurological deficits, inability to move due to accompanying injuries (such as a fracture of the pelvis or lower extremity), or loss of consciousness due to head injury were excluded. A total of 115 patients were included in this study. They were divided into two groups: one group where patients were allowed to ambulate as soon as possible (group A, n=74), and the other group where patients had ABR for at least one week (group B, n=41) regardless of pain. In group B, patients were allowed to ambulate as soon as possible after at least one week. Patients admitted on even-numbered days were classified into group A, and patients admitted on odd-numbered days were classified into group B.

Methods

The changes in the patterns of the compression fractures, visual analog scale (VAS) scores, and complications were compared between the two groups. In each group, the subjects' age, sex, length of hospital stay, BMD and fracture level, trauma history, route of visit, ABR period, VAS scores and compression rate, and ABR-related complications in each ABR period were investigated.

The compression rate of OVCFs was calculated as $100 - [b/(a+c/2)] \times 100$, where "a" and "c" represent the normal vertebral bodies one level higher and lower than the compression-fractured vertebral body, respectively, and "b" represents the height of the compression-fractured vertebral body (FIGURE 1).²⁵⁾ A kyphotic deformity was assessed by measuring the Cobb angle, which was measured as the angle between the superior endplate of the vertebral body above and the inferior endplate of the vertebral body below (FIGURE 1).¹⁾ The courses of the groups were monitored at baseline and at one week, two weeks, one month, three months, and six months after trauma using X-ray images to assess for the development of complications during the admission period. ABR-related complications included constipation, indigestion, Foley catheter insertion, urinary tract infections, cough/sputum, dizziness, and neurasthenia.

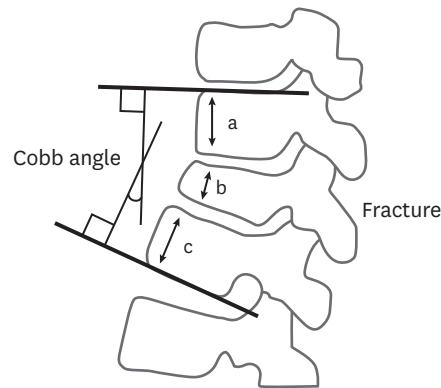


FIGURE 1. Calculation of compression rate and Cobb angle in compression fractures.

Statistical analysis was performed using SPSS statistical software ver. 19.0.0 (SPSS Inc., Chicago, IL, USA), and the χ^2 test, Fisher’s exact test, and independent samples *t*-test were used. Statistical significance was set at $p < 0.05$.

RESULTS

The male-to-female ratio was 27:73. The mean age was 71.1 ± 10.7 years. The mean BMD was -2.5 ± 1.2 (TABLE 1). The numbers of patients who visited the outpatient clinic and those who came into the emergency room were similar (TABLE 1). T12 and L1 fractures were the most common (>50%) (FIGURE 2). There were no statistically significant differences between the two groups. The start of ambulation was on day 3.0 ± 1.2 for group A and day 9.0 ± 1.5 for group B ($p < 0.05$). The duration of hospital stay was 10.3 ± 5.5 days for group A and 14.8 ± 6.0 days for group B ($p < 0.05$) (TABLE 1). Complications, such as constipation, gastrointestinal problems, difficulty voiding, urinary tract infections, cough/sputum, dizziness, and neurasthenia, were higher in group B (68.3%, 65.9%, 19.5%, 4.9%, 12.2%, 12.2%, and 24.4%, respectively) than in group A (44.6%, 33.8%, 8.1%, 0%, 5.4%, 2.7%, and 6.8%, respectively). In particular,

TABLE 1. Characteristics of the study patients

Characteristics	Group A (n=74)	Group B (n=41)	p-value
Sex (male:female)	18:56	13:28	0.309
Age	72.00 ± 10.19	69.44 ± 11.59	0.222
BMD	-2.94 ± 1.20	-2.66 ± 1.25	0.268
BMI	20.39 ± 3.10	22.02 ± 3.16	0.308
Trauma history			
Stumble	46 (62.2)	19 (46.3)	
Fall down	10 (13.5)	7 (17.1)	
Sprain	9 (12.2)	9 (22.2)	
Traffic accident	9 (12.2)	6 (14.6)	
Visit route			
Out patient department	38 (51.4)	18 (43.9)	
Emergency room	36 (48.6)	23 (56.1)	
ABR period (days)	2.95 ± 1.19	8.95 ± 1.45	0.008 [†]
Hospitalization period (days)	10.32 ± 5.51	14.81 ± 6.04	0.02 [*]

Data are shown as mean±SD and number (%).

Data are shown as below: group A, ambulation as soon as possible; group B, 1 week ABR.

Major traffic accidents causing severe injuries, including potential internal injuries, spinal cord injuries, traumatic brain injuries, and other major injuries up to and including death were excluded.

BMD: bone mineral density, BMI: body mass index, ABR: absolute bed rest.

*p-value<0.05; †p-value<0.01.

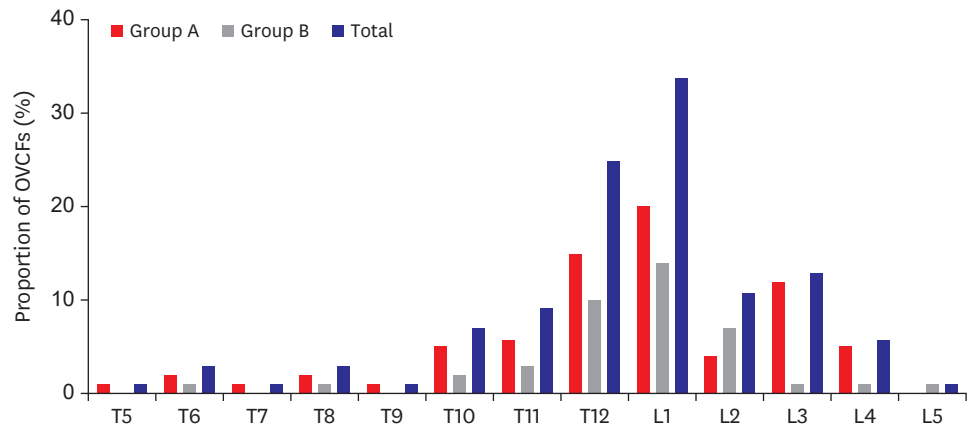


FIGURE 2. Compression fracture level in both groups. There were no statistically significant differences between the two groups ($p>0.05$).

TABLE 2. Absolute bed rest -related complications

Complications	Group A (n=74)	Group B (n=41)	Total (n=115)	p-value
Constipation	33 (44.6)	28 (68.3)	61 (53.0)	0.019*
GI trouble	25 (33.8)	27 (65.9)	52 (45.2)	0.001†
Voiding difficulty	6 (8.1)	8 (19.5)	14 (12.2)	0.073
Urinary tract infection	0 (0)	2 (4.9)	2 (1.7)	0.055
Cough/sputum	4 (5.4)	5 (12.2)	9 (7.8)	0.194
Dizziness	2 (2.7)	5 (12.2)	7 (6.1)	0.041*
Neurasthenia	5 (6.8)	10 (24.4)	15 (13.0)	0.009†
Complications‡	45 (60.8)	35 (85)	80 (69.6)	0.007†

Data are shown as number (%).

*p-value<0.05; †p-value<0.01; ‡Number of patients with any complications.

constipation, indigestion, dizziness, and neurasthenia were significantly higher in group B ($p<0.05$) (TABLE 2).

There were no differences in compression rates, Cobb angles, and VAS scores between the two groups at one week and two weeks after admission (TABLES 3-5). In group A, 4 subjects underwent surgery (vertebroplasty/balloon kyphoplasty); as did 3 subjects in group B, which

TABLE 3. Compression rate after admission in both groups

Compression rate	Group A	Group B	p-value
Initial compression rate (%)	17.10±15.82	19.19±10.92	0.122
First follow up (1 week) (%)	20.64±16.03	20.15±11.17	0.089
Second follow up (2 week) (%)	25.56±19.34	25.66±13.75	0.065
Third follow up (1 month) (%)	28.08±15.88	33.17±11.81	0.115
Fourth follow up (3 month) (%)	31.11±15.17	34.08±13.43	0.566
Fifth follow up (6 month) (%)	33.38±21.48	34.25±13.31	0.051

Data are shown as mean±SD.

TABLE 4. Cobb angle after admission in both groups

Cobb angle	Group A	Group B	p-value
Initial Cobb angle (°)	14.02±9.41	15.17±11.01	0.253
First follow up (1 week) (°)	15.67±9.19	16.18±7.34	0.056
Second follow up (2 week) (°)	15.76±10.33	16.68±6.94	0.103
Third follow up (1 month) (°)	15.95±9.84	16.72±7.32	0.137
Fourth follow up (3 month) (°)	16.73±10.83	17.68±7.64	0.130
Fifth follow up (6 month) (°)	17.33±10.82	17.78±8.88	0.387

Data are shown as mean±SD.

TABLE 5. VAS score after admission in both groups

VAS score	Group A	Group B	p-value
Initial VAS score	6.42±9.41	6.15±1.04	0.207
First follow up (1 week)	3.75±0.71	3.76±0.77	0.143
Second follow up (2 week)	2.55±1.21	2.64±0.96	0.229
Third follow up (1 month)	2.23±1.05	2.34±1.14	0.261
Fourth follow up (3 month)	2.75±1.94	2.50±1.57	0.540
Fifth follow up (6 month)	1.68±1.09	1.93±0.83	0.579

Data are shown as mean±SD.

VAS: visual analog scale.

TABLE 6. Patients undergoing surgery during conservative treatment period

Patients undergoing surgery	Group A (n=74)	Group B (n=41)	Total (n=115)	p-value
VP/BKP	4 (5.4)	3 (7)	7 (6.1)	0.484
Day to operation (days)	21.41±11.09	18.68±15.09	20.24±12.80	0.172

Data are shown as mean±SD and number (%).

VP: vertebroplasty, BKP: balloon kyphoplasty.

figures show no difference between the groups ($p=0.484$) (TABLE 6). Vertebroplasty/balloon kyphoplasty were performed 21.41±11.09 days after admission in group A and 18.68±15.09 days after the admission in group B ($p=0.172$). There were no differences even up to six months after surgery.

DISCUSSION

Percutaneous vertebroplasty and balloon kyphoplasty are the main surgical treatments for vertebral compression fractures.^{4,11,12,15,23} However, many patients with OVCFs and mild kyphosis often choose conservative treatments because of their favorable results and for psychological or economic reasons. Nevertheless, a clear protocol for the conservative treatment of OVCFs has not yet been established.^{12,15,28}

Pain relief, vertebral stability, rehabilitation, and osteoporosis are general treatment goals for OVCF.¹⁶ The Acute pain associated with OVCFs usually subsides within six to twelve weeks.^{18,19,26,28} During this period, orthoses, analgesics, and bed rest have been suggested as conservative treatments.²⁶ In particular, bed rest can prevent bone resorption and secondary fractures.⁶ Several studies have investigated the optimal ABR period. A previous study showed that there was no statistical difference between two bed rest groups: one having ABR for one week and another having ABR for two weeks.⁷ Other studies include those in which bed rest was for three days, those in which the elderly had a longer bed rest period,²⁷ and those that did not recommend bed rest.⁵ Nonetheless, these studies did not clearly suggest an optimal period of ABR. In this study, the group where patients started walking as soon as it was possible for them to (without a fixed ABR period) was compared with the group in which patients had an ABR period of one week or longer.

In the study conducted by Cha et al.,⁷ groups A and B were put on ABR (one week for group A and two weeks for group B). The researchers investigated the correlations between several factors, such as sex, age, BMD, fracture level, clinical deterioration, and complications due to ABR. No statistically significant differences were observed in the incidence of clinical exacerbations between the one- and two-week ABR groups in this study. Since complications due to ABR occurred more frequently in the two-week ABR group, short-term ABR was recommended in this study.

In both groups, the compression rates were not significantly different at baseline and at one week, two weeks, one month, three months, and six months after trauma. In both groups, the proportion of female patients was higher than that of male patients, and the same trend was observed in other studies. The vertebral bodies that most commonly had compression fractures were T12 and L1 in both groups (FIGURE 1). The results of other studies were similar to those of this study because the thoracolumbar junction is the part where the stiff thoracic vertebrae with large rotational motion and the flexible lumbar vertebrae with large flexion motion meet.²⁾

Complications of bed rest include constipation, indigestion, Foley catheter insertion, urinary tract infections, cough/sputum, dizziness, and neurasthenia.⁷⁾ Psychotherapy, passive stretching, neuromuscular electrical stimulation, and early ambulation are recommended for the treatment of these complications.⁶⁾ In addition, ambulation can also help prevent further injuries, realign the spine, and strengthen its axial strength.^{15,28)} In this study, there were no serious life-threatening complications in either group. The most common complication in both groups was constipation, followed by indigestion. The incidence of all complications was higher in group B than in group A. Moreover, the incidence of constipation ($p=0.019$), indigestion ($p=0.001$), dizziness ($p=0.041$), and neurasthenia ($p=0.009$) significantly increased with one-week bed rest ($p<0.05$). Most of the complications were controlled with medications, and most of the symptoms disappeared when the patients started ambulating. The length of hospital stay was also significantly shorter in group A than in group B ($p<0.05$). Therefore, it is explained that there were fewer complications in the group with early walking than in the ABR group for 1 week.

However, as this was a retrospective study, the patients were not randomly divided into two groups, and there was a limitation of the follow-up period between groups not being constant. However, the 1st and 2nd follow-up periods were all almost similar at one and two weeks, and the follow-up intervals thereafter varied from patient to patient. Considering that the average hospitalization period of the patients was two to three weeks and the outpatient treatment after discharge was the same in both groups, this study, evaluating the presence of complications during hospitalization, is considered to be reliable.

CONCLUSION

There was no significant difference in prognosis between the cases that had ABR for at least one week and those that started walking as soon as possible. The incidence of complications due to ABR was lower in the early ambulatory group. In conclusion, it is considered helpful to start walking as early as possible in the conservative treatment of OVCFs.

REFERENCES

1. Alanay A, Pekmezci M, Karaeminogullari O, Acaroglu E, Yazici M, Cil A, et al. Radiographic measurement of the sagittal plane deformity in patients with osteoporotic spinal fractures evaluation of intrinsic error. *Eur Spine J* 16:2126-2132, 2007
[PUBMED](#) | [CROSSREF](#)
2. Alexandru D, So W. Evaluation and management of vertebral compression fractures. *Perm J* 16:46-51, 2012
[PUBMED](#) | [CROSSREF](#)

3. Anselmetti GC, Bernard J, Blatter T, Court C, Fagan D, Fransen H, et al. Criteria for the appropriate treatment of osteoporotic vertebral compression fractures. *Pain Physician* 16:E519-E530, 2013
[PUBMED](#) | [CROSSREF](#)
4. Bernardo WM, Anhesini M, Buzzini R; Brazilian Medical Association (AMB). Osteoporotic vertebral compression fracture - treatment with kyphoplasty and vertebroplasty. *Rev Assoc Med Bras (1992)* 64:204-207, 2018
[PUBMED](#) | [CROSSREF](#)
5. Bornemann R, Hanna M, Kabir K, Goost H, Wirtz DC, Pflugmacher R. Continuing conservative care versus crossover to radiofrequency kyphoplasty: a comparative effectiveness study on the treatment of vertebral body fractures. *Eur Spine J* 21:930-936, 2012
[PUBMED](#) | [CROSSREF](#)
6. Brower RG. Consequences of bed rest. *Crit Care Med* 37:S422-S428, 2009
[PUBMED](#) | [CROSSREF](#)
7. Cha KH, Cho TG, Kim CH, Lee HK, Moon JG. Comparative study on the period of absolute bed rest of vertebral compression fracture. *Korean J Spine* 10:144-148, 2013
[PUBMED](#) | [CROSSREF](#)
8. Chosa K, Naito A, Awai K. Newly developed compression fractures after percutaneous vertebroplasty: comparison with conservative treatment. *Jpn J Radiol* 29:335-341, 2011
[PUBMED](#) | [CROSSREF](#)
9. Gardner MJ, Demetrakopoulos D, Shindle MK, Griffith MH, Lane JM. Osteoporosis and skeletal fractures. *HSS J* 2:62-69, 2006
[PUBMED](#) | [CROSSREF](#)
10. Goldstein CL, Chutkan NB, Choma TJ, Orr RD. Management of the elderly with vertebral compression fractures. *Neurosurgery* 77 Suppl 4:S33-S45, 2015
[PUBMED](#) | [CROSSREF](#)
11. Guo JB, Zhu Y, Chen BL, Xie B, Zhang WY, Yang YJ, et al. Surgical versus non-surgical treatment for vertebral compression fracture with osteopenia: a systematic review and meta-analysis. *PLoS One* 10:e0127145, 2015
[PUBMED](#) | [CROSSREF](#)
12. Hoyt D, Urits I, Orhurhu V, Orhurhu MS, Callan J, Powell J, et al. Current concepts in the management of vertebral compression fractures. *Curr Pain Headache Rep* 24:16, 2020
[PUBMED](#) | [CROSSREF](#)
13. Kado DM, Browner WS, Palermo L, Nevitt MC, Genant HK, Cummings SR. Vertebral fractures and mortality in older women: a prospective study. Study of Osteoporotic Fractures Research Group. *Arch Intern Med* 159:1215-1220, 1999
[PUBMED](#) | [CROSSREF](#)
14. Kanis JA. Diagnosis of osteoporosis and assessment of fracture risk. *Lancet* 359:1929-1936, 2002
[PUBMED](#) | [CROSSREF](#)
15. Longo UG, Loppini M, Denaro L, Maffulli N, Denaro V. Conservative management of patients with an osteoporotic vertebral fracture: a review of the literature. *J Bone Joint Surg Br* 94:152-157, 2012
[PUBMED](#) | [CROSSREF](#)
16. Longo UG, Loppini M, Denaro L, Maffulli N, Denaro V. Osteoporotic vertebral fractures: current concepts of conservative care. *Br Med Bull* 102:171-189, 2012
[PUBMED](#) | [CROSSREF](#)
17. Megale RZ, Pollack A, Britt H, Latimer J, Naganathan V, McLachlan AJ, et al. Management of vertebral compression fracture in general practice: BEACH program. *PLoS One* 12:e0176351, 2017
[PUBMED](#) | [CROSSREF](#)
18. Old JL, Calvert M. Vertebral compression fractures in the elderly. *Am Fam Physician* 69:111-116, 2004.
[PUBMED](#)
19. Park DY, Choi I, Kim TG, Kim WJ, Shin IY, Khil EK. Gray ramus communicans nerve block for acute pain control in vertebral compression fracture. *Medicina (Kaunas)* 57:744, 2021
[PUBMED](#) | [CROSSREF](#)
20. Parreira PCS, Maher CG, Megale RZ, March L, Ferreira ML. An overview of clinical guidelines for the management of vertebral compression fracture: a systematic review. *Spine J* 17:1932-1938, 2017
[PUBMED](#) | [CROSSREF](#)
21. Rousing R, Andersen MO, Jespersen SM, Thomsen K, Lauritsen J. Percutaneous vertebroplasty compared to conservative treatment in patients with painful acute or subacute osteoporotic vertebral fractures: three-months follow-up in a clinical randomized study. *Spine* 34:1349-1354, 2009
[PUBMED](#) | [CROSSREF](#)

22. Rzewuska M, Ferreira M, McLachlan AJ, Machado GC, Maher CG. The efficacy of conservative treatment of osteoporotic compression fractures on acute pain relief: a systematic review with meta-analysis. *Eur Spine J* 24:702-714, 2015
[PUBMED](#) | [CROSSREF](#)
23. Lee SM, Oh HS, Lee SH, Lee HC, Hwang BW. Cement augmented anterior reconstruction and decompression without posterior instrumentation: a less invasive surgical option for osteoporotic thoracolumbar fracture with cord compression. *Korean J Neurotrauma* 16:190-199, 2020
[PUBMED](#) | [CROSSREF](#)
24. Solberg J, Copenhaver D, Fishman SM. Medial branch nerve block and ablation as a novel approach to pain related to vertebral compression fracture. *Curr Opin Anaesthesiol* 29:596-599, 2016
[PUBMED](#) | [CROSSREF](#)
25. Son KH, Chung NS, Jeon CH. Measurement of vertebral compression and kyphosis in the thoracolumbar and lumbar fractures. *J Korean Soc Spine Surg* 17:120-126, 2010
[CROSSREF](#)
26. Tae HS, Kim SD, Park JY, Kim SH, Lim DJ, Suh JK. Gray ramus communicans nerve block: a useful therapeutic adjuvant for painful osteoporotic vertebral compression fracture. *J Korean Neurosurg Soc* 34:505-508, 2003
27. Truumees E, Hilibrand A, Vaccaro AR. Percutaneous vertebral augmentation. *Spine J* 4:218-229, 2004
[PUBMED](#) | [CROSSREF](#)
28. Vorlat P, Leirs G, Tajdar F, Hulsmans H, De Boeck H, Vaes P. Predictors of recovery after conservative treatment of AO-type A thoracolumbar spine fractures without neurological deficit. *Spine* 43:141-147, 2018
[PUBMED](#) | [CROSSREF](#)
29. Yamauchi K, Adachi A, Kameyama M, Murakami M, Sato Y, Kato C, et al. A risk factor associated with subsequent new vertebral compression fracture after conservative therapy for patients with vertebral compression fracture: a retrospective observational study. *Arch Osteoporos* 15:9, 2020
[PUBMED](#) | [CROSSREF](#)